



An Exhaustive Echocardiographic Analysis of Left Ventricular Structure and Functions in Children with Duchenne Muscular Dystrophy

Helen Bornaun,^{1*} Murat Muhtar Yilmazer,² Savas Dedeoglu,³ and Reyhan Dedeoglu⁴

¹Department of Pediatric Cardiology, Kanuni Sultan Suleyman Educational and Research Hospital, Istanbul, Turkey

²Department of Pediatric Cardiology, SBU Izmir Dr. Behcet Uz Children's Hospital, Izmir, Turkey

³Department of Health Sciences, Uskudar University, Istanbul, Turkey

⁴Department of Pediatric Cardiology, Cerrahpasa Medical Faculty Istanbul University, Istanbul, Turkey

*Corresponding author: Helen Bornaun, MD., Kanuni Sultan Suleyman Educational and Research Hospital, Department of Pediatric Cardiology, Istanbul, Turkey. Tel: +90-506343952, E-mail: helenbornaun@gmail.com

Received 2017 October 19; Revised 2018 January 30; Accepted 2018 April 02.

Abstract

Objectives: We aim to characterize cardiac morphological and functional changes by echocardiography that are present in the early and late stages of Duchenne type muscular dystrophy (DMD).

Methods: Sixty-two patients with DMD and 62 healthy children were included in the study. Study group was divided into patients with systolic dysfunction group Ia and those without systolic dysfunction group Ib. Transthoracic echocardiography was performed in all individuals in the study. Left ventricular end diastolic diameter (LVEDd), left ventricular end systolic diameter (LVSD), posterior wall thickness (LVPWd), interventricular septal thickness (IVSD), ejection fraction and fractional shortening (FS), LV mass index (LVmassi), early (E) and late (A) transmitral inflow velocities, the ratio of early-to-late peak velocities (E/A) were recorded. Tissue Doppler measurements of the peak early (E') and late diastolic (A') annular velocities, Doppler measurements of pressure half time (PHT) and mitral valve area were measured.

Results: DMD patients had significantly higher LVmass, LVmass index and mitral valve area ($P < 0.05$). Patients showed significantly lower EF values ($P < 0.001$), SF ($P < 0.001$), stroke volume ($P < 0.05$), cardiac output ($P < 0.05$), Mitral valve PHT ($P < 0.001$), Mitral E' ($P < 0.001$), Mitral A' ($P < 0.001$), E'/A' ratio ($P < 0.001$) than the control patients. Group Ia patients had higher age, LVH and LV mass index, LVEDd ($P < 0.05$), LVSD ($P < 0.05$), IVSD ($P < 0.05$) and LVPWd ($P < 0.05$) compared to group Ib patients ($P < 0.05$). There was a positive linear correlation between age and LVPWd ($P < 0.001$, $r = 0.446$).

Conclusions: Our study showed that diastolic functions began to deteriorate in the early phase of DMD and systolic impairment begins subclinically in early stages.

Keywords: Muscular Dystrophy, Duchenne, Cardiac, Echocardiography, Diastole

1. Background

Duchenne-type muscular dystrophy (DMD) is an X-linked recessive disease that primarily affects the skeletal and cardiac muscles. DMD is the most common form of hereditary neuromuscular disorders that results from a dystrophin gene mutation which is located at Xp21.1. Dystrophin is the cytoskeletal protein that provides a mechanical integrity of the sarcolemma. Dystrophin deficiency causes mechanical weakening of the sarcolemma resulting in inappropriate calcium influx from loss of membrane integrity. The cascade of calcium influx activates proteases that lead to death of the cardiomyocytes. Degeneration begins at the cellular level, results in a cardiac fibrosis

and ultimately formation of dilated cardiomyopathy. The main feature of the disease, as a result of skeletal muscle involvement is progressive muscle weakness (1-4).

Symptoms usually appear in male children before age 6 and may be visible in early infancy. In the later stage, progressive cardiac involvement and muscle degeneration can occur. Cardiac muscle degeneration is associated with fibrous tissue replacement with fatty infiltration. Degenerative changes in the myocardium can cause conduction abnormalities besides dilated cardiomyopathy phenotype (5-7). Myocardial degeneration that leads a maladaptive remodeling, results in cardiac diastolic and systolic dysfunction. This may induce cardiac failure and fatal arrhythmias (8). Cardiac symptoms usually become noticeable after the

age of 10 years and increase in incidence with age (7).

Although recent studies suggested that some genotypes lead to develop cardiac failure in early period of the disease, this is not exactly proven (9-11). Echocardiography is usually first diagnostic tool for the diagnosis of cardiac involvement. However standard echocardiographic methods may fail to detect early changes of myocardial involvement. Tissue Doppler imaging is more useful in the demonstration of myocardial tissue abnormalities before the development of demonstrable systolic dysfunction (12, 13). This study was undertaken to characterize cardiac morphological and functional changes by echocardiography that are present in the early and late stages of DMD.

2. Methods

2.1. Patient Population

This study included all patients diagnosed as DMD who were on follow-up of the pediatric cardiology department of the Istanbul University, Istanbul Medical Faculty. The final diagnosis of DMD was made on the basis of established criteria including genetic analysis, muscular biopsy, or typical clinical findings (neurologic signs, increased creatine phosphokinase levels, and typical calf hypertrophy) (14). Female carriers and patients with Becker muscular dystrophy were excluded.

2.2. Study and Control Groups Included in the Study

Study group was divided into two subgroups as DMD patients with systolic impairment group Ia (n = 32) and those without systolic impairment Group Ib (n = 30). Systolic impairment group consisted of patients whose ejection fraction values were under $60 \pm 5\%$. We wanted to observe if there was any difference between the patients according to their measured data. Our statisticians suggested to group patients according to their EF values. Because the patients had clustered around two values of EF 55 and 65 ranges, we decided to take 1 standard deviation above or below the mean range $60 \pm 5\%$ for ejection fraction (15). Control group consisted of 62 age- and gender-matched healthy children. Control subjects were obtained among children investigated for physiological cardiac murmur. The study protocol was approved by the Hospital Ethics Committee, and written informed consent was obtained.

2.3. Echocardiography

Transthoracic echocardiography by 2-D, Doppler and M-mode was performed with an Vivid-3 echocardiography device (General Electric, USA) with a 3 MHz transducer. All

patients were examined according to the recommendations of American society of echocardiography (16). Each echocardiographic measurement was taken at least three times. Left ventricular end diastolic diameter (LVEDd), left ventricular end systolic diameter (LVSD), ejection fraction (EF) and fractional shortening (FS) were measured by M-mode echocardiography. According to M-mode measurements left ventricular volumes were obtained by Teicholz formula (17).

Left ventricular mass (LV mass) was also estimated by M-mode measurements. For measurement of the components of LV mass including LVEDd, posterior wall thickness (LVPWd) and interventricular septal thickness (IVSd) the following formula was used: $0.8 \times [1.04 \times \{(LVEDd + LVPWd + IVSd)^3 - (LVEDd)^3\}] + 0.6g$. We also calculated LV mass index (LV mass_i) by dividing the LV Mass to body surface area (BSA) (LV mass/BSA (g/m^2)) (18).

Relative wall thickness (RWT) enabled to further classification of increase in LV mass as either concentric hypertrophy (RWT > 0.42) or eccentric hypertrophy (RWT \leq 0.42). Relative wall thickness of the LV was stated as the ratio of twice the posterior wall thickness at end diastole to the end diastolic ventricular dimension ($2 \times LVPWd/LVEDd$). The echocardiographic characteristics according to LV mass and RWT measurements determined left ventricular geometry pattern (19).

Mitral inflow patterns were recorded from the apical four-chamber view with the pulsed wave Doppler. Early (E) and late (A) transmitral inflow velocities, the ratio of early-to-late peak velocities (E/A) were recorded. Left ventricular myocardial diastolic properties were assessed using tissue Doppler imaging. Tissue Doppler measurements were performed in the apical four-chamber view. A sample volume was placed at the lateral corner of the mitral annulus for measurements of the peak early (E') and late diastolic (A') annular velocities. Cardiac diastolic function has passive and active processes. Ventricular relaxation is the active phase and determined by the ratio of E wave to A wave and ratio E' to A'. The passive phase is the ventricular compliance that is determined by the ratio of E/E' (20).

The key variables recommended for assessment of LV diastolic function grade include mitral flow velocities, mitral annular e' velocity and E/E' ratio (21).

We also measured pressure half time (PHT) and mitral valve area from the transmitral Doppler recordings. PHT is obtained by tracing the deceleration slope of the E-wave on Doppler spectral display of transmitral flow. Mitral valve area was determined by the formula $220/PTH$ (22, 23).

2.4. Statistical Methods

The statistical analysis was performed using the statistical package for social sciences version 15 (SPSS Inc,

Chicago, IL, USA). All continuous variables were tested for normal distribution by Kolmogorov-Smirnov test. Baseline hemodynamic characteristics were compared between patients and controls using the t-test (in normally distributed data with equal variances) and Mann-Whitney U-test (with unequal variances). Categorical variables were expressed in frequency and percentage and differences in frequencies were analyzed with chi-square tests. Data were expressed as mean \pm standard deviation or median and ranges. P values < 0.05 were considered as statistically significant.

3. Results

There were no statistical differences in age, gender, or body surface area between study and control groups. The age ranges of the patients with systolic impairment, without systolic impairment and control group were 9.9 ± 1.6 , 7.9 ± 2.91 , and 8.5 ± 3.63 years, respectively. Baseline characteristics of the study and control groups are summarized in [Table 1](#).

3.1. Echocardiographic Characteristics of Normal and DMD Subjects

The echocardiographic properties including M-mode, 2-D Doppler and TDI measurements of the study samples were assessed. Compared with the normal subjects, DMD patients had significantly higher ($P < 0.05$) LVmass, LV mass index and mitral valve area ($P < 0.001$) ([Table 1](#)). These echocardiographic measurements were compared within study groups and control groups. However DMD patients showed significantly lower EF ($P < 0.001$) and SF ($P < 0.001$) values, than the control patients. Patients with DMD had lower values of mitral valve PHT ($P < 0.001$). There was no significant difference between patients and control peers in terms of other measured variables.

3.2. Comparison of Subgroups of the Patients

Approximately half of the study group ($n=30$) had normal left ventricular EF (mean \pm SD; 69 ± 4.9) which constituted group Ib. The remainder of the DMD patients; group Ia had lower EF (54.9 ± 9.3). Cardiac involvement are known to become more prominent with the progression of age in DMD. Therefore group Ia patients had higher age compared to group Ib patients ($P < 0.05$) ([Table 2](#)). Compared with the group Ib subjects, group Ia patients had significantly higher ($P < 0.01$) LVH and LV mass index ([Table 2](#)). Group Ia patients also had increased LVEDd ($P < 0.05$), LVSD ($P < 0.05$), IVSd ($P < 0.05$) and LVPWd ($P < 0.05$). There was a positive correlation between age and LVPWd ($P < 0.001$; $r = 0.446$) ([Figure 1](#)).

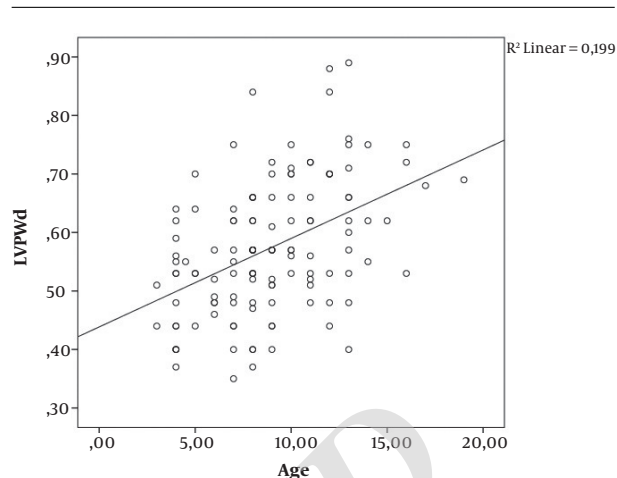


Figure 1. Correlation graphics of left ventricular posterior wall diameter (LVPWd) and age

Consequently, LV mass index was significantly increased in group Ia patients compared to other groups ($P < 0.05$) ([Table 2](#)). The other parameter of hypertrophy was RWT which allows to classify the hypertrophy pattern as concentric (if $RWT > 0.42$) or eccentric (if $RWT < 0.42$). In both 3 groups of this study, RWT was under the ratio of 0.42 and there was no statistically significant difference in RWT values between study and control groups. Left ventricular hypertrophy or increase in mass can change the left ventricular geometry that generally occurs as an adaptive mechanism to various physiological and pathological conditions. The LVmass was increased in group Ia patients as mentioned before. The LV diastolic volume calculated by 2-D echocardiography was significantly increased in group I patients ($P < 0.05$).

3.3. Doppler and TDI Parameters

Comparison of mitral inflow patterns including E wave, A wave and E/A ratio of the DMD patients and control peers, there was no statistically significant difference. Pressure half time measured from the mitral inflow was lower in group Ia than in other groups ($P > 0.05$) ([Table 2](#)). There was also significant difference between group Ib and control groups in terms of PHT ($P < 0.05$). We also measured mitral valve area from mitral inflow waves by Doppler technique. Mitral valve area was significantly increased in both DMD groups compared with the values obtained by controls. In addition patients with systolic impairment showed strictly increased MVA values compared with remaining DMD patients ($P < 0.05$).

Tissue Doppler imaging was used to measure peak myocardial velocities which showed alterations in regional

Table 1. Comparison of the Variables in Patients with Duchenne Muscular Dystrophy and Controls

Variables	Patients with DMD (n = 62)	Controls (n = 62)	P Value
Age, y	9.0 (7-12)	8 (6.75-11)	0.84
Height, m	1.28 (1.19-1.41)	1.35 (1.22-1.48)	0.96
Heart Rate, beats/min	72 (69-76)	73 (70-75)	0.46
Conventional echocardiography			
LVEDd, mm	38.7 (35.6-43.3)	39.1 (36.6-42.4)	0.58
LVSD, mm	25.0 (13.6-57.2)	24 (12.7-37.2)	0.10
IVSd, mm	7 (0.64-0.78)	7.3 (0.66-0.80)	0.22
LVPWd, mm	5.3 (0.48-0.62)	6.2 (5.2-6.6)	0.03*
SF, %	33 (29.9-37.57)	37 (35.21-39.77)	< 0.001**
EF, %	59 (58.75-68)	69 (66.00-71.00)	< 0.001**
LV mass, g	70.8 (58.8-89.41)	64.3 (50.74-88.67)	0.013*
LV mass index, g/m ²	69.0 (58.7-84.20)	65.8 (59.8-71.6)	0.034*
RWT (2*LVWd/ LVEDd)	0.27 (0.17-0.55)	0.29 (0.21-0.41)	0.57
Mitral E, m/s	0.71 (0.64-0.88)	0.79 (0.68-0.89)	0.56
Mitral A, m/s	0.46 (0.42-0.52)	0.50 (0.43-0.56)	0.95
E/A ratio	1.53 (1.45-1.70)	1.60 (1.40-1.77)	0.66
Teicholz method			
LVVD, cm	69.7 (56.54-80.47)	66.1 (52.8-121.0)	0.58
LVVS, cm	22.3 (4.6-161.3)	20.5 (3.9-41.9)	0.10
SF, %	33.6 (9.0-46.7)	37.7 (30.9-45.2)	< 0.001**
Doppler			
Mitral valve PHT, ms	48.6 (39.46-53.82)	56.7 (51.43-62.19)	< 0.001*
Mitral valve area, cm ²	4.5 (4.09-5.58)	3.88 (3.54-4.28)	< 0.001**
Mitral E', cm/s	9 (7-11)	12 (10-14)	< 0.001**
Mitral A', cm/s	15 (14-17)	17 (16-19)	< 0.001**
E/E' ratio	4.83 (4.12-5.56)	4.32 (3.88-5.03)	0.74

Abbreviations: EF, ejection fraction; LVEDd, left ventricle end diastolic diameter; LVPWd, left ventricle posterior wall diameter; LVSD, left ventricle end systolic diameter; LVV, left ventricle end systolic volume; LVVD, left ventricle end diastolic volume; mitral A, peak late diastolic flow, Mitral E' Peak early diastolic velocity measured on tissue Doppler; Mitral A'; peak late diastolic velocity measured on tissue Doppler, RWT, relative wall thickness allows further classification of LV mass increase as either concentric hypertrophy (RWT > 0.42) or eccentric hypertrophy (RWT ≤ 0.42) The data is median and ranges; mitral E, peak early diastolic flow measured with Doppler; SF, shortening fraction.

myocardial function. We evaluated the diastolic velocities of mitral lateral annulus. Among the myocardial tissue velocities, patients in group Ia had lower values of indices measured with tissue Doppler, Mitral E' (P < 0.001), Mitral A' (P < 0.05) than those in group Ib. The ratio of E/E' showed an increase in group Ia compared with group Ib patients.

4. Discussion

We found that DMD patients had lower EF than control patients. Also older DMD patients had impairment in

systolic functions and these patients had strictly increased MVA values compared with remaining DMD patients.

Cardiac involvement develops in about 90% of DMD patients during the course of the disease (6). Although prior reports suggested that cardiomyopathy (CMP) develops with increasing age, the age at which the DMD-associated cardiomyopathy becomes clinically evident is variable (7). With the advent of cardiac fibrosis systolic dysfunction can cause disability and death between 2nd and 3rd decade of life. However some young patients may develop evident CMP before the development of exact cardiac fibrosis. We also observed systolic dysfunction in three DMD patients

Table 2. Comparison of the Variables in the Subgroups of the Patients^{a,b}

Variables	Group Ia EF < 60 ± 5% (n = 32)	Group Ib EF > 60 ± 5% (n = 30)	P Value
Age, y	9.9 ± 0.16 (4 - 17)	7.9 ± 2.9 (3 - 14)	0.026*
Length, m	1.3 ± 0.16 (1.1 - 1.6)	1.2 ± 0.13 (1 - 1.5)	0.05*
Weight, kg	29 ± 13.9 (11 - 78)	23 ± 8.1 (12 - 53)	0.07
Heart rate, beats/min	72 ± 4.3 (60 - 81)	72 ± 4.3 (60 - 81)	0.713
Conventional Echocardiography			
Ejection fraction, %	54 ± 9.3 (20 - 59)	69 ± 4.9 (64 - 83)	0.03*
Fractional shortening, % (m mode)	29 ± 6.4 (9.4 - 32)	37 ± 3.4 (33 - 46)	0.002**
LVEDd, mm	41.9 ± 8 (29 - 63)	37.6 ± 4 (24 - 45)	0.037
LVSD, mm	29.7 ± 8.6 (20 - 57)	23.4 ± 3.4 (13 - 29)	0.01*
IVSD, mm	7.8 ± 0.13 (5.5 - 11)	6.9 ± 0.9 (5 - 8.8)	0.03*
LVPWd, mm	7.6 ± 1.4 (3.5 - 8.9)	5.4 ± 0.9 (3.7 - 7.5)	0.04*
LV mass, g	83 ± 44.2 (33 - 205)	62 ± 19.2 (24 - 104)	0.01*
LV mass index, g/m ²	75 ± 40.2 (43 - 229)	67 ± 19.1 (31 - 122)	0.05
RWT (2*LVSPWd/LVEDd)	0.27 ± 0.08 (17 - 55)	0.29 ± 0.05 (22 - 42)	0.07
Mitral valve Doppler E wave, cm/s	8 ± 0.2 (5 - 13)	7.2 ± 0.13 (5 - 11)	0.06
Mitral valve Doppler A, cm/s	4.9 ± 1.0 (3.2 - 7.2)	4.5 ± 0.7 (3.2 - 6.2)	0.15
Mitral valve Doppler E/A	1.6 ± 0.2 (1.3 - 2.3)	1.5 ± 0.16 (1.3 - 2.0)	0.783
Teicholz method			
LVVD (Teicholz method)	83 ± 42 (33 - 206)	62 ± 16.7 (22 - 95)	0.15
LVVS (Teicholz method)	39 ± 33 (13 - 161)	19.7 ± 6.5 (4.6 - 32.7)	0.001**
Fractional shortening, %	29 ± 6.6 (9 - 42)	37.5 ± 3.7 (30.7 - 46.7)	0.002**
Doppler			
Mitral valve PHT, ms	45.6 ± 10.7 (24 - 72)	49.2 ± 12 (31 - 78)	0.418
Mitral valve area, cm ²	4.6 ± 1.4 (3.0 - 8.9)	4.7 ± 1.1 (2.8 - 6.9)	0.08
Mitral E', cm/s	15 ± 1.3 (13 - 19)	16 ± 3.0 (12 - 24)	0.001**
Mitral A', cm/s	13 ± 1.5 (11 - 18)	9.8 ± 1.9 (6 - 14)	0.002**
TDI mitral valve E/ E'	5.10 (4.35 - 6.29)	4.45 (3.54 - 4.22)	0.006**

Abbreviations: EF, ejection fraction; LVEDd, left ventricle end diastolic diameter; LVPWd, left ventricle posterior wall diameter; LVSD, left ventricle end systolic diameter; LVV, left ventricle end systolic volume; LVVD, left ventricle end diastolic volume; Mitral A, Peak late diastolic flow; Mitral A', peak late diastolic velocity measured on tissue Doppler; Mitral E, peak early diastolic flow measured with Doppler; Mitral E' Peak early diastolic velocity measured on tissue Doppler; RWT, Relative wall thickness allows further classification of LV mass increase as either concentric hypertrophy (RWT > 0.42) or eccentric hypertrophy (RWT ≤ 0.42); SF, shortening fraction.

^aThe patients were grouped according to 1 standard deviation above or below the mean range 60 ± 5% for Ejection fraction.

^bLang RM et al. American society of echocardiography's N, standards C, task force on chamber Q, American college of cardiology echocardiography C, American heart A, European association of echocardiography ESoC. Recommendations for chamber quantification. Eur J Echocardiogr 2006; 7:79 - 108.

under 10 years. However 18 patients over the age of 10 years had no signs of systolic dysfunction in our study. MRI studies also showed that fibrotic replacement started under 10 years old but it takes a time to cause evident systolic dysfunction. Thus, a different mechanism from fibrotic replacement may cause cardiac dysfunction in young DMD patients. As suggested before, some genotypes may associate with early onset of cardiomyopathy and others may protect the early cardiac dysfunction (24, 25).

However, the recent report by Ashwath et al. (26) sug-

gested no correlation between genotyping and cardioprotective effect. Recent genetic testing did not provide predictive information about cardiac involvement, this primarily was used to diagnose the dystrophinopathy (6). Cardiac involvement was usually determined by echocardiography. The electrocardiogram and Holter monitoring were used to determine the early signs of cardiomyopathy and cardiac autonomic dysfunction (27). In our previously published study autonomic dysfunction was detected to be developed in the earlier period of DMD before the develop-

ment of mechanical cardiac dysfunction (28).

In addition, early detection of DMD-associated cardiomyopathy leads to early initiation of treatment which may slow cardiac remodeling and delay heart failure symptoms.

In the current study continuous wave Doppler signal of transmitral flow derived from mitral valve area was significantly increased in DMD patients compared with controls. In DMD subgroups, patients with systolic impairment had significantly highest MVA than remaining patients. Also this group had increased LVEDd ($P < 0.05$), LVSD ($P < 0.05$), IVSd ($P < 0.05$) and LVPWd. This observation can support that left ventricular dilatation similar to other causes of dilated cardiomyopathy leads to dilatation of mitral valvular annulus in DMD.

DMD-associated heart diseases are usually expressed as dilated cardiomyopathies. However some authors have reported that other types of CMP such as hypertrophic pattern or non-compaction type have been determined in patients with DMD. The best established indicator of fibrotic process in myocardium is LGE. MRI studies showed that LGE-positivity occurs early but become more prevalent with increasing age and decreasing LV ejection fraction (7).

DMD-associated CMP is characterized by fibrotic replacement of dead cells and compensatory hypertrophy of remaining cardiomyocytes. We used M-mode echocardiography to determine left ventricular chamber and wall dimensions. We also observed LV mass index was significantly higher in DMD patients. In addition, DMD patients with systolic impairment had higher LV mass values than remaining DMD patients. Increase in left ventricular mass may be related to maladaptive remodelling induced by dystrophinopathy. Loss of cardiomyocytes leads to increased ventricular dimension that causes a rise in wall stress. Consequently LV wall hypertrophy develops to compensate increases in wall stress (29). However maladaptive remodeling occurs when increase in LV volume is disproportionate to LV wall thickness, resulting in a dilated cardiomyopathy phenotype. LV hypertrophy is an adaptive process response to variable clinical situations. Our findings supported that DMD associated CMP demonstrates a unique remodeling pattern distinct from DCM. Plausible explanation for distinct mechanism for DMD associated CMP is the fibrotic process that is not distributed uniformly in the myocardium (30). Recent reports suggest that diastolic abnormalities exist early in the setting of normal chamber size and LV systolic function (19). In the current study conventional Doppler signals measured by the mitral inflow differed significantly between study and the control groups. Doppler tissue imaging showed that diastolic functions began to deteriorate in the early phase

of cardiac involvement. The hypothesis by Markham et al. (31) regarding diastolic dysfunction in the early stages of DMD is that dysfunction of the active component of diastole results in alterations in calcium homeostasis leading to impaired ventricular relaxation. Nevertheless, progression of the myocardial fibrosis contributes to impairment in the passive component of diastole leading to deteriorate ventricular compliance and the development of systolic dysfunction. In this study we also found E/E' reflecting the ventricular compliance was higher in DMD patients with lower EF. In substance cardiac involvement is at cellular level yet, when diastolic functions begin to deteriorate. Thus, TDI measurements of the mitral annulus may serve to identify early cardiac decompensation.

The prognostic value of this study seems to be superior to that provided by new echocardiography methods like global longitudinal strain in follow up and will require further longitudinal follow-up data with larger DMD patient series.

References

- Eidem BW. Identifying abnormalities of left ventricular systolic function in asymptomatic "carriers" of dystrophin mutations: getting better...But not there yet. *J Am Soc Echocardiogr.* 2010;**23**(8):854-6. doi: [10.1016/j.echo.2010.06.025](https://doi.org/10.1016/j.echo.2010.06.025). [PubMed: [206596664](https://pubmed.ncbi.nlm.nih.gov/206596664/)].
- Gumerson JD, Michele DE. The dystrophin-glycoprotein complex in the prevention of muscle damage. *J Biomed Biotechnol.* 2011;**2011**:210797. doi: [10.1155/2011/210797](https://doi.org/10.1155/2011/210797). [PubMed: [22007139](https://pubmed.ncbi.nlm.nih.gov/22007139/)]. [PubMed Central: [PMC3189583](https://pubmed.ncbi.nlm.nih.gov/PMC3189583/)].
- Ameen V, Robson LG. Experimental models of duchenne muscular dystrophy: relationship with cardiovascular disease. *Open Cardiovasc Med J.* 2010;**4**:265-77. doi: [10.2174/1874192401004010265](https://doi.org/10.2174/1874192401004010265). [PubMed: [21258567](https://pubmed.ncbi.nlm.nih.gov/21258567/)]. [PubMed Central: [PMC3024556](https://pubmed.ncbi.nlm.nih.gov/PMC3024556/)].
- Zhou L, Lu H. Targeting fibrosis in Duchenne muscular dystrophy. *J Neuropathol Exp Neurol.* 2010;**69**(8):771-6. doi: [10.1097/NEN.0b013e3181e9a34b](https://doi.org/10.1097/NEN.0b013e3181e9a34b). [PubMed: [20613637](https://pubmed.ncbi.nlm.nih.gov/20613637/)]. [PubMed Central: [PMC2916968](https://pubmed.ncbi.nlm.nih.gov/PMC2916968/)].
- Shevchenko KG. Selected issues of the Duchenne Muscular Dystrophy gene and cell therapy. *Cell Ther Transplant.* 2012;**3**(1).
- Verhaert D, Richards K, Rafael-Fortney JA, Raman SV. Cardiac involvement in patients with muscular dystrophies: magnetic resonance imaging phenotype and genotypic considerations. *Circ Cardiovasc Imaging.* 2011;**4**(1):67-76. doi: [10.1161/CIRCIMAGING.110.960740](https://doi.org/10.1161/CIRCIMAGING.110.960740). [PubMed: [21245364](https://pubmed.ncbi.nlm.nih.gov/21245364/)]. [PubMed Central: [PMC3057042](https://pubmed.ncbi.nlm.nih.gov/PMC3057042/)].
- Gulati S, Saxena A, Kumar V, Kalra V. Duchenne muscular dystrophy: prevalence and patterns of cardiac involvement. *Indian J Pediatr.* 2005;**72**(5):389-93. [PubMed: [15973020](https://pubmed.ncbi.nlm.nih.gov/15973020/)].
- Yilmazer MM, Omeroglu RE, Bornaun H, Oner N, Nisli K, Ertugrul T. Repolarization abnormalities in Duchenne-type muscular dystrophy. *Turk Kardiyol Dern Ars.* 2009;**37**(8):538-42. [PubMed: [20200454](https://pubmed.ncbi.nlm.nih.gov/20200454/)].
- Percival JM, Adamo CM, Beavo JA, Froehner SC. Evaluation of the therapeutic utility of phosphodiesterase 5A inhibition in the mdx mouse model of duchenne muscular dystrophy. *Handb Exp Pharmacol.* 2011;(204):323-44. doi: [10.1007/978-3-642-17969-3_14](https://doi.org/10.1007/978-3-642-17969-3_14). [PubMed: [21695647](https://pubmed.ncbi.nlm.nih.gov/21695647/)]. [PubMed Central: [PMC4063120](https://pubmed.ncbi.nlm.nih.gov/PMC4063120/)].
- Burke W. Genomics as a probe for disease biology. *N Engl J Med.* 2003;**349**(10):969-74. doi: [10.1056/NEJMra012479](https://doi.org/10.1056/NEJMra012479). [PubMed: [12954746](https://pubmed.ncbi.nlm.nih.gov/12954746/)].

11. Jefferies JL, Eidem BW, Belmont JW, Craigen WJ, Ware SM, Fernbach SD, et al. Genetic predictors and remodeling of dilated cardiomyopathy in muscular dystrophy. *Circulation*. 2005;**112**(18):2799–804. doi: [10.1161/CIRCULATIONAHA.104.528281](https://doi.org/10.1161/CIRCULATIONAHA.104.528281). [PubMed: [16246949](https://pubmed.ncbi.nlm.nih.gov/16246949/)].
12. Chetboul V, Escriou C, Tessier D, Richard V, Pouchelon JL, Thibault H, et al. Tissue Doppler imaging detects early asymptomatic myocardial abnormalities in a dog model of Duchenne's cardiomyopathy. *Eur Heart J*. 2004;**25**(21):1934–9. doi: [10.1016/j.ehj.2004.09.007](https://doi.org/10.1016/j.ehj.2004.09.007). [PubMed: [15522473](https://pubmed.ncbi.nlm.nih.gov/15522473/)].
13. Chetboul V, Carlos C, Blot S, Thibaud JL, Escriou C, Tissier R, et al. Tissue Doppler assessment of diastolic and systolic alterations of radial and longitudinal left ventricular motions in Golden Retrievers during the preclinical phase of cardiomyopathy associated with muscular dystrophy. *Am J Vet Res*. 2004;**65**(10):1335–41. [PubMed: [15524319](https://pubmed.ncbi.nlm.nih.gov/15524319/)].
14. Pradhan S. Valley sign in duchenne muscular dystrophy: importance in patients with inconspicuous calves. *Neurol India*. 2002;**50**(2):184–6. [PubMed: [12134184](https://pubmed.ncbi.nlm.nih.gov/12134184/)].
15. Lang RM, Bierig M, Devereux RB, Flachskampf FA, Foster E, Pellikka PA, et al. Recommendations for chamber quantification. *Eur J Echocardiogr*. 2006;**7**(2):79–108. doi: [10.1016/j.euje.2005.12.014](https://doi.org/10.1016/j.euje.2005.12.014). [PubMed: [16458610](https://pubmed.ncbi.nlm.nih.gov/16458610/)].
16. Gottdiener JS, Bednarz J, Devereux RB, Gardin J, Klein AL, Manning WJ, et al. American Society of Echocardiography recommendations for use of echocardiography in clinical trials: A report from the american society of echocardiography's guidelines and standards committee and the task force on echocardiography in clinical trials. *J Am Soc Echocardiograph*. 2004;**17**(10):1086–119.
17. Teichholz LE, Kreulen T, Herman MV, Gorlin R. Problems in echocardiographic volume determinations: echocardiographic-angiographic correlations in the presence of absence of asynergy. *Am J Cardiol*. 1976;**37**(1):7–11. [PubMed: [1244736](https://pubmed.ncbi.nlm.nih.gov/1244736/)].
18. Lang RM, Bierig M, Devereux RB, Flachskampf FA, Foster E, Pellikka PA, et al. Recommendations for chamber quantification: a report from the American Society of Echocardiography's Guidelines and Standards Committee and the Chamber Quantification Writing Group, developed in conjunction with the European Association of Echocardiography, a branch of the European Society of Cardiology. *J Am Soc Echocardiogr*. 2005;**18**(12):1440–63. doi: [10.1016/j.echo.2005.10.005](https://doi.org/10.1016/j.echo.2005.10.005). [PubMed: [16376782](https://pubmed.ncbi.nlm.nih.gov/16376782/)].
19. Verma A, Meris A, Skali H, Ghali JK, Arnold JM, Bourgoun M, et al. Prognostic implications of left ventricular mass and geometry following myocardial infarction: the VALIANT (VALsartan In Acute myocardial iNfarcTion) Echocardiographic Study. *JACC Cardiovasc Imaging*. 2008;**1**(5):582–91. doi: [10.1016/j.jcmg.2008.05.012](https://doi.org/10.1016/j.jcmg.2008.05.012). [PubMed: [19356485](https://pubmed.ncbi.nlm.nih.gov/19356485/)].
20. Maurer MS, Spevack D, Burkhoff D, Kronzon I. Diastolic dysfunction: can it be diagnosed by Doppler echocardiography? *J Am Coll Cardiol*. 2004;**44**(8):1543–9. doi: [10.1016/j.jacc.2004.07.034](https://doi.org/10.1016/j.jacc.2004.07.034). [PubMed: [15489083](https://pubmed.ncbi.nlm.nih.gov/15489083/)].
21. Nagueh SF, Smiseth OA, Appleton CP, Byrd B3, Dokainish H, Edvardsen T, et al. Recommendations for the Evaluation of Left Ventricular Diastolic Function by Echocardiography: An Update from the American Society of Echocardiography and the European Association of Cardiovascular Imaging. *J Am Soc Echocardiogr*. 2016;**29**(4):277–314. doi: [10.1016/j.echo.2016.01.011](https://doi.org/10.1016/j.echo.2016.01.011). [PubMed: [27037982](https://pubmed.ncbi.nlm.nih.gov/27037982/)].
22. Sohn DW, Chai IH, Lee DJ, Kim HC, Kim HS, Oh BH, et al. Assessment of mitral annulus velocity by Doppler tissue imaging in the evaluation of left ventricular diastolic function. *J Am Coll Cardiol*. 1997;**30**(2):474–80. [PubMed: [9247521](https://pubmed.ncbi.nlm.nih.gov/9247521/)].
23. Osterne EC, Haddad J, da Motta VP, da Motta PA, Osterne TE, Osterne NM, et al. Determination of mitral valve area through pressure half-time measurements in the left atrium and pulmonary capillary wedge. *Arq Bras Cardiol*. 2006;**87**(6):705–10. [PubMed: [17262107](https://pubmed.ncbi.nlm.nih.gov/17262107/)].
24. Rafael JA, Cox GA, Corrado K, Jung D, Campbell KP, Chamberlain JS. Forced expression of dystrophin deletion constructs reveals structure-function correlations. *J Cell Biol*. 1996;**134**(1):93–102. [PubMed: [8698825](https://pubmed.ncbi.nlm.nih.gov/8698825/)]. [PubMed Central: [PMC2120912](https://pubmed.ncbi.nlm.nih.gov/PMC2120912/)].
25. Rafael JA, Rafael JA, Mills PL, Cole NM, Faulkner JA, Wang K, et al. Transgenic mdx mice expressing dystrophin with a deletion in the actin-binding domain display a "mild Becker" phenotype. *J Cell Biol*. 1996;**134**(4):873–84. [PubMed: [8769413](https://pubmed.ncbi.nlm.nih.gov/8769413/)]. [PubMed Central: [PMC2120962](https://pubmed.ncbi.nlm.nih.gov/PMC2120962/)].
26. Ashwath ML, Jacobs IB, Crowe CA, Ashwath RC, Super DM, Bahler RC. Left ventricular dysfunction in duchenne muscular dystrophy and genotype. *Am J Cardiol*. 2014;**114**(2):284–9. doi: [10.1016/j.amjcard.2014.04.038](https://doi.org/10.1016/j.amjcard.2014.04.038). [PubMed: [24878125](https://pubmed.ncbi.nlm.nih.gov/24878125/)]. [PubMed Central: [PMC4768789](https://pubmed.ncbi.nlm.nih.gov/PMC4768789/)].
27. Angelini C, Di Leo R, Cudia P. Autonomic regulation in muscular dystrophy. *Front Physiol*. 2013;**4**:257. doi: [10.3389/fphys.2013.00257](https://doi.org/10.3389/fphys.2013.00257). [PubMed: [24065927](https://pubmed.ncbi.nlm.nih.gov/24065927/)]. [PubMed Central: [PMC3778236](https://pubmed.ncbi.nlm.nih.gov/PMC3778236/)].
28. Yilmazer MM, Omeroglu RE, Bornaun H, Oner N, Nisli K. Duchenne Muskuler Distrofi'de Kardiyak Otonomik Disfonksiyonun Degerlendirilmesi. *J Neurol Sci*. 2010;**27**(1):12–9. Turkish.
29. Burchfield JS, Xie M, Hill JA. Pathological ventricular remodeling: mechanisms: part 1 of 2. *Circulation*. 2013;**128**(4):388–400. doi: [10.1161/CIRCULATIONAHA.113.001878](https://doi.org/10.1161/CIRCULATIONAHA.113.001878). [PubMed: [23877061](https://pubmed.ncbi.nlm.nih.gov/23877061/)]. [PubMed Central: [PMC3801217](https://pubmed.ncbi.nlm.nih.gov/PMC3801217/)].
30. Mazur W, Hor KN, Germann JT, Fleck RJ, Al-Khalidi HR, Wansapura JP, et al. Patterns of left ventricular remodeling in patients with Duchenne Muscular Dystrophy: a cardiac MRI study of ventricular geometry, global function, and strain. *Int J Cardiovasc Imaging*. 2012;**28**(1):99–107. doi: [10.1007/s10554-010-9781-2](https://doi.org/10.1007/s10554-010-9781-2). [PubMed: [21222036](https://pubmed.ncbi.nlm.nih.gov/21222036/)].
31. Markham LW, Michelfelder EC, Border WL, Khoury PR, Spicer RL, Wong BL, et al. Abnormalities of diastolic function precede dilated cardiomyopathy associated with Duchenne muscular dystrophy. *J Am Soc Echocardiogr*. 2006;**19**(7):865–71. doi: [10.1016/j.echo.2006.02.003](https://doi.org/10.1016/j.echo.2006.02.003). [PubMed: [16824995](https://pubmed.ncbi.nlm.nih.gov/16824995/)].