

## §Case Report

## Unusual presentation of gestational trophoblastic neoplasm: Report of two cases

F. Amouzegar Hashemi<sup>1\*</sup>, F. Ghaemmaghami<sup>2</sup>, N. Behtash<sup>2</sup>

<sup>1</sup> Radiation Oncology Department, Cancer Institute, Imam Khomeini Hospital, Tehran, Iran

<sup>2</sup> Gynecology Oncology Department, Tehran University of Medical Sciences, Tehran, Iran

Gestational Trophoblastic Neoplasm (GTN) is among rare human tumors which can be observed with widespread metastasis. Two young patients with emergent neurologic symptoms with no gynecological problems are presented in this report. GTN was later diagnosed in both cases with brain metastasis. The first case: A 22 years old patient, admitted to the infectious disease ward, with probable diagnosis of Encephalitis. After brain CT scan and measurement of  $\beta$  human chorionic gonadotropin ( $\beta$ hCG), GTN with brain metastasis was confirmed. The second case: A 33 years old patient who underwent craniotomy due to hemorrhagic brain tumor in neurosurgery department. Brain metastatic GTN was confirmed by histological examinations. Both cases received multiagent chemotherapy concurrent with whole brain irradiation of 3000 cGy in 10 fractions (F) within a period of 2 weeks, and chemotherapy was continued for additional course. The patients were both well after about 22 months. Diagnosis of GTN should be considered in any woman of reproductive age. **Iran. J. Radiat. Res., 2006; 3 (4): 199-202**

**Keywords:** Brain metastatic GTN, choriocarcinoma, multiagent chemotherapy, WBRT.

### INTRODUCTION

Gestational Trophoblastic Neoplasm originates from placental tissue and it is one of the rare human tumors that can be observed with wide spread metastasis<sup>(1)</sup>.

It is known that about 80% of Gestational Trophoblastic Neoplasms have remote metastatic lesions, and brain is the second metastatic site which occurs in only 10% of GTN patients<sup>(2)</sup>.

Virtually, all patients with brain metastasis have concurrent pulmonary, and or vaginal involvement. Vaginal bleeding usually precedes neurological symptoms. Prognosis in patients with brain metastasis is worse than vaginal or pulmonary

metastasis and almost exclusively are seen in patients who have had a non molar pregnancy with a long delay in the diagnosis<sup>(1)</sup>

Prodromal symptoms of brain metastases are defined as those neurologic symptoms which are mild and transient in nature, and may be present for several weeks before the onset of the classical symptoms. The classical symptoms of brain metastases are defined as those neurologic symptoms having a fulminate onset and are associated with progressive deterioration of the patient's neurologic status<sup>(4)</sup>.

The initial presence of brain metastasis can be confirmed by

CT scan, magnetic resonance imaging (MRI), or serum / CSF  $\beta$  human chorionic gonadotropin ( $\beta$ hCG) ratio. Imaging studies may not be able to show micrometastasis in very early stage of brain metastases<sup>(4)</sup>. Cases have been reported with brain metastasis without evidence on imaging studies. Measurement of plasma / CSF ( $\beta$ hCG) ratio should be considered in deferential diagnosis<sup>(2)</sup>.

GTN should be considered in any woman of reproductive age who presents with neurologic symptoms. Observation of these two patients was supported the concept that some patients with central nervous system involvement have minimal gynecologic symptoms.

### Case 1

A 22 years old female was admitted to the infectious diseases department with

#### \*Corresponding author:

Dr. Farnaz Amouzegar Hashemi, Radiation Oncology Department, Cancer Institute, Imam Khomeini Hospital, Tehran 14194, Iran.

Fax: +98 21 66428655

E-mail: [amoozfar@sina.tums.ac.ir](mailto:amoozfar@sina.tums.ac.ir)

presumptive diagnosis of encephalitis and symptoms of convulsion, unconsciousness and left-sided paralysis in November 2002. A week prior to admission she had been complaining of severe headache, nausea, vomiting and convulsion. On admission the chest X-ray and other usual imaging studies were normal. She had a history of stillbirth about a year prior to admission and amenorrhea for 3 months. The pregnancy test was positive but the sonography did not show gestational sac. During admission she developed vaginal bleeding and the  $\beta$ hCG level was 1300 mIU/ml. A probable encephalitis induced abortion was considered. Two days later  $\beta$ hCG was reported as 17560 mIU/ml. She developed neurological symptoms such as urinary incontinence and limitation in movement. Abdominal and brain CT-Scan was performed which showed multiple metastatic lesions in brain figure 1. She was transferred to gynecologic oncology department for further management. With diagnosis of metastatic GTN, she was started on chemotherapy. After the first course, multi-agent chemotherapy, she was treated

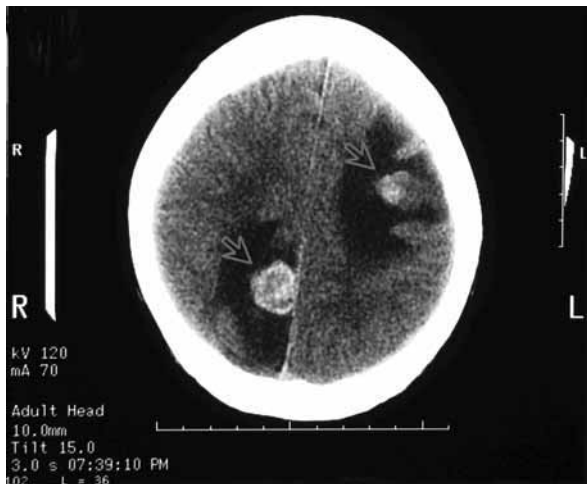

Figure 1. Brain metastasis (Case 1).

with a high dose of combination chemotherapy according to the following protocol:

Day 1: Etoposide 100 mg/m<sup>2</sup> IV (500 cc N/S in 30 min)  
 Actinomycin-D (Act-D) 0.5 mg IV stat  
 Methotrexate (MTX) 100mg/m<sup>2</sup> IV stat  
 Methotrexate (MTX) 1000 mg/m<sup>2</sup>

(1000 cc N/S in 12 h)  
 Day 2: Etoposide 100 mg/m<sup>2</sup> IV (500 cc N/S in 30 min)  
 Actinomycin-D (Act-D) 0.5 mg IV stat  
 Folic acid 30 mg IM or PO Q12h for 6 doses, start 32h after MTX commend  
 Day 8: Etoposide 100 mg/m<sup>2</sup> IV (500 cc N/S in 30 min)  
 Cisplatinum 60-80 mg/m<sup>2</sup> IV (100cc 1 mg/min)  
 Every 7 days 1, 2, 8 ... 15, 16, 22

During the first course of chemotherapy, the patient was referred to the Radiation Oncology Department. Concurrent whole brain radiotherapy (WBRT), was given (3000 cGy in 10 fractions during 2weeks). After she completed the four cycles of chemotherapy,  $\beta$ hCG turned to negative, but the treatment was continued for 4 additional courses. The patient is now alive without evidence of disease, 2 years after completion of her treatment.

### Case 2

A 33 years old female, was referred to Radiation Oncology department from Neurosurgery department in April 2003, with brain metastasis diagnosed from GTN. She was primarily admitted because of left sided hemiplegia following headache. Brain MRI was reported a nonhomogen density in right parietal lobe with significant mass effect and surrounding edema which hemorrhagic tumor was the first diagnosis (figure 2). She underwent parasagittal craniotomy and resec-

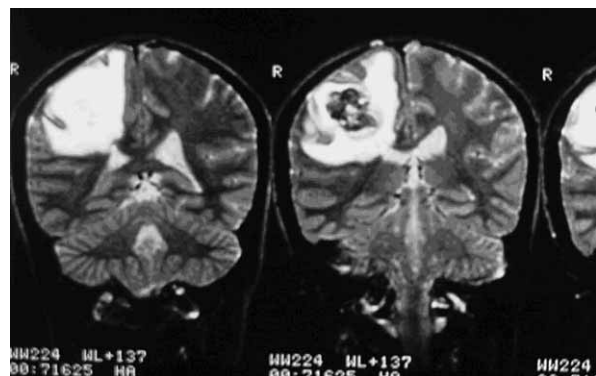


Figure 2. Hemorrhagic brain tumor (Case 2).

tion of tumor. The tumor had 4 cm diameter, and microscopically was metastatic choriocarcinoma. Ten days after surgery and before admission in Gynecology Oncology Department, the  $\beta$ hCG titre was reported to be about 500 mIU/ml, but it increased and reached to 442000 mIU/ml. The patient had a history of molar pregnancy 8 months earlier and had undergone suction curettage. Due financial problems she hadn't done the follow up. After a few months, she experienced left hemiplegia and hemiparesis following a very severe headache. Her work up revealed multiple lung metastases and also right kidney involvement on CT-scan. The patient underwent treatment with EMA-EP concurrent with whole brain irradiation (3000 cGy in 10 fractions in 2 weeks) chemotherapy dose modification was necessary due to liver enzymes elevation and bone marrow suppression. GCSF was added after the third course of chemotherapy. After 4 courses of chemotherapy,  $\beta$ hCG turned to negative, but the treatment was continued for 3 additional courses. Now it is about 19 months after the last course of chemotherapy and the patient is doing well without any recurrence evidence.

## DISCUSSION

Intracranial hemorrhage due to brain metastases from GTN has been described to be caused by the nature of trophoblastic cells, which tend to invade into the vessels and it can be subdural, subarachnoid, or intracerebral. Pathological examination of surgically resected or autopsy material in cases with intracranial hemorrhage has demonstrated tumor emboli occluding cerebral vessels and, less commonly, aneurysm formation. It is proposed that invasion of the vessel wall follows embolization of tumor with consequent weakening and destruction of the vessel wall leading to hemorrhage. Aneurysm may subsequently be formed due to focal damage to the vessel wall and this may eventually rupture. There is a good correlation with a

sudden onset and rapid progression of neurological signs and also with the characteristic CT-scan findings (2). These metastases tend to be very vascular and to have a tendency for central necrosis and hemorrhage (3). The diagnosis of metastatic GTN should be considered in any woman of reproductive age with neurologic symptoms and should trigger the prompt testing of the hCG. It is probable that these patients have no gynecology related symptoms (1).

Gestational Trophoblastic Neoplasm (GTN) is a rare malignancy, which is extremely responsive to chemotherapy even with metastatic tumors (5). We usually use EMA-EP regimen as first line multi-agent chemotherapy with high risk GTN in place of EMA-Co due to our and other positive studies (6,7,8).

GTN has long been known to be a radiosensitive tumor (4). Brain irradiation not only has tumoricidal effect but also can act as a haemostatic agent (9). Therefore it is recommenced whole brain irradiation concurrent with chemotherapy to reduce the risk of spontaneous cerebral hemorrhage (9).

Schechter *et al.* (4) in a study based on autopsy findings reported that the CNS involvement is multi-focal and craniotomy is not an adequate treatment. Due to microscopic vascular invasion, hemorrhage in the brain may occur at the sites remote from the primary tumor. Therefore even though the majority of the patients present with clinical evidence of solitary mass, WBRT would likely be more effective than craniotomy for definitive treatment (4). Rustin *et al.* (10) in 25 patients with CNS involvement utilized intensive treatment with EMA-CO chemotherapy without WBRT and reported 72% of 5 years survival. They believe that WBRT was not needed to be used for all patients, but a second look into the acquired data proves that 44% of the patients have undergone craniotomy to control hemorrhage and edema. Weed *et al.* (11) in another study have shown the remission rate of 50% (7/14), in patients who were under treatment by multi-agent chemotherapy and WBRT.

Moreover, study of 78 patients with central

nervous system metastasis from trophoblastic disease showed 18 patients received chemotherapy and whole brain radiation, 25 patients were treated with chemotherapy alone and 35 patients received neither chemotherapy nor radiotherapy<sup>(12)</sup>. In the latter group there were no survivors and 74% of deaths resulted from central nervous system lesions. Among the patients who received only chemotherapy, survival rate was 24% and 58% of the patients died of CNS problems.

The group of patients who received both chemotherapy and radiation, survival rate was about 50% and none of deaths were of CNS origin. This study also suggests that radiation has a distinct therapeutic role in the treatment of CNS involvement in GTN.

In another study of 42 patients with CNS metastases of GTN, treatment with multi-agent chemotherapy and radiation, showed a survival rate of 44% which is comparable with the rate reported for intratecal methotrexate regimen<sup>(13)</sup>.

We have previously reported that, 5 out of 9 patients responded to multi-agent chemotherapy (high dose EMA-EP) and concurrent WBRT<sup>(14)</sup>. We didn't observe any complications due to combination of chemotherapy and WBRT. Similar to Schechter et al.<sup>(4)</sup> none of our patients had developed radiation induced dementia, impairment of higher cognitive functioning or other late neurologic sequelae directly attributable to the WBRT. However, when multi-agent chemotherapy and whole brain radiotherapy (WBRT) have been used concurrently, overall 50-80% of patients with brain metastases can be expected to be cured<sup>(4, 15, 16)</sup>.

In conclusion, diagnosis of GTN should be considered in any woman of reproductive age who has unexplained neurologic symptoms. In addition multi-agent chemotherapy concurrent with WBRT will result over 50% survival rate in GTN patients with brain metastases.

## REFERENCES

1. Berkowitz RS and Goldstein DP (1996) Chorionic tumors, *The new England Journal of Medicine*, **335**: 1740-1748.
2. Kang SB, Lee CM, Kim JW, Park NH, Lee HP (2000) Chemoresistant choriocarcinoma cured by pulmonary lobectomy and craniotomy. *Int J Gynecol Cancer*, **10**: 165-169.
3. Newlands ES (2003) The management of recurrent and drug resistant gestational trophoblastic neoplasia (GTN) *Best Prac & Res Clin Obstet & Gynecol*, **17**: 905-923.
4. Shchecter NR, Mychalczak B, Jones W, Sprigg SD (1998) Prognosis of patients treated with whole-brain radiation "Therapy for metastatic Gestational Trophoblastic Disease. *Gynecol Oncol*, **68**: 183-191.
5. Hoskins WJ, Peres CA, Young RC (2000) Principals and Practice of Gynecology Oncology, Third edition, Lippincott, Williams and Wilkins, Philadelphia, USA, pp: 1117-1132.
6. Surwit EA, Childers JA (1991) High-risk metastatic gestational trophoblastic disease. A new dose- intensive, multiagent chemotherapeutic regimen. *J Reprod Med*, **36**: 45-8.
7. Ghaemmaghami F, Modares M, Arab M, et al. (2004) EMA-EP regimen as first-line multiple agent chemo-therapy in high risk GTN. *Int J Gynecol Cancer*, **14**: 360-365.
8. Ghaemmaghami F, Behtash N, Soleimani K, Hanjani P (2004) Management of patients with metastatic gestational trophoblastic tumor. *Gynecol Oncol*, **94**: 187-190.
9. Berkowitz RS, Goldstein DP (2000) Gestational Trophoblastic Neoplasia. In: Practical Gynecologic Oncology, (Berek JS, Hacker NF, eds). Third edition. Lippincott, Williams and Wilkins, Philadelphia, USA, pp: 615-630.
10. Rustin GJS, Newlands EE, Begent RHJ, Dent J, Bagshawe KD (1989) Weekly alternating etoposide, methotrexate, and atinomycin/vincristine and cyclophosphamide chemotherapy for the treatment of CNS metastases of choriocarcinoma. *J Clin Oncol*, **7**: 900-903.
11. Weed JC and Hammond CB (1980) Cerebral metastatic choriocarcinoma: Intensive therapy and prognosis. *Obstet Gynecol*, **55**: 89-99.
12. Yordan EL, Schlaerth Jr, Gaddiso J, Morrow CP (1987) Radiation therapy in the management of gestational choriocarcinoma metastatic to the central nervous system. *Obstet Gynecol*, **69**: 622-30.
13. Evans JR, John AC, Soper T, Daniel L, et al. (1995) Gestational trophoblastic disease metastatic to the central nervous system. *Gynecol Oncol*, **59**: 226-230.
14. Ghaemmaghami F, Behtash N, Memarpour N, et al. (2004) Evaluation & Management of brain metastatic patients with high risk gestational trophoblastic tumors. *Int J Gynecol Cancer*, **14**: 966-971.
15. Small WJ, Lurain JR, Shetty RM, Huang CF, Applegate GL, Brand WN (1996) Gestational trophoblastic disease metastatic to the brain. *Radiology*, **200**: 277-280.
16. Altintas A and Varder MA (1999) Central nervous system involvement in gestational trophoblastic neoplasia. *Int J Gynecol Cancer*, **9**: 161-162.