

Radiation-induced acute kidney toxicity: Protective effect of *L-carnitine* versus amifostine

V. Yurut-Caloglu^{1*}, M. Caloglu¹, T. Deniz-Yalta², T. Aktoz³, D. Nurlu¹,
N. Kilic-Durankus¹, E. Arda³, G. Turkkan¹, O. İnci³

¹Trakya University, Faculty of Medicine, Departments of Radiation Oncology, Edirne, Turkey

²Trakya University, Faculty of Medicine, Departments of Pathology, Edirne, Turkey

³Trakya University, Faculty of Medicine, Departments of Urology, Edirne, Turkey

ABSTRACT

► Original article

* Corresponding author:

Dr. Murat Caloglu,

Fax: +90 2842361074

E-mail:

caloglumurat@hotmail.com

Revised: Nov. 2014

Accepted: Jan. 2015

Int. J. Radiat. Res., October 2015;
13(4): 317-324

DOI: 10.7508/ijrr.2015.04.004

Background: The aim of the study was to compare the radioprotective efficacy in the kidney of L-carnitine to that of amifostine. **Materials and Methods:** Thirty three-month-old Wistar albino rats were randomly assigned to four groups: Group 1 (Control); Group 2 (Irradiation alone); Group 3 (amifostine plus irradiation); and Group 4 (L-carnitine before irradiation). The rats in Groups 2, 3, and 4 were irradiated individually with a single dose of 20 Gy to whole abdomen. L-carnitine (300 mg/kg) or amifostine (200 mg/kg) was administered 30 minutes before irradiation. Euthanasia was performed 5 days after irradiation, and kidneys were evaluated histopathologically. **Results:** Dilatation of Bowman's capsule, congestion of blood vessels, and tubular epithelial degeneration were significantly different among the groups ($p < 0.05$). Pretreatment with both L-carnitine and amifostine reduced the radiation-induced dilatation of Bowman's capsule ($p < 0.05$), congestion of blood vessels ($p < 0.05$), and tubular epithelial degeneration ($p < 0.05$). L-carnitine and amifostine were similar in protective effect. **Conclusion:** L-carnitine was equally effective as amifostine in protecting the kidney against acute irradiation damage.

Keywords: Amifostine, histopathology, irradiation, kidney, L-carnitine, radioprotection.

INTRODUCTION

In abdominal malignancies, radiation therapy (RT) is known to be an important treatment modality. The kidney is a dose-limiting organ, restricting the application of irradiation in the abdominal area. Morphologic studies of radiation nephropathy have found evidence of injury to blood vessels, glomeruli, tubular epithelium, and interstitium. Whole kidney dose-response data suggest a total dose associated with 5% and 50% risk of injury at 5 years of 18–23 Gy and 28 Gy, in 0.5–1.25 Gy/fraction, respectively ⁽¹⁾. Radiation-induced kidney damage is not thoroughly eliminated by dose-fractionation approaches. In these patients,

prophylactic use of radioprotectants before irradiation may be an alternative strategy for reduction of renal damage.

The effect of ionizing radiation is primarily mediated by the action of free radicals, which can cause damage to DNA, proteins, and lipids. For that reason, antioxidative defense mechanisms are responsible for much of the radiation damage ⁽²⁾. Amifostine (S-2{3-aminopropylamino}-ethylphosphorothioic acid; Ethylol; WR-2721) is a prodrug that is converted *in vivo* by alkaline phosphatase to an active sulfhydryl compound (WR-1065). This substance selectively protects normal cells from antineoplastic drug toxicity by scavenging free radicals, by donating hydrogen ions to free

radicals, by depleting oxygen, and by binding to active derivatives of antineoplastic agents (3, 4). Our previous studies revealed substantial radioprotective effects of amifostine on lung and kidney (5-7). However, use of amifostine has been reported to cause undesirable side effects that include nausea, vomiting, sneezing, hot flashes, mild somnolence, hypocalcaemia, and hypotension (8, 9).

L-carnitine (3-hydroxy-4-trimethylammoniumbutyric acid) is a small water-soluble molecule that facilitates the transmission of long-chain fatty acids into the mitochondria of skeletal muscle and cardiomyocytes, where they undergo beta-oxidation (10). L-carnitine prevents the formation of reactive oxygen species produced by the xanthine/xanthine oxidase system and so decreases damage to the cell membrane. L-carnitine is obtained mostly from the diet or can be given exogenously. It can also be synthesized endogenously by skeletal muscle, heart, liver, kidney, and brain. L-carnitine is a relatively well-tolerated and safe compound (11, 12). The radioprotective effect of L-carnitine has been reported in earlier studies (7, 13-16).

To the best of our knowledge, no study to date has ever investigated the efficacy of L-carnitine in prevention of radiation-induced acute renal damage. The aim of the present study was therefore to evaluate the radioprotective effects of L-carnitine in an irradiated kidney and to compare these to the radioprotection afforded by amifostine.

MATERIALS AND METHODS

Animals and experimental design

All animal experiments are conducted strictly under the guidelines of the Institutional Animal Ethics Committee. The rats were housed in rat cages with *ad libitum* access to a standard rodent diet and tap water, with a 12:12-hr artificial light cycle, mean temperature 21 ± 2 °C, and mean humidity 55 ± 2 %. At three weeks old, all animals were randomly assigned into four groups, for the following treatments:

Group 1: Control (CONT), n = 6, normal saline alone, injected with normal saline (200 mg/kg)

by intraperitoneal injection (i.p.) 30 minutes before a sham irradiation;

Group 2: Irradiation alone (RT), n = 8, injected with normal saline (200 mg/kg) by i.p. 30 minutes before irradiation;

Group 3: Amifostine before irradiation (AMI+RT), n = 8, injected with amifostine (200 mg/kg) by i.p. 30 minutes before irradiation;

Group 4: L-carnitine before irradiation (LC+RT), n = 8, injected with L-carnitine (300 mg/kg) by i.p. 30 minutes before irradiation. Selection of the 30-min interval between L-carnitine administration and exposure to radiation was based on our previous study on animals (7).

All experimental procedures were performed on anesthetized rats. Anesthesia was maintained with ketamine and xylazine (50 mg/kg BW and 10 mg/kg BW, i.m.) during irradiation. The follow-up period was 5 days, during which all rats were monitored by the veterinary care staff.

Irradiation

The rats in AMI+RT, LC+RT, and RT groups were irradiated individually with a single dose of 20 Gy through an anterior 4×3 cm single portal to whole abdomen, using 60Co treatment unit (Cirrus, cis-Bio Int., Gif Sur Yvette, France) at a source skin distance of 65 cm. The dose rate was 0.59 Gy/min. The rats were anesthetized and then fixed onto a 20×30 cm blue Styrofoam treatment couch (Med-Tec, Orange City, IA) in a prone position. Correct positioning of the fields was controlled for each individual rat by use of a therapy simulator (Mecaserto-Simics, Paris, France). Special dosimetry was done for the irregular fields. Dose homogeneity across the field was ± 5 %. After irradiation, the animals were closely observed until recovery from anesthesia. The CONT group received an equal field sham irradiation.

Euthanasia

The rats were euthanized 5 days after the radiation therapy. Prior to euthanasia, the rats received anesthesia in the form of a ketamine and xylazine combination. Euthanasia was performed by decapitation.

Histopathological analysis

Histological evaluation was performed according to the classification proposed by Kiris *et al.* (17). Kidneys that were removed from rats at the end of the experimental period were cut into two sagittal sections and then fixed in 10% formaldehyde at room temperature for 24 hours and processed in graded alcohols and xylene before being embedded in paraffin blocks. Using a microtome, slide sections of 5 µm were taken from the paraffin blocks. Sections were then deparaffinized with xylene and stained with hematoxylin and eosin (H-E). Histological evaluation was performed in a blinded manner by a pathologist under a light microscope. Renal specimens were evaluated according to glomerular sclerosis, focal glomerular necrosis, dilatation of Bowman’s capsule, degeneration of tubular epithelium, necrosis in tubular epithelium, tubular dilatation, interstitial inflammatory infiltration, congestion of blood vessels, vessel wall thickening, and interstitial fibrosis. Histological changes were scored on a 4-point scale: (-) no changes; (+) focal, mild changes; (++) multifocal intermediate changes; and (+++) prominent, extensive changes.

Statistical analysis

The data were analyzed using standard statistical methods (Statistica version 7 software). One-way analysis of variance (ANOVA) was used for statistical comparisons among the groups. The statistical analysis was conducted using one-way ANOVA followed by a post hoc Tukey’s honestly significant difference test. A *p*-value of less than 0.05 was considered to indicate significance.

RESULTS

Histopathologic analyses were conducted on 30 rats. There were no deaths during the follow-up period. Renal damage for each group is summarized in table 1. Histopathological damage such as dilatation of Bowman’s capsule, congestion of blood vessels, and tubular epithelial degeneration were significantly different among the groups (*p* < 0.05). The interstitial inflammatory infiltration was the same among the groups. There was no evidence of tubular epithelial necrosis, focal glomerular necrosis, tubular dilation, vessel wall thickening,

Table 1. Frequency of pathological damage in each group according to the grade of damage.

	CONT (n=6)	RT (n=8)	LC+R(n=8)	AMI+ R(n=8)	<i>p value*</i>
<i>The dilatation of Bowman's capsule</i>					
Grade 0	6	-	-	1	<0.05
Grade 1	-		3	5	
Grade 2	-		5	2	
Grade 3	-	8	-	-	
<i>Congestion of blood vessels</i>					
Grade 0	5	-	-	-	<0.05
Grade 1	1	-	1	3	
Grade 2	-	-	5	4	
Grade 3	-	8	2	1	
<i>Tubular epithelial degeneration</i>					
Grade 0	6	-	-	-	<0.05
Grade 1	-	2	5	5	
Grade 2	-	-	3	3	
Grade 3	-	6	-	-	

Data show the number of rats in each group. **p value* generated from ANOVA test.
AMI + RT, 200 mg/kg, i.p., amifostine 30 min prior to irradiation; LC + RT, 300 mg/kg, i.p., L-carnitine 30 min prior to irradiation; RT, normal saline 30 min prior to irradiation; CONT, normal saline 30 min prior to sham irradiation.

interstitial fibrosis, or glomerular sclerosis.

Dilatation of Bowman's capsule was significantly higher in the RT group than in the CONT group ($p < 0.05$). All rats in the RT group had grade 3 Bowman's capsule dilatation (figure 1; panels a, b, and c). However, grade 3 dilatation was not seen in either the AMI+RT or LC+RT groups. Pre-treatment with amifostine or L-carnitine reduced the radiation-induced dilatation of Bowman's capsule ($p < 0.05$). However, this parameter was also significantly different between the CONT group and both the LC+RT and AMI+RT groups ($p < 0.05$). Grade 0 damage was observed only in the AMI+RT group and not in the LC+RT group (figure 2). Grade 2 damage was more dominant in the LC+RT group while grade 1 damage was observed in the AMI+RT group. The protective effect of L-carnitine was statistically similar to that of amifostine for this parameter.

The congestion of blood vessels increased

significantly in RT ($p < 0.05$), LC+RT ($p < 0.05$) and AMI+RT ($p < 0.05$) as compared to the CONT group. Five rats remained undamaged, although one had congestion of blood vessels. Moreover, all rats in RT exhibited grade 3 injury. As compared to irradiation alone, L-carnitine and amifostine decreased the congestion of blood vessels significantly ($p < 0.05$). Two rats in LC+RT and one rat in AMI+RT had grade 3 congestion. The protective effect of L-carnitine and amifostine was similar (figure 3 and 4).

Tubular epithelial degeneration, the other radiation-induced acute damage, was significantly increased in RT ($p < 0.05$) as compared to CONT. In RT, two rats had grade 1 injury and 6 rats had grade 3 injury. L-carnitine and amifostine before irradiation reduced the damage ($p < 0.05$). The degree of tubular epithelial degeneration was similar in LC+RT and AMI+RT. Grade-3 damage was not observed in either LC+RT or AMI+RT.

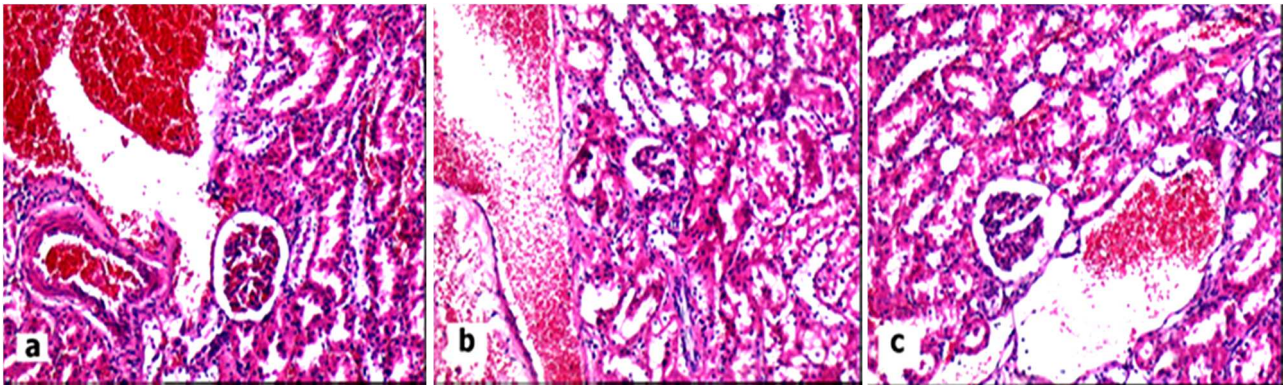


Figure 1. (panel a, b, and c): Microscopy of the renal tissue demonstrating significant dilatation of the bowman capsule and congestion of the blood vessels in the radiotherapy group (HE×25).

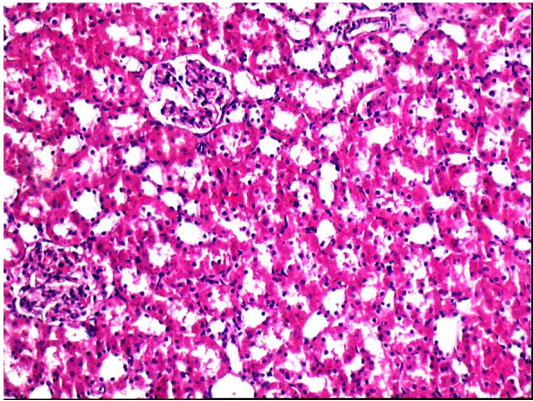


Figure 2. Normal histomorphology of the kidney with no dilatation of the Bowman capsule and congestion of the blood vessels in the control group (HE×25).

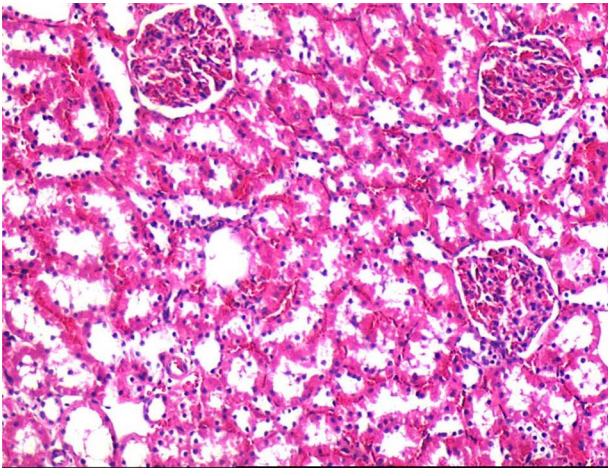


Figure 3. Microscopy of the renal tissue demonstrating slight dilatation and congestion of the blood vessels in the amifostine group (HE×25).

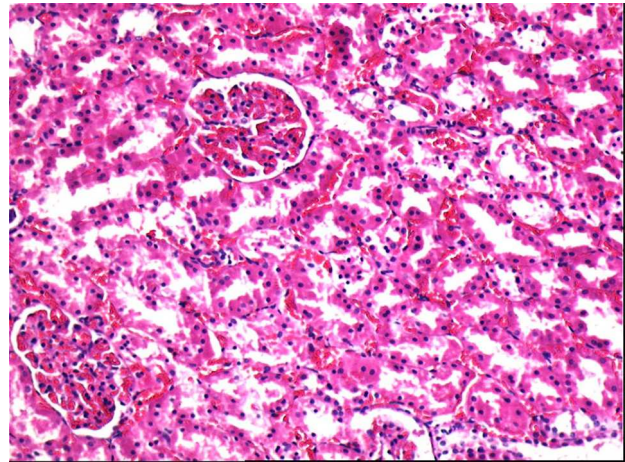


Figure 4. Microscopy of the renal tissue demonstrating slight dilatation and congestion of the blood vessels in the carnitine group (HE×25).

DISCUSSION

Treatment prior to irradiation with L-carnitine decreased radiation-induced dilatation of Bowman's capsule, congestion of blood vessels, and tubular epithelial degeneration to the same extent as amifostine, as determined from the histopathological findings. However, this amelioration did not restore the parameters to the CONT level. Neither L-carnitine nor amifostine were found to have any protective effect against interstitial inflammatory infiltration. There was no evidence of tubular epithelial necrosis or of focal glomerular necrosis.

Acute kidney injury (AKI) is a rapid decrease in renal function over days to weeks, causing an accumulation of nitrogenous products in the blood. The causes of AKI can be classified as prerenal, renal, and postrenal. Symptoms include anorexia, nausea, and vomiting. Seizures and coma may occur if the condition is untreated. Fluid, electrolyte, and acid-base disorders develop quickly; treatment is directed at the cause but also includes fluid and electrolyte management and sometimes dialysis. Although many causes are reversible if diagnosed and treated early, the overall survival rate remains at about 50% because many patients with AKI have significant underlying disorders. Most survivors have adequate kidney function, but about 10% require dialysis or

transplantation—half of those immediately and the others as renal function slowly deteriorates⁽¹⁸⁾. Irradiation is a renal cause of AKI. For cancer patients, AKI can be a serious, life-threatening condition. At the very least, it can be an obstacle to delivery of optimal cancer treatment or may cause interruption of treatment and hospitalization. For that reason, the effort to avoid onset of AKI during RT is an important aspect of the treatment of cancer patients by abdominal irradiation. To our knowledge, no study to date has assessed the effectiveness of LC and amifostine on radiation-induced acute renal failure.

The effects of irradiation on tissues, such as immediate or delayed cell death, cellular injury, arrest of cellular division, or abnormal repair, are to be expected. All components of the kidney, including blood vessels, tubular epithelium, glomeruli, and interstitium are affected in radiation-induced renal damage. In current clinical practice, doses of radiation to the kidneys are lower than the doses in traditional treatments, which are usually greater than 20 Gy and are more frequently associated with radiation nephropathy⁽¹⁹⁾. Almost fifty years ago, Luxton identified 25 Gy as the threshold dose for radiation nephropathy, but this applied to irradiation spread out in multiple fractions over 25 to 30 days⁽²⁰⁾. Cassady pooled the data on bilateral whole kidney RT tolerance and confirmed a threshold dose for RT injury of 15

Gy, with a 5% and 50% risk of injury at 5 years for whole-kidney RT of 18 Gy and 28 Gy, respectively, within 5 weeks ⁽²¹⁾. In the present study, 20 Gy was used in accordance with previous pioneering studies ^(22, 23), and irradiation-induced acute renal damage was evidenced by the histopathological lesions in kidney tissues. Robbins *et al.* irradiated rat kidneys with a single dose of 10–20 Gy X-rays and reported a chronic, progressive, dose-dependent reduction in renal functions. They emphasized that this process was initially observed 8 weeks post-irradiation and progressed to ultimate renal failure from approximately 16 weeks onward, after a dose of 20 Gy X-rays ⁽²²⁾.

Rats have also been used in 'preclinical irradiation studies' involving exposure to high radiation doses. Following a dose of 30 Gy, there is acute congestion, interstitial edema, and cloudy swelling of tubular and glomerular cells. These abnormalities disappear, and no change is noted until Day 15 when thickening of the glomerular basement membrane and pyknosis of glomerular epithelial cells becomes evident. By days 26–45, there is substantial basement membrane thickening, endothelial swelling, decreased glomerular nuclei and telangiectasia of glomerular loops with focal necrosis. By this time, the tubules show extensive pyknosis, intraluminal casts, and foci of inflammation associated with regenerating tubules. Within 4 months, the necrosis and inflammation subside and extensive fibrosis develops. The arterioles show internal fibrosis and elastosis. Nephrosclerosis develops in animals surviving 100 days or longer after 10 Gy ^(14, 24-27).

L-carnitine can act as a free radical scavenger and antioxidant. In addition, L-carnitine can control carbohydrate metabolism to maintain cell membrane structure and cell viability, and it is a necessary cofactor in the oxidation of long-chain fatty acids. Moreover, L-carnitine increases endogenous antioxidant defense mechanisms, which may have protected the animals from radiation-induced organ toxicity.

Altas *et al.* showed that L-carnitine could improve radiation-induced cochlear damage in guinea pigs ⁽¹⁴⁾. In a rat study by Kocer *et al.*,

L-carnitine also was shown to serve as a protective agent against irradiation-induced lens damage ⁽¹⁶⁾. The radioprotective properties of L-carnitine in delaying the onset and decreasing the severity of radiation-induced oral mucositis have also been reported in another animal study ⁽¹⁵⁾.

In the present study, one of the radiation-induced acute injuries was the dilatation of Bowman's capsule. Damage to Bowman's capsule was observed by Kanter *et al.* in the acute phase after irradiation; pre-treatment with amifostine reduced this damage ⁽²⁸⁾. In the present study, all rats in the RT group had grade 3 dilatation of Bowman's capsule. Pretreatment with amifostine as well as L-carnitine decreased this damage. However, the main damage score was in the LC+RT group (grade 2), while in the AMI+RT group, it was grade 1.

This study has shown radiation-induced acute morphologic changes in the kidney, consisting of congestion of blood vessels. However, we found no inflammatory changes in the vascular walls as reported in previous research. Madrazo *et al.*, for instance, reported inflammation in the vicinity of the blood vessels, but found no evidence of inflammation of the vascular walls ⁽²⁴⁾. In the present study, all rats in the RT group had grade 3 congestion; acute congestion after 30 Gy was observed in previous studies ⁽²⁴⁻²⁷⁾.

L-carnitine and amifostine significantly decreased the congestion of blood vessels as compared with irradiation alone ($p < 0.05$). Two rats in LC+RT and one rat in AMI+RT had grade 3 congestion. The protective effect of L-carnitine was similar to that of amifostine. Neither amifostine nor L-carnitine ameliorated radiation-induced acute edema to control level.

The microscopic lesions described in the kidneys following irradiation usually indicate that the primary lesion is mainly tubular, and it would appear that this portion of the nephrons is more radiosensitive than the glomerular tissue ⁽⁷⁾. Madrazo *et al.*, reported that the earliest detectable change was observed after irradiation consisting of vacuolation and hyaline droplets in the cytoplasm of the tubules ⁽²⁴⁾. In the present study, tubular epithelial degeneration was found to be significantly

different among the groups. Both amifostine and L-carnitine significantly ameliorated this damage, with no difference in the level of protective effect. However, as necrosis in the tubular epithelium was not shown, this is considered to be related to late effect. The protective effect of amifostine against radiation-induced acute renal damage has previously been shown in animal models. Kanter *et al.* found acute loss of luminal brush border in tubules after irradiation, and pre-treatment with amifostine markedly prevented these tubular changes ⁽²⁸⁾. Caloglu *et al.*, used histopathological and functional methods to compare the protective effects of L-carnitine and amifostine against radiation-induced late nephrotoxicity ⁽⁷⁾. They found that tubular damage was less common in the L-carnitine and amifostine group than in the irradiation group. To our knowledge, no study to date has evaluated the protective effect of L-carnitine on radiation-induced acute nephrotoxicity.

The present study is limited by not having evaluated radiation-induced kidney injury by reference to oxidative stress markers, antioxidants, plasma parameters of blood chemistry (such as blood urea nitrogen and creatinine), and isotope scintigraphy. The aim of this study was to compare the effectiveness of amifostine and L-carnitine in protecting against radiotherapy-induced acute kidney damage, using histopathological methods. Further studies, evaluating both renal and whole-body markers of oxidative stress and renal function, are necessary to determine the mechanisms of the protection afforded by these compounds. Further studies are also needed to evaluate the protective effects of amifostine and L-carnitine at all stages, from acute to late phases, to understand the progression of damage in radiation-induced nephropathy.

In conclusion, based on the results of the present study, L-carnitine can be said to protect against single fraction irradiation-induced acute renal injury, as does amifostine. Radiation-induced renal damage remains a significant clinical side effect for cancer survivors, and it would therefore also be worthwhile to study the effects of *in vivo* administration of L-carnitine

and amifostine in radiation-treated cancer patients, with the prospect of reducing radiation-induced renal damage.

Conflicts of interest: none to declare.

REFERENCES

1. Dawson LA, Kavanagh BD, Paulino AC, Das SK, Miften M, Li XA *et al.*, (2010) Radiation-associated kidney injury. *Int J Radiat Oncol Biol Phys*, **76**(3): S108-15.
2. Weiss JF and Landauer MR (2000) Radioprotection by antioxidants. *Ann N Y Acad Sci*, **899**: 44-60.
3. Williams MV and Denekamp J (1983) Modification of the radiation response of the mouse kidney by misonidazole and WR-2721. *Int J Radiat Oncol Biol Phys*, **9**(11): 1731-6.
4. Kouloulas VE, Kouvaris JR, Kokakis JD, Kostakopoulos A, Mallas E, Metafa A *et al.*, (2004) Impact on cytoprotective efficacy of intermediate interval between amifostine administration and radiotherapy: a retrospective analysis. *Int J Radiat Oncol Biol Phys*, **59**(4): 1148-56.
5. Uzal C, Durmus-Altun G, Caloglu M, Ergulen A, Altaner S, Yigitbasi NO (2004) The protective effect of amifostine on radiation-induced acute pulmonary toxicity: detection by (99m)Tc-DTPA transalveolar clearances. *Int J Radiat Oncol Biol Phys*, **60**(2): 564-9.
6. Kaldır M, Cosar-Alas R, Cermik TF, Yurut-Caloglu V, Saynak M, Altaner S *et al.*, (2008) Amifostine use in radiation-induced kidney damage. Preclinical evaluation with scintigraphic and histopathologic parameters. *Strahlenther Onkol*, **184**(7): 370-5.
7. Caloglu M, Yurut-Caloglu V, Durmus-Altun G, Oz-Puyan F, Ustun F, Cosar-Alas R *et al.*, (2009) Histopathological and scintigraphic comparisons of the protective effects of L-carnitine and amifostine against radiation-induced late renal toxicity in rats. *Clin Exp Pharmacol Physiol*, **36**(5-6): 523-30.
8. Andreassen CN, Grau C, Lindegaard JC (2003) Chemical radioprotection: a critical review of amifostine as a cytoprotector in radiotherapy. *Semin Radiat Oncol*, **13**(1): 62-72.
9. Kligerman MM, Glover DJ, Turrisi AT, Norfleet AL, Yuhas JM, Coia LR *et al.*, (1984) Toxicity of WR-2721 administered in single and multiple doses. *Int J Radiat Oncol Biol Phys*, **10**(9): 1773-6.
10. Vanella A, Russo A, Acquaviva R, Campisi A, Di Giacomo C, Sorrenti V *et al.*, (2000) L-propionyl-carnitine as superoxide scavenger, antioxidant, and DNA cleavage protector. *Cell Biol Toxicol*, **16**(2): 99-104.
11. Bertelli A, Conte A, Ronca G (1994) L-propionyl carnitine protects erythrocytes and low density lipoproteins against peroxidation. *Drugs Exp Clin Res*, **20**(5): 191-7.
12. Fritz IB and Arrigoni-Martelli E (1993) Sites of action of carnitine and its derivatives on the cardiovascular system: interactions with membranes. *Trends Pharmacol Sci*, **14** (10): 355-60.

13. Mansour HH (2006) Protective role of carnitine ester against radiation-induced oxidative stress in rats. *Pharmacol Res*, **54**(3): 165-71.
14. Altas E, Ertekin MV, Gundogdu C, Demirci E (2006) L-carnitine reduces cochlear damage induced by gamma irradiation in Guinea pigs. *Ann Clin Lab Sci*, **36**(3): 312-8.
15. Ucuncu H, Ertekin MV, Yoruk O, Sezen O, Ozkan A, Erdogan F *et al.*, (2006) Vitamin E and L-carnitine, separately or in combination, in the prevention of radiation-induced oral mucositis and myelosuppression: a controlled study in a rat model. *J Radiat Res*, **47**(1): 91-102.
16. Kocer I, Taysi S, Ertekin MV, Karslioglu I, Gepdiremen A, Sezen O *et al.*, (2007) The effect of L-carnitine in the prevention of ionizing radiation-induced cataracts: a rat model. *Graefes Arch Clin Exp Ophthalmol*, **245**(4): 588-94.
17. Kiris I, Kapan S, Kilbas A, Yilmaz N, Altuntas I, Karahan N *et al.*, (2008) The protective effect of erythropoietin on renal injury induced by abdominal aortic-ischemia-reperfusion in rats. *J Surg Res*, **149**(2): 206-13.
18. Rewa O and Bagshaw SM (2014) Acute kidney injury-epidemiology, outcomes and economics. *Nat Rev Nephrol*, **10**(4): 193-207.
19. Cohen EP and Robbins ME (2003) Radiation nephropathy. *Semin Nephrol*, **23**(5): 486-99.
20. Luxton RW (1953) Radiation nephritis. *Q J Med*, **22**(86): 215-42.
21. Cassady JR (1995) Clinical radiation nephropathy. *Int J Radiat Oncol Biol Phys*, **31**(5): 1249-56.
22. Robbins ME, O'Malley Y, Zhao W, Davis CS, Bonsib SM (2001) The role of the tubulointerstitium in radiation-induced renal fibrosis. *Radiat Res*, **155**(3): 481-9.
23. Robbins ME, Zhao W, Davis CS, Toyokuni S, Bonsib SM (2002) Radiation-induced kidney injury: a role for chronic oxidative stress? *Micron*, **33**(2): 133-41.
24. Madrazo A, Suzuki Y, Churg J (1969) Radiation nephritis: acute changes following high dose of radiation. *Am J Pathol*, **54**(3): 507-27.
25. Berdjis CC (1978) Experimental acute renal failure in primates. Clinical and histopathologic evaluation in light and electron microscopy. *Urology*, **12**(5): 598-604.
26. Guttman PH. and Kohn HI (1960) Progressive intercapillary glomerulosclerosis in the mouse, rat, and Chinese hamster, associated with aging and X-ray exposure. *Am J Pathol*, **37**: 293-307.
27. Rich, JG, Glagov S, Larsen K, Spargo B (1961) Histochemical studies of rat kidney after abdominal x-irradiation. *Arch Pathol*, **72**: 388-409.
28. Kanter M, Topcu-Tarlacalisir Y, Uzal C (2011) Role of amifostine on acute and late radiation nephrotoxicity: a histopathological study. *In vivo*, **25**(1): 77-85.