

## Ameliorative effects of Hesperidin on radiation induced brain injury in rats

A. Kale<sup>1\*</sup>, Ö. Pişkin<sup>2</sup>, Y. Baş<sup>3</sup>, B.G. Aydın<sup>2</sup>, M. Can<sup>4</sup>, Ö. Elmas<sup>5</sup>, Ç. Büyükuysal<sup>6</sup>

<sup>1</sup>Department of Neurosurgery, Bülent Ecevit University Faculty of Medicine, Zonguldak, Turkey

<sup>2</sup>Department of Anesthesiology and Reanimation, Bülent Ecevit University Faculty of Medicine, Zonguldak, Turkey.

<sup>3</sup>Department of Pathology, Hitit University Faculty of Medicine, Çorum, Turkey

<sup>4</sup>Department of Biochemistry, Bülent Ecevit University Faculty of Medicine, Zonguldak, Turkey

<sup>5</sup>Department of Radiation Oncology, Bülent Ecevit University Faculty of Medicine, Zonguldak, Turkey

<sup>6</sup>Department of Biostatistics, Bülent Ecevit University Faculty of Medicine, Zonguldak, Turkey

### ABSTRACT

**Background:** Extensive research has been focused on radiation induced brain injury. Animal and human studies have shown that flavonoids have remarkable toxicological profiles. This study aims to investigate the neuroprotective effects of hesperidin in an experimental radiation induced brain injury. **Materials and Methods:** 32 adult male Wistar-Albino rats were randomly divided into 4 groups (control, hesperidin, radiation, and radiation+hesperidin groups; 8 rats in each group). 200 mg/kg doses of hesperidin were administered to the animals in the hesperidin and radiation+ hesperidin groups, radiation and radiation+ hesperidin groups were exposed to a dose of 20 Gy cranium region. Tissue samples, and biochemical levels of tissue injury markers in four groups were compared. **Results:** In all measured parameters of oxidative stress, administration of hesperidin significantly demonstrated favorable effects. Both plasma and tissue levels of malondialdehyde and total antioxidant status significantly changed in favor of antioxidant activity. Histopathological evaluation of the tissues also demonstrated significant decrease in cellular degeneration and infiltration parameters after hesperidin administration. **Conclusion:** This Hesperidin demonstrated significant neuroprotection after radiation induced brain injury. Further studies with different experimental settings including neurological outcome are required to achieve conclusive results.

**Keywords:** Radiation, brain injury, hesperidin, neuroprotection.

### ► Original article

#### \*Corresponding authors:

Kale Aydemir, M.D.,

Fax: +90 372 261 0264

E-mail:

aydemirkale@gmail.com

Revised: April 2018

Accepted: June 2018

Int. J. Radiat. Res., April 2019;  
17(2): 229-236

DOI: 10.18869/acadpub.ijrr.17.2.229

### INTRODUCTION

The efficacy of radiotherapy in brain metastases, primary central nervous system tumors and various tumors is known, and radiotherapy has been used for a long time. With increasing doses of radiotherapy, the rate of tumor control increases. At the same time, the risk of normal brain tissues being affected is also increased, which in turn results in an increased risk of complications. Therefore, tumor control, in a sense, is dependent on the radiotherapy tolerance of normal brain tissue <sup>(1,2)</sup>. Brain injury

due to radiation is a continuous and dynamic process. Based on the time course of the clinical picture, brain injury can be classified under three phases as acute, early delayed, and late delayed <sup>(3)</sup>. The mechanisms of radiation induced brain injury corresponding to clinical findings are not fully understood. After irradiation, ischemia theories due to direct destruction of brain parenchymal cells and damage to the vascular system have been developed <sup>(4,5)</sup>.

Recent research on radiation induced brain injury have benefited from using animal models.

In particular, rats have been used to elicit a variety of pathological changes (eg, vascular lesions, edema, necrosis and demyelination) (4). At the molecular, cellular and tissue levels, neuroinflammation, epigenetic and histopathological changes, apoptosis, impaired cell proliferation and differentiation, and other radiation induced phenomena can be observed. In radiation damage, radiation dose, fractionation and volume play an important role.

The basic mechanism of ionizing radiation occurs in two ways, either by causing cell death or by the mechanism of indirect action. The actual injury is caused by the indirect mechanism. Ionized radiation generates radical oxygen species (ROS) that are created by the ionization of water in the environment. The resulting ROS leads to the oxidation of macromolecules such as proteins, DNA, lipids, and mediates the damaging effect of ionizing radiation in biological systems. As a result, lipid peroxidation and protein oxidation products increase (6-8). The antioxidant system is a protective mechanism, which fights against oxidants, consisting of many antioxidants that are derived from exogenous/endogenous sources. Antioxidant drugs or agents that neutralize ROS have been reported to reduce ionizing radiation induced injury (2,7,9,10). Flavonoids are known to have antioxidant properties that can liberate free radicals directly, inhibit the enzymes of oxygen reduction pathways, and detect transient metal cations (11-13). This has raised a growing interest with the effects. Hesperidin (HP) is a bioflavonoid which is abundant in citrus species such as lemon and orange and is known to have pharmacological activities such as antioxidant, analgesic, anti-carcinogenic, antihypertensive, antiviral and antiinflammatory effects (14). HP is a powerful radical scavenger that facilitates the cellular antioxidant defense mechanisms and can also traverse the blood brain barrier (15,16).

Various in vitro studies with experimental animals and humans have provided supportive evidence for neuroprotective effects of HP against both neurotoxic chemicals and in various models of neuronal damage and neurodegenerative diseases (17-24). The

neuroprotective efficacy of hesperidin is attributed to its ability of inhibiting Fe<sup>2+</sup>-induced linoleate peroxidation and auto-oxidation of cerebral membranes, scavenging peroxy nitrite radicals and inhibition of ROS generation, including hydroxyl radical (25-27). Although many hypotheses have been developed, the precise mechanisms of these protective effects have not been fully explored. While its neuroprotective properties are known, literature on the role of hesperidin in ionizing radiation induced brain injury is still in its infancy. To our knowledge, this study is the first one to investigate the neuroprotective effects of hesperidin against brain injury after ionizing radiation.

## **MATERIALS AND METHODS**

### **Chemicals**

Hesperidin was purchased from Sigma-Aldrich Co (St Louis, MO, USA).

### **Animals and experimental protocol**

After the study was approved by the Animal Experiments Local Ethical Committee of Zonguldak (Turkey), Bulent Ecevit University (BEUN) School of Medicine, 2017-11-06/04, 32 adult (6-8 month old) male Wistar-Albino rats weighing 300 to 350 g were randomly divided into 4 groups. All of the rats included in the study were obtained from BEUN Experimental Animals Research Unit, all of them have been fed with standard rat pellets and housed in temperature and humidity controlled (23±1°C and 55% relative humidity) rooms that were lit on a daily schedule (12:12 hours light/dark) until the day of experiment. During the experiment, the care of the laboratory animals were in accordance with international guidelines.

The control group was given only physiological saline (PS) (n=8), group HP was given Hesperidin 200 mg/kg body weight (BW) daily in distilled water and 0.25 ml PS for 15 day (n=8), group RAD was given only irradiation (n=8) and group RAD+HP was given HP 50 mg/kg BW daily in distilled water and 0.25 ml PS for 15 day and then irradiated (n=8). At the end of

15 days, the animals of group RAD and RAD+HP were exposed to a dose of 20 Gy cranium region. All rats were decapitated at 7 days after exposure to radiation.

### **Irradiation**

Simulation of a rat was done with a 1 mm slice computerized tomography scan, and the dose calculation was performed with the Eclipse treatment planning system version 8.9 (Varian Medical Systems, Palo Alto, CA, USA). Anaesthetized (90 mg/kg ketamine and 10 mg/kg xylazine i.p.) rats in the prone position were subjected to whole-body irradiation with a single dose of 20 Gy photon using a 6 MV linear accelerator (Clinac, Varian Medical Systems, Palo Alto, CA, USA) at a dose rate of approximately 1 Gy/min with the source-axis distance technique with 1.0 cm of bolus material on the surface. Animals were returned to their home cages following irradiation. Control animals were anaesthetized but were not exposed to radiation.

### **Chemical analysis**

Tissue samples were homogenized with phosphate buffered saline (pH 7.4) using a glass Teflon homogenizer (Ultra Turrax IKA T18 Basic) after cutting the tissues into small pieces with scissors (for 2 min at 5,000 rpm). The homogenate was then centrifuged at 5,000 g for 15 min. The supernatant was used for the analysis. Serum and tissue levels of total antioxidant status (TAS) and malondialdehyde (MDA) were measured by colorimetric method using TAS and MDA kit (Oxford Biomedical Research, Oxford, USA) in accordance with the manufacturer's protocol.

### **Histopathological evaluation**

Brain samples taken from rats were fixed in 10% formalin for 12 hours and then embedded in paraffin. 5 micron thick sections were taken from the tissues and stained with hematoxylin and eosin stain. The white matter of brain tissue was examined in 4 groups. Seven parameters were evaluated as hypertrophy in astrocytes, microglial reaction, inflammatory reaction, vascular telangiectasis, endothelial enlargement, edema and axonal damage. The damage severity

score in the tissue and cells was determined. Each criterion was scored from 0 to 3 (0=normal, 1=mild damage 2=moderate damage 3=severe damage).

### **Statistical analysis**

Statistical analyses were performed in SPSS 19.0 package software. The descriptive statistics of the measurement variables consisting of median, minimum and maximum values are provided. The Shapiro Wilk test was used for the normal distribution test. Kruskal Wallis test was used for comparison of 4 independent groups, and Mann-Whitney U-test with Bonferroni correction was used for subgroup comparisons. Comparisons with a p value below 0.05 were considered statistically significant in all statistical comparisons in the study.

## **RESULTS**

Values of MDA and TAS in plasma and tissue are shown on table 1.

### **Plasma changes**

Median plasma MDA level of the control group was 3.92  $\mu\text{mol/L}$  (2.87-5.13) and was significantly increased to 7.57  $\mu\text{mol/L}$  (6.26-8.29) in the RAD group ( $p < 0.001$ ). In the RAD+HP group this value decreased significantly to 4.47  $\mu\text{mol/L}$  (3.88-6.44) ( $p < 0.001$ ), (figure 1).

Median plasma TAS level of the control group was 0.36 mmol/L Trolox equivalent (0.32-0.39) and was significantly decreased to 0.30 mmol/L Trolox equivalent (0.27-0.32) in the RAD group ( $p < 0.001$ ). In the RAD+HP group this value increased significantly to 0.35 mmol/L Trolox equivalent (0.33-0.39) ( $p < 0.001$ ), (figure 2).

### **Tissue changes**

The median tissue MDA level of the control group was 53.45 nmol/g wet tissue (45.50-67.40) and the median tissue MDA level was significantly increased in the RAD group to 95.60 nmol/g wet tissue (89.40-108.70) ( $p < 0.001$ ). In the RAD+HP group, this value significantly decreased to 72.65 nmol/g wet tissue (65.50-85.30) ( $p < 0.001$ ), (figure 3).

The median tissue TAS level of the control group was 19.85  $\mu\text{mol Trolox equivalents/g}$  (16.10-23.60) and was significantly decreased in the RAD group at 15.05  $\mu\text{mol Trolox equivalents/g}$  (14.40-16.60) ( $p=0.001$ ). In the RAD+HP group, this value was significantly increased to 23.85  $\mu\text{mol Trolox equivalents/g}$  (21.70-25.10) ( $p<0.001$ ), (figure 4).

**Histopathological evaluation**

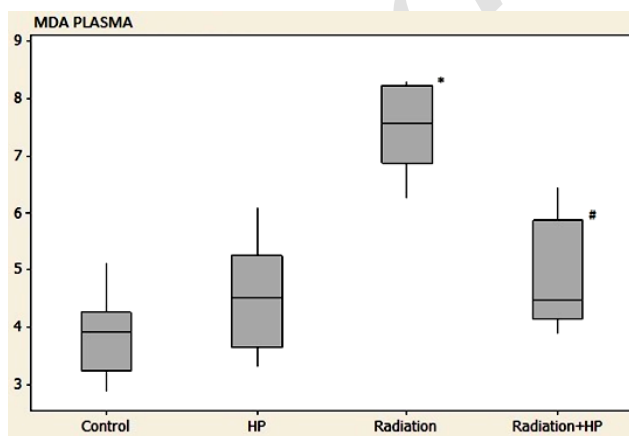
Control and HP groups had normal histomorphologic structure in the brain cortex. In the RAD group, astrocytes showed diffuse hypertrophy, numerical increase and light clusters in nuclear chromatin. The microglial cell reaction was noticeable in the cortical area. The

inflammatory cell reaction is monitored in such a way that the lymphocyte response will form locally clusters. Vascular dilatation, congestion and swelling degeneration in endothelial cells were widely observed. Edema was more prominent especially around veins and Rosenthal fibrils were frequently distinguished (figure 5A-E). In the RAD+HP group, hypertrophy in astrocytes became less frequent. Chromatin clusters had disappeared. The microglial cell reaction diluted. The inflammatory cell reaction was milder. Vascular dilatation and endothelial damage were not significant. Edema was milder (figure 5F). A significant change in damage scores between the groups was detected ( $p<0.05$ ), (figure 6).

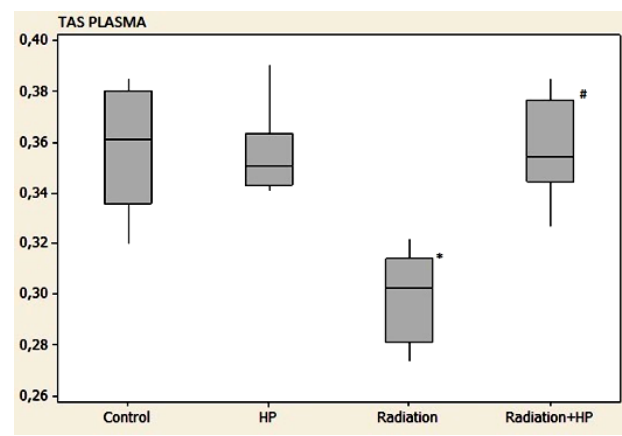
**Table 1.** Values of MDA and TAS in plasma and tissue.

	Control	HP	RAD	RAD+HP
MDA plasma ( $\mu\text{mol/L}$ )	3.92 (2.87-5.13)	4.52 (3.32-6.10)	7.57(6.26-8.29) <sup>a</sup>	4.47(3.88-6.44) <sup>b</sup>
TAS plasma (mmol/LTroloxequivalent)	0.36(0.32-0.39)	0.35 (0.34-0.39)	0.30(0.27-0.32) <sup>a</sup>	0.35(0.33-0.39) <sup>b</sup>
MDA tissue (nmol/g wettissue)	53.45(45.50-67.40)	52.80 (45.90-63.50)	95.60(89.40-108.70) <sup>a</sup>	72.65(65.50-85.30) <sup>b</sup>
TAS tissue ( $\mu\text{molTroloxequivalents/g}$ )	19.85(16.10-23.60)	19.90 (18.50-25.60)	15.05(14.40-16.60) <sup>a</sup>	23.85(21.70-25.10) <sup>b</sup>

a shows significant differences between Control and RAD groups ( $p<0.05$ )  
 b shows significant differences between RAD and RAD+HP groups ( $p<0.05$ )



**Figure 1.** Levels of plasma MDA ( $\mu\text{mol/L}$ ) in groups.



**Figure 2.** Levels of plasma TAS (mmol/LTroloxequivalent) in groups.

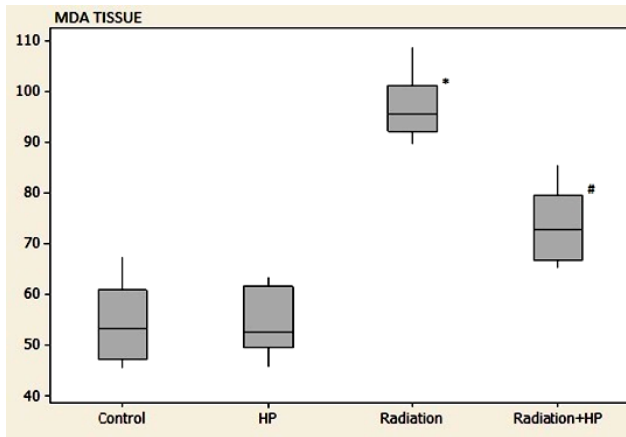


Figure 3. Levels of tissue MDA (nmol/g wettissue) in groups.

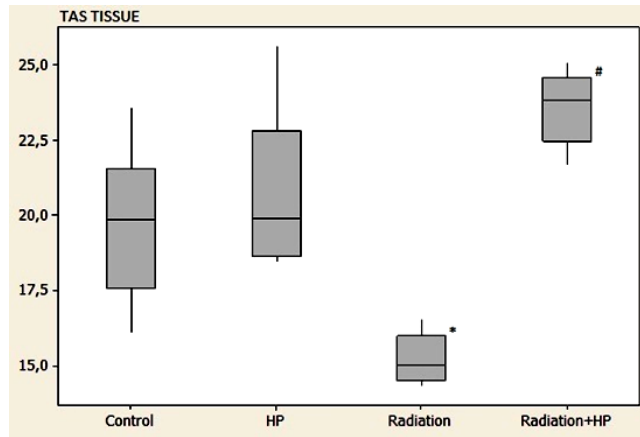


Figure 4. Levels of tissue TAS (μmol Trolox equivalents/g) in groups. \* shows significant differences between Control and RAD groups (p<0.05) # shows significant differences between RAD and RAD+HP groups (p<0.05) (Figure 1,2,3,4)

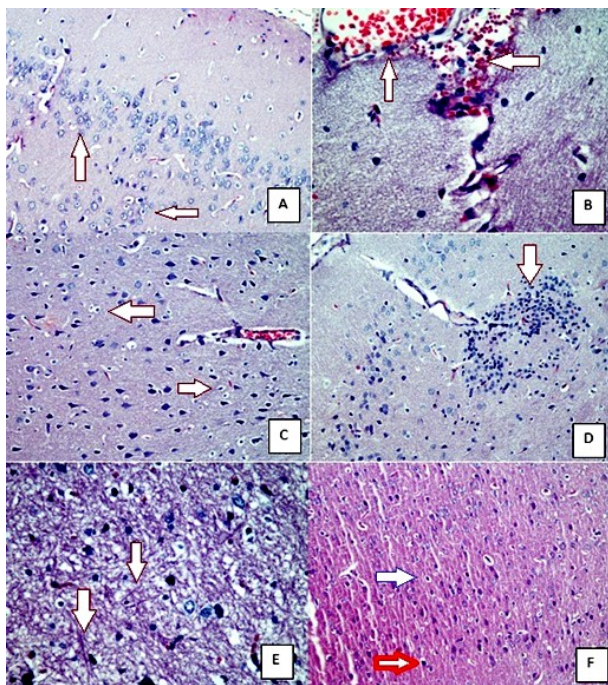


Figure 5. Effects of radiation on brain cortex in RAD group. **A)** Astrocytes showed diffuse hypertrophy (arrows) (H&E, X20) **B)** Vascular dilatation, congestion and endothelial cell enlargement (arrows) (H&E, X40). **C)** Microglial infiltration (arrows) and axonal swelling (H&E, X20) **D)** Inflammatory reaction (arrows) and congestion (H&E, X20) **E)** Edema and prominence of Rosenthal fibers (arrows) (H&E, X40). **F)** In RAD+HP group; Hypertrophy in astrocytes became less frequent, chromatin clusters had disappeared (orange arrow), the microglial cell (white arrow) reaction diluted, the inflammatory cell reaction was milder, vascular dilatation and endothelial damage were not significant, edema was milder.

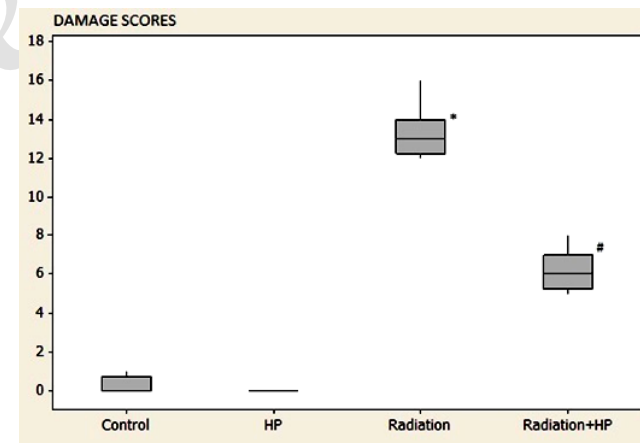


Figure 6. Levels of damage scores in groups. \* shows significant differences between Control and RAD groups (p<0.05) # shows significant differences between RAD and RAD+HP groups (p<0.05) (Figure 1,2,3,4)

## DISCUSSION

Radiotherapy is a widely used method in the treatment of central nervous system tumors. The objective is to apply minimal damage to healthy tissues while delivering an effective dose to the target lesion. Despite protective measures, side effects cannot be prevented completely. The mechanism of tissue damage caused by radiation is not fully understood<sup>(28)</sup>. In this study, biochemical and histopathologic changes were observed by creating a cerebral tissue injury model with single dose radiation.

There are many studies on neural damage and radiation doses, and no consensus has been reached<sup>(1,2,4,5,7,8,10)</sup>. During radiotherapy, ionizing radiation has been shown to interact with biological systems to produce excess ROS leading to significant cell damage in DNA, proteins, and membrane lipids. Production of excessive oxygen radicals shifts the balance between pro-oxidant and antioxidant systems towards the pro-oxidant system. ROS also reduces the intracellular concentration of antioxidants. ROS production is considered to be an important cause of radiation induced tissue damage<sup>(8,28-30)</sup>. The increase in lipid peroxidation is accompanied by an increase in free radical compounds in neuronal cells. Neural membranes in the brain are affected more rapidly by free radicals, especially because they are rich in unsaturated fatty acids, and a higher lipid peroxidation is observed. Therefore, with the increase in the formation of free radicals, both the structure and function of neurons are affected<sup>(2,6,28)</sup>.

Publications suggesting that radiation induced brain injury can be reduced by the use of agents that inhibit the action of ROS have been reported<sup>(2,7,10)</sup>. Specific evidence exists on the neuroprotective effects of HP<sup>(17-19,21,22)</sup>. Studies show that HP can exert neuroprotection and antagonize oxidative stress<sup>(19,21,22)</sup>. Oxidative stress occurs when ROS accumulate in cells, from either excessive production or insufficient neutralization, causing damage to proteins, lipids, and DNA. Mitochondria are a major contributor of cellular ROS; ROS produced in the mitochondria can also target the electron

transport chain, resulting in a cycle where ROS production increases, followed by ATP depletion and ultimately cell death<sup>(31,32)</sup>. Based on these premises, the identification of novel compounds which can counteract oxidative stress as potential therapeutics has drawn considerable interest from academic scholars recently. Natural compounds have received much attention in this regard, and polyphenols such as hesperidin have been investigated.

Rong et al. reported that possible mechanism of the neuroprotective effects of hesperidin are likely the result of free radical reduction and phosphorylated Akt activation and concluded that, hesperidin prevented the increase in ROS and MDA levels, reduce neuronal death, and improved behavior recovery on a hypoxia-ischemic brain injury in neonatal rat<sup>(17)</sup>. Hesperidin also protects primary neurons against hydrogen peroxide and LPS<sup>(33,34)</sup>. Raza et al. demonstrated that HP reduced free radicals and inflammation and limited the extent of brain damage following stroke<sup>(24)</sup>. Nones et al. demonstrated that hesperidin protects post-mitotic neurons from death *in vitro*, leading to an increase in the neuronal population with the activation of the PI3 and MAP kinases pathways<sup>(23)</sup>. Chang et al. reported that hesperidin presynaptically reduced glutamate release in the hippocampus *in-vitro*, and that administering hesperidin prevented KA-induced excitotoxicity *in-vivo*<sup>(21)</sup>.

Malondialdehyde, which emerges as a result of the reaction between polyunsaturated fatty acids and free radicals, is an end product of MDA lipid peroxidation. It changes the membrane properties by causing cross-connection among lipids, proteins, and nucleic acids. So, MDA is one of the best known products of lipid oxidation and it can be used as a marker of cell membrane injury<sup>(35)</sup>. In this study, oxidative and antioxidant activities induced by radiation in the brain were evaluated by MDA and TAS measurements in brain tissue and blood. A significant increase was observed in the RAD group while the MDA values of the blood and the tissue were low in the control group ( $p < 0.001$ ). There was a significant decrease in both parameters in the RAD+HP group ( $p < 0.001$ ). A

significant decrease was observed in the RAD group while the TAS values of blood and tissue were high in the control group ( $p < 0.001$ ). A significant increase was observed in both parameters in the RAD+HP group ( $p < 0.001$ ).

In addition, histopathological evaluation of brain tissue was performed. Hypertrophy, microglial reaction, inflammatory reaction, vascular telangiectasis, endothelial enlargement, edema and axonal damage in astrocytes were evaluated. While the brain tissues were normal in Control and HP groups, RAD group showed diffuse hypertrophy, numerical increase and mild clustering of nuclear chromatin in the astrocytes. The microglial cell reaction was diffuse but relatively mild. The inflammatory cell reaction was diffuse, and the lymphocyte response was especially observed. Vascular dilatation, congestion and swelling degeneration in endothelial cells were widely observed. Edema was more prominent particularly around the veins, and Rosenthal fibrils were frequently distinguished. In RAD+HP group, mild hypertrophy in astrocytes was generally observed. Chromatin clusters had disappeared. The microglial cell reaction became less frequent. The inflammatory cell reaction was milder. Vascular dilatation and endothelial damage were not significant. Edema was milder.

Biochemical and histopathological results show that oxidative stress is increased in the neural tissue damage induced by radiation. Hesperidin treatment reduces this effect. Based on these findings, radiation induced tissue injury can be reduced by lipid peroxidation of hesperidin and its positive effects on the antioxidant system.

Oxidative stress is the cause of neuronal damage in the brain. For this reason, we think that a strong antioxidant such as HP may protect brain tissue against oxidative stress. We have observed that HP treatment protects against radiation-induced brain damage due to its strong antioxidant properties and can prevent damage and lipid degeneration in neurons.

A limitation of our study is that we analyzed only certain biochemical and histopathological parameters. We found that hesperidin exhibits protective and therapeutic effects on radiation

induced brain injury in rats; however, additional experimental and clinical studies are required to confirm our findings before hesperidin treatment for radiation induced brain injury can be used clinically.

## CONCLUSION

Hesperidin demonstrated significant neuroprotection after radiation induced brain injury. Further studies with different experimental settings including neurological outcome are required to achieve conclusive results. Further research to clarify the mechanism underlying the effects of Hesperidin will provide a better understanding of the affected cell targets from this compound.

**Conflicts of interest:** Declared none.

## REFERENCES

1. Mildenerger M, Beach TG, McGeer EG, Ludgate CM (1990) An animal model of prophylactic cranial irradiation: histologic effects at acute, early and delayed stages. *Int J Radiat Oncol Biol Phys*, **18(5)**: 1051-60.
2. Cihan YB, Arsav V, Göcen E (2011) Royal Jelly in the Prevention of Radiation-Induced Brain Damages. *Journal of Neurological Sciences, [Turkish]* **29**: 475-486.
3. Behin A and Delattre JY (2004) Complications of radiation therapy on the brain and spinal cord. *Semin Neurol*, **24**: 405-417.
4. Yang L, Yang J, Li G, Li Y, Wu R, Cheng J, Tang Y (2017) Pathophysiological Responses in Rat and Mouse Models of Radiation-Induced Brain Injury. *Mol Neurobiol*, **54(2)**: 1022-1032.
5. Hopewell JW (1979) Late radiation damage to the central nervous system: a radiobiological interpretation. *Neuropathol Appl Neurobiol*, **5**: 329-343.
6. Gorman AM, McGowan A, O'Neill C, Cotter T (1996) Oxidative stress and apoptosis in neurodegeneration. *J Neurol Sci*, **139**: 45-52.
7. Sezen O, Ertekin MV, Demircan B, Karslioğlu I, Erdoğan F, Koçer I, Calik I, Gepdiremen A (2008) Vitamin E and L-carnitine, separately or in combination, in the prevention of radiation-induced brain and retinal damages. *Neurosurgica Review*, **31**: 205-213.
8. Steen RG, Spence D, Wu S, Xiong X, Kun LE, Merchant TE (2001) Effect of therapeutic ionizing radiation on the

- human brain. *Ann Neurol*, **50**: 787-795.
9. Kondziolka D, Somoza S, Martinez AJ, Jacobsohn J, Maitz A, Lunsford LD, Flickinger JC (1997) Radioprotective effects of the 21-Aminosteroid U- 74389G for stereotactic radiosurgery. *Neurosurg*, **41**: 203-208.
  10. Erol FS, Topsakal C, Ozveren MF, Kaplan M, Ilhan N, Ozercan IH, Yildiz OG (2004) Protective effects of melatonin and vitamin E in brain in damage due to gamma radiation: an experimental study. *Neurosurg Rev*, **27**: 65-69.
  11. Rice-Evans CA, Miller NJ, Paganga G (1996) Structure-antioxidant activity relationships of flavonoids and phenolic acids. *Free Radic Biol Med*, **20**: 933-956 4.
  12. Rice-Evans C (2001) Flavonoid antioxidants. *Curr Med Chem*, **8**: 797-8075.
  13. Gaur V and Kumar A (2010) Hesperidin pre-treatment attenuates NO-mediated cerebral ischemic reperfusion injury and memory dysfunction. *Pharmacol Rep*, **62**: 635-648.
  14. Kamisli S, Ciftci O, Kaya K, Cetin A, Kamisli O, Ozcan C (2015) Hesperidin protects brain and sciatic nerve tissues against cisplatin-induced oxidative, histological and electromyographical side effects in rats. *Toxicol Ind Health*, **31(9)**: 841-51.
  15. Shagirtha K and Pari L (2011) Hesperetin, a citrus flavonone, protects potentially cadmium induced oxidative testicular dysfunction in rats. *Ecotoxicol Environ Saf*, **74(7)**: 2105-11.
  16. Youdim KA, Dobbie MS, Kuhnle G, Proteggente AR, Abbott NJ, Rice-Evans C (2003) Interaction between flavonoids and the blood-brain barrier: in vitro studies. *J Neurochem*, **85(1)**: 180-192.
  17. Rong Z, Pan R, Xu Y, Zhang C, Cao Y, Liu D (2013) Hesperidin pretreatment protects hypoxia-ischemic brain injury in neonatal rat. *Neuroscience*, **255**: 292-9.
  18. Hwang SL, Shih PH, Yen GC (2012) Neuroprotective effects of citrus flavonoids. *J Agric Food Chem*, **60(4)**: 877-85.
  19. Oztanir MN, Ciftci O, Cetin A, Aladag MA (2014) Hesperidin attenuates oxidative and neuronal damage caused by global cerebral ischemia/reperfusion in a C57BL/6 mouse model. *Neurol Sci*, **35(9)**: 1393-9.
  20. Li M, Lin XF, Lu J, Zhou BR, Luo D (2016) Hesperidin ameliorates UV radiation-induced skin damage by abrogation of oxidative stress and inflammatory in HaCaT cells. *J Photochem Photobiol B*, **165**: 240-245.
  21. Chang CY, Lin TY, Lu CW, Huang SK, Wang YC, Chou SS, Wang SJ (2015) Hesperidin inhibits glutamate release and exerts neuroprotection against excitotoxicity induced by kainic acid in the hippocampus of rats. *Neurotoxicology*, **50**: 157-69.
  22. Menze ET, Tadros MG, Abdel Tawab AM, Khalifa AE (2012) Potential neuroprotective effects of hesperidin on 3-nitropropionic acid-induced neurotoxicity in rats. *Neurotoxicology*, **33(5)**: 1265-75.
  23. Nones J, E Spohr TC, Gomes FC (2011) Hesperidin, a flavone glycoside, as mediator of neuronal survival. *Neurochem Res*, **36(10)**: 1776-84.
  24. Raza SS, Khan MM, Ahmad A, Ashafaq M, Khuwaja G, Tabassum R, Javed H, Siddiqui MS, Safhi MM, Islam F (2011) Hesperidin ameliorates functional and histological outcome and reduces neuroinflammation in experimental stroke. *Brain Res*, **28**: 1420: 93-105.
  25. Saija A, Scalese M, Lanza M, Marzullo D, Bonina F, Castelli F (1995) Flavonoids as antioxidant agents, importance of their interaction with biomembranes. *Free Radic Biol Med*, **19(4)**: 481-486.
  26. Kim JY, Jung KJ, Choi JS, Chung HY (2004) Hesperetin, a potent antioxidant against peroxynitrite. *Free Radic Res*, **38(7)**: 761-769.
  27. Jung HA, Jung MJ, Kim JY, Chung HY, Choi JS (2003) Inhibitory activity of flavonoids from *Prunus davidiana* and other flavonoids on total ROS and hydroxyl radical generation. *Arch Pharm Res*, **26(10)**: 809-815.
  28. Durak MA, Parlakpınar H, Polat A, Vardi N, Ekici K, Ucar M, Ozhan O, Yildiz A, Pasahan R (2017) Protective and therapeutic effects of molsidomine on radiation induced neural injury in rats. *Biotech Histochem*, **92(1)**: 68-77.
  29. Ishisaka A, Ichikawa S, Sakakibara H, Piskula MK, Nakamura T, Kato Y, Ito M, Miyamoto K, Tsuji A, Kawai Y and Terao J (2011) Accumulation of orally administered quercetin in brain tissue and its antioxidative effects in rats. *Free Radic Biol Med*, **51(7)**: 1329-36.
  30. Panagiotakos G, Alshamy G, Chan B, Abrams R, Greenberg E, Saxena A, Bradbury M, Edgar M, Gutin P, Tabar V (2007) Long-term impact of radiation on the stem cell and oligodendrocyte precursors in the brain. *PLoS One*, **11(2)**: e588.
  31. Ott M, Gogvadze V, Orrenius S, Zhivotovsky B (2007) Mitochondria, oxidative stress and cell death. *Apoptosis*, **12(5)**: 913-922.
  32. Costa LG, Garrick JM, Roquè PJ, Pellacani C (2016) Mechanisms of Neuroprotection by Quercetin: Counteracting Oxidative Stress and More. *Oxid Med Cell Longev*, **?**: 2986796.
  33. Hwang SL and Yen GC (2008) Neuroprotective effects of the citrus flavanones against H<sub>2</sub>O<sub>2</sub>-induced cytotoxicity in PC12 cells. *J Agric Food Chem*, **56(3)**: 859-64.
  34. Vafeiadou K, Vauzour D, Lee HY, Rodriguez-Mateos A, Williams RJ, Spencer JP (2009) The citrus flavanone naringenin inhibits inflammatory signalling in glial cells and protects against neuroinflammatory injury. *Arch Biochem Biophys*, **484(1)**: 100-9.
  35. Halliwell B and Chirico S (1993) Lipid peroxidation: its mechanism, measurement, and significance. *Am J Clin Nutr*, **57(5)**: 715S-724S.