

Retrograde superselective intra-arterial chemoradiotherapy for squamous cell carcinoma of the buccal mucosa

J.T. Koizumi, S. Minamiyama, Y. Hayashi, K. Osawa, N. Ohashi, T. Ohya, M. Iida, T. Iwai, S. Oguri, M. Hirota, M. Kioi, K. Mitsudo*

Department of Oral and Maxillofacial Surgery, Yokohama City University Graduate School of Medicine, Fukuura, Kanazawa-Ku, Yokohama, Kanagawa 236-0004 Japan

ABSTRACT

Background: The aim of this retrospective study was to evaluate the therapeutic outcomes and organ preservation in patients with squamous cell carcinoma of the buccal mucosa treated with radiotherapy and retrograde superselective intra-arterial chemotherapy. **Materials and Methods:** Between April 2006 and March 2016, 28 patients (3 with stage II; 8 with stage III; and 17 with stage IV) with squamous cell carcinoma of the buccal mucosa were treated with definitive intra-arterial chemoradiotherapy. The median follow-up for all patients was 39 months (range, 4-123 months). Catheterization of the tumor feeding arteries from the superficial temporal and/or occipital arteries was performed. Treatment consisted of radiotherapy (total 50-70 Gy) and daily concurrent superselective intra-arterial chemotherapy (docetaxel, 50-70 mg/m², cisplatin, total 125-175 mg/m²) for 5-7 weeks. **Results:** After intra-arterial chemoradiotherapy, primary site complete response was achieved in 25 (89.3%) of 28 cases. Three-year local control and overall survival rates were 82.1% and 85.4%, respectively. Grade 3 or 4 toxicities included mucositis in 96.4%, and dermatitis in 28.6% of patients. Grade 3 toxicities included dysphagia in 35.7%, neutropenia in 28.6%, anemia in 10.7%, and fever in 7.1% of patients. **Conclusion:** Retrograde superselective intra-arterial chemoradiotherapy for squamous cell carcinoma of the buccal mucosa provided good local control and overall survival.

Keywords: Carcinoma of the buccal mucosa, Chemoradiotherapy, Intra-arterial infusion, Oral cancer, Organ preservation.

► Original article

*Corresponding authors:

Kenji Mitsudo, PhD,
Fax: +81 45 785 8438

E-mail:
mitsudo@yokohama-cu.ac.jp

Revised: June 2018

Accepted: September 2018

Int. J. Radiat. Res., April 2019;
17(2): 283-291

DOI: 10.18869/acadpub.ijrr.17.2.283

INTRODUCTION

Squamous cell carcinoma (SCC) of the buccal mucosa accounts for approximately 10% of all oral cavity SCC in North America, Western Europe and Japan (1,2). However, SCC of the buccal mucosa is not uncommon in Southeast Asia and Indian populations because of the prevalence of betel nut use (3,4). Differences in etiology make it difficult to compare survival and treatment outcomes from Southeast Asian countries to those originating from other countries (5). Although a few clinical studies have examined SCC of the buccal mucosa, these

reports have been limited by a small study population. Larger multi-institutional studies have also been conducted, but they combine patients treated at multiple institutions and lack the strength of numbers needed to draw meaningful conclusions. Finally, SCC of the buccal mucosa is often considered together with other carcinomas of the oral cavity in clinical studies, further confounding conclusions that can be drawn regarding evaluation and treatment (6). Standard treatment of resectable advanced oral SCC, including carcinoma of the buccal mucosa, is surgery with or without adjuvant therapy. For patients with locally

advanced oral cancer, extended resection with reconstructive surgery causes loss of oral function and reduces quality of life. Especially in locally advanced SCC of the buccal mucosa, both aesthetic and functional losses are inevitable because of the anatomical features of the buccal mucosa, and the resection areas often include the surrounding tissue, not only the mucosa, but also the cheek skin, lip, and maxilla and mandible bone. Preserving function and aesthetic features while maintaining or improving locoregional control and the survival rate are important issues. Superselective intra-arterial chemotherapy for head and neck cancer has the advantage of delivering a high concentration of chemotherapeutic agents to the tumor. We developed retrograde superselective intra-arterial chemoradiotherapy (IACRT) for patients with advanced oral SCC, and our treatment results of IACRT for locally advanced oral cancer have been reported to be similar to those of surgery. IACRT can preserve organs and minimize functional disturbance, suggesting the usefulness of this treatment modality⁽⁷⁻¹¹⁾.

The aim of this study was to evaluate the therapeutic results and rate of organ preservation in patients with SCC of the buccal mucosa treated with IACRT and followed at a single institution.

MATERIALS AND METHODS

Patients

Between April 2006 and March 2016, 30 patients with SCC of the buccal mucosa underwent IACRT. Two of these patients were found to be ineligible for the study due to a catheter infection. Thus, 28 patients (19 male, 9 female; median age, 66 years; age range, 40-88 years) were eligible for evaluation in a single-institution, retrospective analysis. (table 1). For all patients, the median follow-up was 39 months (range, 4-123 months).

Eligible patients had untreated, histologically confirmed SCC of the buccal mucosa with no evidence of distant metastases. The primary lesion and cervical lymph nodes were assessed

by positron emission tomography-computed tomography (PET-CT), enhanced CT, magnetic resonance imaging (MRI), and ultrasound examination before treatment. TNM staging was classified according to the 2009 Union for International Cancer Control (UICC) staging system⁽¹²⁾. Patients who had received previous definitive treatment, including surgery and chemoradiotherapy (CRT), were excluded. Patients were required to have an Eastern Cooperative Oncology Group (ECOG) performance status of 0 or 1, a white blood cell count of at least 3500 cells/mm³, a platelet count of at least 100,000/mm³, and a hemoglobin of at least 9 g/dL. Patients with cerebral infarction, or severe liver, kidney, heart, or lung dysfunction were ineligible. The local institutional research board approved this study (No.B141101002), and informed consent was obtained from each participant. The study was conducted in compliance with the Declaration of Helsinki.

Catheterization of target arteries

Before treatment, 3-dimensional computed tomography angiography (3D-CTA) of the carotid artery was performed to identify the main tumor-feeding arteries and determine their morphology. Catheterization of the facial artery (FA) and maxillary artery (MA) from STA was performed according to the method described by Tohnai *et al.*⁽¹³⁾ and Fuwa *et al.*⁽¹⁴⁾. When the tumor had 2 or more feeding arteries, 2 catheters were inserted into the 2 arteries via STA and occipital artery (OA)⁽¹⁵⁾. After catheterization, flow check digital subtraction angiography (DSA) and angio- computed tomography (angio-CT) were performed in all cases.

Radiotherapy

Radiotherapy was planned for all patients after appropriate immobilization using a thermoplastic mask and CT-based techniques. Three-dimensional conformal radiotherapy was performed at 4 or 6 MV and 2 Gy/fraction/day. The irradiation field was changed according to the status of the primary tumor and lymph nodes. In cases of T2N0 disease, the field

contained the primary tumor and the neck levels I to III on the ipsilateral side. In cases of T3-4N0, the field contained the primary site and the neck levels I to III on the bilateral side. The dose delivered was 40Gy/20 fractions and an additional irradiation was delivered to the primary tumor. The planned total dose delivered to the primary tumor was 60Gy/30 fractions. In cases of cervical lymph node metastases, the field contained the primary site and the neck levels I-IV on the ipsilateral side (N1) or the neck levels I-V on the bilateral side (N2). The dose delivered was 40Gy/20 fractions, and an additional irradiation was delivered to the primary tumor and metastatic lymph nodes. The planned total dose delivered to the primary tumor and the metastatic lymph nodes were both 60Gy/30 fractions. The dose to the spinal cord ranged from 40 to 45Gy.

Supers elective intra-arterial chemotherapy

The anticancer agent was injected in a bolus for 1 hour through the intra-arterial catheter when radiotherapy was performed. The planned total dose of docetaxel (DOC) was 60 mg/m² (10mg/m²/week), and that of cisplatin (CDDP) was 150 mg/m² (5 mg/m²/day) (figure 1) ⁽⁷⁻¹¹⁾. When catheters were inserted into the 2 arteries, a half dose of anticancer agents was injected into

each of the two lines. Sodium thiosulfate (2g/body) was administered intravenously to provide effective CDDP neutralization after the anticancer agent was given.

Assessment and follow-up

All patients were evaluated 4weeks after completion of treatment by PET-CT, enhanced CT, and MRI, as the first time assessment of treatment effects. If residual primary tumor or residual metastatic lymph nodes were present after this treatment, a salvage treatment was performed 6–8 weeks after completion of IACRT. After the first assessment, all patients were received regular medical examinations and image evaluations. If primary and/or neck recurrence was detected, salvage surgery was planned as soon as possible.

Toxicity assessment

Toxicities encountered during therapy were evaluated according to the National Cancer Institute – Common Terminology Criteria for Adverse Events v4.0. Evaluation categories were neutropenia, anemia, thrombocytopenia, nausea, oral mucositis, radiation dermatitis, dysphagia, acute kidney injury, and fever as early toxicities, with osteoradionecrosis (ORN) of the jaw and dry mouth as late toxicities.

Table 1. Characteristics of patents with squamous cell carcinoma of the buccal mucosa (n = 28).

Characteristics	No. of patients	(% of total)
Age (years)		
Median	66	
Range	40-88	
Gender		
Male	19	(68)
Female	9	(32)
T classification		
T2	9	(32)
T3	8	(29)
T4a	11	(39)
N classification		
N0	17	(61)
N1	4	(14)
N2b	7	(25)
Stage classification		
II	3	(11)
III	8	(29)
IVA	17	(60)

Statistical analysis

Local control (LC) and overall survival (OS) rates were estimated using the Kaplan-Meier method. Cases of residual or recurrent primary tumor after treatment were considered to be local failures even if salvage surgery was successful. The Cox's proportional hazards model was used to analyze potential variables associated with LC and OS in both univariate

and multivariate analysis. Differences were considered significant when the P value was < 0.05. The results are shown as hazard ratios (HRs), 95% confidence intervals (CIs) and P values on the basis of the Cox's proportional hazards model. Data analysis was performed using SPSS version 20 (IBM SPSS Inc., Armonk, NY).

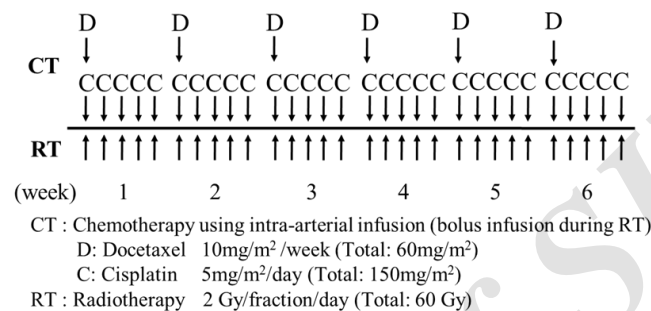


Figure 1. Treatment schedule. Treatment consists of radiotherapy (60 Gy) and daily concurrent superselective intra-arterial chemotherapy (DOC: 60 mg/m², CDDP: 150 mg/m²)

RESULTS

Catheterization into tumor feeding arteries

The tumor-feeding arteries of SCC of the buccal mucosa are MA and FA. Twenty-two patients had 2 tumor-feeding arteries; ipsilateral MA and FA, 2 patients had 4 tumor-feeding arteries; bilateral FAs and MAs, 2 patients had 3 tumor-feeding arteries; one was ipsilateral MA, FA and contralateral MA, and the other was ipsilateral MA, FA and contralateral FA, and 2 patients had 1 tumor-feeding artery; ipsilateral FA.

After catheterization, flow check digital subtraction angiography (DSA) and angio-CT can help to check perfusion to the tumors by confirming enhancement of the feeding area, and weekly staining by injection of a small amount of indigotindisulfonate sodium from the intra-arterial catheter is necessary. Figure 2 shows a case of T3 carcinoma of the buccal mucosa. Perfusion to the tumor is seen from the tumor-feeding arteries.

Treatment results

The median total dose of irradiation was 60 Gy/30 fractions (range, 50-70 Gy), and the

median total doses of DOC and CDDP were 60 mg/m² and 150 mg/m² (range, 50-70 mg/m² and 125-175 mg/m²), respectively. After IACRT, primary site complete response (CR) was achieved in 25 (89.3%) of 28 patients, and residual tumor was seen in 3 (10.7%); 2 of 3 cases refused salvage treatment, and 1 received chemotherapy. Two patients (7.1%) had local recurrence during follow-up. These 5 patients with local failure had T4a disease. Of the 11 patients with cervical lymph node metastases before treatment, 10 patients were achieved clinical CR of the neck lesion after IACRT. The other 1 patient underwent neck dissection and this patient survived for 117 months without disease. Four patients (14.3%) died due to progression of the primary lesion.

The 3-year LC rate of patients with SCC of the buccal mucosa was 82.1% (95% confidence interval [CI]: 68.0-96.2%) (figure 3A). The 3-year OS rate of patients with carcinoma of the buccal mucosa was 85.4% (95% CI: 72.1-98.7%) (figure 3B).

Toxicities

Grade 3 or 4 toxicities included mucositis in 27 cases (96.4%) and dermatitis in 8 cases (28.6

%). Grade 3 toxicities included dysphagia in 18 cases (35.7%), neutropenia in 8 cases (28.6%), anemia in 3 cases (10.7%), and fever in 2 cases (7.1%). No patients died as a result of treatment toxicity. Severe toxicities, included neutropenia, anemia, nausea, and fever, were resolved within 1 month in all cases. Dysphagia recovered in most cases, but 2 patients were dependent on percutaneous endoscopic gastrostomy after IACRT. Late toxicities of grade 1-2 ORN and grade 1-2 dry mouth were seen in 6 cases and 19 cases of 24 survived patients, respectively

(table 2).

Factors related to local control and overall survival

On univariate analysis, a total dose of radiation over 60Gy was significantly associated with OS ($P= 0.018$) (table 3), and there were no significant variables associated with LC. On multivariate analysis, the only significant predictor of OS was total dose of radiation over 60 Gy (HR, 13.81; 95% CI, 1.203-58.718, $P= 0.035$) (table 4).

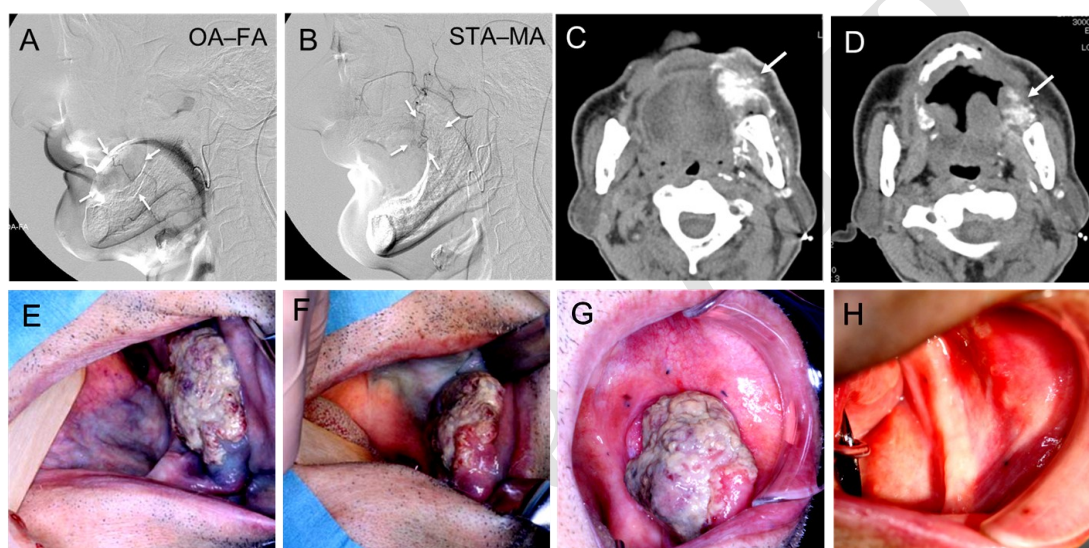


Figure 2. T3 carcinoma of the buccal mucosa. Two catheters are superselectively inserted into the left facial artery (FA) and left maxillary artery (MA). Digital subtraction angiograms show tumor stains are seen with the use of contrast medium (A, B: arrowheads). Angio-CT images show perfusion of the anterior of the tumor can be seen from FA (C: arrowhead), and that of the posterior of the tumor can be seen from MA (D: arrowhead). The blue staining of the anterior of the tumor, left buccal mucosa, left mandibular gingiva and left mouth floor is visible from FA (E), and that of posterior of the tumor, left maxillary gingiva and left hard palate is visible from MA (F). A nodular tumor is evident on the left buccal mucosa before treatment (G), with clinical complete response after treatment (H). Abbreviations FA facial artery; OA occipital artery; MA maxillary artery; STA superficial temporal artery.

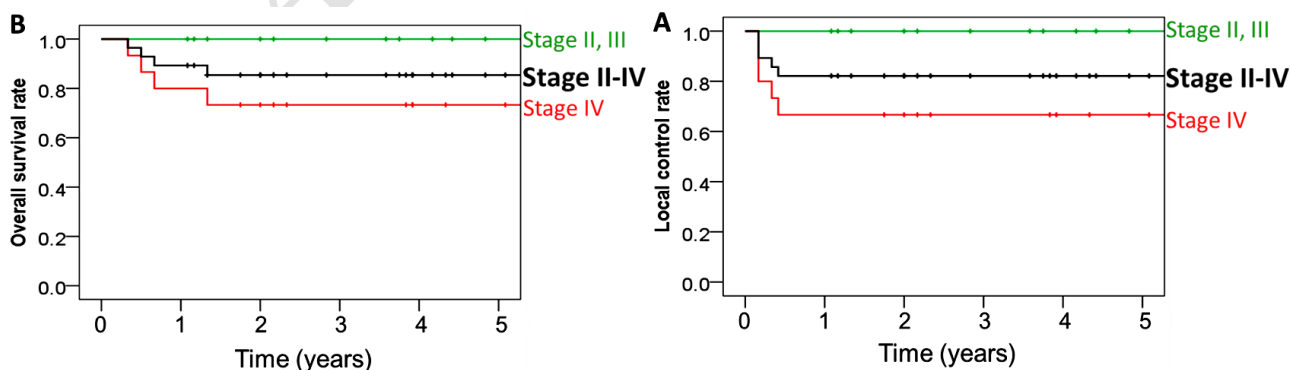


Figure 3. Local control (A) and overall survival (B). The 3-year LC rate of patients with carcinoma of the buccal mucosa is 82.1% (stage II, III: 100%, stage IV: 66.7%) (A). The 3-year OS rates is 85.4% (stage II, III; 100%, stage IV; 73.3%) (B). Abbreviations LC local control; OS overall survival.

Table 2. Early and late adverse events.

Toxicity	Grade, No (%)			
	1	2	3	4
<i>(Early)</i>				
Neutropenia	2 (7)	9 (32)	8 (29)	0
Anemia	8 (29)	12 (43)	3 (11)	0
Thrombocytopenia	2 (7)	3 (11)	0	0
Nausea	8 (29)	0	1 (4)	-
Oral mucositis	0	1 (4)	26 (92)	1 (4)
Radiation dermatitis	1 (4)	19 (68)	7 (25)	1 (4)
Dysphagia	0	10 (36)	18 (64)	0
Acute kidney injury	4 (14)	3 (11)	0	0
Fever	7 (25)	5 (18)	2 (7)	0
<i>(Late)</i>				
Osteonecrosis of the jaw	4 (14)	2 (7)	0	0
Dry mouth	13 (46)	6 (21)	0	0

National Cancer Institute Common Terminology Criteria for Adverse Events, version 4.0

Table 3. Univariate analysis of patients' characteristics and treatment factors.

Variables	Level	No. of patients	Local control			Overall survival		
			HR	95% CI	P value	HR	95% CI	P value
Sex	female	9	1		0.478	1		0.821
	male	19	1.361	0.581-3.192		0.813	0.134-4.919	
Age	<66	15	1		0.247	1		0.123
	≥66	13	3.819	0.395-36.927		5.633	0.627-50.598	
T classification	2 or 3	17	1		0.825	1		0.094
	≥4a	11	1.095	0.489-2.452		6.535	0.727-58.732	
N classification	(-)	17	1		0.214	1		0.919
	(+)	11	1.591	0.257-1.355		1.910	0.152-5.461	
Stage	II or III	11	1		0.562	1		0.142
	≥IVA	17	1.257	0.579-2.728		3.869	0.637-23.517	
Total dose of RT	≥60 Gy	23	1		0.104	1		0.018*
	<60 Gy	5	5.106	0.713-36.543		8.841	1.452-53.856	

Abbreviations * P < 0.05; HR hazard ratio; CI confidence interval; RT radiotherapy

Table 4. Multivariate analysis of prognostic factors based on Cox's proportional-hazards model.

(Overall survival)			
Selected factor	Level	P value	HR (95% CI)
T classification	2 or 3	0.291	1
	≥4a		6.942 (0.191-25.293)
Total dose of RT	≥60 Gy	0.035*	1
	<60 Gy		13.818 (1.203-58.718)

Abbreviations * P < 0.05; HR hazard ratio; CI confidence interval; RT radiotherapy

DISCUSSION

In the present trial of IACRT for patients with SCC of the buccal mucosa, LC and OS rates were excellent. Table 5 summarizes the treatment outcomes of SCC of the buccal mucosa in

previous studies. There were some studies that showed the efficacy and safety of definitive CRT or radiotherapy for patients with SCC of the buccal mucosa. Iqbal *et al.* (16) reported the survival outcomes with induction chemotherapy and hypofractionated radiation with concurrent

single agent CDDP chemotherapy for 63 patients (5 with stage III, 33 with stage IVA and 25 with stage IVB) with SCC of the buccal mucosa. CR of the primary site was achieved in 39 (61.9%) of 63 patients, and 19 (48.7%) patients relapsed. Five-year OS, disease-free survival, and progression-free survival rates were 30%, 49%, and 30%, respectively. For patients with locally advanced SCC of the buccal mucosa, it is difficult to control the primary tumor with conventional radiotherapy combined with systemic chemotherapy, and this results in a poor prognosis. On the other hand, superselective intra-arterial chemotherapy has the advantage of delivering a high concentration of the chemotherapeutic agents to the tumor, and daily concurrent CRT, that is IACRT, provided good local control (7-11).

In the Surveillance, Epidemiology, and End Results study in the United States of America, 5-year disease-specific survival and OS rates of 825 patients with stage I-IV SCC of the buccal

mucosa who underwent surgery or radiotherapy alone were 57.3% and 44.1%, respectively (2). Jan *et al.* reported survival rates and investigated relevant prognostic factors in 415 patients with SCC of the buccal mucosa in central Taiwan; of the 415 patients, 394 underwent surgery as their initial treatment. The 5-year OS rate of patients with stage I-IV SCC of the buccal mucosa was 71%; the 5-year OS rates for stage I, stage II, stage III, and stage IV were 88%, 79%, 69%, and 53%, respectively (17). A previous multicenter retrospective study including 7870 patients with stage I-IV SCC of the buccal mucosa in Taiwan who underwent surgery with or without adjuvant therapy reported that the 5-year DSS and OS rates were 78% and 71%, respectively (18). In this study, 3-year OS rate was 85.4% (stage II, III; 100%, stage IV; 73.3%). Although these treatment results are not comparable, our IACRT can preserve organs, and our treatment results are similar to or better than those of surgery.

Table 5. Summary of treatment outcome of squamous cell carcinoma of the buccal mucosa.

Author Year	No. cases	Stage (No. cases)	Treatment (No. cases)	LC	OS	DFS, PFS, DSS
Iqbal H ^[16] 2015	63	Stage III (7) Stage IVA (31) Stage IVB (25)	ICT+CRT		30% (5y)	DFS: 49% (5y) PFS: 30% (5y)
Camilon PR ^[2] 2014	825	Stage I (175) Stage II (136) Stage III (125) Stage IV (207) unknown (182)	OP(±CRT) RT		44% (5y)	DSS: 57% (5y)
Jan JC ^[17] 2011	415	Stage I (72) Stage II (138) Stage III (69) Stage IV (136)	OP (210) OP+CT/RT (184) CT/RT (7) CRT (14)		I: 88% (5y) II: 79% (5y) III: 69% (5y) IV: 53% (5y)	
Liao CT ^[18] 2017	7870	Stage I (2450) Stage II (1904) Stage III (1129) Stage IV (2387)	OP (4700) OP+CT (238) OP+RT (1112) OP+CRT (1820)		71% (5-y)	DSS: 78% (5y)
Koizumi T (present study)	28	Stage II (3) Stage III (8) Stage IV (17)	Intra-arterial CRT	82.1% (3y) II: 100% III: 100% IV: 67%	85.4% (3y) II: 100% III: 100% IV: 73%	

Abbreviations

LC local control; OS overall survival; DFS disease free survival; PFS progression free survival; DSS disease specific survival; OP operation; ICT induction chemotherapy; CRT chemoradiotherapy; RT radiotherapy; CT chemotherapy.

Many patients with head and neck cancer treated by radiotherapy present with dysphagia⁽¹⁹⁾, and some of the dysphagic patients develop aspiration pneumonia requiring treatment⁽²⁰⁾. Heulelom et al. reported that late toxicity of grade 3-4 esophageal toxicity, including dysphagia, was seen in 18% of patients treated with concomitant intra-arterial or intravenous CDDP-based CRT for advanced head and neck cancer⁽²¹⁾. In the present study, early toxicity of grade 3 dysphagia occurred in 18 cases (35.7%) with severe mucositis, but, dysphagia recovered in most cases. No severe renal disease developed, which is because of the low-dose CDDP infusion and neutralization of CDDP using sodium thiosulfate during treatment. In the present study, no patients died due to treatment toxicities during and after treatment.

CONCLUSION

Surgery has been the standard treatment for patients with advanced oral cancer including SCC of the buccal mucosa, and wide tumor excisions in patients with SCC of the buccal mucosa may lead to a significant sacrifice of facial skin and/or jaw bone, reducing oral function and quality of life. IACRT provided good LC and OS for patients with locally advanced SCC of the buccal mucosa. This treatment may become one of the treatment options for SCC of the buccal mucosa.

ACKNOWLEDGEMENT

This study was supported in part by JSPS KAKENHI Grant Number 16K11730.

Conflicts of interest: Declared none.

REFERENCES

1. Ariyoshi Y, Shimahara M, Omura K, Yamamoto E, Mizuki H, Chiba H, et al. (2008) Epidemiological study of malignant tumors in the oral and maxillofacial region: survey of

- member institutions of the Japanese Society of Oral and Maxillofacial Surgeons, 2002. *Int J Clin Oncol*, **13**: 220-8.
2. Camilon PR, Stokes WA, Fuller CW, Nguyen SA, Lentsch EJ (2014) Does buccal cancer have worse prognosis than other oral cavity cancers? *Laryngoscope*, **124**: 1386-91.
3. DeConde A, Miller ME, Palla B, Lai C, Elashoff D, Chhetri D, et al. (2012) Squamous cell carcinoma of buccal mucosa: a 40-year review. *American Journal of Otolaryngology*, **33**: 673-7.
4. Fang QG, Shi S, Li ZN, Zhang X, Liua FY, Xu ZF, et al. (2013) Squamous cell carcinoma of the buccal mucosa: Analysis of clinical presentation, outcome and prognostic factors. *Mol Clin Oncol*, **1**: 531-4.
5. Coppin C, de Wilde PC, Pop LA, van den Hoogen FJ, Merckx MA (2006) Treatment results of patients with a squamous cell carcinoma of the buccal mucosa. *Oral Oncol*, **42**: 795-9.
6. Diaz EM Jr, Holsinger FC, Zuniga ER, Roberts DB, Sorensen DM (2003) Squamous cell carcinoma of the buccal mucosa: one institution's experience with 119 previously untreated patients. *Head Neck*, **25**: 267-73.
7. Mitsudo K, Shigetomi T, Fujimoto Y, Nishiguchi H, Yamamoto N, Furue H, et al. (2011) Organ preservation with daily concurrent chemoradiotherapy using superselective intra-arterial infusion via a superficial temporal artery for T3 and T4 head and neck cancer. *Int J Radiat Oncol Biol Phys*, **79**: 1428-35.
8. Mitsudo K, Koizumi T, Iida M, Iwai T, Nakashima H, Oguri S, et al. (2014) Retrograde superselective intra-arterial chemotherapy and daily concurrent radiotherapy for stage III and IV oral cancer: analysis of therapeutic results in 112 cases. *Radiother Oncol*, **111**:306-10.
9. Minamiyama S, Mitsudo K, Hayashi Y, Iida M, Iwai T, Nakashima H, et al. (2017) Retrograde superselective intra-arterial chemotherapy and daily concurrent radiotherapy for T2-4N0 tongue cancer: control of occult neck metastasis. *Oral Surg Oral Med Oral Pathol Oral Radiol*, **124**:16-23.
10. Hayashi Y, Mitsudo K, Sakuma K, Iida M, Iwai T, Nakashima H, et al. (2017) Clinical outcomes of retrograde intra-arterial chemotherapy concurrent with radiotherapy for elderly oral squamous cell carcinoma patients aged over 80 years old. *Radiat Oncol*, **12**: 112.
11. Mitsudo K, Hayashi Y, Minamiyama S, Ohashi N, Iida M, Iwai T, et al. (2018) Chemoradiotherapy using retrograde superselective intra-arterial infusion for tongue cancer: analysis of therapeutic results in 118 cases. *Oral Oncol*, **79**: 71-77.
12. Sobin LH, Gospodarowicz MK, Wittekind C (2009) International union against cancer. TNM Classification of Malignant Tumors 7th ed. New York, NY: Wiley-Blackwell, 25-9.
13. Tohnai I, Fuwa N, Hayashi Y, Kaneko R, Tomarua Y, Hibino Y, et al. (1998) New superselective intra-arterial infusion via superficial temporal artery for cancer of the tongue and tumour tissue platinum concentration after carboplatin (CBDCA) infusion. *Oral Oncol*, **34**: 387-90.
14. Fuwa N, Ito Y, Matsumoto A, Kamata M, Kodaira T, Furutani K, et al. (2000) A combination therapy of continuous

- superselective intraarterial carboplatin infusion and radiation therapy for locally advanced head and neck carcinoma. Phase I study. *Cancer*, **89**: 2099-105.
15. Iwai T, Fuwa N, Hirota M, Mitsudo K, Tohnai I (2014) Secure surgical method for catheter placement via the occipital artery to achieve retrograde superselective intra-arterial chemotherapy for advanced oral cancer: Alternative to approach via the superficial temporal artery. *Indian J Otolaryngol Head Neck Surg*, **66**: 205-7.
 16. Iqbal H, Jamshed A, Bhatti AB, Hussain R, Jamshed S, Irfan M, *et al.* (2015) Five-year follow-up of concomitant accelerated hypofractionated radiation in advanced squamous cell carcinoma of the buccal mucosa: a retrospective cohort study. *Biomed Res Int*, 963574. doi: 10.1155/2015/963574.
 17. Jan JC, Hsu WH, Liu SA, Wong YK, Poon CK, Jiang RS, *et al.* (2011) Prognostic factors in patients with buccal squamous cell carcinoma: 10-Year Experience. *J Oral Maxillofac Surg*, **69**: 396-404.
 18. Liao CT, Wen YW, Yang LY, Lee SR, Ng SH, Liu TW, *et al.* (2017) Comparative clinical outcomes of Taiwanese patients with resected buccal and tongue squamous cell carcinomas. *Oral Oncol*, **67**: 95-102.
 19. Russi EG, Corvo R, Merlotti A, Alterio D, Franco P, Pergolizzi S, *et al.* (2012) Swallowing dysfunction in head and neck cancer patients treated by radiotherapy: Review and recommendations of the supportive task group of the Italian Association of Radiation Oncology. *Cancer Treat Rev*, **38** (8): 1033-49.
 20. Pikus L, Levine MS, Yang YX, Rubenstein SE, Katzka DA, Laufer I, *et al.* (2003) Videofluoroscopic studies of swallowing dysfunction and the relative risk of pneumonia. *Am J Roentgenol*, **180**(6): 1613-6.
 21. Heukelom J, Lopez-Yurda M, Balm AJ, Wijers OB, Buter J, Gregor, T, *et al.* (2016) Late follow-up of the randomized radiation and concomitant high-dose intra-arterial or intravenous cisplatin (RADPLAT) trial for advanced head and neck cancer. *Head Neck*, **38**: E488-E93.

Archive of SID