

Evaluation of the effects of dental filling material artifacts on IMRT treatment planning in patient with nasopharyngeal cancer

P. Saadatmand¹, A. Shanei^{1*}, A. Amouheidari², I. Abedi¹

¹Department of Medical Physics, School of Medicine, Isfahan University of Medical Sciences, Isfahan, Iran

²Radiation Oncology Department, Isfahan Milad General Hospital, Isfahan, Iran

ABSTRACT

Background: Presence of artifacts, caused by dental filling high-Z materials (DFM), on intensity-modulated radiation therapy (IMRT) treatment plan CT images may lead to uncertainty in head and neck calculated dose distributions. Hence, the purpose of this study was to investigate the effects of DFM on the IMRT calculated dose distribution and consequent radiobiological derived outcomes for nasopharyngeal cancer patients. **Materials and Methods:** IMRT optimization of two groups (15 patients in each) of nasopharyngeal cancer (NPC) patients with (group I) and without (group II) dental amalgam was performed by using the Prowess Panther treatment planning system (TPS). For all the patients, target prescribed dose was 70 Gy to planning target volume. We used 3 sets of treatment plans including; nine fields arrangement (F9E) and two plans of seven fields (namely: F7 and F7E) at different angles. The dose volume histograms (DVHs), monitor units (MUs), Homogeneity index (HI), conformity index (CI), Tumor control probability (TCP) and normal tissue complication probability (NTCP) of main organs at risk (OARs) were analyzed. **Results:** According to the results, the TCP of PTV70 due to presence of dental filling material was significantly decreased ($p=0.031$). On the other hand received dose by mandible, left cochlea, both eyes and right optic nerve were considerably different between patients with and without artifacts ($p<0.05$), whereas mandible showed the maximum differences (up to 315.65 cGy) compared to the other studied OARs. **Conclusion:** Results Presence of dental artifact in patients with nasopharyngeal carcinoma leads to uncertainty in calculated dose of IMRT treatment plans, especially for mandible as an OAR.

Keywords: Dental Filling Material, Treatment Planning, Intensity Modulated Radiation Therapy, Nasopharyngeal Carcinoma.

► Technical note

*Corresponding authors:

Dr. Ahmad Shanei,

E-mail: shanei@med.mui.ac.ir

Revised: December 2018

Accepted: January 2019

Int. J. Radiat. Res., July 2019;
17(3): 477-483

DOI: 10.18869/acadpub.ijrr.17.3.477

INTRODUCTION

The intensity-modulated radiation therapy (IMRT) is the main treatment modality, with a good efficiency and outcome, for nasopharyngeal cancer (NPC) patients (1, 2).

The presence of dental filling material (DFM) amalgams in patients with NPC leads to streaking artefacts on computed tomography (CT) images, that can perturb the dose distribution by obscuring the underlying

anatomy and causing changes in CT number of surrounding tissues (3, 4). Furthermore, the existence of DFM can lead to uncertainties in the contouring step during planning of a IMRT treatment (5).

One idea to decrease the effects of DFM on IMRT plans is to limit direction of the radiation field, not to directly pass through these high density materials (6, 7). However, this may significantly affect the outcome of the IMRT plan by giving poor results in terms of target

coverage and OAR sparing ⁽⁶⁾. On the other hand, using some methods for image metal artifact reduction such as employing different CT filters and/or image post-processing, may not fully eliminate this kind of artifacts ⁽⁸⁾. Moreover, many centers may not have access to Megavoltage CT (MVCT), which is an efficient method for such artifacts correction ⁽⁹⁾.

Regarding the effects of DFM on IMRT plans, Maerz *et al.* have predicted that, using a method for metal artifact reduction, can increase accuracy of IMRT dose calculation [10]. Kim *et al.* reported existence of hot and cold spots in organs at risk (OARs) and the target volumes (TVs) in presence of dental metal artifact in head and neck IMRT plans ^(11, 12).

This work aims to perform clinical evaluation of the effects of DFM artifacts on the IMRT calculated dose distributions and radiobiological derived outcomes.

According to the best of our knowledge, no study has been conducted to evaluate clinical effects of dental artifact on dose received by all the OARs in vicinity of nasopharynx for IMRT of nasopharyngeal cancer patients.

MATERIALS AND METHODS

Patient selection

Two groups of 15 patients with locally advanced nasopharyngeal cancer (NPC) (stages II to III tumors, according to the American Joint Committee on Cancer staging classification) admitted to the Milad Hospital, Isfahan, Iran between November 2017 and June 2018 were enrolled to this study. The First group was included patients with 3 to 7 filled teeth. Whereas, in the second group which was considered as control one, patients had no filled teeth. The median age of the patients was 41 years (range: 23 to 59 years).

Treatment planning

CT Simulation

The patients were immobilized with head and neck thermoplastic mask in the supine position for CT (Siemens 64-Slice) imaging and IMRT

simulation process. The calibration of the machine was performed by Prowess Company using a commercial phantom, (062 M Model, CIRS Inc., USA).

Target delineation and dose prescription

Organs' contouring was performed according to the International Commission on Radiation Units and Measurements (ICRU) reports 50, 62 and 83.

The CTV₇₀ was included GTV plus 5 mm margin and CTV_{59.4} was considered the CTV₇₀ plus a margin of 5mm for microscopic involvement. Levels of I-V nodal regions were defined according to the Radiation Therapy Oncology Group (RTOG) 0225 and 0615 protocols. The CTV₅₄ included the clinically negative low neck regions ^(13, 14). The planning target volume (PTV) was defined as the CTV, including a circumferential margin of 5 mm.

Dose prescriptions were 70 Gy at 2.12 Gy/fraction to the PTV₇₀, 59.4 Gy at 1.80 Gy/fraction to the PTV₇₀ and 54 Gy at 1.64 Gy/fraction to the PTV₅₄ delivered as simultaneous integrated boosts.

Treatment planning techniques

IMRT planning was performed using Prowess Panther TPS (version 5.50). 3 IMRT Plans including F7E, 7 fields with equally spaced gantry angles; F7 with 0°, 75°, 130°, 155°, 205°, 230° and 285° beam angles and F9E, 9 fields with equally spaced gantry angles were generated for 6 MV SIMENS-ARTISTE linear accelerator. The structural constraints that were employed during the IMRT optimization are illustrated in table 1 ^(14, 15).

Evaluations of the treatment plans

According to the ICRU83 report, the quality of each plan for two groups of patient was evaluated based on the cumulative and differential dose volume histogram (DVH) derived from IMRT dose distribution. The mean dose (D_{mean}), volume receiving 100% of the prescribed dose ($V_{100\%}$) was used to evaluate coverage of PTVs. Homogeneity index (HI) was also studied to evaluate the homogeneity of the

PTV. $HI = (D_{2\%} - D_{98\%}) / D_{50\%}$; [$D_{2\%}$, $D_{98\%}$ and $D_{50\%}$ were the doses received by 2%, 98% and 50% of the PTV volume]. Conformity index (CI) was considered to evaluate the fitness of the PTV to the prescription isodose volume in treatment plans. By using the formula; $CI = \frac{V_{PTV} \times V_{TV}}{TV_{PV}}$; where V_{TV} : treatment volume of prescribed isodose lines; V_{PTV} : volume of PTV; TV_{PV} : volume of V_{PTV} within V_{TV} , conformity index was calculated. The Maximal dose (D_{max}) or mean dose (D_{mean}) of OARs were also determined.

To derived tumor control probability (TCP) and normal tissue complication probability (NTCP), an equivalent uniform dose (EUD)-based TCP/NTCP formula⁽¹⁶⁾ (equations 1 and 2) derived by Gay and Niemierko⁽¹⁷⁾ was used.

$$TCP = \frac{1}{1 + \left(\frac{TCD_{50}}{EUD}\right)^{4\gamma_{50}}} \quad (1)$$

$$NTCP = \frac{1}{1 + \left(\frac{TD_{50}}{EUD}\right)^{4\gamma_{50}}} \quad (2)$$

Where, γ_{50} : a unitless model parameter for each organ; TCD_{50} : the tumor dose to control 50% of the Tumors; TD_{50} : the tolerance dose for a 50% complication rate when the whole organ of interest is homogeneously irradiated. The parameters for radiobiological evaluation are listed in table 2^(18, 19).

Statistical analysis

Data were analyzed using Paired sample t-test of SPSS statistical software (version 22) for comparing DVH and radiobiological parameters between the two studied groups. The $p < 0.05$ was considered statistically significant.

Table 1. Dose constraints to the OARs for IMRT planning in this study.

Structure	Dose(Gy)	Reference
Spinal cord*#	$D_{max} < 45$ Gy	(14, 15)
Brain stem*#	$D_{max} < 54$ Gy	(14, 15)
Chiasm and Optic nerves*#	$D_{max} < 54$ Gy	(14, 15)
Mandible and TMJs*#	$D_{max} < 70$ Gy	(14, 15)
Temporal lobes*	$D_{max} < 60$ Gy	(14)
Oral cavity (excluding PTV's)#	$D_{mean} < 40$ Gy	(14)
Parotid gland*#	single gland $D_{mean} < 26$ Gy	(14)
Eyes*#	$D_{mean} < 35$ Gy	(14)
	$D_{max} < 50$ Gy	(14)
Lens#	$D_{max} < 25$ Gy	(14)
	$D_{max} < 8$ Gy	(15)
Inner/middle ears*	$D_{mean} < 50$ Gy	

TMJs, temporomandibular joints; PTV, planning target volume; * RTOG protocol 0225; # RTOG protocol 0615

Table 2. Dosimetric and radiobiological comparison of target volume and OARs between two groups in three IMRT plan

Technique		F7		F7E		F9E	
Structure\endpoint (TCP or NTCP parameters)	parameter	Group I	Group II	Group I	Group II	Group I	Group II
PTV70 (-10, 2.28,51.77)	D _{mean} (cGy)	7344.45±67.97	7349.96±59.55	7349.85±57.67	7357.99±63.85	7302.31±66.96	7346.92±87.53
	V _{70Gy} (%)	97.01±2.39	97.77±2.36	97.05±2.84	98.25±1.77	97.16±2.36	98.36±1.58
	HI	0.08±0.01	0.09±0.08	0.08±0.01*	0.06±0.02*	0.08±0.04	0.07±0.03
	CI	1.91±0.72	1.76±0.36	1.88±0.52	2.02±0.52	1.61±0.23	1.79±0.21
PTV _{59.4}	D _{mean} (cGy)	6828.12±72.35	6806.42±78.19	6801.22±60.49	6887.82±236.43	6814.27±54.16	6828.82±60.33
	V _{59.4Gy} (%)	97.01±0.87	97.16±1.38	96.16±0.95	96.59±0.94	97.31±1.05	97.34±0.88
	HI	0.26±0.01	0.26±0.02	0.27±0.02	0.26±0.02	0.25±0.02	0.24±0.02
	CI	2.69±0.16	2.69±0.38	2.75±0.22	2.79±0.34	2.58±0.16	2.61±0.32
PTV ₅₄	D _{mean} (cGy)	5801.76±36.44	5827.59±57.05	5849.63±68.25	5871.73±46.86	5822.05±55.61	5850.87±49.00
	V _{54Gy} (%)	95.19±1.87	95.37±2.38	95.72±2.09	96.68±1.85	95.38±2.39	96.29±2.36
	HI	0.16±0.02	0.16±0.01	0.17±0.02	0.16±0.02	0.16±0.01	0.16±0.02
Spinal cord \myelitis (7, 3, 65)	D _{max} (cGy)	4015.39±302.46	4108.11±387.01	4231.71±288.41	4269.20±326.32	4231.71±288.41	4269.20±326.32
	NTCP (%)	0.00±0.00	0.00±0.00	0.00±0.00	0.00±0.00	0.00±0.00	0.00±0.00
Brain stem \necrosis (7, 3, 65)	D _{max} (cGy)	5311.87±374.68	5177.44±343.36	5271.82±394.68	5244.71±347.84	5174.30±367.05	5088.03±398.58
	NTCP (%)	0.17±0.10	0.17±0.12	0.14±0.09	0.14±0.11	0.17±0.09	0.14±0.13
Left parotid \xerostomia (1, 2.2, 24.8)	D _{mean} (cGy)	2319.45±222.97	2304.05±288.15	2407.89±267.05	2291.63±311.31	2356.26±263.18	2278.08±317.96
	NTCP (%)	14.54±10.90	16.14±12.31	21.92±13.19	17.51±10.34	19.20±10.34	16.57±11.59
Right parotid \xerostomia (1, 2.2, 24.8)	D _{mean} (cGy)	2285.25±282.95	2144.98±322.47	2415.27±194.53	2265.15±235.64	2429.61±188.90	2360.93±236.64
	NTCP (%)	13.79±11.31	11.26±8.18	21.14±10.28	14.05±9.18	18.54±11.31	14.66±10.30
Left optic nerve \blindness (25, 3, 65)	D _{max} (cGy)	783.52±1094.13	586.21±519.95	913.76±1403.09	582.36±474.14	785.88±1140.91	612.81±496.67
	NTCP (%)	0.00±0.00	0.00±0.00	0.01±0.03†	0.00±0.00†	0.00±0.00	0.00±0.00
Right optic nerve \blindness (25, 3, 65)	D _{max} (cGy)	792.71±4057.22	724.60±619.21	918.61±1303.79	670.11±494.33	974.52±1203.34	686.11±473.41
	NTCP (%)	0.00±0.01	0.00±0.00	0.01±0.05‡	0.00±0.00‡	0.00±0.00	0.00±0.00
Chiasm \blindness (4, 3, 65)	D _{max} (cGy)	1133.05±973.27	1163.08±819.45	1183.75±1046.05	1307.09±794.18	1224.02±1142.96	1396.82±947.06
	NTCP (%)	0.00±0.00	0.00±0.00	0.00±0.00	0.00±0.00	0.00±0.00	0.00±0.00
Left eye \blindness (5, 2, 65)	D _{max} (cGy)	532.60±610.30 ^{††}	761.31±673.14 ^{††}	602.02±761.00	606.65±585.71	532.82±555.65	669.62±672.88
	NTCP (%)	0.00±0.00	0.00±0.00	0.00±0.00	0.00±0.00	0.00±0.00	0.00±0.00
Right eye \blindness (5, 2, 65)	D _{max} (cGy)	591.81±645.48 [#]	850.01±704.75 [#]	602.90±724.49	683.75±937.96	555.31±819.48 ^{##}	824.36±605.62 ^{##}
	NTCP (%)	0.00±0.00	0.00±0.00	0.00±0.00	0.00±0.00	0.00±0.00	0.00±0.00
Left Lens \cataract (3, 1, 18)	D _{max} (cGy)	258.78±223.15	304.98±352.24	281.96±378.80	233.17±246.93	231.45±220.68	281.91±407.97
	NTCP (%)	0.16±0.39	0.01±0.02	0.09±0.31	0.05±0.00	0.16±0.56	0.01±0.00
Right lens \cataract (3, 1, 18)	D _{max} (cGy)	256.56±244.24	323.72±371.07	271.13±361.52	316.12±511.46	302.92±455.10	288.82±344.21
	NTCP (%)	0.03±0.07	0.02±0.04	0.03±0.08	0.01±0.01	0.02±0.06	0.01±0.02
Mandible \osteoradi- onecrosis (14, 4, 72)	D _{max} (cGy)	6696.51±311.28 ^{*†}	6380.86±323.41 ^{*†}	6627.66±275.01 ^{§§}	6358.60±329.00 ^{§§}	6684.07±237.26 ^{‡‡}	6405.03±263.13 ^{‡‡}
	NTCP (%)	0.58±0.45 ^{#‡}	0.27±0.26 ^{#‡}	0.71±0.35 ^{*‡}	0.31±0.28 ^{*‡}	0.66±0.48 ^{†††}	0.29±0.31 ^{†††}
TMJ-L	D _{max} (cGy)	4128.96±679.69	4317.41±942.44	4143.26±925.05	4445.63±1045.99	3928.35±1167.37	4395.35±862.68
TMJ-R	D _{max} (cGy)	4521.28±64.17	4688.47±831.38	4785.54±831.37	4651.54±1079.83	4209.53±884.46	4474.47±698.48
Cochlea-L	D _{max} (cGy)	4092.36±495.36	4245.71±460.18	3954.34±533.59	4191.38±536.61	3954.26±463.93 [∅]	4337.40±387.23 [∅]
	D _{mean} (cGy)	3229.22±961.29	3673.72±475.34	3266.26±494.67	3437.62±407.32	3280.66±469.10	3603.06±378.47
Cochlea-R	D _{max} (cGy)	4188.91±505.19	4308.03±571.94	3905.94±554.57	4117.98±620.15	4107.55±535.18	4075.65±675.71
	D _{mean} (cGy)	3667.39±474.66	3714.92±481.87	2989.62±965.32	3297.80±451.43	3500.00±566.87	3300.51±846.06
Oral cavity\late muco- sal necrosis(10, 2, 68)	D _{mean} (cGy)	3588.69±417.51	3624.5881±250.97	3742.01±403.29	3760.32±322.56	3582.72±377.43	3678.76±306.89
	NTCP (%)	2.14±1.17	2.29±1.01	2.81±1.60	2.54±0.73	2.11±1.26	2.15±1.05

F7: 7 IMRT fields with 0, 75, 130, 155, 205, 230, 285 angles; F7E: 7 IMRT fields with 50° equally spaced gantry angles; F9: 9 fields IMRT with 40° equally spaced gantry angles; Group I, included patients with DFM; Group II included patients without DFM; TCP, Tumor control probability (%); NTCP, normal tissue complication probability (%);TCP and NTCP parameters used are listed in parentheses: (a, v50, TD50), Paired t-test with a P value<0.05 regarded to be statistically significant. *, **, †, ††, †††, ††, ‡, ‡‡, #, ##, #‡ and ∅, indicated P value <0.05 between two group of patients.

RESULTS

Comparison of the dose distribution and radiobiological parameters

Typical dose distributions and DVH produced by one of the used 3 techniques are shown in figure 1. Dosimetric and radiobiological comparison of target volume and sparing OARs between the two groups for the used IMRT plans are presented in table 2.

As shown in table 2, the mean dose and $V_{100\%}$ of all PTVs showed no statistical significant difference between the two studied groups ($p>0.05$). While, patients with DFM showed significantly less homogeneity (up to 33.33%) for PTV_{70} in F7E technique (p value = 0.044). The presences of artifact in the F9 technique lead to a statically significant decrease (up to 0.36%) in TCP of PTV_{70} .

The planning objective mentioned for OARs in table 1 was met by all the planning

techniques. As shown in table 2, dosimetric and radiobiological comparison of spinal cord, brainstem, parotid glands, oral cavity, TM joints, lens, chiasm and right cochlea showed no significant difference between two groups when all IMRT techniques were compared ($p>0.05$). The presences of DFM lead to a statically significant decrease in maximum dose of both eyes in the F7 and F9 IMRT techniques and also decrease in maximum dose of left cochlea in F9 technique.

As shown in table 2, using F7E technique, the presences of DFM resulted in a statically significant increase in NTCP of both optic nerves ($p<0.05$). Furthermore, the patients with DFM showed a significant increase in NTCP of the mandible (up to 0.40%) for all the used techniques. These differences were not clinically significant ($p>0.05$). Among all OARs, parotid gland showed maximum increase in NTCP due to DFM (up to 7.09%).

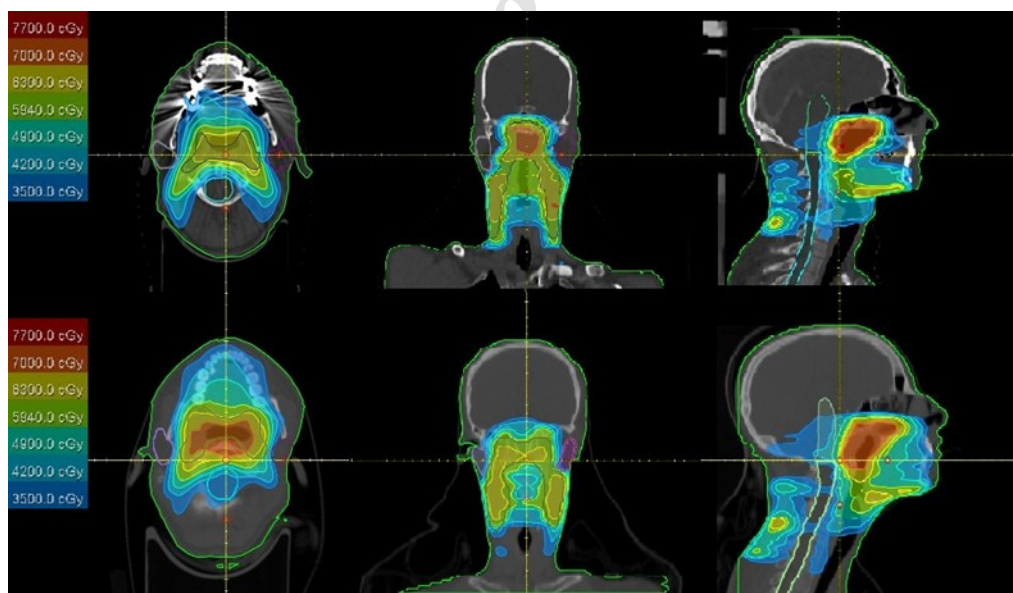


Figure 1. Differences in dose distributions for 9 fields IMRT plans on representative axial, sagittal, and coronal images from the planning CT scan for one NPC patient with dental filling material (upper panel) and a patient without dental filling material (lower panel).

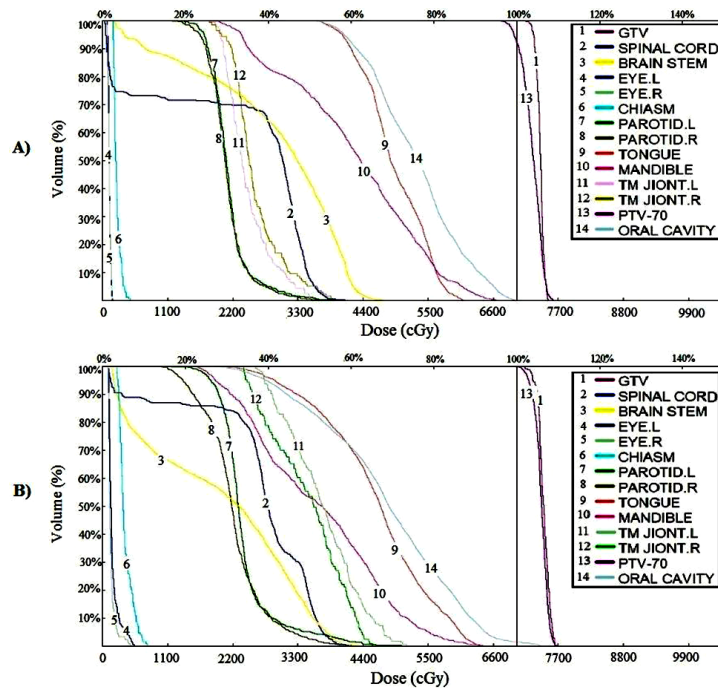


Figure 2. Differences in DVH for 7E fields IMRT plans on one representative case with DFM (A) and without DFM (B).

DISCUSSION

In our study, it was observed that presence of 3 to 7 filled teeth with amalgam, can significantly affect calculated dose distribution of IMRT treatment plan for NPC patients.

Kim *et al.* (11,12) predicted under coverage of CTV (for up to 0.8 Gy), hotspot dose of less than 0.3 Gy in both parotids, 0.6% decrease in TCP of CTV and 1.1% and 0.1% increase in NTCP of parotid gland and spinal cord respectively by means of reasonable metal-artifacts-correction when result compared to an image data set that more closely approximated the patient anatomy without any dental metal artifacts. In our study, we found that differences were mainly depended on IMRT field angles. Moreover, maximum 0.44 Gy decrease of mean dose and 0.36% change of TCP of PTV₇₀ for F9 technique, maximum increase of 1.16 Gy and 1.50 Gy for left and right parotid gland, respectively, for F7E technique and up to 6.68% increase of parotid NTCP in our study showed that metal artifact correction predicted by Kim seems inadequate.

Also Webster *et al.* (7) have found all discrepancies by means of extended CT/density

look-up table together with a simple manual bulk density correction on IMRT planning for the head and neck within the target volume were <1 Gy and those in OARs (spinal cord, parotid glands and brain stem), whilst occasionally approaching 2 Gy for the brainstem that compatible with our study for F9 technique but for other techniques discrepancies of parotid glands exceed 1 Gy.

Also discrepancies of chiasm, mandible, both TMJs and cochlea for some technique exceed 1 Gy, that these organs not mentioned by Webster.

The result of this study can be used to take practical steps to minimize clinical concerns due to presence of DFM artifact on IMRT treatment plan for NPC patients.

CONCLUSION

Presence of dental artifact in patients with nasopharyngeal carcinoma leads to inaccuracy of image CT numbers and adversely affects the counteracting and dose calculation steps of an IMRT treatment plan.

ACKNOWLEDGEMENT

This report is based on a research project (# 396891), supported by the Department of Research and Technology of Isfahan University of Medical Sciences, Isfahan, Iran. The authors wish to acknowledge the staff of Milad Hospital for Support and assistance in this study.

Ethical Statement

The study is retrospective and does not involve the treatment of patients, it did not violate ethics. A written consent form was signed.

Conflicts of interest: Declared none.

REFERENCES

- Zhang L, Chen Q-Y, Liu H, Tang L-Q, Mai H-Q (2013) Emerging treatment options for nasopharyngeal carcinoma. Drug design, development and therapy, 7: p. 37.
- Kamomae T, Itoh Y, Okudaira K, Nakaya T, Tomida M, Miyake Y, et al (2016) Dosimetric impact of dental metallic crown on intensity-modulated radiotherapy and volumetric-modulated arc therapy for head and neck cancer. Journal of applied clinical medical physics, 17(1): p. 234-245.
- Richard P, Sandison G, Dang Q, Johnson B, Wong T, Parvathaneni U (2015) Dental amalgam artifact: Adverse impact on tumor visualization and proton beam treatment planning in oral and oropharyngeal cancers. Practical radiation oncology, 5(6): e583-e588.
- Shimamoto H, Sumida I, Kakimoto N, Marutani K, Okahata R, Usami A, et al. (2015) Evaluation of the scatter doses in the direction of the buccal mucosa from dental metals. Journal of applied clinical medical physics, 16(3): p. 233-243.
- Mail N, Albarakati Y, Ahmad Khan M, Saeedi F, Safadi N, Al-Ghamdi S, et al. (2013) The impacts of dental filling materials on RapidArc treatment planning and dose delivery: challenges and solution. Medical physics, 40(8).
- Asena A (2017) Dosimetry in the vicinity of high-density materials in radiotherapy. Queensland University of Technology.
- Webster GJ, Rowbottom CG, Mackay RI (2009) Evaluation of the impact of dental artefacts on intensity-modulated radiotherapy planning for the head and neck. Radiotherapy and Oncology, 93(3): p. 553-558.
- De Crop A, Casselman J, Van Hoof T, Dierens M, Vereecke E, Bossu N, et al. (2015) Analysis of metal artifact reduction tools for dental hardware in CT scans of the oral cavity: kVp, iterative reconstruction, dual-energy CT, metal artifact reduction software: does it make a difference? Neuroradiology, 57(8): p. 841-849.
- Schreiner LJ, Rogers M, Salomons G, Kerr A, editors. (2005) Metal artifact suppression in megavoltage computed tomography. in Medical Imaging 2005: Physics of Medical Imaging. International Society for Optics and Photonics, 637-645.
- Maerz M, Koelbl O, Dobler B, (2015) Influence of metallic dental implants and metal artefacts on dose calculation accuracy. Strahlentherapie und Onkologie, 191(3): p. 234-241.
- Kim Y, Tomé WA, Bal M, McNutt TR, Spies L (2006) The impact of dental metal artifacts on head and neck IMRT dose distributions. Radiotherapy and oncology, 79(2): p. 198-202.
- Kim Y and Tomé WA (2007) On the radiobiological impact of metal artifacts in head-and-neck IMRT in terms of tumor control probability (TCP) and normal tissue complication probability (NTCP). Medical & biological engineering & computing, 45(11): 1045-1051.
- Lee AW, Ng WT, Pan JJ, Poh SS, Ahn YC, AlHussain H, et al. (CTV) for nasopharyngeal carcinoma. Radiotherapy and Oncology, 25-36.
- Halperin EC, Brady LW, Perez CA, Wazer DE (2013) Perez & Brady's principles and practice of radiation oncology. Lippincott Williams & Wilkins.
- Chen BB, et al. at least 3-4 co-authors must be mentioned (2018) Prospective matched study on comparison of volumetric-modulated arc therapy and intensity-modulated radiotherapy for nasopharyngeal carcinoma: dosimetry, delivery efficiency and outcomes. Journal of Cancer, 9(6): p. 978.
- Sanchez-Nieto B and Nahum A (1999) The delta-TCP concept: a clinically useful measure of tumor control probability. Int J Radiat Oncol Biol Phys, 44(2): p. 369-380.
- Gay HA and Niemierko A (2007) A free program for calculating EUD-based NTCP and TCP in external beam radiotherapy. Physica Medica, 23(3-4): 115-125.
- Lee T-F, Ting H-M, Chao P-J, Fang F-M (2012) Dual arc volumetric-modulated arc radiotherapy (VMAT) of nasopharyngeal carcinomas: a simultaneous integrated boost treatment plan comparison with intensity-modulated radiotherapies and single arc VMAT. Clinical Oncology, 24 (3): 196-207.
- Emami B, Lyman J, Brown A, Cola L, Goitein M, Munzenrider J, et al. (1991) Tolerance of normal tissue to therapeutic irradiation. Int J Radiat Oncol Biol Phys, 21(1): p. 109-122.

Archive of SID