

Study of the Protective Effect of *Teucrium polium* L. Extract on Acetaminophen-Induced Hepatotoxicity in Mice

Hossein Forouzandeh^a, Mohammad Ebrahim Azemi^b, Iran Rashidi^c,
Mehdi Goudarzi^a and Heibatullah Kalantari^{d*}

^aSchool of Pharmacy, Department of Pharmacology and Toxicology, Ahvaz Jundishapur University of Medical Sciences, Ahvaz, Iran. ^bSchool of Pharmacy, Department of Pharmacognosy and Medicinal plants Research Center, Ahvaz Jundishapur University of Medical Sciences, Ahvaz, Iran. ^cDepartment of Pathology, School of Medicine, Ahvaz Jundishapur University of Medical Sciences, Ahvaz, Iran. ^dSchool of Pharmacy, Department of Pharmacology and Toxicology, Toxicology Research Center and Medicinal plants Research Center, Ahvaz Jundishapur University of Medical Sciences, Ahvaz, Iran.

Abstract

In the present study, protective effect of *Teucrium polium* L. (Labiatae) extract on acetaminophen-induced hepatotoxicity was investigated in mice. Animals were divided into six groups, each group consist of 8 mice. Group one as the negative control group received normal saline, while group two received only crude extract of *T. polium* L. (500 mg/Kg) for five days and group three as the positive group received acetaminophen (500 mg/Kg). Groups four, five and six received crude extract in doses of 125, 250 and 500 mg/Kg, respectively, and on the fifth day, one hour after the last administration, acetaminophen was given orally (500 mg/Kg). Then on the 6th day, animals were sacrificed, their blood was collected to determine serum enzyme activities of ALT, AST and ALP to measure the serum levels of directed and total bilirubin. The livers were removed for histological examination. The results of this study showed the protective effect in all doses but the most significant protection was observed in doses of 250 and 500 mg/Kg ($p < 0.05$). Also these findings were supported and confirmed by histological examination.

Keywords: Hepatotoxicity; Acetaminophen; *Teucrium polium* L.; Protective.

Introduction

It is well known that medicinal plants play an important role in health care system and can be called as a main source of new chemical substances with potential therapeutic effects (1). In recent years, there has been a shift towards therapeutic evaluation of herbal products in liver diseases (2). The genus *Teucrium* L. (Labiatae) is

very diverse and contains more than 300 species mainly found in the Mediterranean region (3). *Teucrium polium* L. is a wild-growing flowering plant, which belongs to Labiatae family (4). This plant has been used in folk medicine for various purposes such as anti-inflammatory, anti-bacterial, anti-pyretic, anti-spasmodic, anti-hypertensive and anti-hyperlipedemic (5, 6). Furthermore, the plant possesses hypoglycemic, insulinotropic, diuretic, diaphoretic, tonic, cholagogic and antioxidant properties (8-11). Acetaminophen is a widely used nonprescription

* Corresponding author:

E-mail: kalantarih@yahoo.com

analgesic and antipyretic drug that has a very low rate of liver toxicity at normal therapeutic doses, however, it causes hepatic and renal injuries in humans and experimental animals when administered in high doses (12-14). Liver, as a major vital organ, metabolizes acetaminophen in the form of glucuronidated and sulfated product and the subsequent metabolite is excreted by urine (15), but small fraction metabolized by cytochrome P₄₅₀ to a highly reactive free radical, *n*-acetyl-*p*-benzoquinone imine (NAPQI) (16). This metabolite is a strong electrophile oxidizing agent normally detoxified by reduced glutathione (GSH) in the liver (17). However, after acetaminophen overdose, the glucuronidation and sulfation pathways become saturated, and more acetaminophen becomes available for activation by the cytochrome P₄₅₀, which produces a large amount of NAPQI leading to rapid depletion of hepatic GSH levels. Subsequently, NAPQI metabolite binds covalently to cell macromolecules that results in cell damage or cell death (18, 19). The aim of this study was to evaluate the hepatoprotective activities of hydro alcoholic extract of *T. polium* on acetaminophen-induced hepatotoxicity.

Experimental

Animals

Studies were carried out using male ICR mice (6-8 weeks old, 25-30 g), obtained from Animal house of Ahvaz Jundishapur University of Medical Science, Iran. Mice were kept in polycarbonate cages under standard condition (temperature 25 ± 2°C) with 12 h light/dark cycle. They were provided with standard pellet diet and free access to drinking water *ad libitum*. The animals were acclimatized to the environment for a week before the commencement of experiment. The investigation was performed according to the Local Animal Ethics Committee guidelines for the use of experimental animals.

Chemicals

All the chemicals were of analytical grade. Solvents were purchased from Merck (Darmstadt, Germany). The acetaminophen powder was purchased from Darou pakhsh Company (Iran).

Preparation of plant extract

Plant was collected from Larestan region, Iran in April 2008 and shade-dried. The plants were identified at the Herbarium of Department of Pharmacognosy, School of Pharmacy, Ahvaz, Iran, where the voucher specimens were preserved (number voucher: T-0157). The whole plant was crushed into small pieces and soaked in an 80% aqueous-ethanol solution in a large container for 3 days with occasional shaking. The extract was filtered through a clean cotton cloth and the filtrate was dried by using a rotary evaporator at 40°C. The extract yield was 16% w/w (19).

Study design

Plant extract was dissolved in normal saline before the administration to mice. Acetaminophen was first dissolved in normal saline at 70°C, and then cooled to 37°C for administration; it was administered orally in a single dose of 500 mg/Kg. Mice were divided randomly into six groups, each of which consisted of eight animals. All mice were treated orally for five consecutive days. Group one as the negative control group received normal saline (10 mL/Kg), while group two received only crude extract of *T. polium* L. (500 mg/Kg) for five days and group three as the positive group received acetaminophen (500 mg/Kg) on the fifth day. Groups four, five and six received crude extract during five days in doses of 125, 250 and 500 mg/Kg, respectively and on the fifth day, acetaminophen was administered (500 mg/Kg) one hour after the last administration of the crude extract. Then, on the 6th day, animals were sacrificed and their blood was collected to estimate ALT, AST and ALP, direct and total bilirubin. Liver was removed and kept in 10% formalin solution for histopathological examination.

Biochemical assays

The blood samples were allowed to clot for 40 min at room temperature. Serum was separated by centrifugation at 2500 rpm at 30°C for 15 min. Activities of aspartate aminotransferase (AST) and alanine aminotransferase (ALT) in serum were determined employing the method of Reitman and Frankel. In this procedure, transaminase reacts with 2, 4-dinitrophenylhydrazones reagent and produces color complex that is proportional to the AST and ALT

Table 1. Effects of the pretreatment with *Teucrium polium* L. extract on the serum activities of AST, ALT and ALP in acetaminophen-induced hepatotoxicity.

Groups	AST (U/L)	ALT (U/L)	ALP (U/L)
1. normal saline	73.87 ± 20.08 ^b	63.25 ± 8.92 ^b	88.62 ± 10.79 ^b
2. <i>T. polium</i> (500 mg/Kg)	81.75 ± 21.75 ^b	61.62 ± 8.65 ^b	95.62 ± 13.98 ^b
3. Acetaminophen (500 mg/Kg)	848.50 ± 38.26 ^a	683.50 ± 42.63 ^a	171.62 ± 16.87 ^a
4. <i>T. polium</i> 125 mg/Kg + Acetaminophen	702.12 ± 24.58 ^{a,b}	547.00 ± 41.70 ^{a,b}	128.50 ± 15.08 ^{a,b}
5. <i>T. polium</i> 250 mg/Kg + Acetaminophen	406.00 ± 20.52 ^{a,b}	338.75 ± 45.24 ^{a,b}	101.00 ± 16.97 ^b
6. <i>T. polium</i> 500 mg/Kg + Acetaminophen	441.50 ± 112.68 ^{a,b}	354.00 ± 43.98 ^{a,b}	96.50 ± 12.85 ^b

Mice in group 1 received normal saline solution, while group 2 received *T. polium* L. extract (500 mg/Kg) for 5 days, group 3 received acetaminophen on the fifth day. The mice in groups 4, 5 and 6 were pretreated with *T. polium* L. extract (125, 250 and 500 mg/Kg, p.o, respectively) once daily for five consecutive days. One hour after the final treatment, the mice were treated with acetaminophen (500 mg/Kg, p.o). Hepatotoxicity was determined 24 h later by quantifying the serum activities of alanine aminotransferase (ALT) and aspartate aminotransferase (AST) as well as alkaline phosphatase (ALP). Each value represents the mean ± SD for eight mice. ^a: Significantly different from the control at $p < 0.05$. ^b: Significantly different from acetaminophen at $p < 0.05$.

concentrations (21). Alkaline phosphatase (ALP) was estimated according to king (22), while serum levels of direct and total bilirubin were determined according to the method of Watson and Rogers. In this method, the conventional diazo reagent was added to plasma, and then the color densities were determined (23).

Histopathological assessments

The liver specimens were fixed in 10% neutral buffered-formalin and then, Liver tissues were dehydrated with a sequence of ethanol solutions, embedded in paraffin, cut into 5 µm sections, stained with hematoxylin and eosin dye (H and E stain) and observed under a photomicroscope (24). The observed morphological changes included cell necrosis, fatty change and the

infiltration of lymphocytes and Kupffer cells.

Statistical analysis

Statistical analysis was performed using the statistical package SPSS 16.0 for Windows. The results were expressed as mean ± SD. One-way ANOVA followed by Tukey post-test were applied for statistical analysis with the level of significance set at $p < 0.05$.

Results

It is clear that an increase in serum levels of AST, ALT, ALP and bilirubin concentrations in blood indirectly reflects the failure of liver function due to the acetaminophen-induced hepatotoxicity. The effects of pre-treatment with different doses of *T. polium* extract

Table 2. Effects of the pretreatment with *Teucrium polium* L. extract on the serum levels of direct and total bilirubin in acetaminophen-induced hepatotoxicity.

Groups	Direct bilirubin	Total bilirubin
1. normal saline	.3100 ± .06437	.4925 ± .12361
2. <i>T. polium</i> (500 mg/Kg)	.3438 ± .08450	.5112 ± .14025
3. Acetaminophen (500 mg/Kg)	.4225 ± .08940	.6075 ± .18211
4. <i>T. polium</i> 125 mg/Kg + Acetaminophen	.4488 ± .09658	.5762 ± .13511
5. <i>T. polium</i> 250 mg/Kg + Acetaminophen	.3900 ± .10981	.5925 ± .15360
6. <i>T. polium</i> 500 mg/Kg + Acetaminophen	.3712 ± .11319	.5412 ± .15797

Animals in group 1 received normal saline solution, whereas animals in group 2 received *T. polium* L. extract (500 mg/Kg) for 5 days. Group 3 received acetaminophen on the fifth day. The mice in groups 4, 5 and 6 were pretreated with *T. polium* L. extract (125, 250 and 500 mg/Kg, po, respectively) once daily for five consecutive days. One hour after the final treatment, the mice were treated with acetaminophen (500 mg/Kg, po).

Each value represents the mean ± SD for eight mice. ^a: Significantly different from the control ($p < 0.05$). ^b: Significantly different from acetaminophen group ($p < 0.05$).

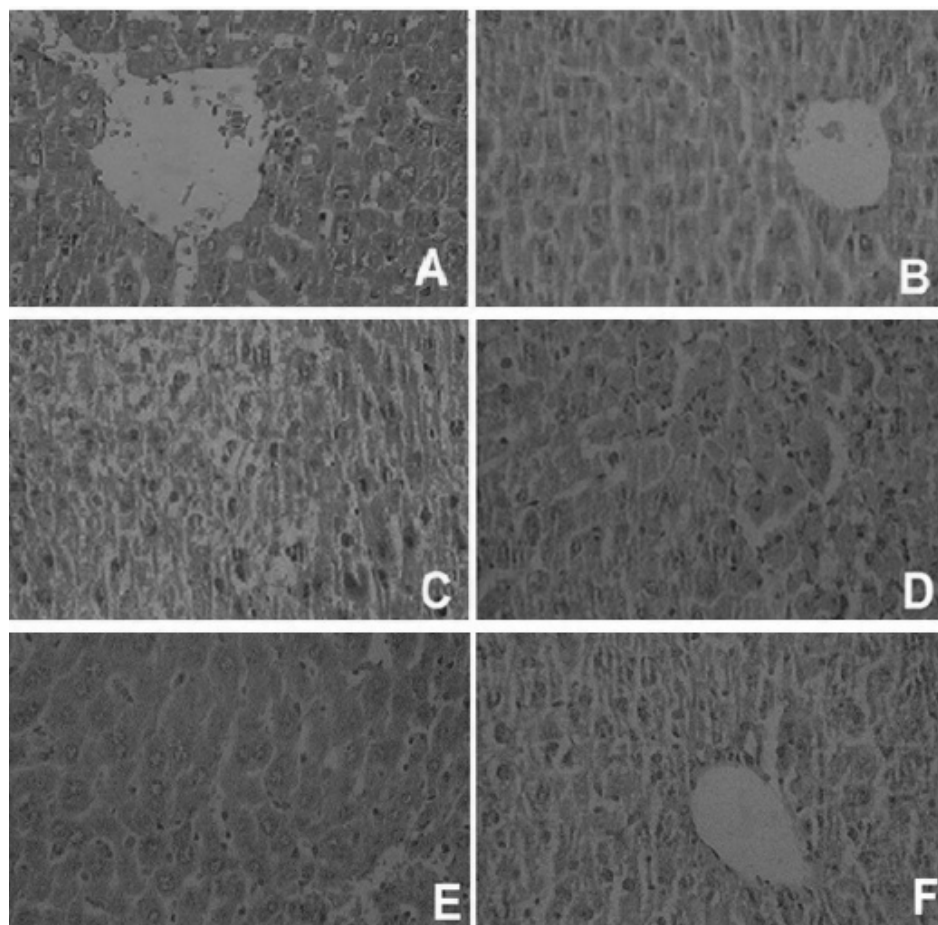


Figure 1. Histopathological observations (liver sections stained with Hematoxylin and Eosin, magnification x 100) showing the effects of *Teucrium polium* extract on acetaminophen-induced histopathological changes in mouse liver. (A) Normal, (B) *T. polium L.* extract (500 mg/Kg) shows normal hepatic architecture with distinct hepatic cells, sinusoidal spaces and a central vein; (C) acetaminophen-treated group shows severe centrilobular hepatic necrosis, fatty changes, ballooning degeneration, and infiltrating lymphocytes; (D), (E) and (F) are acetaminophen groups pre-treated with 125, 250 and 500 mg/Kg of *T. polium L* extract, respectively. D shows milder degree of hepatocyte necrosis, fatty changes, ballooning degeneration, and infiltrating lymphocytes. In pictures E and F, only mild inflammation and lymphocyte infiltration are observed.

(125, 250 and 500 mg/Kg) on serum levels of liver enzymes and bilirubin in acetaminophen-induced hepatotoxicity are shown in Tables 1 and 2.

Data showed that 24 h after the acetaminophen administration mice developed significant hepatocellular damage as it was evident from a significant increase in the serum activities of ALT, AST and ALP ($p < 0.05$) when compared with the negative control group (Table 1). The positive control group showed slightly (not significant) increase in serum direct and total bilirubin concentration, as shown in Table 2. Pretreatment of mice with 125, 250 and 500 mg/Kg of hydroalcoholic extracts of *T. polium* exhibited a significant ($p < 0.05$) reduction in

the levels of AST, ALT and ALP as compared with the positive control group (Table 1). Direct and total bilirubin concentration, elevated by acetaminophen, exhibited a slight decrease in response to the pre-treatment with the plant extract (Table 2). The histopathological study of liver in the negative control group and the second group with only crude extract showed a normal hepatic architecture with distinct hepatic cells, sinusoidal spaces and a central vein (Figures 1A and 1B).

Acetaminophen-intoxicated group exhibited severe histopathological changes, such as centrilobular hepatic necrosis, fatty changes, ballooning degeneration, and infiltrating lymphocytes (Figure 1C). The group that

received 125 mg/Kg of *T. polium* extract showed partial protection of hepatocytes (Figure 1D), while pretreatment with doses of 250 and 500 mg/Kg of hydro alcoholic extract showed best results and prevented these histopathological changes associated with the hepatotoxicity induced by acetaminophen. Results of groups that received 250 mg/Kg and 500 mg/Kg of the extract of *T. polium* are shown in Figure 1E and Figure 1F.

Discussion

Liver is one of the largest organs in human body and the major site for metabolism and excretion (25). It has a wide range of functions, including detoxification, protein synthesis, and production of biochemical's necessary for digestion (26). Liver diseases have become one of the major causes of morbidity and mortality in human all over the world and hepatotoxicity due to drugs appears to be the most common contributing factor (27). Protection against acetaminophen induced toxicity has been used as a test for a potential hepatoprotective agent by several investigators (28-31).

Acetaminophen, as an analgesic and antipyretic drug, is readily available without prescription. In therapeutic doses, acetaminophen is well tolerated; side effects and interaction with other drugs are usually not observed. However, overdose of acetaminophen causes acute centrilobular hepatic necrosis in humans and experimental animals (32, 33). The rise in serum levels of transaminases (AST and ALT) and ALP have been attributed to the damaged structural integrity of the liver, because these are normally located in the cytoplasm and are released into the circulation after cellular damage (34). The elevation in the levels of bilirubin has been reported in acetaminophen-induced hepatotoxicity. Bilirubin, an endogenous organic anion binds reversibly to albumin and it is transported to the liver, and then conjugated with glucuronic acid and excreted in the bile. In hepatobiliary disease, bilirubin concentration exceeds the upper limits of normal (35, 36). Since hepatic damage induced by acetaminophen is mediated by its free radical metabolites (16-18), antioxidant

activity or inhibition of the generation of free radicals is important in the protection against acetaminophen-induced liver injury (37). It has been reported that *T. polium* possess profound anti-inflammatory and antioxidant activity (10, 11, 38). Furthermore, *T. polium* extract enhances intracellular glutathione levels by promoting the glutathione biosynthetic pathway (39). These properties motivate us to study its hepatoprotectivity in acetaminophen-induced liver toxicity.

Panovska *et al.* investigated hepatoprotective activity of the ethyl acetate extract of *Teucrium polium* L. against CCl₄-induced liver damage. They reported that intraperitoneal injection of *T. polium* extract for 7 days resulted in restoration of liver damage to the normal state (40).

Our results provided strong evidence that *T. polium* extract significantly inhibited the acute liver toxicity induced by high doses of acetaminophen in mice, as shown by a decrease in serum liver enzyme activities (AST, ALT and ALP) and bilirubin concentrations (Tables 1 and 2). Moreover, the liver morphology and histopathology findings confirm the protective activity of this extract against the acetaminophen-induced liver damage as it is evident by the reversal of centrilobular necrosis, fatty changes (steatosis) and scattered lymphocytes infiltrate in hepatic parenchyma by *T. polium* administration. Thus, as shown in Figures 1E and 1F, only mild inflammation and lymphocyte infiltration were observed. Although this protective effect was dose-dependent, there was no significant difference between doses of 250 and 500 mg/Kg of *T. polium* extract (Table 1). Despite the fact that *T. polium* extract significantly reduced ALT and AST levels in groups 4, 5 and 6, it can't completely restore these biochemical parameters to the normal values. Moreover, group two that received only crude extract of *T. polium* L (500 mg/Kg, once daily, for 5 days) did not have any significant differences with negative control group based on biochemical parameters (AST, ALT, ALP and bilirubin) and histopathological findings and did not cause liver damage. Similarly, in the study of Iriadam *et al.*, oral administration of *T. polium* L (82 mg/Kg) did not cause any adverse effect on liver (39).

In conclusion, this herbal extract had potential

protective effect in all doses but the most significant protection was observed in doses of 250 and 500 mg/Kg ($p < 0.05$). In addition, these findings were supported and confirmed by histological examination. Further studies are required to isolate and purify the bioconstituents involved in hepatoprotection of this plant as well as to confirm the mechanisms responsible for hepatoprotective activity.

Acknowledgment

This work was a part of M.Sc thesis of Hossein Forouzandeh which was supported by the grant number of TRC-8901 provided by Deputy of Research Affairs of Ahvaz Jundishapur University of Medical Sciences, Ahvaz, Iran.

References

- (1) Blumenthal M. *The complete German Commission E monographs: therapeutic guide to herbal medicines*. Thieme Medical Pub. (1998).
- (2) Susunaga GS, Siani AC, Pizzolati MG, Yunes RA and Delle Monache F. Triterpenes from the resin of *Protium heptaphyllum*. *Fitoterapia*. (2001) 72: 709-711.
- (3) Boulila A, Bejaoui A, Messaoud C and Boussaid M. Variation of Volatiles in Tunisian Populations of *Teucrium polium* L.(Lamiaceae). *Chemistry and Biodiversity*. (2008) 5: 1389-1400.
- (4) Khoshnood-Mansoorkhani MJ, Moein MR and Oveisi N. Anticonvulsant Activity of *Teucrium polium* Against Seizure Induced by PTZ and MES in Mice. *Iranian J. Pharm. Res.*(2010) 9: 395-401.
- (5) Mousavi SE, Shahriari A, Ahangarpour A, Vatanpour H and Jolodar A. Effects of *Teucrium polium* Ethylacetate Extract on Serum, Liver and Muscle Triglyceride Content of Sucrose-induced Insulin Resistance in Rat. *Iranian J. Pharm. Res.* (2012) 11: 347-355
- (6) Ardestani A and Yazdanparast R. Inhibitory effects of ethyl acetate extract of *Teucrium polium* on *in-vitro* protein glycooxidation. *Food and Chemical Toxicology*. (2007) 45: 2402-2411.
- (7) Rasekh H, Khoshnood-Mansourkhani M and Kamalinejad M. Hypolipidemic effects of *Teucrium polium* in rats. *Fitoterapia*.(2001) 72: 937-939.
- (8) Mousavi SE, Shahriari A, Ahangarpour A Vatanpour H and Jolodar A. Effects of *Teucrium polium* Ethylacetate Extract on Serum, Liver and Muscle Triglyceride Content of Sucrose-induced Insulin Resistance in Rat. *Iranian J. Pharm. Res.* (2012) 11: 347-355.
- (9) Esmacili MA and Yazdanparast R. Hypoglycaemic effect of *Teucrium polium*: studies with rat pancreatic islets. *J. ethnopharmacology*. (2004) 95: 27-30.
- (10) Ljubuncic P, Dakwar S, Portnaya I, Cogan U, Azaizeh H and Bomzon A. Aqueous extracts of *Teucrium polium* possess remarkable antioxidant activity *in-vitro*. *Evidence Based Complementary and Alternative Medicine*. (2006) 3: 329-338.
- (11) Couladis M, Tzakou O, Verykokidou E and Harvala C. Screening of some Greek aromatic plants for antioxidant activity. *Phytotherapy Research*. (2003) 17: 194-195.
- (12) Mitchell M, Schenker S, Avant G and Speeg Jr K. Cimetidine protects against acetaminophen hepatotoxicity in rats. *Gastroenterology*. (1981) 81: 1052.
- (13) Lee WM. Acetaminophen and the U.S. Acute Liver Failure Study Group: Lowering the risks of hepatic failure. *Hepatology*. (2004) 40: 6-9.
- (14) Richie JP, Lang CA and Chen T S. Acetaminophen-Induced Depletion Of Glutathione And Cysteine In The Aging Mouse Kidney. *Biochemical Pharmacology*. (1992) 44: 129- 135.
- (15) McClain CJ, Price S, Barve S, Devalarja R and Shedlofsky S. Acetaminophen Hepatotoxicity:An Update. *Current Gastroenterology Reports*. (1999) 1: 42-49.
- (16) Zaher H, Buters JTM, Ward JM and Bruno MK. Protection against Acetaminophen Toxicity in CYP1A2 and CYP2E1 Double-Null Mice. *Toxicology and Applied Pharmacology*.(1998) 152: 193-199.
- (17) Sener G, Sehirlirli AO and Ayanoglu-Dulger G. Protective effects of melatonin, vitamin E and N-acetylcysteine against acetaminophen toxicity in mice: a comparative study. *J. Pineal Res.* (2003) 35: 61-68.
- (18) Yoon MY, Kim SJ, Lee BH, Chung JH and Kim YC. Effects of dimethylsulfoxide on metabolism and toxicity of acetaminophen in mice. *Biological and Pharmaceutical Bulletin*. (2006) 29: 1618-1624.
- (19) Lee KJ, You HJ, Park SJ and Kim YS. Hepatoprotective effects of Platycodon grandiflorum on acetaminophen-induced liver damage in mice. *Cancer Letters*. (2001) 174: 73-81.
- (20) Handa SS, Khanuja SPS, Longo G and Rakesh DD. Extraction Technologies For Medicinal And Aromatic Plants. International Centre For Science And High Technology, Trieste (2008) 74-80.
- (21) Reitman S and Frankel S. A colorimetric method for the determination of serum levels of glutamic oxaloacetic acid and pyruvic acid transaminases. *Am. J. Clin. Pathol.* (1957) 10: 394-399.
- (22) King J. *The phosphohydrolases and alkaline phosphatases: Practical clinical enzymology* Van Nostrand Company limited London (1965).
- (23) Watson D and Rogers JA. A study of six representative methods of plasma bilirubin analysis. *J. Clin. Pathol.* (1961) 14: 271-278.
- (24) Bancroft JD and Stevens A. Theory and practice of histological techniques. 4th ed. Churchill Livingstone, New York (1996).
- (25) Ahsan R, Islam KM, Musaddik A and Haque E. Hepatoprotective activity of methanol extract of some medicinal plants against carbon tetrachloride induced

- hepatotoxicity in albino rats. *Global J. Pharmacology*. (2009) 3: 116-122.
- (26) Angelico M, Gridelli B and Strazzabosco M. A.I.S.F. Commission on liver transplantation. Practice of adult liver transplantation in Italy: Recommendations of the Italian association for the study of the liver (A.I.S.F.). *Digest. Liver Dis.* (2005) 37: 461-467.
- (27) Bhawna S and Kumar SU. Hepatoprotective activity of some indigenous plants. *International J. Pharm. Tech. Res.* (2009) 1: 1330-1334.
- (28) Dwivedi Y, Rastogi R, Garg N and Dhawan B. Prevention of paracetamol-induced hepatic damage in rats by picroliv, the standardized active fraction from *Picrorhiza kurroa*. *Phytotherapy Research*. (1991) 5: 115-119.
- (29) Visen PKS, Shukla B, Patnaik GK and Dhawan BN. Andrographalide protects rat hepatocytes against paracetamol induced damage. *J. Ethnopharmacol.* (1993) 40: 131-136.
- (30) Singh A and Handa SS. Hepatoprotective activity of *Apium graeolens* and *Hygrophila auriculata* against paracetamol and thioacetamide intoxication in rats. *J. Ethnopharmacol.* (1995) 49: 119-126.
- (31) Kalantari H, Khorsandi LS and Taherimobarekeh M. The protective effect of the *Curcuma longa* extract on acetaminophen induced hepatotoxicity in mice. *Jundishapur Journal of Natural pharmaceutical products*. (2007) 2: 7-12.
- (32) Ita S, Akpanyung E, Umoh B, Ben E and Ukafia S. Acetaminophen induced hepatic toxicity: Protective role of *Ageratum conyzoides*. *Pakistan J. Nutrition*. (2009) 8: 928-932.
- (33) Jollow D, *et al.* Acetaminophen-induced hepatic necrosis. II. Role of covalent binding in vivo. *Journal of Pharmacology and Experimental Therapeutics*. (1973) 187: 195.
- (34) Chenoweth MB and Hake CL. The smaller halogenated aliphatic hydrocarbons. *Annual Review of Pharmacology*. (1962) 2: 363-398.
- (35) Ellenhorn MJ and Ellenhorn S. *Medical toxicology and treatment of human poisoning* Williams and Willkins Company, Philadelphia (1997).
- (36) Yamaguchi T, Terakado M and Hario F. Role of bilirubin as an antioxidant in an ischemia-reperfusion of rat liver and induction of heme oxygenase. *Biochem. Biophys Res. Commun.* (1996) 223: 129-135.
- (37) Bhoopata L, Srichairatanakoob S and Kanjanapothic D. Hepatoprotective effects of lychee (*Litchi chinensis* Sonn.): A combination of antioxidant and anti-apoptotic activities. *Journal of Ethnopharmacology*. (2011) 136: 55-66.
- (38) Tariq M, Ageel AM and Al-Said MS. Antiinflammatory activity of *T. polium*. *Int. J. Tissue React.* (1989) 11: 185-188.
- (39) Shtukmaster S, Ljubuncic P and Bomzon A. The effect of an aqueous extract of *Teucrium polium* on glutathione homeostasis *in-vitro*: A possible mechanism of its hepatoprotectant action. *Hindawi Publishing Corporation*. (2010) 1-7.
- (40) Panovska TK, Kulevanova S, Gjorgoski I, Bogdanov A M and Petrushevska G. Hepatoprotective effect of the ethyl acetate extract of *Teucrium polium* L. against carbontetrachloride-induced hepatic injury in rats. *Acta. Pharm.* (2007)57: 241-8.
- (41) Iriadam M, Musa D, Gumushan H and Baba F. Effects of two Turkish medicinal plants *Artemisia herba-alba* and *Teucrium polium* on blood glucose levels and other biochemical parameters in rabbits. *J. Cell and Molecular Biology*. (2006) 5: 19-24.

This article is available online at <http://www.ijpr.ir>
