

^{99m}Tc-Ubiquicidin [29–41], a Promising Radiopharmaceutical to Differentiate Orthopedic Implant Infections from Sterile Inflammation

Davood Beiki^a, Gholamali Yousefi^a, Babak Fallahi^{a*}, Mohammad Naghi Tahmasebi^b, Ali Gholamrezanezhad^a, Armaghan Fard-Esfahani^a, Mostafa Erfani^c and Mohammad Eftekhari^a

^aResearch Center for Nuclear Medicine, Tehran University of Medical Sciences, Tehran, Iran. ^bDepartment of Orthopedic and Trauma Surgery, Shariati Hospital, Tehran University of Medical Sciences, Tehran, Iran. ^cNuclear Science Research School, Nuclear Sciences and Technology Research Institute, Atomic Energy Organization of Iran, Tehran, Iran.

Abstract

Ubiquicidin (UBI) [29-41] is a synthetic cationic antimicrobial peptide that preferentially binds to bacterial cell membrane at the site of infection. We aimed to assess diagnostic value of ^{99m}Tc-UBI [29-41] as a radiopharmaceutical in differentiation of bacterial infection from sterile inflammation in suspected orthopedic implants. Nine patients suspected for orthopedic implant infection, all males with the mean age of 41.6 ± 20.9 years, were studied. A dose of 10 MBq/Kg (range : 555-740 MBq) ^{99m}Tc-UBI [29-41] was injected intravenously. A dynamic study followed by static whole body imaging at 30, 60 and 120 min post-radiotracer injection was acquired. Periprosthetic tissue culture was considered the closest test to a gold standard for diagnosing infections and scintigraphic scans were categorized as true- or false-positive and true- or false-negative, considering the bacterial culture as the gold standard. No adverse reaction was observed during or after the radiotracer injection days. There were five true positive, four true negative and no false positive and false negative scans. Sensitivity, specificity, positive predictive value (PPV) and negative predictive value (NPV) were all calculated as 100%. We found a high diagnostic accuracy for ^{99m}Tc-UBI [29-41] scintigraphy in differentiation of bacterial infection from sterile inflammation in suspected orthopedic implants. Therefore, ^{99m}Tc-UBI [29-41] scintigraphy might be potentially recommended as a safe and promising imaging modality in these settings. However, further studies on a larger number of patients and different pathologies are still needed.

Keywords: Radiopharmaceutical; Ubiquicidin [29-41]; Technetium-99m; Scintigraphy; Orthopedic implant; Infection; Inflammation.

Introduction

As the number of orthopedic procedures continues to rise, there is a substantial increase in surgical implantation of internal

devices and prostheses. Accordingly, the diagnosis of orthopedic implant infections, as one of the most important complications of the procedure, is becoming an increasingly common challenge. Oftentimes, the non-invasive diagnostic differentiation between infection and sterile inflammation is problematic, while clinical management decisions need to be made promptly in order to

* Corresponding author:
E-mail: bfallahi@tums.ac.ir

avoid subsequent serious complications. The current available imaging approaches include ultrasound (1, 2), computed tomography (CT) (3, 4), magnetic resonance imaging (MRI) (5, 6), ^{99m}Tc bone and/or Gallium citrate scintigraphy (7, 8), labeled antigranulocyte antibody or labeled leukocyte study (9), labeled antibiotic such as ciprofloxacin (10), the avidin-biotin system imaging (11-13) and FDG-PET (14-17), which despite the high sensitivity, lack specificity for infections (18, 19). Therefore, advances in the non-invasive differentiation between infection and sterile inflammation are needed.

Ubiquicidin (UBI) [29-41] is a synthetic cationic antimicrobial peptide that preferentially binds to bacterial cell membrane at the site of infection (19-25). Considering its affinity for bacterial components, UBI [29-41] has been labeled with ^{99m}Tc and tested as a potential scintigraphic agent for diagnosis of suspected orthopedic implant infections (26). Limited, but promising, preclinical and pilot studies on this radiopharmaceutical were recently published, but they suffer from remarkable shortcomings, the main one being the absence of a reliable gold standard; therefore, to provide multicentral evidence on its efficacy, further studies were encouraged (26). We aimed to assess the diagnostic value of ^{99m}Tc -UBI [29-41] scintigraphy in differentiation of bacterial infection from sterile inflammation in suspected orthopedic implants.

Experimental

Radiopharmaceutical

^{99m}Tc -Pertechnetate fresh elute from the $^{99}\text{Mo}/^{99m}\text{Tc}$ Generator was used to label the antimicrobial peptide UBI [29-41], which both were supplied by the Radioisotope Division, Atomic Energy Organization of Iran. The radiopharmaceutical was prepared by adding ^{99m}Tc -pertechnetate fresh elute to HYNIC-UBI [29-41] kit and incubating for 15 min at room temperature. The radiopharmaceutical kit was stored at room temperature and used within 6 h of reconstitution. All the labeling and quality controls were done according to the manufacturer's instructions.

Patients

Fourteen consecutive patients, suspicious for implant infection with no history of antibiotic therapy for their present condition, were enrolled in the study. In addition, patients with known hepatic and/or renal disease or history of hypersensitivity state were excluded from the study. The study was approved by the committee on ethics, Tehran University of Medical Sciences and each subject gave written informed consent.

Procedure

Imaging procedure was done with patients in supine position, using a Dual head gamma camera (ADAC, USA) equipped with LEGP collimator. Immediately after the intravenous injection of 10 MBq/Kg (range: 555-740 MBq) of ^{99m}Tc -UBI [29-41], dynamic imaging with 10 sec for each frame up to 10 min post-injection was acquired from the target and the contralateral body regions. Besides, the whole-body anterior and posterior views were obtained at 30, 60, and 120 min after the injection and scanning speed was set at 12 cm/min in all acquisition procedures. The SPECT images were obtained at 2 h post-injection, if needed. The photopeak was set at 140 KeV for ^{99m}Tc .

Visual scoring system was used to categorize studies as positive or negative. The scans were graded as follows (27): 0 (minimal or no uptake; less than or equivalent to soft tissue); 1 (mild; target uptake less than the liver activity); 2 (moderate; uptake greater than or equal to that of the liver activity) and 3 (intense; uptake greater than or equal to that of the kidneys). Lesion activities with grades of 0 or 1 were considered as negative scan and those with grades of 2 or 3 considered as positive scan. All scintigraphic images were interpreted by two experienced nuclear medicine physicians blinded to all radiological and laboratory data and the final decision was made by consensus.

As there is no definite non-invasive gold standard for detection of orthopedic implant infection, periprosthetic tissue culture was considered as the closest test to a gold standard for diagnosing infections and scintigraphic scans were categorized as true- or false-positive and true- or false-negative, considering the bacterial culture as the gold standard. For this purpose,

samples for culturing were taken from the site by an experienced orthopedist.

Statistical analysis

Sensitivity (proportion of true positives identified correctly by the scintigraphy), specificity (proportion of true negatives identified correctly by the scintigraphy), positive predictive value (PPV: proportion of patients with infection who were diagnosed correctly) and negative predictive value (NPV: proportion of patients with negative test results who are diagnosed correctly) of ^{99m}Tc-UBI [29-41] scintigraphy were calculated.

Results and Discussion

Fourteen patients underwent ^{99m}Tc-UBI [29-41] scintigraphy. As five patients refused the tissue sampling procedure, nine patients, all males with the mean age of 41.6 ± 20.9 years, were included in the final analysis. Three objects had hip prosthesis, four internal fixators of tibia, one internal fixator of femur and one internal fixator of humerus. Based on the results of bacteriological culture, five patients had orthopedic implant infections, the pathogenic microorganism in all of which was *Staphylococcus aureus*.

No adverse reaction was observed during or after the radiotracer injection days. In six patients, the scan was interpreted as positive and in three of them, as negative. In all positive studies, the radiotracer activity at the implant site was higher than adjacent tissues in early images (positive blood pool phase). No significant difference was seen in the intensity of uptake in scans between the 30, 60 and 120 min images. Considering the bacteriologic culture as the gold standard, there were five true positive, four true negative and no false positive and false negative scans. Sensitivity, specificity, PPV, NPV and diagnostic accuracy were all calculated as 100%.

Currently available non-invasive imaging modalities suffer from remarkable limitations in the assessment of inflammatory diseases involving internal devices and prostheses. For example, bone scintigraphy, Gallium scans, and ¹⁸F-FDG PET, in spite of their high sensitivity, offer poor sensitivity and MRI is limited due to the artifacts induced by metallic implants (18,

28, 29). Regarding these limitations, a need for an alternative imaging approach has been emphasized.

In-vitro studies have shown a specific binding of ^{99m}Tc-labeled UBI to bacteria and it has been suggested that the accumulation at infection sites, could be the result of its high thermodynamic stability, selectivity and stereo specificity (19). On the other hand, *in-vivo* studies have revealed that there is a significant difference in the ^{99m}Tc-UBI uptake between the bacterial infection and non-bacterial inflammation sites compared to ⁶⁷Ga-citrate, with an average infection/inflammation ratio of 2.08 ± 0.49 for ^{99m}Tc-UBI and 1.14 ± 0.45 for ⁶⁷Ga-citrate (25). These findings prompted investigators to apply ^{99m}Tc-UBI [29-41] scintigraphy for the diagnosis of various human infectious processes and to differentiate it from sterile inflammation (18, 30, 31).

We found an excellent diagnostic accuracy for ^{99m}Tc-UBI [29-41] scintigraphy, which supports the promising previous reports (Table 1). These studies altogether suggest the application of ^{99m}Tc-UBI [29-41] as a reliable imaging modality for differentiation of bacterial infection from sterile inflammation in suspected orthopedic implants. Although the role of this method in diagnostic management of patients with suspected orthopedic implant infection has yet to be defined in larger number of patients and multicenter studies, the approach seems to be promising to arrive at a reliable and early non-invasive diagnosis. Previously, the potential role of quantitative ^{99m}Tc-UBI [29-41] scintigraphy to monitor antibiotic therapy in patients with orthopedic infection has been suggested, as significant reduction in radiotracer uptake after a successful treatment is seen (26). In studies by Nibbering *et al.*, ^{99m}Tc-UBI [29-41] scintigraphy showed an inverse correlation between intensity of radiopharmaceutical uptake and dose of antibiotic in the infection focus (32, 33), which further suggest its application for treatment monitoring purposes.

To date, more than 70 patients suspicious for osteomyelitis and orthopedic implant infection have been studied with ^{99m}Tc-UBI [29-41] scintigraphy, which has resulted in accuracy indices of more than 80% in the published

Table 1. A review on clinical trials assessing the accuracy of ^{99m}Tc -UBI [29-41] scintigraphy in various musculoskeletal applications.

Author/Year	Sample size	Pathology	Sensitivity	Specificity	Accuracy	Gold standard
Assadi <i>et al.</i> 2011 (1)	20	11 Diabetic ulcer, 5 fracture or orthopedic implant, 4 miscellaneous infections	100	100	100	consensus of clinicians considering clinical and paraclinical data
Meléndez-Alafort <i>et al.</i> 2004 (7)	6	Pediatric cases suspicious for osteomyelitis cases	100	100	100	Gallium Scintigraphy
Dillmann-Arroyo <i>et al.</i> 2011 (13)	27	Vertebral osteomyelitis (12 with orthopedic implants)	100	88	-	histopathologic study or microbiologic culture or with the clinical findings after a follow-up of > 6 months
Akhtar <i>et al.</i> 2005 (10)	18	10 soft-tissue infections, 3 bone infection, 1 patient with no bacterial infection	100	80	94.4	bacterial culture as the major criterion and clinical tests, radiography, and 3-phase bone scanning as minor criteria
Cumulative value	71	-	100	90.4	-	-

reports (Table 1). However, application of ^{99m}Tc -UBI [29-41] scintigraphy is not limited to musculoskeletal indications. Vallejo *et al.* have applied the same imaging technique to diagnose the mediastinitis after cardiac surgery and reported a high diagnostic accuracy of more than 90% (34). Sepulveda-Mendez *et al.* also found a specificity of 95.35%, sensitivity of 97.52%, positive predictive value of 96.72%, negative predictive value of 96.47%, and the accuracy of 96.62% for ^{99m}Tc -UBI [29-41] scintigraphy in 196 patients with fever of unknown origin (35). Brouwer *et al.* suggested that ^{99m}Tc -UBI [29-41] scintigraphy can be a dedicated non-invasive imaging tool for the early detection of infective endocarditis (36).

Technical considerations

In our study, we found no significant difference in the intensity of radiopharmaceutical uptake between 30, 60 and 120 min images. This finding is supported by previous studies (18, 20, 37) and could be considered as an indirect evidence of the strong radiopharmaceutical avidity for the target peptide. It also suggests that ^{99m}Tc -UBI [29-41] will be cleared rapidly from the circulation with a first pass-like pattern (18, 27) and a high target to background ratio is achieved as early as 15 min post-injection. The radiopharmaceutical shows fast renal clearance with negligible liver uptake and hepatobiliary excretion (Figure 1). Therefore, ^{99m}Tc -UBI [29-41] scintigraphy

can be completed in just half an hour after the injection, as delayed imaging adds no additional finding to the study. It has been confirmed that the effective dose is within acceptable range, even for application in pediatric population (24).

Safety profile

No adverse reaction was seen in our population, which is in accordance with the previous reports (18, 27, 38). The safety profile and lack of hazards of handling blood products (the major disadvantage of labeled leukocytes) as well as its applicability to leukopenic patients and low probability of resistance to antimicrobial peptides has been considered as the major advantages of ^{99m}Tc -UBI [29-41] scintigraphy (17).

Study limitation

Small sample size of the study was the major limitation. Besides, in our study, all patients with infected implants had *Staphylococcus aureus* positive cultures, which are explained by the fact that *Staphylococcus aureus* is the most common cause of osteomyelitis in this setting. Akhtar *et al.* reported that ^{99m}Tc -UBI [29-41] shows less avidity at sites infected with *E. coli* than *S. aureus* and concluded that the lower accumulation with *E. coli* might be explained by either the lower virulence of the organism or diminished affinity of the peptide for *E. coli* membranes (39). Larger study populations probably will increase a

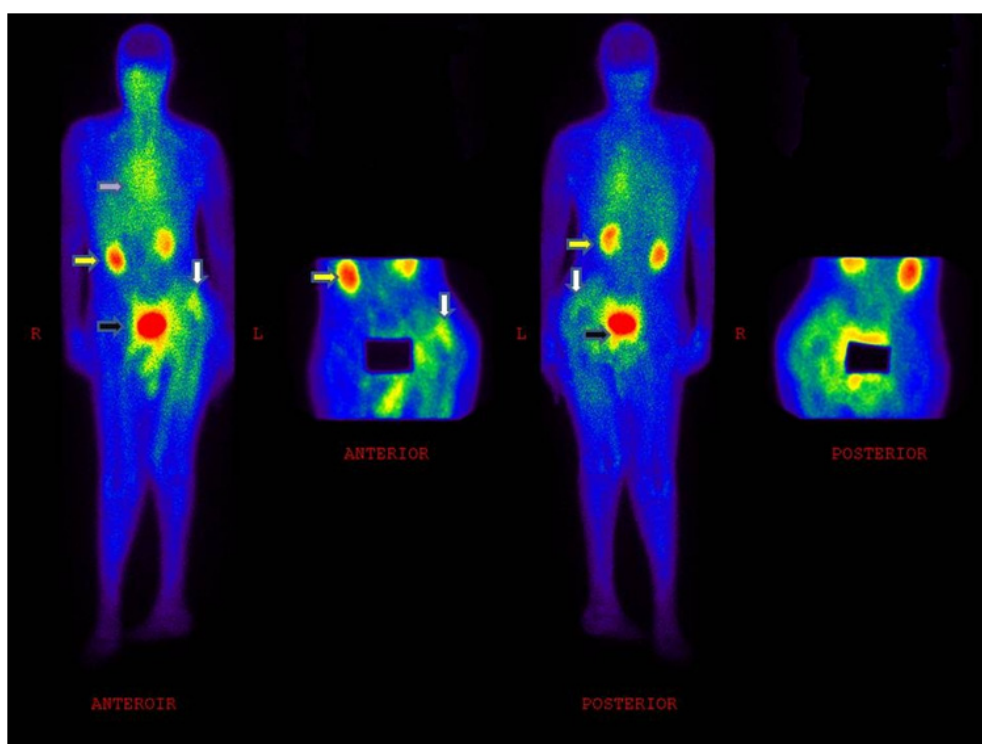


Figure 1. A 62 y/o patient (weight: 74 Kg) with left hip prosthesis, showing increased ^{99m}Tc-UBI [29-41] uptake corresponding to the region of prosthesis. The arrow in white shows the infection site, the arrow in yellow shows radiotracer excretion by the kidneys, the arrow in black shows radiotracer accumulation in bladder, and the arrow in purple shows cardiac blood pool activity.

higher probability of covering other pathogenic organisms and will provide the opportunity to assess the diagnostic accuracy of ^{99m}Tc-UBI [29-41] scintigraphy in other pathogenic organisms.

Conclusion

We found a high diagnostic accuracy for ^{99m}Tc-UBI [29-41] scintigraphy in differentiation of bacterial infection from sterile inflammation in suspected orthopedic implants. Therefore, ^{99m}Tc-UBI [29-41] scintigraphy might be potentially recommended as a safe and promising imaging modality in these settings. However, further studies on larger number of patients and different pathologies are still needed.

Acknowledgment

This study was part of a MD thesis and financially supported by Tehran University of Medical Sciences (grant no. 88-01-58-8269). The ^{99m}Tc-UBI has been of the items in the “National

Radiopharmaceutical Production Project, 2010-2012, Tehran, Iran”.

References

- (1) Eisler T, Svensson O, Engstrom CF, Reinholt FP, Lundberg C, Wejknar B, Schmalholz A and Elmstedt E. Ultrasound for diagnosis of infection in revision total hip arthroplasty. *J. Arthroplasty.* (2001) 16:1010-1017.
- (2) Gibbon WW, Long G, Barron DA and O'Connor PJ. Complications of orthopedic implants: sonographic evaluation. *J. Clin. Ultrasound.* (2002) 30:288-299.
- (3) Robertson DD, Magid D, Poss R, Fishman EK, Brooker AF and Sledge CB. Enhanced computed tomographic techniques for the evaluation of total hip arthroplasty. *J. Arthroplasty.* (1989) 4:271-276.
- (4) Cyteval C, Hamm V, Sarrabere MP, Lopez FM, Maury P and Taourel P. Painful infection at the site of hip prosthesis: CT imaging. *Radiology.* (2002) 224:477-483.
- (5) White LM, Kim JK, Mehta M, Merchant N, Schweitzer ME, Morrison WB, Hutchison CR and Gross AE. Complications of total hip arthroplasty: MR imaging-initial experience. *Radiology.* (2000) 215:254-262.
- (6) Hayter CL, Koff MF and Potter HG. Magnetic resonance imaging of the postoperative hip. *J. Magn.*

- Reson. Im.* (2012) 35:1013-1025.
- (7) Mountford PJ, Coakley AJ, Hall FM and Wells CP. Dual radionuclide subtraction imaging of vertebral disk infection using an In-111-labeled leukocyte scan and a Tc-99m-labeled tin colloid scan. *Eur. J. Nucl. Med.* (1983) 8:557-558.
 - (8) Van FT, Renaux P, el Esper I, Jarde O and Vives P. Labeled leukocyte scintigraphy and total hip prosthesis. *Acta. Orthop. Belg.* (1996) 62:212-217.
 - (9) Mountford PJ and Coakley AJ. Role of technetium-99m phosphonate bone and indium-111 leukocyte scanning for detecting the infected hip prosthesis. *J. Nucl. Med.* (1989) 30:562-563.
 - (10) Larikka MJ, Ahonen AK, Niemela O, Junila JA, Hamalainen MM, Britton K and Syrjala HP. Comparison of 99mTc ciprofloxacin, 99mTc white blood cell and three-phase bone imaging in the diagnosis of hip prosthesis infections: improved diagnostic accuracy with extended imaging time. *Nucl. Med. Commun.* (2002) 23:655-661.
 - (11) Lazzeri E, Manca M, Molea N, Marchetti S, Consoli V, Bodei L, Bianchi R, Chinol M, Paganelli G, and Mariani G. Clinical validation of the avidin/indium-111 biotin approach for imaging infection inflammation in orthopaedic patients. *Eur. J. Nucl. Med.* (1999) 26:606-614.
 - (12) Elmaleh DR, Babich JW, Graham W and Fischman AJ. Tc-99m-biotin analogs for infection imaging without pre- or post targeting with avidin-antibody conjugates. *J. Nucl. Med.* (1998) 39:267-267.
 - (13) Goodwin DA. New methods for localizing infection - a role for avidin-biotin, *J. Nucl. Med.* (1992) 33:1816-1818.
 - (14) Chen SH, Ho KC, Hsieh PH, Lee MSS and Yen TC. Potential clinical role of [F-18]FDG-PET/CT in detecting hip prosthesis infection: a study in patients undergoing two-stage revision arthroplasty with an interim spacer. *Q. J. Nucl. Med. Mol. Im.* (2010) 54:429-435.
 - (15) Chryssikos T, Parvizi J, Ghanem E, Newberg A, Zhuang HM and Alavi A. FDG-PET imaging can diagnose periprosthetic infection of the hip. *Clin. Orthop. Relat. Res.* (2008) 466:1338-1342.
 - (16) St Delank K, Schmidt M, Michael JWP, Dietlein M, Schicha H and Eysel P. The implications of 18F-FDG PET for the diagnosis of endoprosthetic loosening and infection in hip and knee arthroplasty: Results from a prospective, blinded study. *BMC. Musculoskel. Dis.* (2006) 7:20.
 - (17) Stumpe KDM, Notzli HP, Zanetti M, Kamel EM, Hany TF, Gorres GW, von Schulthess GK and Hodler J. FDG PET for differentiation of infection and aseptic loosening in total hip replacements: Comparison with conventional radiography and three-phase bone scintigraphy. *Radiology.* (2004) 231:333-341.
 - (18) Assadi M, Vahdat K, Nabipour I, Sehhat MR, Hadavand F, Javadi H, Tavakoli A, Saberifard J, Kalantarhormozi MR, Zakani A and Eftekhari M. Diagnostic value of ^{99m}Tc-ubiquicidin scintigraphy for osteomyelitis and comparisons with ^{99m}Tc-methylene diphosphonate scintigraphy and magnetic resonance imaging. *Nucl. Med. Commun.* (2011) 32: 716-723.
 - (19) Ferro-Flores G, de María Ramírez F, Meléndez-Alafort L, de Murphy CA and Pedraza-López M. Molecular recognition and stability of ^{99m}Tc-UBI 29-41 based on experimental and semiempirical results. *Appl. Radiat. Isot.* (2004) 61: 1261-1268.
 - (20) Meléndez-Alafort L, Nadali A, Pasut G, Zangoni E, De Caro R, Cariolato L, Giron MC, Castagliuolo I, Veronese FM and Mazzi U. Detection of sites of infection in mice using ^{99m}Tc-labeled PN(2)S-PEG conjugated to UBI and 99mTc-UBI: a comparative biodistribution study. *Nucl. Med. Biol.* (2009) 36: 57-64.
 - (21) Meléndez-Alafort L, Ramírez Fde M, Ferro-Flores G, Arteaga de Murphy C, Pedraza-López M and Hnatowich DJ. Lys and Arg in UBI: a specific site for a stable Tc-99m complex? *Nucl. Med. Biol.* (2003) 30: 605-615.
 - (22) Brouwer CP, Wulferink M and Welling MM. The pharmacology of radiolabeled cationic antimicrobial peptides. *J. Pharm. Sci.* (2008) 97: 1633-1651.
 - (23) Ferro-Flores G, de María Ramírez F, Meléndez-Alafort L, de Murphy CA and Pedraza-López M. Molecular recognition and stability of ^{99m}Tc-UBI 29-41 based on experimental and semiempirical results. *Appl. Radiat. Isot.* (2004) 61: 1261-1268.
 - (24) Meléndez-Alafort L, Rodríguez-Cortés J, Ferro-Flores G, Arteaga De Murphy C, Herrera-Rodríguez R, Mitsoura E and Martínez-Duncker C. Biokinetics of (99m)Tc-UBI 29-41 in humans. *Nucl. Med. Biol.* (2004) 31: 373-379.
 - (25) Ferro-Flores G, Arteaga de Murphy C, Pedraza-López M, Meléndez-Alafort L, Zhang YM, Rusckowski M and Hnatowich DJ. *In-vitro* and *in-vivo* assessment of 99mTc-UBI specificity for bacteria. *Nucl. Med. Biol.* (2003) 30: 597-603.
 - (26) Nazari B, Azizmohammadi Z, Rajaei M, Karami M, Javadi H, Assadi M and Asli IN. Role of 99mTc-ubiquicidin 29-41 scintigraphy to monitor antibiotic therapy in patients with orthopedic infection: a preliminary study. *Nucl. Med. Commun.* (2011) 32: 745-751.
 - (27) Akhtar MS, Qaisar A, Irfanullah J, Iqbal J, Khan B, Jehangir M, Nadeem MA, Khan MA, Afzal MS, Ul-Haq I and Imran MB. Antimicrobial peptide 99mTc-ubiquicidin 29-41 as human infection-imaging agent: clinical trial. *J. Nucl. Med.* (2005) 46: 567-573.
 - (28) Signore A, Mather SJ, Piaggio G, Malviya G and Dierckx RA. Molecular imaging of inflammation/infection: nuclear medicine and optical imaging agents and methods. *Chem. Rev.* (2010) 110: 3112-3145.
 - (29) Israel O, Keidar Z. PET/CT imaging in infectious conditions. *Ann. N. Y. Acad. Sci.* (2011) 1228: 150-166.
 - (30) Dillmann-Arroyo C, Cantú-Leal R, Campa-Núñez H, López-Cavazos C, Bermúdez-Argüelles M and Mejía-Herrera JC. Application of the ubiquicidin 29-41 scan in the diagnosis of pyogenic vertebral osteomyelitis.

- Acta Ortop. Mex.* (2011) 25: 27-31.
- (31) Brouwer CP, Sarda-Mantel L, Meulemans A, Le Guludec D and Welling MM. The use of technetium-99m radiolabeled human antimicrobial peptides for infection specific imaging. *Mini Rev. Med. Chem.* (2008) 8: 1039-1052.
- (32) Nibbering PH, Welling MM, Paulusma-Annema A, Brouwer CP, Lupetti A and Pauwels EK. ^{99m}Tc-Labeled UBI 29-41 peptide for monitoring the efficacy of antibacterial agents in mice infected with *Staphylococcus aureus*. *J. Nucl. Med.* (2004) 45:321-326.
- (33) Nibbering PH, Welling MM, Paulusma-Annema A, van den Barselaar MT and Pauwels EKJ. Monitoring the efficacy of antibacterial treatments of infections with ^{99m}Tc-labeled antimicrobial peptides. *Nucl. Med. Commun.* (2000) 21: 575-576.
- (34) Vallejo E, Martinez I, Tejero A, Hernandez S, Jimenez L, Bialostozky D, Sanchez G, Ilarraza H and Ferro-Flores G. Clinical utility of ^{99m}Tc-labeled ubiquicidin 29-41 antimicrobial peptide for the scintigraphic detection of mediastinitis after cardiac surgery. *Arch. Med. Res.* (2008) 39: 768-774.
- (35) Sepúlveda-Méndez J, de Murphy CA, Rojas-Bautista JC and Pedraza-López M. Specificity of ^{99m}Tc-UBI for detecting infection foci in patients with fever in study. *Nucl. Med. Commun.* (2010) 31: 889-895.
- (36) Brouwer CP, Gemmel FF and Welling MM. Evaluation of ^{99m}Tc-UBI 29-41 scintigraphy for specific detection of experimental multidrug-resistant *Staphylococcus aureus* bacterial endocarditis. *Q. J. Nucl. Med. Mol. Imaging.* (2010) 54: 442-450.
- (37) Akhtar MS, Khan ME, Khan B, Irfanullah J, Afzal MS, Khan MA, Nadeem MA, Jehangir M and Imran MB. An imaging analysis of (99m)Tc-UBI (29-41) uptake in *S. aureus* infected thighs of rabbits on ciprofloxacin treatment. *Eur. J. Nucl. Med. Mol. Imaging.* (2008) 35: 1056-1064.
- (38) Fard-Esfahani A, Beiki D, Fallahi B, Mohajeri-Tehrani MR, Gharaie MR, Rouhipour N, Dehghanian M, Saghari M, Emami-Ardekani A and Eftekhari M. Evaluation of ^{99m}Tc-ubiquicidin 29-41 scintigraphy in differentiation of bacterial infection from sterile inflammation in diabetic foot. *Iran. J. Nucl. Med.* (2010) 18: 20-28.
- (39) Akhtar MS, Iqbal J, Khan MA, Irfanullah J, Jehangir M, Khan B, Ul-Haq I, Muhammad G, Nadeem MA, Afzal MS and Imran MB. ^{99m}Tc-labeled antimicrobial peptide ubiquicidin (29-41) accumulates less in *Escherichia coli* infection than in *Staphylococcus aureus* infection. *J. Nucl. Med.* (2004) 45: 849-856.

This article is available online at <http://www.ijpr.ir>
