

The Importance of Attenuation Correction for Coincidence Positron Tomography on a Hybrid PET/SPECT Gamma Camera System

Philip Cohen MD, Vesna Sossi PhD, Tom Ruth PhD, Michael Boldt MD, Kelly Hudkins RTNM

Lions Gate Hospital and University of British Columbia-TRIUMF
Vancouver/ BC/ Canada

The development of a dual head gamma camera that can perform both routine SPECT scan and coincidence imaging was introduced in 1995 by ADAC Laboratones, Inc. as the Vertex/MCD™ camera. In August 1997, Lions Gate Hospital became the first Canadian hospital to upgrade an existing ADAC Vertex™ SPECT to coincidence imaging for Positron Emmission Tomography. The versatility of these devices and their relatively low cost make positron imaging feasible in the community hospital setting. (Fig 1)

In September of 1999, the Lions Gate Hospital system was further upgraded with the acquisition of ADAC's MCD-AC™ attenuation correction hardware/software package. All patients now undergoing PET studies on the

system are imaged with the attenuation correction upgrade.

For single photon detection, gamma ray attenuation has been a major factor reducing image quality for single photon detection. In coincidence imaging, attenuation correction problems are even more severe due to the fact that the two photons must travel a longer distance than a single photon in tissue to reach the detectors. A pair of Cesium-137 (Cs137) point sources was attached to the sides of the camera heads for transmission scan by each detector. The MCD-AC™ requires a separate transmission scan with the Cs137 point source in singles mode to generate an attenuation map which will be used during the reconstruction of the emission images to compensate for

attenuation effects in those images. The point source assembly is equipped with shutter that opens only acquiring the transmission scan. When the source shutter is turned on, the Cs137 point source casts a collimated fan beam of gamma rays, which passes through the patient body and produces a transmission projection. Users have three options to choose from: transmission scan only, emission scan only, and transmission-emission scan. It normally sets up a 6-minute transmission scan then a 24 minute emission for one bed position of a whole body imaging. (1-12) (Fig.2)

Imaging Procedure

Patients are asked to fast from dinnertime the previous day.

- Blood sugar determined by finger stick, preferably should be <120mg/dl.
- Diabetic patients receive 2-3 units of crystalline insulin SC at least one hour before injection.
- Patients are injected with 5mCi (185MBq) of F-18 FDG.
- No Physical exercise the day of the study.
- No eating or unnecessary talking after injection.
- IV saline infusion is preferred, 10mg lasix are given intravenously 30 minutes later. Bladder catheterization is preferred for all

patients with pelvic lesions in order to minimize bladder activity.

- Patients, if not catheterized, must empty bladder immediately before imaging.
- The waiting period is at least 60 minutes before imaging.
- For lung lesions, 2 body positions from lower neck to mid abdomen or upper pelvis, 30% overlap (60cm imaged area).
- For other indications whole trunk, 3 bed positions (89cm imaged area) from upper thigh to lower neck. Start with pelvis if patient is not catheterized to take advantage of recently emptied bladder, to reduce bladder activity.

Time to change from single photon to coincidence imaging mode is less than 4 minutes and can be interspersed in the normal clinical flow. The system operates at 800,000 to 1.5 million counts per second. The coincidence counts are between 8,000-12,000 cps. The acquisition time per stop is 40 seconds. Thirty-two stops acquired and are automatically reformatted into 96 projections since multiple projection angles are acquired at each physical stop. Emission scans performed first in bed position # 1 followed by transmission scan acquired with continuous TCT motion. The transmission study is automatically formatted into 90 projections, which corresponds to 3 seconds per projection.

Case Presentation

We report on the case of a 73 year old male who presented 2 years previously with a lung tumor involving the left lung, which was resected. The patient was well for a year, when he developed skin lesions which were diagnosed as dermatomyositis. Because of the high association between this skin condition and malignancy, the patient was worked up for recurrent lung malignancy, with no evidence of recurrence on CT scans or plain films of the chest. He was referred for a PET study at our institution, which showed recurrent disease in the mediastinum. We show examples of this patient's study with no attenuation correction, with attenuation correction, and contrast with a dedicated PET scan. (Fig.3)

While the dedicated PET scanner, due to its higher counting statistics, is able to show more lesions, two lesions were quite easily detected in the mediastinum of this patient using the MCD-ACTM system. Improvement in lesion detectability is markedly enhanced in the attenuation corrected image, and the absence of activity in the right lung due to air, the lesion target/background in the mediastinum is more marked. Correct positioning of activity in the liver, and soft-tissue activity due to previous left lung resection are clearer. In this patient's case, all standard x-ray imaging studies had been

normal.

Discussion

Many vendors are currently offering hybrid PET/SPECT gamma cameras to do coincidence positron tomography imaging. The appeal of this particular approach is that one can start to demonstrate the benefits of PET studies in oncology, and educate the referring physicians as to the utility of PET, without tying up a large dollar amount (usually \$1 million plus Canadian dollars) in a dedicated PET system. One can therefore benefit well-selected patients with PET scans using a standard SPECT system, waiting until there is enough clinical demand to justify the higher expenditure necessary for a dedicated system.

While hybrid SPECT/PET systems are able to image cancerous lesions which are often not visible on standard radiology tests (CT, MRI, chest x-ray) as demonstrated in our patient presentation, they are still count limited. The addition of attenuation correction hardware/software to the ADAC camera, or any of these systems, is more important than in dedicated PET cameras, because of this lower count limitation. Scatter, random, and attenuated counts are a higher proportion of total counts than in dedicated systems, and these systems benefit more substantially in terms of image

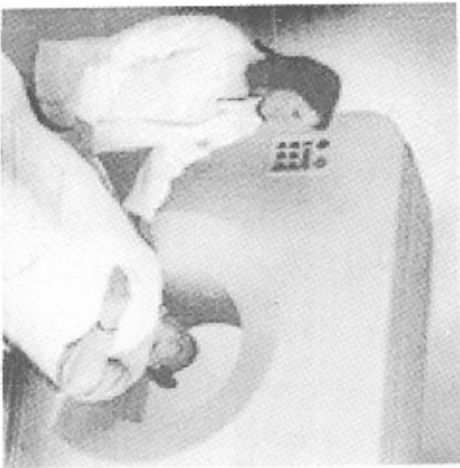
improvement by the addition of attenuation correction than do dedicated PET systems. Similarly, it is anticipated that more accurate random and scatter correction, and additional head and urinary bladder lead shielding will likely benefit these systems more markedly, and probably continue to show significant upgrade in clinical performance of these systems when implemented. Additional improvement is likely from improving PET reconstruction algorithms. Based on measurements at our institution, the space resolution in phantom studies is 1.2 cm in the axial plane with coincidence systems, compared to 1 cm for dedicated systems, but this resolution falls dramatically off the axial plane simply due to the current computer reconstruction algorithms used for image reconstruction.

It is anticipated that the performance of these hybrid coincidence systems can still be substantially improved, and will approach that of dedicated lower end PET scanners. Because of the thinner NaI crystal compared to PGO crystals in dedicated systems, and the fact that coincidences are limited to only 4 areas of each crystal, it is certain that count rates will be in the order of 10% to 30% that of dedicated systems. However if a higher percentage of true

coincidences can be achieved, and blurring caused by suboptimal reconstruction algorithms eliminated, the ability to detect lesions will continue to be significantly improved. The spatial resolution of hybrid SPECT/PET systems should approach those of dedicated systems, albeit with fewer counts. This inferiority, however, may be compensated somewhat by the larger surface area of these systems relative to dedicated PET cameras, as well as the potential for slightly longer counting times in the future.

In Canada, PET is also not reimbursed under a separate fee code, as is currently in the United States. Most Canadian PET centers operate under large research grants, and the lack of PET availability has limited the spread of the technology for cancer detection. Our institution currently also receives the funding for the F-18 FDG under a research grant from the University of British Columbia TRIUMF (Tri-University Meson Facility). Several other Canadian centers, such as the University of Alberta and Hotel-Dieu in Levis Quebec will begin doing oncology PET in the near future, and we anticipate that this useful technology will begin to impact Canadian cancer patients dramatically in the near future.

Coincidence Upgrade




Vertex/MCD

Dedicated PET

- Installed Aug 1997
 - New detectors
 - Thicker scintillator
 - high count-rate electronics
 - More shielding
- Auxiliary storage
- Sun Hyper Sparc processing station
- Acquisition and processing software

Figure 1.

AC Hardware



- 2 detachable ^{137}Cs sources
- Depleted Uranium shielding
- Transmission scan acquired separately from emission
- Scan time approximately 3 minutes
- Radiation exposure to patient $< 0.3 \text{ mSv/hr}$

Figure 2.

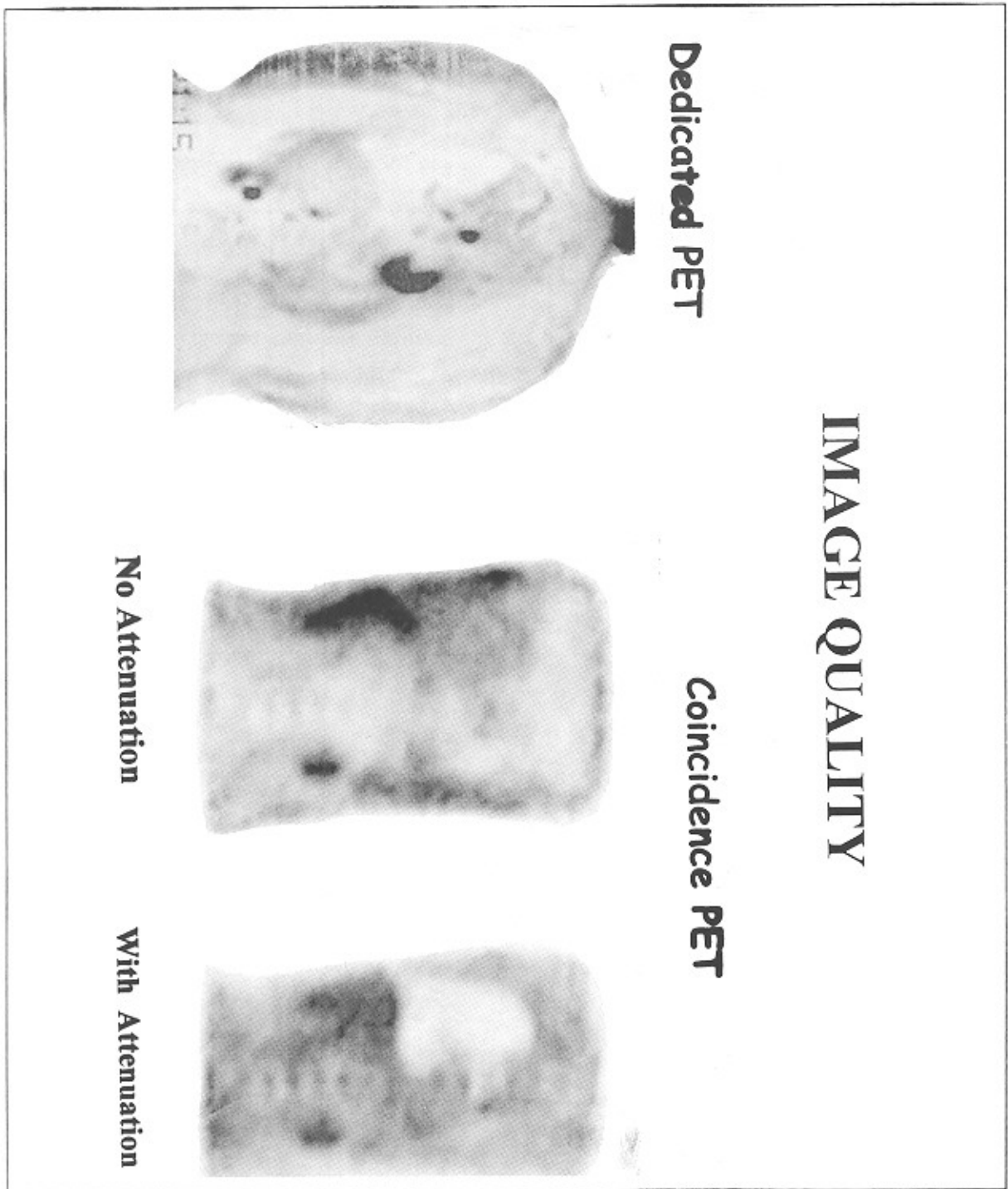


Figure 3.

References

1. Abdel-Dayem H., Luo J, El-Zeftawy H, Sadek S. Clinical experience with dual head gamma camera coincidence imaging, *Clinical Positron Imaging*, 1999, vol 2. No 1 31-39.
2. Phelps, M., Cherry S. The changing design of positron emission tomography. *Clin Posit Imag*, 1998, 31-43. Wagner, H. Multi-energy imaging in nuclear oncology. *Clin Posit Imag*. 1998, 1: 47-50.
4. Abdel-Dayem H.M. Rosen C. El-Zeftawy H.A. et al. PET imaging using F-18 FDG dual head gamma camera in detection of musculoskeletal and soft tissue tumors. *Proceedings of ASCO*, 1998, vol. 17.
5. Abdel-Dayem, H.M., Bonfils, E., Teilgin P., et al. Dual head coincidence imaging (DHCI) of F-18 FDG in primary lung nodules (PLN). *J Nud. Med*. 1998, 38: P. 109
6. Weber W., Abdel-Dayem, H.M., Young, C., et al. Assessment of pulmonary lesions with 18 fluorodeoxyglucose (18FDG) positron imaging using a gamma camera operated in coincidence mode. *J. Nucl. Med.*, 38, P. 108.
7. Lewellen TK, Miyaoka RS, Kaplan MS, et al. Preliminary investigation of coincidence imaging with a standard dual-headed SPECT system. *J Nucl Med* 1995, 36, P. 175.
8. Muehllehner G, Geagan M, Countryman P. SPECT scanner with PET coincidence capability. *J Nucl Med* 1995, 36, P. 70.
9. Muehllehner O, Colsher Jo, Lewitt RM. A hexagonal bar positron camera: Problems and solutions. *IEEE, NS* 1983, 30: 652-660.
10. Mankoff DA, Muehllehner G, Karp JS. The high countrate performance of a two dimensionally positron-sensitive detector for positron emission tomography. *Phys Med Biol*. 1989, 34: 437-456.
11. Mankoff DA, Muehllehner G, Miles O. A local coincidence triggering system for PET tomographs composed of large-area position-sensitive detectors. *IEEE-NS*. 1990, 37: 730-736.
12. Shreve P, Steveton RS, Deters E, Gross MD, Whal RL, Lesion detection in oncologic diagnosis: Comparison of dual head coincidence with dedicated PET imaging, abstract *J of Nuclear Med*, 1998, 39(5): P. 108.
13. Al-Sugair A, Hamblen SM, Laymon CE, Turkington TG, Coleman RE, Lesion detection using nonattenuation corrected dedicated and Camera-Based PET compared with attenuation corrected dedicated PET, Abstract *J of Nuclear Med*, 1998, p. 108
14. Sossi V, Krzywinski M, Cohen P, Knitzek K, Hudkins K, De Rosario J, Morrison KS, Jivan S, Johnson RR, Ruth TJ, UBC/TRIUMF Performance of the ADAC

The Importance of Attenuation Correction for Coincidence Positron Tomography

- MCD dual head coincidence Camera
Abstract J of Nuclear Med, 1998, 39(5), p.
173
15. Kryzwinski M, Cohen P, Mankoff DA, De
Rosario J, Ruth TJ, Effect of Countrate on
Contrast in a Dual Head Coincidence
Camera, V Sossi, accepted for the 1998
IEEE/MIC meeting Nov 1998, Toronto
Canada
16. Budinger TF, PET Instrumentation: What
are the Limits? Seminars in Nuclear
Medicine, 1998, 27(3), pp. 247-267.