

## Delayed Imaging for Detection of Meckel's Diverticulum in Tc-99m Pertechnetate Scintigraphy

Narjess-Khatoon Ayati, MD; Seyed Rasoul Zakavi, MD;  
Ramin Sadeghi, MD; Vahid Reza Dabbagh Kakhki, MD

Nuclear Medicine Department, Imam Reza Hospital,  
Mashhad University of Medical Sciences, Mashhad, Iran.

(Received 28 November 2008, Revised 12 December 2008, Accepted 16 December 2008)

### ABSTRACT

Tc-99m pertechnetate scintigraphy is the modality of choice for diagnosis of Meckel's diverticulum. Interpretation of Meckel's scan identifies a focal area of radiopharmaceutical uptake in the anterior abdomen similar to normal gastric mucosa. The activity must be of the same pattern and intensity as gastric uptake. We present a 13-year-old patient with gastrointestinal bleeding and anemia. Tc-99m pertechnetate scintigraphy was performed and initial images did not show any abnormal tracer activity in the abdomen. However, imaging continued and a focal activity was detected on the right side of the abdomen 60 minutes delayed image. Follow laparoscope operation the Meckel's diverticulum was removed and the patient's symptoms disappeared completely. It is suggest to pay special attention to delayed images (60 minutes or beyond) especially when earlier images are negative.

**Key Words:** Tc-99m pertechnetate scan, Meckel's diverticulum, Gastrointestinal bleeding.

Iran J Nucl Med 2008; 16(2): 45-48

**Corresponding author:** Dr. Vahid Reza Dabbagh Kakhki, Assistant Professor, Department of Nuclear Medicine, Imam Reza Hospital, Mashhad University of Medical Sciences, Ebn Sina Street. Mashhad, Iran.

E-mail: E-mail: dabbaghvr@mums.ac.ir

## INTRODUCTION

Meckel's diverticulum is the most common congenital anomaly of the gastrointestinal tract as a remnant of the vitelline duct in 1.5% to 3% of population (1-3). Painless lower gastrointestinal (GI) bleeding is the most common complication of Meckel's diverticulum in children which can result in anemia (1, 4). From different diagnostic procedures, nuclear medicine has a pivotal role in the diagnosis of Meckel's diverticulum (5). Meckel's scintigraphy using Tc-99m pertechnetate is the imaging of choice for detection of ectopic gastric mucosa which provides high sensitivity, specificity and accuracy for detecting Meckel's diverticulum (6). Routinely, after intravenous injection of Tc-99m pertechnetate, anterior dynamic images from the abdomen are obtained as flow phase. Then immediate and one image every 5 minutes up to 30 minutes are acquired (7, 8). In different literatures, it is mentioned that the activity must be the same of gastric uptake in pattern and intensity. Activity in Meckel's will appear at the same time as normal gastric mucosa and remain in same position despite peristalsis (7, 8). In other word, it appears simultaneously with the stomach (8).

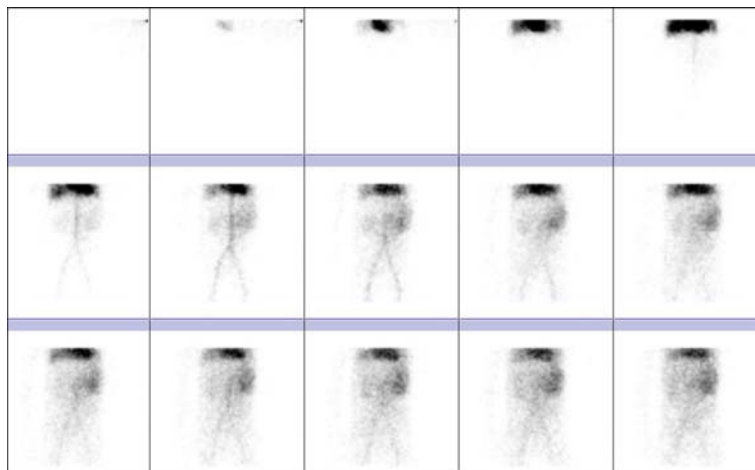
## CASE REPORT

A 13-year-old female with a history of intermittent GI bleeding and severe anemia (Hb=5.5), was referred to our department for Meckel's diverticulum Tc-99m pertechnetate scintigraphy. She was pale on examination. The patient received oral Cimetidine (20 mg/kg/d) for 2 days before the scan. After intravenous administration of 15 mCi Tc-99m pertechnetate, anterior imaging from the abdomen using a dual head gamma camera (E.CAM siemens), equipped with a parallel hole low energy high resolution collimator was obtained. At first, dynamic flow images were obtained, and then static images every 5-minute up to 90 minutes. Flow images (Figure. 1) were normal. In

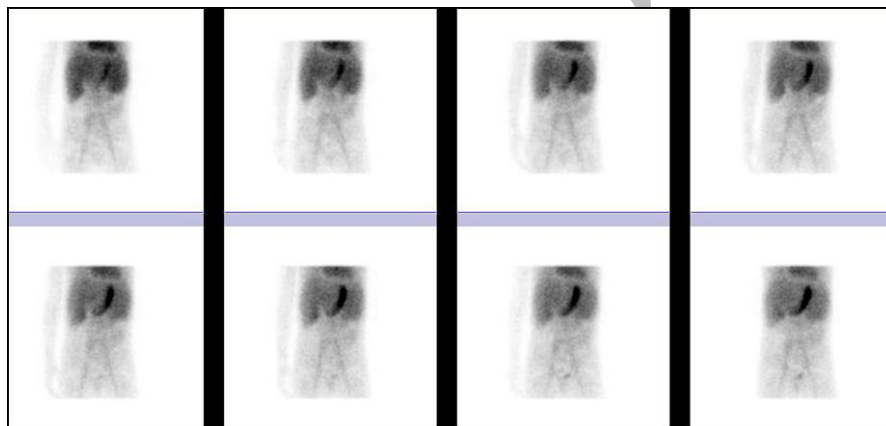
early static images left upper quadrant gastric mucosa was visualized but no abnormal focal activity in other parts of the abdomen (Figure. 2). Imaging continued and 60 minutes after radiotracer injection, a focal activity appeared in the right lateral side of the abdomen (Figure. 3). On delayed anterior, oblique and right lateral views and in the post-void imaging this focal activity persisted. The patient underwent laparoscopic operation and diagnosis of Meckel's diverticulum confirmed. Following treatment GI bleeding stopped completely and her Hb and HCT began to rise.

Although we expect to see Meckel's activity and normal gastric mucosa activity simultaneously with the stomach (2, 9), even before any tracer appears in the bladder (8), our case points to special attention to delayed image. In fact, delayed images help us to reduce false negative results in Meckel's scintigraphy. This delay in visualization of Meckel's diverticulum may be due to presence of a very small gastric mucosa in the diverticulum, poor blood supply due to associated complications such as volvulus or infarction, decreased function of ectopic gastric mucocells, and/or rapid washout of radiotracer due to an irritating effect of the active bleeding (2, 9). Another reason which is reported for non visualization of Meckel's diverticulum by Connolly et al. is abnormal tracer localization overlying the iliac vessels (6). They recommended SPECT images at 30-minute to separate suspected Meckel's diverticulum from vascular structures (6). We also suggest that to see abnormal focal tracer activity indicative of Meckel's diverticulum by delayed images, because it is reported the intensity in the region of the Meckel's diverticulum increases over time (8), while Tc99m-pertechnetate activity will washout from the blood pool and vascular structures. So on delayed images, it can be seen more clearly rather than early images.

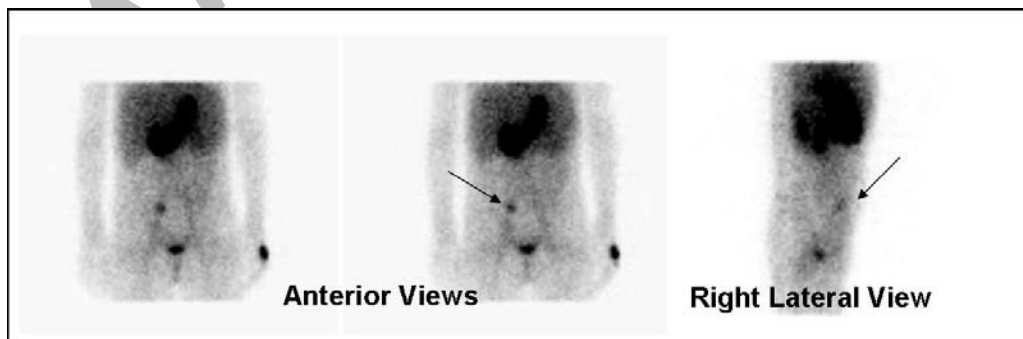
We suggest that specially in case of lack of visualization of any activity in the abdomen at the time of appearance of gastric mucosa,



**Figure 1:** Normal dynamic flow phase images (anterior view of the abdomen) in the Tc-99m pertechnetate scintigraphy.



**Figure 2:** Sequential anterior images of the abdomen in the Tc-99m pertechnetate scintigraphy: No remarkable abnormal tracer activity is noticed in the abdomen.



**Figure 3:** Delayed 60-minute anterior, post-void and right lateral static images in the Tc-99m pertechnetate scintigraphy: Focal increased tracer activity(arrows) which is due to Meckel's diverticulum.

at least delayed acquisition of static images should be performed at 60 minutes and beyond after Tc-99m pertechnetate injection.

### REFERENCES

1. Alavi A, Daniel W, Hongming Z. Scintigraphic detection and localization of gastrointestinal bleeding site. In: Sandler MP. Diagnostic nuclear medicine. 4<sup>th</sup> ed. Philadelphia: Williams & Wilkins, 2003.p.547-548.
2. Katherine LK. Evaluation of gastrointestinal bleeding by nuclear medicine techniques. In: Henkin RE. Nuclear Medicine. 2<sup>nd</sup> ed. Philadelphia: Mosby Elsevier; 2006.p.988-993.
3. Stathaki MI, Karkavitsas NS. Nuclear Medicine in the diagnosis of lower gastrointestinal bleeding. Hell J Nucl Med 2007; 10(3):197-204.
4. Howarth DM. the role of nuclear medicine in the detection of acute gastrointestinal bleeding. Semin Nucl Med 2006; 36(2):133-146.
5. Sadeghi R, Dabbagh Kakhki VR, Zakavi R. Dramatic Movement of a Meckel's diverticulum on Tc-99m pertechnetate imaging. Clin Nucl Med 2007; 32(6):460-461.
6. Connolly LP, Treves ST, Bozorgi F, O'Connor SC. Meckel's diverticulum:demonstration of heterotopic gastric mucosa with technetium-99m-pertechnetate SPECT. J Nucl Med 1998; 39(8):1458-1460.
7. Shackett P. Nuclear medicine technology: Procedures and quick reference. Philadelphia: Lippincott Williams & Wilkins; 2000.p.178.
8. Emamian SA, Shalaby-Rana E, Majd M. The spectrum of heterotopic gastric mucosa in children detected by Tc-99m pertechnetate scintigraphy. Clin Nucl Med 2001; 26(6):529-535.
9. Kumar R, Tripathi M, Chandrashekar N, Agarwala S, Kumar A, Dasan JB et al. Diagnosis of ectopic gastric mucosa using 99Tcm-pertechnetate: spectrum of scintigraphic findings. Br J Radiol 2005; 78(932):714-720.

Archive of SID