

The diagnostic difference between ^{18}F - FDG PET and $^{99\text{m}}\text{Tc}$ -HMPAO SPECT perfusion imaging in assessment of Alzheimer's disease

Maged Abdel Galil Hamed¹ and Ahmed Fathy Abdel Ghany²

¹Radiology Department, Faculty of Medicine, Zagazig University, Zagazig, Egypt

²Radiology Department, Faculty of Medicine, Ain Shams University, Cairo, Egypt

(Received 17 April 2016, Revised 10 August 2016, Accepted 13 August 2016)

ABSTRACT

Introduction: Brain imaging with F-18 fluorodeoxyglucose (^{18}F -FDG) positron emission tomography or Tc-99m hexamethylpropyleneamine oxime ($^{99\text{m}}\text{Tc}$ -HMPAO) SPECT is widely used for the evaluation of Alzheimer's dementia (AD); we aim to assess superiority of one method over the other.

Methods: Twenty four patients with clinical diagnosis of Alzheimer disease underwent ^{18}F -FDG PET and $^{99\text{m}}\text{Tc}$ -HMPAO SPECT in order to assess the zones of hypo metabolism & hypoperfusion specific for Alzheimer's disease.

Results: ^{18}F -FDG PET showed specific zones of hypometabolism in 19 patients (79.1%) while SPECT was positive in 15 cases (62.5%) with statistically significant difference ($P= 0.027$).

Conclusion: ^{18}F -FDG PET was significantly superior to HMPAO SPECT and ^{18}F -FDG PET could replace the classic role of perfusion SPECT in diagnosis of Alzheimer's disease.

Key words: PET; SPECT; HMPAO; Alzheimer's disease

Iran J Nucl Med 2017;25(1):17-22

Published: January, 2017

<http://irjnm.tums.ac.ir>

Corresponding author: Maged Abdel Galil Hamed, Radiology Department, Faculty of Medicine, Zagazig University, Zagazig, Egypt. E-mail: magedbox@gmail.com

INTRODUCTION

Alzheimer's dementia (AD) is one of the leading causes of dementia that needs early diagnosis. The patient presents with clinical features of memory loss and progressive impairment of high cognitive abilities due to progressive neuronal damage, leading to social and occupational problems [1].

The use of structural imaging such as CT or MRI is used to exclude other intracerebral pathologies and to determine the extent of regional brain atrophy [2].

^{99m}Tc -HMPAO Single photon emission computed tomography (SPECT) as well as ^{18}F -FDG positron emission tomography (PET) are used for the early diagnosis of AD and are helpful to clarify the diagnosis in doubtful cases [3].

Abnormalities in both studies in AD are broadly similar with hypometabolism (for ^{18}F -FDG PET) and hypoperfusion (for SPECT) commonly affecting both temporoparietal cortex, with the posterior cingulate and medial temporal areas particularly affected in AD while sensory motor cortices and the cerebellum are usually spared [4].

The aim of this study is to compare the abilities of ^{18}F -FDG PET and ^{99m}Tc -HMPAO SPECT for diagnosis of Alzheimer's disease.

METHODS

Study population

Twenty four patients with clinical diagnosis of AD 14 (58.3%) males, 10 (41.7%) females, their ages were ranging from 54 to 80 years (mean age 65.87 years St 7.4), all were examined in the study during the period of July 2014 to March 2016. All patients performed brain ^{18}F -FDG PET/CT as well as ^{99m}Tc -HMPAO perfusion SPECT scan within 2-3 weeks from the PET scan. The results were correlated to each other in all patients.

The research protocols was approved by Ethics Committee of Faculty of Medicine, Zagazig University, Egypt. The study group was informed about the purpose and significant of the study and a written consent to participate in the study was obtained. The participants were reassured that their information will remain confidential.

Brain ^{18}F -FDG PET/CT protocol

Patients fasted for at about 8 hours before the study. Mean fasting blood glucose level of the patients was 118- 150 mg/dL, and 11 patients had a history of diabetes mellitus. The study began 45 to 60 minutes after the administration of 6-10 mCi ^{18}F -FDG using a hybrid PET/CT system (Ingenuity, Philips, The Netherlands). CT data were acquired first using the following parameters: rotation time 0.5 sec; 120 kV;

140 mAs; with slice thickness 1 mm without the administration of contrast media. After the acquisition of CT data, the patient automatically advanced into the PET scanner and acquisition of PET data was done in 3-dimensional mode with the patient in exactly the same position on the table taking about 3 minutes. The CT data was used for attenuation correction.

^{99m}Tc -HMPAO SPECT protocol

SPECT brain scans were acquired using a Bright view (Philips, the Netherlands) dual-detector gamma camera, starting 30 min after the intravenous administration of (15–30 mCi) of ^{99m}Tc -HMPAO. One hundred twenty 25-s planar views were obtained on a 128 X 128 matrix, zoom 1.23 with pixel size 3.9 mm, using a high resolution low-energy collimator and circular orbit with a radius of 14 cm. Section images were processed with 4 iterations and 20 subsets, post filtered with a 3-dimensional gaussian filter of 1.1 cm in full width at half maximum with uniform attenuation correction and resolution recovery; reformatted data is reconstructed into axial, and coronal and sagittal sections.

Data analysis

Visual analysis: The primary outcome preselected for the study was diagnostic accuracy using visual scan assessment. Scans were rated visually by 3 nuclear medicine and radiology consultant who were unaware of the diagnosis and any clinical information. Separate identification labels were randomly generated for the ^{18}F -FDG PET and SPECT scans, For visual rating, for both PET and SPECT, the observers viewed a display with 15 axial, coronal, and sagittal slices covering the whole brain, 128 × 128 pixels each slice. PET and SPECT scans were both oriented to the orbitomeatal line. In the visual rating, the key imaging features were reduced uptake. Each reader independently rated each scan on a 5-point scale for the degree of confidence in overall abnormality typical of dementia. After individual ratings were completed, the imaging team met to compare and review all their ratings and to produce a set of consensus ratings for each scan. Each scan result was also given a consensus classification of normal or AD.

Quantitative analysis: Post processing is done using a Philips Portal work station 5.5 (Neuro Q application) where both the PET and SPECT images are reoriented, usually to a cranio-caudal orientation, and normalization of uptake. Images obtained in axial projections are reviewed. Use of color coding aid in defining areas of altered metabolism. Generation of statistical brain maps of the data to a normal template and use of region of interest sampling which requires

a co-registered structural image for the guidance of sample placement allows comparison of various metabolic activities between patients with use of statistical modeling, that enables the display of any hypometabolic zones on either two-dimensional cross-sectional images or 3D surface-rendered images facilitating pattern recognition, which is the key to the diagnosis.

Statistical parametric mapping (SPM) approaches, which, unlike ROI approaches, may not be able to study accurately small regions such as the hippocampus in atrophic brains.

RESULTS

Twenty four patients (14 males and 10 females) with clinical diagnosis of AD performed FDG PET and HMPAO SPECT of the brain to identify zones of hypometabolism specific for AD, PET showed specific zones of hypometabolism in 19 patients (79.1 %) while perfusion SPECT was positive in 15 patients (62.5%), both studies matched positive in 14 patients (58.3 %) (Figure 1) matched negative in 4 patients (16%), with 4 patients positive in PET and negative in SPECT (16.6 %) (Figure 2) and one patient positive in SPECT and negative in PET (4.1 %) (Table 1).

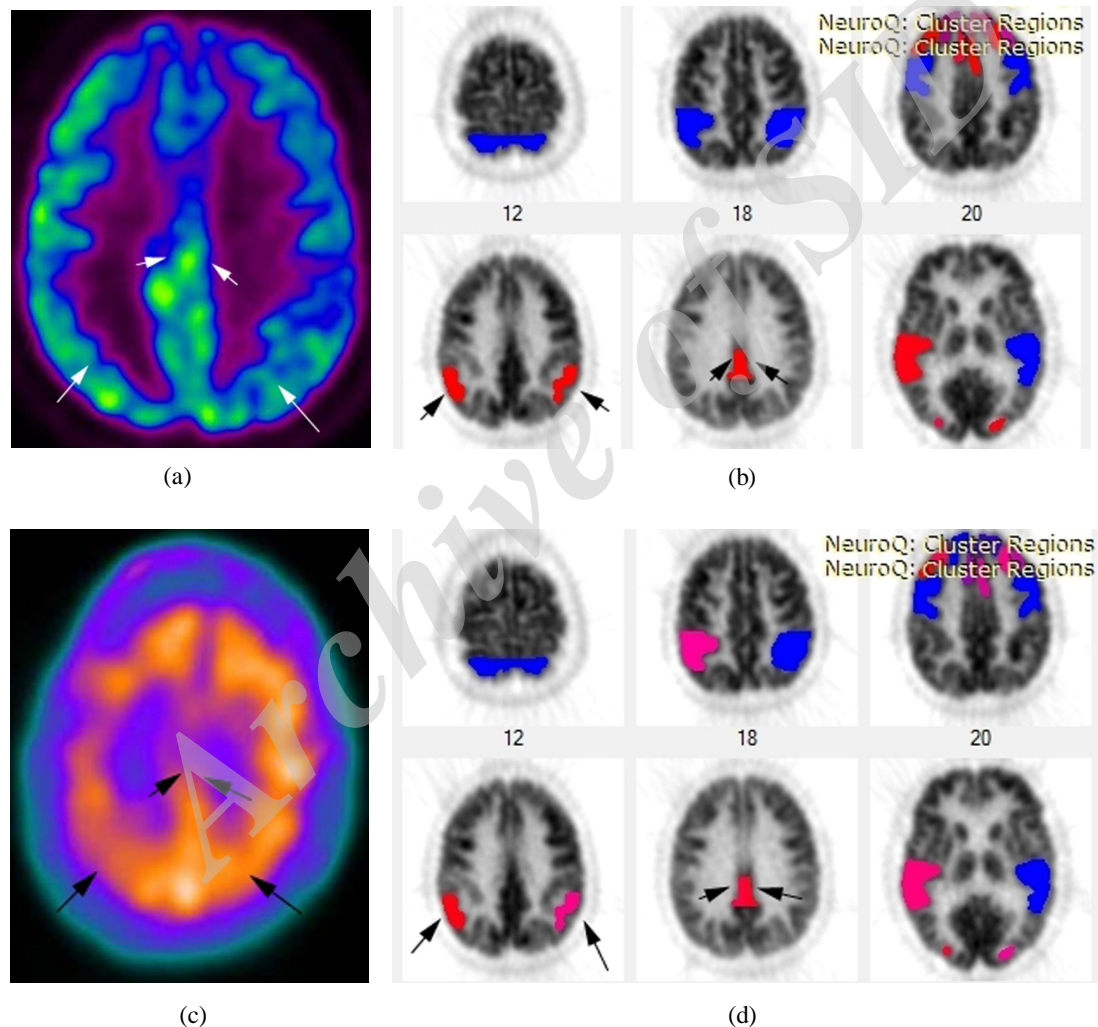


Fig 1. ^{18}F -FDG PET axial colored image (a) showing decreased FDG uptake in both posterior parietal (PP) and posterior cingulate nuclei (PCN) Neuro Q analysis colored image (b) showed hypometabolism in the PP regions as well as the PCN (red colored and arrowed) < 3 SD, (c) HMPAO SPECT axial image showing hypoperfused zones in the PP and PCN (d) Neuro Q analysis colored image showing hyperperfused right PP (red colored) < 3 SD, hypoperfused left PP < 2 SD (purple colored) and hypoperfused PCN < 4 SD.

(SD = standard deviation; blue = normal metabolism; violet < 1 SD; purple < 2 SD and red < 3 SD).

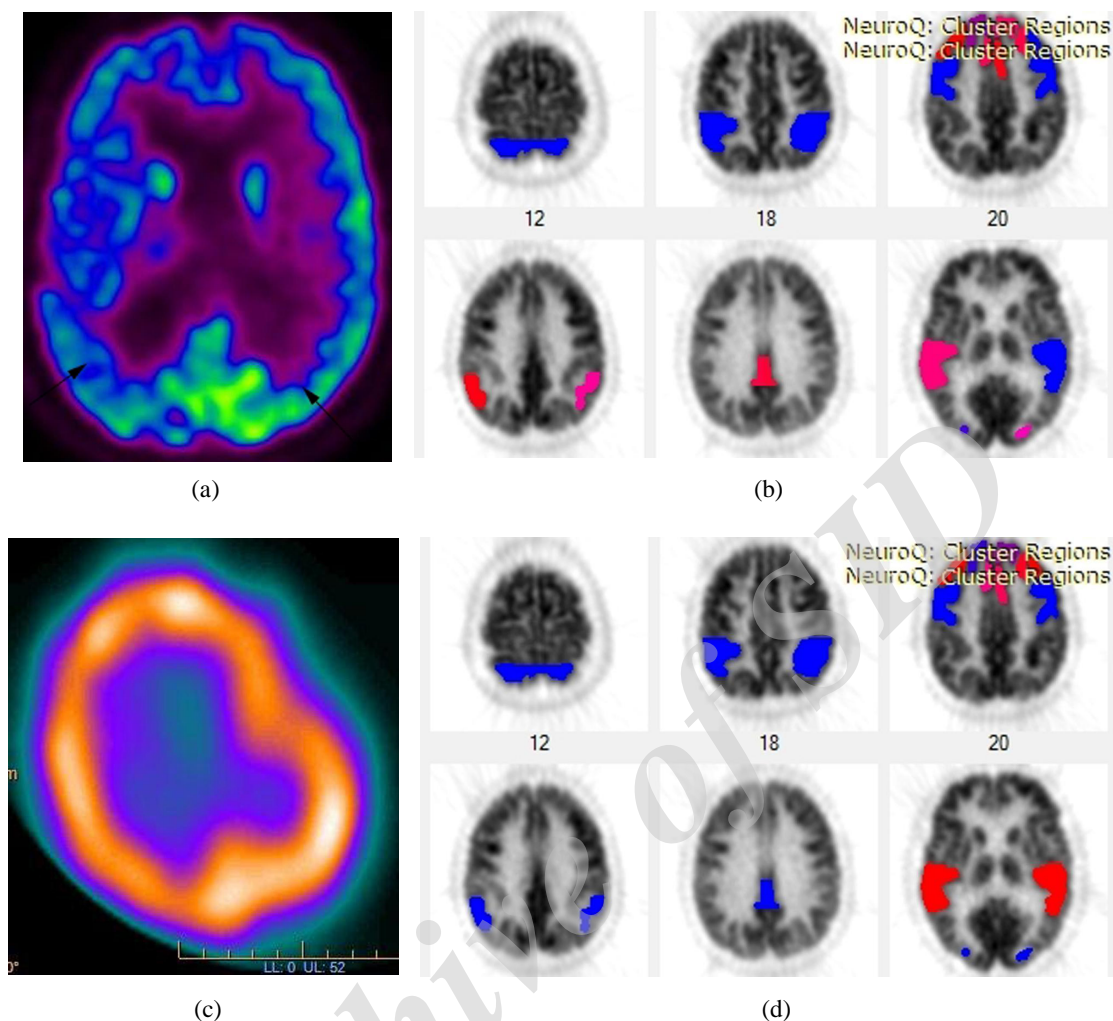


Fig 2. ¹⁸F-FDG PET axial colored image (a) showing decreased ¹⁸F-FDG uptake in both posterior parietal (PP) and posterior cingulate nuclei (PCN) more to the right side, Neuro Q analysis colored image (b) showed hypometabolism in the right PP regions as well as the PCN (red colored and arrowed) < 3 SD, and <2 SD on the left PP (purple colored) (c) ^{99m}Tc-HMPAO SPECT axial image showing no hypoperfused zones in the PP and PCN (d) Neuro Q analysis colored image showing no hypoperfused zones (blue colored).

Table 1: Demographic and diagnostic findings of the patients.

N	Age	Sex	SPECT (hypoperfusion)	PET/CT (hypometabolism)
1	60	M	+	+
2	70	M	+	+
3	68	M	-	+
4	59	F	+	+
5	66	F	-	-
6	80	F	-	-
7	56	F	+	+
8	71	F	+	+
9	61	M	+	-
10	65	M	+	+
11	72	M	-	+
12	54	F	-	+
13	62	M	+	+
14	71	M	+	+
15	58	F	-	-
16	69	M	+	+
17	65	M	-	+
18	73	M	+	+
19	77	F	-	-
20	63	M	+	+
21	68	F	+	+
22	79	F	+	+
23	57	M	+	+
24	62	M	+	+

To assess the difference between both examination the chi-square test were done which showed statistically significance difference between both studies ($P < 0.027$) and Cohen's kappa was 0.415.

DISCUSSION

Progressive memory loss and impairment of cognitive functions, due to progressive neuronal loss and gliosis in parietal cortex propagating to other regions are conclusive for Alzheimer's dementia. An early detection of AD is imperative on the grounds that symptomatic medical treatment turned out to be more compelling in the early periods of the disease that can alter the side effects progression.

Our study assess the difference between FDG PET and HMPAO SPECT to analyze AD and identify the

superiority of FDG PET over HMPAO SPECT perfusion in diagnosis of AD.

Multiple studies previously contrasted FDG PET and HMPAO SPECT to analyze AD. Messa et al. examined likely AD patients and typical controls [5]. Their outcomes demonstrated that the two techniques show comparable capacities to demonstrate the diminished tracer uptake in the parietal region with comparable symptomatic precision. ¹⁸F-FDG PET was more precise than HMPAO SPECT in showing frontal cortex biological abnormalities. PET and SPECT could distinguish AD patients from ordinary controls.

Mielke et al. found that metabolic PET imaging differentiated AD patients from normal controls and was slightly better than HMPAO SPECT using comparison between perfusion and metabolic ratios by receiver operating characteristic curves (ROC) [6]. Herholz et al. utilized voxel-based investigation as a part of looking at AD patients having slight or moderate manifestations and normal controls [7]. Results demonstrated solid correspondence of SPECT and FDG PET in parietal cortex and weaker one in the cerebellum and frontal regions. This was credited to different attenuation correction capabilities and spatial resolution of the both methods.

Dobert et al. utilizing visual and ROI examination reported that sensitivity and specificity of metabolic imaging in recognizing early dementia was 91% and 89%, individually, while perfusion imaging showed 64% and 89%, separately, particularly in patients with motor cognitive impairment (MCI) [8].

Silverman et al. directed the biggest study on pathologically affirmed AD patients (n = 146), reporting that brain PET had a sensitivity of 94% and specificity of 73% in determination of AD [9]. Hoffman et al. [10] and Jagust et al. [11] discovered sensitivities somewhere around 84% and 93% with specificities somewhere around 63% and 74%, respectively.

A meta-analysis was studied by Bloudek et al. including analytic imaging in AD somewhere around 1990 and 2010. Twenty studies researching the utilization of metabolic PET imaging in the diagnosis of AD from normal controls indicated pooled sensitivity of 90% and specificity of 89% [12].

Jagust et al. demonstrated a sensitivity of 86% and specificity of 73% for SPECT in separating AD from controls [13]. A further clinical-pathological study taking a gander at 70 patients with dementia took after to post-mortem examination demonstrated SPECT expanded the exactness of findings. A clinical finding alone was connected with an 84% rate histopathology; this was raised to 92% with a positive SPECT. Those with a conceivable AD

analysis demonstrated a 67% accuracy, which was expanded to 84% with a positive perfusion imaging. The general sensitivity for SPECT in diagnosing AD in subjects with pathological confirmation was sensitivity 63% with specificity of 82%.

SPECT stays less expensive and all the more promptly accessible than PET, and whether services should switch to FDG PET scans at added cost is not clear. PET is prone to be progressively accessible at numerous centers, and expenses are lessening [14]. There have been attempts to examine the cost effectiveness of PET and SPECT in diagnosing AD with differing results. McMahon's paper thought about expenses and quality-balanced life year's associated with utilization of PET and SPECT in Alzheimer's detection [15].

It is hard to draw conclusions from this paper the same number of estimations are utilized, and the modalities were compared with practical MRI that to date is not consolidated in symptomatic rules. They summarized that any advantages from PET would be constrained at high cost however found that SPECT created less advantages at higher expenses. A different study looking at a conventional approach for AD conclusion against a methodology joining PET found that the option of PET enhanced diagnostic precision and did not add to the general costs [16].

Our results correlated with much of the above researches. Yet the cost effectiveness of using PET as key stage in routine workup of AD need further assessment.

CONCLUSION

¹⁸F-FDG PET proved to be more effective in diagnosis of Alzheimer's dementia than ^{99m}Tc-HMPAO SPECT perfusion.

REFERENCES

1. Gallucci M, Limbucci N, Catalucci A, Caulo M. Neurodegenerative diseases. *Radiol Clin North Am.* 2008 Jul;46(4):799-817.
2. Jack CR Jr, Albert MS, Knopman DS, McKhann GM, Sperling RA, Carrillo MC, Thies B, Phelps CH. Introduction to the recommendations from the National Institute on Aging-Alzheimer's Association workgroups on diagnostic guidelines for Alzheimer's disease. *Alzheimers Dement.* 2011 May;7(3):257-62.
3. Pupi A, Nobili FM. PET is better than perfusion SPECT for early diagnosis of Alzheimer's disease -- against. *Eur J Nucl Med Mol Imaging.* 2005 Dec;32(12):1466-72.
4. Silverman DH. Brain ¹⁸F-FDG PET in the diagnosis of neurodegenerative dementias: comparison with perfusion SPECT and with clinical evaluations lacking nuclear imaging. *J Nucl Med.* 2004 Apr;45(4):594-607.
5. Messa C, Perani D, Lucignani G, Zenorini A, Zito F, Rizzo G, Grassi F, Del Sole A, Franceschi M, Gilardi MC. High-resolution technetium-99m-HMPAO SPECT in patients with probable Alzheimer's disease: comparison

- with fluorine-18-FDG PET. *J Nucl Med.* 1994 Feb;35(2):210-6.
6. Mielke R, Pietrzyk U, Jacobs A, Fink GR, Ichimiya A, Kessler J, Herholz K, Heiss WD. HMPAO SPET and FDG PET in Alzheimer's disease and vascular dementia: comparison of perfusion and metabolic pattern. *Eur J Nucl Med.* 1994 Oct;21(10):1052-60.
 7. Herholz K, Schopphoff H, Schmidt M, Mielke R, Eschner W, Scheidhauer K, Schicha H, Heiss WD, Ebmeier K. Direct comparison of spatially normalized PET and SPECT scans in Alzheimer's disease. *J Nucl Med.* 2002 Jan;43(1):21-6.
 8. Döbert N, Pantel J, Frölich L, Hamscho N, Menzel C, Grünwald F. Diagnostic value of FDG-PET and HMPAO-SPET in patients with mild dementia and mild cognitive impairment: metabolic index and perfusion index. *Dement Geriatr Cogn Disord.* 2005;20(2-3):63-70.
 9. Silverman DH, Small GW, Chang CY, Lu CS, Kung De Aburto MA, Chen W, Czernin J, Rapoport SI, Pietrini P, Alexander GE, Schapiro MB, Jagust WJ, Hoffman JM, Welsh-Bohmer KA, Alavi A, Clark CM, Salmon E, de Leon MJ, Mielke R, Cummings JL, Kowell AP, Gambhir SS, Hoh CK, Phelps ME. Positron emission tomography in evaluation of dementia: Regional brain metabolism and long-term outcome. *JAMA.* 2001 Nov 7;286(17):2120-7.
 10. Hoffman JM, Welsh-Bohmer KA, Hanson M, Crain B, Hulette C, Earl N, Coleman RE. FDG PET imaging in patients with pathologically verified dementia. *J Nucl Med.* 2000 Nov;41(11):1920-8.
 11. Jagust W, Reed B, Mungas D, Ellis W, Decarli C. What does fluorodeoxyglucose PET imaging add to a clinical diagnosis of dementia? *Neurology.* 2007 Aug 28;69(9):871-7.
 12. Bloudek LM, Spackman DE, Blankenburg M, Sullivan SD. Review and meta-analysis of biomarkers and diagnostic imaging in Alzheimer's disease. *J Alzheimers Dis.* 2011;26(4):627-45.
 13. Jagust W, Thisted R, Devous MD Sr, Van Heertum R, Mayberg H, Jobst K, Smith AD, Borys N. SPECT perfusion imaging in the diagnosis of Alzheimer's disease: a clinical-pathologic study. *Neurology.* 2001 Apr 10;56(7):950-6.
 14. Herholz K, Westwood S, Haense C, Dunn G. Evaluation of a calibrated (18)F-FDG PET score as a biomarker for progression in Alzheimer disease and mild cognitive impairment. *J Nucl Med.* 2011 Aug;52(8):1218-26.
 15. McMahon PM, Araki SS, Sandberg EA, Neumann PJ, Gazelle GS. Cost-effectiveness of PET in the diagnosis of Alzheimer disease. *Radiology.* 2003 Aug;228(2):515-22.
 16. Silverman DH, Gambhir SS, Huang HW, Schwimmer J, Kim S, Small GW, Chodosh J, Czernin J, Phelps ME. Evaluating early dementia with and without assessment of regional cerebral metabolism by PET: a comparison of predicted costs and benefits. *J Nucl Med.* 2002 Feb;43(2):253-66.

Archive of SPECT