

Intestinal duplication with ectopic gastric mucosa diagnosed by Meckel's diverticulum scan

AVS Anil Kumar¹, PG Kumar¹, Karunesh Chand²

¹Department of Nuclear Medicine, Command Hospital, Pune, India

²Department of Paediatric surgery, Command Hospital, Pune, India

(Received 1 July 2016, Revised 26 July 2016, Accepted 27 July 2016)

ABSTRACT

Gastrointestinal duplications are rare congenital malformations and they may vary greatly in presentation, size, location and symptoms. The presence of ectopic gastric mucosa (EGM) in them is not common and they are difficult to diagnose prior to surgery. We present the case of a child with long intestinal duplication with ectopic gastric mucosa who presented with just severe anemia and delayed milestones without any history of evident bleeding or abdominal symptoms and was accurately diagnosed prior to surgery with Meckel's scan. The case highlights the importance of the simple pertechnetate Meckel's scan in the imaging armamentarium involved in the evaluation of such cases.

Key words: Meckel's scan; Pertechnetate; Intestinal duplication

Iran J Nucl Med 2017;25(1):73-76

Published: January, 2017

<http://irjnm.tums.ac.ir>

Corresponding author: Dr AVS Anil Kumar, Department of Nuclear Medicine, Command Hospital, Pune, India. E-mail: avsanil2002@yahoo.com

INTRODUCTION

Ectopic gastric mucosa is the leading cause of severe GI bleeding in children. Meckel's diverticulum is the most common site. Uncommon sites are intestinal duplication and the small bowel proper. Intestinal duplications vary greatly in their presentation and are often difficult to diagnose prior to surgery. Meckel's scan is extremely useful in detection of ectopic gastric mucosa when present in such cases. We present the case of a 2.5 year old child who presented with severe anaemia and was detected to have intestinal duplication with ectopic gastric mucosa that was successfully diagnosed prior to surgery using Meckel's scan.

CASE REPORT

A 2.5 years old boy was brought with history of failure to thrive of one year duration. History of poor feeding, and delayed milestones for age were present. There was no history of fever, cough, haematochezia, melena, hematemesis, haemoptysis, cyanotic spells or any congenital abnormality. Examination revealed a poorly nourished child, unable to stand without support and seeking mother's attention. Height and weight for age were < 50th percentile. Marked pallor was present, there was no icterus, purpura, ecchymosis, cyanosis, clubbing or lymphadenopathy present. Abdominal examination revealed no abnormality. His Cardio-vascular, Respiratory and Neurological examination were all normal.

Investigations revealed a Hemoglobin 2.8gm %, peripheral blood smear showed microcytic hypochromic anemia with no evidence of hemolysis, Total WBC count- 10,900/mm³ with lymphocyte predominance, Platelet count – 460,000/ mm³, serum bilirubin – 0.9 mg/dl, Urine Bile Salts and Pigments – Negative, Serum Iron 20µg/dl, TIBC- 512 µg/dl, Transferrin Saturation-13% and USG abdomen was normal, Stool for occult blood was repeatedly positive. He was subjected to Upper GI endoscopy which was normal. Contrast enhanced CT scan (CECT) of abdomen and pelvis revealed a normal study. He underwent a Meckel's Scan. The scan was done by injecting 37 MBq (1 mCi) of 99mTcO₄⁻ (pertechnetate) IV and multiple static anterior and posterior images of 500k counts each were taken for 30 minutes. The scan revealed instant uptake of the tracer in the whole left side of abdomen that was seen simultaneously with the gastric uptake and increased in intensity over time - suggestive of ectopic gastric mucosa in large areas of small intestine (Figure 1). Hence a preoperative diagnosis of duplication of small bowel with ectopic gastric mucosa was made. The Child was given multiple blood transfusions and Hemoglobin was built up to 10gm% prior to surgery. Exploratory laparotomy was performed and a 110 cm

of intestinal duplication starting from 60 cm distal to duodeno-jejunal junction was detected (Figure 2).

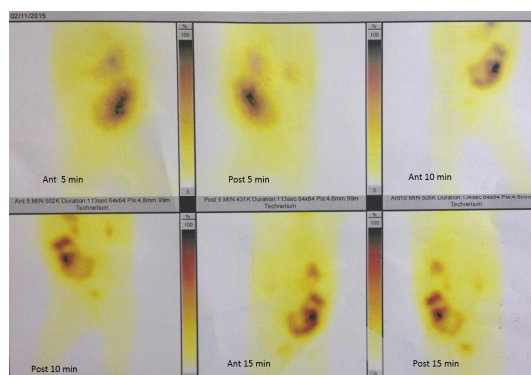


Fig 1. Meckel's scan showing large uptake in whole left side of abdomen. Anterior and posterior images of the abdomen shown at 5 min, 10 min and 15 min post injection.

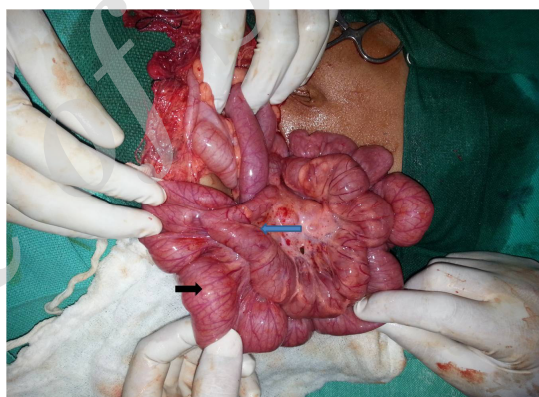


Fig 2. Per operative finding - Normal bowel (black arrow), duplicated bowel (blue arrow).

A sealed perforation was seen in duplicated bowel at its terminal end (Figure 3). The initial 50cm of duplicated bowel did not have a common wall with native bowel. Last 60 cm shared a common wall with the native bowel. Complete resection of the duplication was carried out (Figure 4). Pathological examination of the sections revealed mucosa, submucosa and either absent or atrophic muscularis propria. The mucosa was lined by gastric foveolar lining with paucity of goblet cells and normal gastric glands. The findings consistent with complete jejunoileal duplication with heterotrophic gastric mucosa. Post-op status was uneventful.

Patient has been on regular follow-up and his delayed milestones are on the road to recovery. His nutrition state has improved, there has been no recurrence of anemia and the child is thriving well.

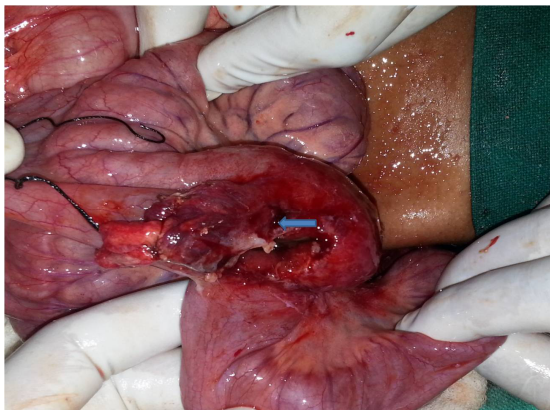


Fig 3. Sealed perforation seen at the terminal end of duplicated bowel (blue arrow).

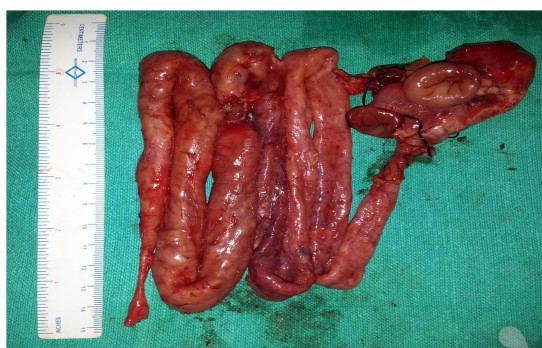

Fig 4. The resected duplication.

DISCUSSION

Gastrointestinal duplications are rare congenital malformations that may vary greatly in presentation, size, location and symptoms [1]. They may present as painless bleeding or with intestinal obstruction or palpable mass. Most of the small intestinal duplications present with intestinal obstruction. Our case presented with severe anaemia and delayed milestones but there was no history of any bleeding, distension of abdomen or pain. The presence of ectopic gastric mucosa (EGM) in intestinal duplications is not very common. It has been reported between 17 – 36% [2]. However, when they are present, they cause severe bleeding. It needs high index of suspicion for detection of intestinal duplications as they are only rarely diagnosed prior to surgery accurately [3]. Commonly used imaging modalities for intestinal duplications are ultrasonography, CT scan and MRI. However these modalities are unable to pick up presence of EGM [4]. Meckel's scan can accurately detect presence of EGM and hence is an extremely useful non-invasive investigation which can localize the site and cause of

bleeding in such cases [5]. Meckel's scan is done by injecting Tc-99m pertechnetate IV and obtaining images for 90 minutes. Normally this tracer is taken up by gastric mucosa, thyroid and salivary glands. A positive scan shows ectopic focus of uptake in the abdomen which occurs simultaneously with stomach uptake and becomes hotter over time. Both Meckel's diverticulum and intestinal duplication are to be considered in positive cases, as both will take up the tracer if EGM is present [6]. In case of intestinal duplications, the uptake may be irregular and can occur even before the stomach shows uptake [7]. In our case, there was uptake seen in whole of the left abdomen occurring simultaneously with the stomach uptake and increasing in intensity over time, hence pointing towards a diagnosis of long intestinal duplication. The sensitivity of detection of EGM in duplication cysts has been found to be around 75% [8]. Many authors have advocated the use of cimetidine or pentagastrin to improve the accuracy of detection of EGM [9]. In our case we have not used any pharmacological intervention. Sometimes repeated scans are required to detect small areas of ectopic mucosa which go undetectable or if Barium studies have been done previously where in the retained Barium will interfere with the detection [5]. However in our case it was a 110 cm of duplication with ectopic mucosa and all of it lit up in the scan.

The per-operative finding was a 110 cm of bowel duplication, beginning 60 cm from the duodeno-jejunal junction ending 40 cm short of the ileocecal junction, communicating with the terminal ileum and a sealed perforation was seen in duplicated bowel at its terminal end. Usually the intestinal duplications vary in length from few to several centimeters and occasionally the entire length [10]. Our case had a total 110 cm of duplication. Unusual part of the case was that perforation was present without any peritonitis or any previous symptoms of pain abdomen.

There is higher incidence of associated anomalies in such cases in the form of vertebral and urinary tract anomalies, malrotation and atresia. Rarely malignant transformation can occur in HGM within the duplication [11]. However, in our case there was no associated anomaly.

CONCLUSION

This case highlights the importance of Meckel's scan in the preoperative diagnosis of intestinal duplications with EGM.

REFERENCES

1. Karnak I, Ocal T, Senocak ME, Tanyel FC, Büyükpamukçu N. Alimentary tract duplications in

- children: report of 26 years' experience. *Turk J Pediatr.* 2000 Apr-Jun;42(2):118-25.
2. Tong SC, Pitman M, Anupindi SA. Best cases from the AFIP. Ileocecal enteric duplication cyst: radiologic-pathologic correlation. *Radiographics.* 2002 Sep-Oct;22(5):1217-22.
 3. Brown RL, Azizkhan RG. Gastrointestinal bleeding in infants and children: Meckel's diverticulum and intestinal duplication. *Semin Pediatr Surg.* 1999 Nov;8(4):202-9.
 4. Hur J, Yoon CS, Kim MJ, Kim OH. Imaging features of gastrointestinal tract duplications in infants and children: from oesophagus to rectum. *Pediatr Radiol.* 2007 Jul;37(7):691-9.
 5. Emamian SA, Shalaby-Rana E, Majd M. The spectrum of heterotopic gastric mucosa in children detected by Tc-99m pertechnetate scintigraphy. *Clin Nucl Med.* 2001 Jun;26(6):529-35.
 6. Satya R, O'Malley JP. Case 86: Meckel diverticulum with massive bleeding. *Radiology.* 2005 Sep;236(3):836-40.
 7. Kiratli PO, Aksoy T, Bozkurt MF, Orhan D. Detection of ectopic gastric mucosa using 99mTc pertechnetate: review of the literature. *Ann Nucl Med.* 2009 Feb;23(2):97-105.
 8. Kumar K, Dhull VS, Karunanithi S, Chakraborty PS, Roy SG, Ghosh S, Agarwala S, Tripathi M. Synchronous thoracic and abdominal enteric duplication cysts: Accurate detection with (99m)Tc-pertechnetate scintigraphy. *Indian J Nucl Med.* 2015 Jan-Mar;30(1):59-61.
 9. Diamond RH, Rothstein RD, Alavi A. The role of cimetidine-enhanced technetium-99m-pertechnetate imaging for visualizing Meckel's diverticulum. *J Nucl Med.* 1991 Jul;32(7):1422-4.
 10. Bhattacharya A, Samujh R, Rao KL, Mittal BR. Long segment jejuno-ileal duplication cyst with ectopic gastric mucosa detected on 99mTc-pertechnetate scintigraphy. *Indian J Nucl Med.* 2013 Apr;28(2):96-8.
 11. Lee NK, Kim S, Jeon TY, Kim HS, Kim DH, Seo HI, Park DY, Jang HJ. Complications of congenital and developmental abnormalities of the gastrointestinal tract in adolescents and adults: evaluation with multimodality imaging. *Radiographics.* 2010 Oct;30(6):1489-507.

Archive of SID