

Meningioma: A false positive finding of metastasis from prostate adenocarcinoma using ^{68}Ga -PSMA PET/CT scan

Atena Aghaei¹, Kamran Aryana¹, Roham Salek², Seyed Rasoul Zakavi¹, Hojjat Ahmadzadefar³

¹Nuclear Medicine Research Center, Mashhad University of Medical Sciences, Mashhad, Iran

²Cancer Research Center, Mashhad University of Medical Sciences, Mashhad, Iran

³Department of Nuclear Medicine, University Hospital Bonn, Bonn, Germany

(Received 4 April 2018, Revised 10 July 2018, Accepted 11 July 2018)

ABSTRACT

A 73-year-old man with history of prostatic adenocarcinoma radical prostatectomy underwent $^{99\text{m}}\text{Tc}$ -MDP whole-body bone scan and subsequent ^{68}Ga -labeled prostate-specific membrane antigen (PSMA) ligand PET/CT for restaging due to a gradual rise of prostate-specific antigen levels. Whole-body bone scan showed two focal zones of slightly increased uptake in the right fronto-parietal and temporal bones. ^{68}Ga -PSMA PET/CT scan showed local recurrence in the prostatic bed and two foci of slightly increased uptake in the right temporal and fronto-parietal lobes. A brain CT scan, with IV contrast confirmed that foci of increased uptake in the temporal and parietal lobes were consistent with typical meningioma.

Key words: Meningioma; ^{68}Ga -PSMA; Prostate cancer; Bone scan

Iran J Nucl Med 2019;27(1):53-56

Published: January, 2019

<http://irjnm.tums.ac.ir>

Corresponding author: Dr. Atena Aghaei, Nuclear Medicine Research Center, Mashhad University of Medical Sciences, Mashhad, Iran. E-mail: aghaceat@mums.ac.ir

CASE HISTORY

A 73-year-old man, with prostate cancer, who underwent radical prostatectomy 10 years ago, was referred to our center for whole-body bone scan with $^{99\text{m}}\text{Tc}$ -methylene diphosphonate ($^{99\text{m}}\text{Tc}$ -MDP). His serum prostate-specific membrane antigen (PSA) value had risen gradually starting four years ago, with a PSA doubling-time of about one year. His last serum PSA was 2.56 ng/ml.

Whole-body bone scan was performed with a dual-head Siemens gamma camera (e-cam), which showed two focal zones of increased tracer uptake in the skull (right fronto-parietal and temporal bones (Figure 1).

Later, a ^{68}Ga -labeled prostate-specific membrane antigen (PSMA) ligand positron emission tomography/computed tomography (PET/CT) scan was performed, which showed two foci of tracer activity in the brain, localized in the right fronto-parietal and temporal lobes (Figures 2 and 3). There was also a zone of increased activity in the left prostatic bed.

Neurosurgery consultation was ordered for possibility of cranial surgery in order to excise the suspicious metastatic lesions.

A brain CT scan was performed for surgery planning. The brain CT scan showed two focal round areas of homogeneously increased enhancement in the right fronto-parietal and temporal lobes, which is typical of the appearance of meningioma, with no evidence of adjacent bone destruction (Figures 4, 5, 6). Thus,

cranial surgery was cancelled and radiotherapy of the prostatic bed was planned.

DISCUSSION

PSMA is a cell surface protein with high expression in prostate carcinoma cells and also a variety of other malignant and benign tumors [1-3]. But despite its expression by subsets of various types of malignancies, PSMA is still considered to be highly sensitive and specific for detecting prostatic cells. ^{68}Ga -PSMA PET/CT scan is used for staging, restaging and treatment planning of patients with prostate cancer [4-6].

This case demonstrates that meningioma can be a false positive finding in either $^{99\text{m}}\text{Tc}$ -MDP bone scan or ^{68}Ga -PSMA PET/CT scan.

There are few case reports of increased ^{68}Ga -PSMA uptake in meningioma that may be mistaken as a foci of metastasis. Brain MRI is useful in differential diagnosis and may confirm meningioma with typical MRI findings [7].

Meningiomas are among the most common tumors of the central nervous system. They consist about 19% of intracranial and 25% of spinal tumors [8]. They often contain steroid hormone receptors and the presence of progesterone receptors (PRs). Even in a small number of tumor cells, have been shown to be a favorable prognostic factor for meningioma [9, 10].

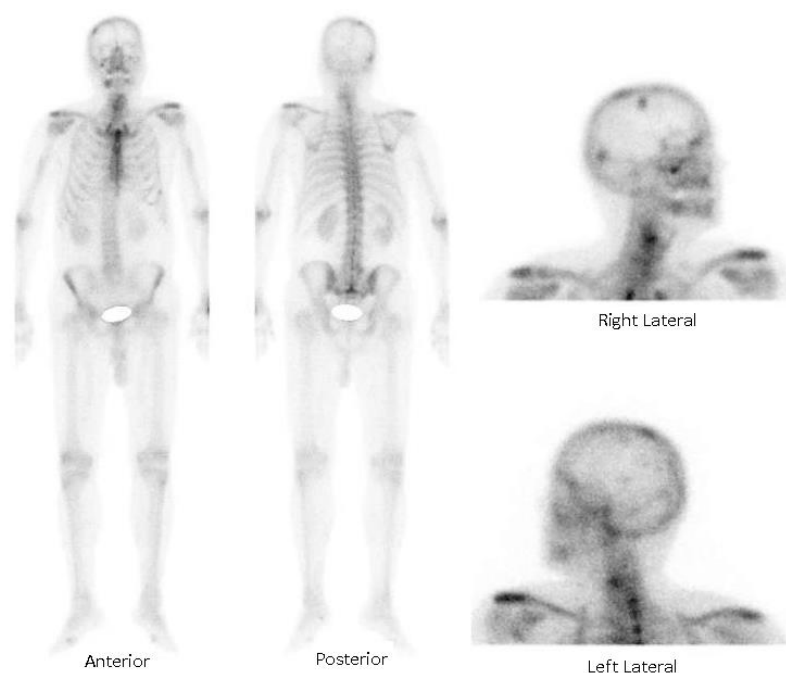


Fig 1. Whole-body bone scan with $^{99\text{m}}\text{Tc}$ -methylene diphosphonate ($^{99\text{m}}\text{Tc}$ -MDP).

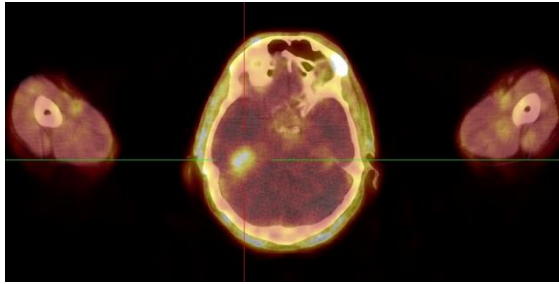


Fig 2. ⁶⁸Ga-PSMA PET/CT scan –skull, showing a mass in the right parieto-temporal region, which has low SUV(SUV max=1.83).

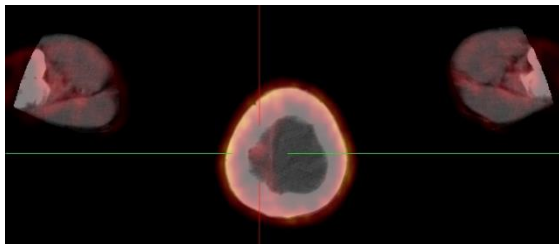


Fig 3. ⁶⁸Ga-PSMA PET/CT scan- skull, showing a small mass in the right fronto-parietal region.

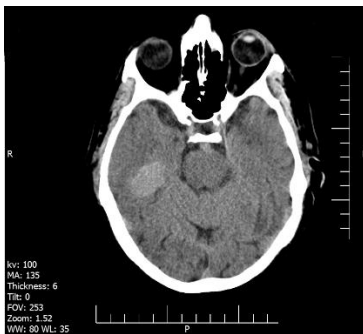


Fig 4. Brain CT scan, without contrast, showing the bigger meningioma,(right temporo-parietal calcified meningioma).

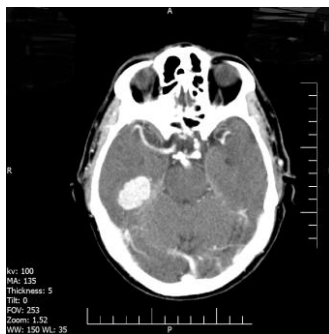

Fig 5. Brain CT scan, with IV contrast- showing the mentioned meningioma, in the right temporo-parietal region, with homogenous enhancement and well defined borders.

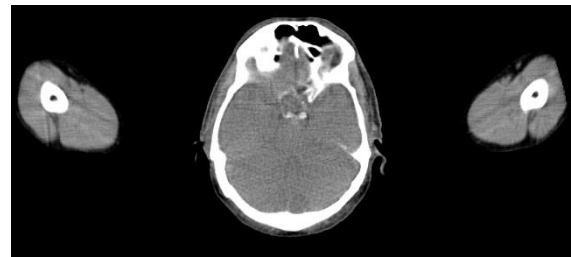

Fig 6. Brain CT scan, bone window- showing homogenous borders of the skull bones, without evidence of bone destruction, the usual pattern of meningioma.

There are no histopathological studies, to-date, evaluating the presence of PSMA receptors in meningioma. This case report suggests that meningioma may express PSMA receptors, and it may be mistaken as brain metastasis in PSMA imaging. Histopathologic diagnosis is mandatory if MRI findings was not typical of meningioma [11].

REFERENCES

1. Sathegke M, Modiselle M, Vorster M, Mokgoro N, Nyakale N, Mokaleng B, Ebenhan T. ⁶⁸Ga-PSMA imaging of metastatic breast cancer. *Eur J Nucl Med Mol Imaging*. 2015 Aug;42(9):1482-3.
2. Artigas C, Otte FX, Lemort M, van Velthoven R, Flamen P. Vertebral hemangioma mimicking bone metastasis in ⁶⁸Ga-PSMA ligand PET/CT. *Clin Nucl Med*. 2017 May;42(5):368-370.
3. Spatz S, Tolkach Y, Jung K, Stephan C, Busch J, Ralla B, Rabien A, Feldmann G, Brossart P, Bundschuh RA, Ahmadzadehfar H, Essler M, Toma M, Müller SC, Ellinger J, Hauser S, Kristiansen G. Comprehensive evaluation of prostate specific membrane antigen expression in the vasculature of renal tumors: Implications for imaging studies and prognostic role. *J Urol*. 2018 Feb;199(2):370-377.
4. Afshar-Oromieh A, Holland-Letz T, Giesel FL, Kratochwil C, Mier W, Haufe S, Debus N, Eder M, Eisenhut M, Schäfer M, Neels O, Hohenfellner M, Kopka K, Kauczor HU, Debus J, Haberkorn U. Diagnostic performance of ⁶⁸Ga-PSMA-11 (HBED-CC) PET/CT in patients with recurrent prostate cancer: evaluation in 1007 patients. *Eur J Nucl Med Mol Imaging*. 2017 Aug;44(8):1258-1268.
5. Ahmadzadehfar H, Azgomi K, Hauser S, Wei X, Yordanova A, Gaertner FC, Kürpig S, Strunk H, Essler M. ⁶⁸Ga-PSMA-11 PET as a Gatekeeper for the Treatment of Metastatic Prostate Cancer with ²²³Ra: Proof of Concept. *J Nucl Med*. 2017 Mar;58(3):438-444.
6. Ahmadzadehfar H, Schlenkhoff CD, Rogenhofer S, Yordanova A, Essler M. ⁶⁸Ga-PSMA-11 PET Represents the Tumorcidal Effect of ²²³Ra in a Patient With Castrate-Resistant Metastatic Prostate Cancer. *Clin Nucl Med*. 2016 Sep;41(9):695-6.
7. Bilgin R, Ergül N, Çermik TF. Incidental meningioma mimicking metastasis of prostate adenocarcinoma in ⁶⁸Ga-labeled PSMA ligand PET/CT. *Clin Nucl Med*. 2016 Dec;41(12):956-958.

8. Jain TK, Jois AG, Kumar VS, Singh SK, Kumar R, Mittal BR. Incidental detection of tracer avidity in meningioma in ⁶⁸Ga-PSMA PET/CT during initial staging for prostate cancer. *Rev Esp Med Nucl Imagen Mol.* 2017 Mar - Apr;36(2):133-134.
9. Jääskeläinen J. Seemingly complete removal of histologically benign intracranial meningioma: late recurrence rate and factors predicting recurrence in 657 patients. A multivariate analysis. *Surg Neurol.* 1986 Nov;26(5):461-9.
10. Hsu DW, Efird JT, Hedley-Whyte ET. Progesterone and estrogen receptors in meningiomas: prognostic considerations. *J Neurosurg.* 1997 Jan;86(1):113-20.
11. Sheikhabaei S, Afshar-Oromieh A, Eiber M, Solnes LB, Javadi MS, Ross AE, Pienta KJ, Allaf ME, Haberkorn U, Pomper MG, Gorin MA, Rowe SP. Pearls and pitfalls in clinical interpretation of prostate-specific membrane antigen (PSMA)-targeted PET imaging. *Eur J Nucl Med Mol Imaging.* 2017 Nov;44(12):2117-2136.