

The Study of Histological Effects of Solder Fumes in Rat Lungs

*¹Mohammad Reza Arab, ²Ramezan Mirzaei, ³Mehrbod Karimi, ⁴Rezvaneh Mashhadi

Abstract

Objective(s)

To determine the potential toxic effects of manual soldering flux cored solder wire on lung of the rat as an experimental model.

Materials and Methods

A total number of 48 adult male rats were divided into experimental (n= 30) and control (n= 18) groups. Based on exposure time to solder fume, each group was further subdivided into 2, 4 and 6 week subgroups. Rats of experimental groups were exposed to fume in exposure chamber for 1 hour/day (Research Center of Zahedan University of Medical Sciences, 12 Apr 2005 to 14 May 2005). The amount of fumes were measured daily by standard methods. At the end of experiment, lung specimens were collected from each experimental and control subgroups. Tissue samples were processed routinely and thickness of epithelium in bronchioles and interalveolar septas were measured in stained microscopic slides. Obtained data were analyzed by SPSS.

Results

Statistical analysis of data for thickness of epithelium in bronchioles showed that there was only a significant difference between 4 week experimental and control subgroups ($P < 0.001$). Analysis of data for thickness of interalveolar septa showed statistically significant differences between experimental and control subgroups of 4 and 6 weeks ($P < 0.001$). Histological examination was also revealed an inflammatory process in bronchioles and disorganized architecture in alveoli of lung in experimental subgroups.

Conclusion

The result showed that solder fume can change the normal architectures of epithelium in bronchioles and alveoli of the lung and it seems that the severities of changes were dependent on the exposure time.

Keywords: Bronchiole, Pulmonary alveoli, Rat, Soldering flux

1- Cell and Molecule research center, Faculty of Medicine, Zahedan University of Medical Sciences, Zahedan, Iran

*Corresponding author: Tel: +98-5413414569; Fax: +98-5413414571; email: mr_arabz@yahoo.com

2- Faculty of Medicine, Zahedan University of Medical Sciences, Zahedan, Iran

3- Department of Pathology, Faculty of Medicine, Zahedan University of Medical Sciences, Zahedan, Iran

4- Imam Ali Hospital, Zahedan University of Medical Sciences, Zahedan, Iran

Introduction

Welding process involves joining metal parts by heating the pieces to melting temperature (1). Soldering process as a type of welding produces various contaminants at a sufficient rate to cause both short term and long term health effects, especially if not properly controlled (2). The metal composition of the generated fume during welding of metals is mostly dependent on the welding electrode or wire which is consumed during the process (3). Based on epidemiologic data more than two million workers worldwide perform welding process as part of their work duties (3). Previous studies showed that 22% of solderers or persons working near solderers were found to be suffering from occupational asthma and other lung diseases (4). One of the main limitations to study the adverse health effects of welding fumes is the variable environmental condition of the work places. This includes different ventilation qualities and also exposure to a number of other toxic materials such as asbestos, smoking, silica and organic solvents (2).

Chronic exposure to welding fumes is also associated with a significant reduction in lung function. There is growing evidence that welding fume exposure may be associated with increased cardiovascular disease. Although the exact mechanisms for cardiovascular disease are unknown, it seems that systemic inflammation resulting from occupational exposure to these fumes may be partly responsible for the increased cardiovascular risk in welders (1). Fumes inhalation exposure for workers in confined and poorly ventilated spaces have been found to exhibit more negative lung function than workers in well ventilated areas (5). The results of a meta analysis by Sjogren and colleagues showed a correlation between stainless steel welding fumes and the occurrence of lung cancer, especially when the two most important confounders namely smoking habits and asbestos exposure have been taken into account (6). The International Agency for Research on Cancer (IGRC) has concluded that welding fumes were possibly carcinogenic to humans, despite the fact that the finding was based on limited evidence in humans and inadequate evidence in laboratory animals (4).

The respiratory effects are often seen in full time welders and include bronchitis, airway irritation, lung function changes, lung fibrosis and possible increase in the incidence of lung cancer (7). *In vivo* studies showed that welding fume is both toxic and mutagenic to mammalian cells (8). It has been estimated that nearly 400000 workers in the United States were employed full time as welders, cutters, solderers and brazers during the year of 2002 (8). Formaldehyde, stannum (Sn) and lead (Pb) are found in solder wire. Formaldehyde as one of the toxic materials evaporated during soldering process is an extremely reactive chemical which after reaction to monoamine or amide, forms methylene bridges with proteins and DNA. It seems that chronic exposure to formaldehyde increases the cancer incidence (9). The aim of the present study was to determine the histological effects of solder fume on rat lung in a controlled media in exposure chamber.

Materials and Methods

A total number of 48 adult male Sprague-Dawley rats weighted 125 ± 15 g obtained from Pasture Institute (Karaj, Iran) were randomly divided into experimental ($n= 30$) and control ($n= 18$) groups. After adaptation to room standard condition (12 hr light/12 hr darkness, 46-50% humidity, 22 ± 2 °C and free access to water and food) each group according to exposure time to fumes were equally subdivided into 2, 4 and 6 week subgroups. Rats of experimental groups were exposed to colophony fumes (whole body exposure) for 1 hr/day (13-14 PM), which were directed into the exposure chamber made of plexy glass. The experiment was done in research center of Zahedan University of Medical Sciences, 12 Apr 2005 to 14 May 2005. The chamber had an internal volume of 0.83 m^3 and fumes were conducted to hood inlet and outlet with 200 cm length, which was ventilated 5-6 times/hr. The speed of manual solder wire was fixed at 5 m/min. Soldering wire (Alloy 36/37 with diameter of 0.8 mm and rosin activated) was commercially available and purchased from Jafre Company. (Iran). The air samples of exposure chamber were collected daily for analysis of fumes by personal chamber (SKC

Histological Effects of Solder Fume

224 EE- UK) using (filter 0.8 pore sizes, 37 mm diameter, Millipore) every 30 min for 1 hr at a flow rate of 2 liter/min. The solder fumes were analyzed for their metal composition and formaldehyde concentration using visible absorption spectrophotometry (Spectronic, 20D, Milton Ray, Belgium) and atomic absorption spectrophotometer (ATI/Unicam, 929 USA) according to the methods described by National Institute of Occupational Safety and Health (NIOSH 3500, OSHA 206 and ASTM D4185-90) (10-12). The temperature of the exposure chamber was maintained at 22 ± 3 °C. The ethics committee of Zahedan University of Medical Sciences (Iran) approved the design of the experiment. In both experimental and control groups at the designated time point, animals were sacrificed by deep anesthesia and lungs (after weighting, A&D) were fixed in neutral formalin saline. Lung tissue samples were processed routinely and prepared microscopic slides (5-7 μm in thickness) were stained with Hematoxylin and Eosin. In prepared sections thickness of the epithelium of bronchioles and interalveolar septa were measured (blindly) after calibration of the microscope by stage micrometer. Sections were also checked for any other histological changes. Weights of the rats for both experimental and control groups were measured before and after the experiment.

Quantitative results are expressed as mean \pm SD. Statistical analyses of data were performed using SPSS software (ver.12) with ANOVA and LSD as Post Hoc test and *P* value less than 0.05 was considered significant.

Results

The results of analysis of the air samples in the exposure chamber showed that the concentration of fumes for stannum (Sn), lead (Pb) and formaldehyde was 0.35 mg/m^3 , 3 mg/m^3 and 0.193 mg/m^3 respectively.

The histological finding showed disorganized architecture of the epithelium in bronchioles in experimental group and there was also infiltration of inflammatory cells in the lamina propria of the bronchioles. There was no normal alveolar pattern in the experimental subgroups. The severity of these changes was especially prominent in 6 week experimental subgroup. Alveolar macrophages were prominent in experimental compared to the control group Figure 1 (A-D). Analysis of data for the epithelial thickness in bronchioles showed only a significant difference between 4 week experimental and its own control subgroup ($P < 0.001$). Furthermore analysis of data for interalveolar septal thickness showed significant difference between 4 and 6 control subgroups and their own experimental subgroups ($P < 0.005$) (Table 1). There was no significant difference between weight of the lung for none of experimental and their control groups. Statistical analysis for the weight of rats before and after the experiment did not show any significant difference between control and experimental groups (Table 1). There were no distinct behavioral changes related to inhalation of solder fumes in experimental subgroups in comparison to controls.

Table 1. Comparison of rats weights, lungs weights, thicknesses of epithelium in bronchioles and interalveolar septum in experimental and control groups after inhalation exposure to solder fumes.

| Variables | Groups | 2 weeks | | 4 weeks | | 6 weeks | |
|--|--------|------------------|------------------|------------------|------------------|------------------|------------------|
| | | control | experimental | control | experimental | control | experimental |
| Lung weights (g) | | 1.82 \pm .17 | 1.82 \pm .29 | 1.87 \pm .12 | 1.84 \pm .18 | 1.92 \pm .23 | 2.06 \pm .17 |
| Rats weights before experiment (g) | before | 128 \pm 12.4 | 121.2 \pm 15.8 | 128.1 \pm 7.3 | 132 \pm 16.9 | 121.1 \pm 20.2 | 131 \pm 14.6 |
| Rats weights after experiment (g) | after | 180.4 \pm 12.2 | 185 \pm 20.5 | 207.1 \pm 17.8 | 225.1 \pm 16.1 | 213.1 \pm 13.8 | 246.2 \pm 21.2 |
| Thickness of epithelial Bronchiole (μm) | | 22 \pm 9.9 | 23.09 \pm 7.61 | 18 \pm 7.4 | 31.5. \pm 10.3 | 21 \pm 6.7 | 23.8 \pm 6.2 |
| Thickness of Inter-alveolar septa (μm) | | 8.9 \pm 3.1 | 9.7 \pm 3.5 | 7.1 \pm 3.2 | 17.9 \pm 6.7 | 10.6 \pm 4.7 | 24.3 \pm 12.6 |

* Significant difference $P < 0.001$, † and ‡ Significant difference $P < 0.005$.

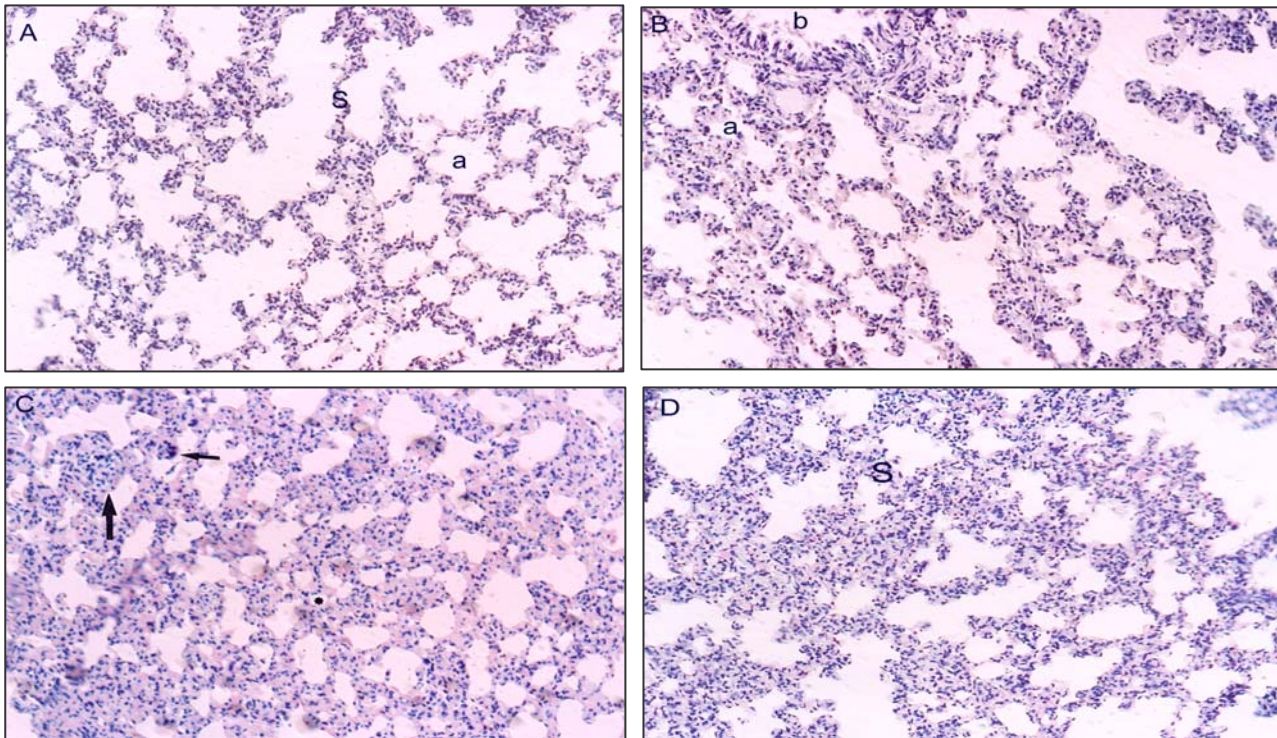


Figure 1. Normal architecture (a) of alveoli and interalveolar septa (s) in control group (A), disorganized architecture of alveoli (a) and cellular and nuclear atypia in bronchiole (b) were shown in experimental groups of 2 week exposure time (B), and small alveoli (*), alveolar macrophages (thin arrow) and diffuse interstitial inflammation (thick arrow) were seen in 4 week (C) and 6 week exposure time (D), increase in thickness of interalveolar septa (S) was evident in 6 week exposure time. H-E staining. Original magnification×200.

Discussion

In the present study an important histological findings in experimental group was the hyperplasia and cellular atypia in bronchioles and disorganized architecture in alveoli. Our data showed an increase in thickness of interalveolar septa in experimental group. Cellular atypia was characterized by variation in cellular/nuclear size and nuclear displacement. All of these changes can be classified as some grades of dysplasia. Fumes, gases and metal particles which are formed by evaporation of the metals-primarily at the tip of electrode or wire- are oxidized on contact with air and form small particles which have a crucial role in pulmonary toxicity (13). Statistical analysis of the obtained data showed that there was only a significant difference for the thickness of the epithelium in bronchioles between experimental and control of 4 weeks subgroups. It seems that solder fumes induce an inflammatory and hyperplastic reaction in experimental subgroups. Study of Yu and colleagues showed that instillation of welding

fume particles caused an initial increase in the inflammatory pulmonary responses, although this reaction returned to a normal level after this initial reaction (7). Analysis of our results for the thickness of interalveolar septum showed a significant difference between experimental and their own control of 4 and 6 week subgroups. Our finding showed a difference in reaction between bronchioles and interalveolar septa in response to solder fumes. Exposure to solder fumes from rosin based fluxes containing colophony or rosin can give rise to respiratory irritation. Soldering fumes can also induce irritation in eyes and upper respiratory tract and on contact with the skin can cause dermatitis. It seems that inhalation of the large amounts of fumes and gases generated during soldering operations may be physically irritating and deposit in nasal mucosa (14). Although the respiratory epithelium of the bronchiole acts as a biological barrier for the fumes and prevents their entrance to mucosa, our results clearly showed that the fumes induce hyperplasia and

dysplasia in bronchioles. It seems that increase in the epithelial thickness of bronchioles is partly attributable to hyperplastic reaction of the bronchiolar epithelium. Diffuse inflammatory reaction which was observed in the lung is responsible for the increase in the thickness of the interalveolar septum. This increased inter-alveolar septal thickness is dependent on the exposure time. The results of this study are in consistent with the Yu and colleagues which reported that electric welding fumes can induce some histopathological changes such as fibrosis and increase in alveolar macrophages in rats (15).

The type of the lung disease after exposure to welding fumes are dependent on the nature of the offending agent, its physicochemical form, the dose and exposure time and host factors. Obstructive lung disease may result from occupational exposure to mineral and metallic dust or from jobs involving working with metal compounds such as welding (14). Pulmonary function assessment of solders engaged in soldering of printed circuit showed a significantly lower spirometry indices such as forced expiratory volume (FEV) and forced expiratory capacity (FEC) in comparison to the control groups (16). One of the most important factors in welding/soldering fume inhalation

environment is the ventilation factors of the workplace. Work related rhinitis was also present in 22% of exposed workers. The most important factor for this rhinitis is sensitivity to colophony fumes released from solder flux during soldering process (17).

Although our results did not show any significant change in rat weight after inhalation exposure to solder fume, Sung and colleagues reported that body weight of experimental rat group decreased after 60 day exposure and it was recovered after the next 60 day recovery period (5). It is probable that this inconsistency is partly due to difference in the exposure time in the two studies.

Conclusion

Our study shows that solder fumes can induce some pathological changes in lung. It seems that different mechanisms are active in reaction of bronchioles and alveoli to solder fumes.

Acknowledgment

The authors would like to thanks from Under secretary for research of Zahedan University of Medical Sciences for financial support of the project and Dr M Hashemi for his critically reading the manuscript.

References

1. Kim JY, Chen JC, Boyce PD, Christiani DC. Exposure to welding fumes is associated with acute systemic inflammatory responses. *Occup Environ Med* 2005; 62:157-163.
2. Antonini JM, Clarke RW, Murthy GG, Streekanthan P, Jenkins N, Eagar TW, *et al.* Freshly generated stainless steel welding fumes induces grater lung inflammation in rats as compared to aged fumes. *Toxicol Lett* 1998; 98:77-86.
3. Solano Lopez C, Zeidler-Erderly PC, Hubbs AF, Reynolds SH, Roberts JR, Taylor MD, *et al.* Welding fumes exposure and associated inflammatory and hyperplastic changes in the lungs of tumor associated A/J mice. *Toxicol Pathol* 2006; 34:364-372.
4. Palmer K, Crane G. Respiratory disease in workers exposed to colophony solder flux fumes: Continuing health concerns. *Occup Med* 1997; 47:491-98.
5. Sung JH, Choi BG, Maeng SH, Kim SJ, Chung HC, Han JH, *et al.* Recovery from welding fume exposure induced lung fibrosis and pulmonary function changes in Sprague Dawley rats. *Toxicol Sci* 2004; 82:608-613.
6. Sjorgen B, Hansen KS, Kjuus H, Person Per-Gunnar. Exposure to stainless steel welding fumes and lung cancer: a meta analysis. *Occup Environ Med* 1994; 51:335-336.
7. Yu IJ, Song KS, Maeng SH, Kim SJ, Sung JH, Han JH, *et al.* Inflammatory and genotoxic responses during 30 day welding fume exposure period. *Toxicol Lett* 2004; 154:105-115.
8. Antonini JM, Leonard SS, Roberts JR, Solano Lopez C, Young SH, Shi X, *et al.* Effect of stainless steel manual arc welding fume on free radical production, DNA damage and apoptosis. *Mol Cell Biochem* 2005; 297:17-23.
9. Gulec M, Gurel A, Armutcu F. Vitamin E protects against oxidative damage caused by formaldehyde in the liver and plasma of rats. *Mol Cell Biochem* 2006; 290:61-67.

10. American Society for testing and materials, Annual book of ASTM standards: atmospheric analysis and occupational health and safety; standard practice for measurement of metals in work place atmosphere. Easton, USA: ASTM; 1996; Vol.11.03, D 4185-90: 246-253.
11. <http://www.cdc.gov/niosh/docs/2003%2D154/pdf/3500.pdf>.
12. Occupational safety and Health Administration. Analytical Methods Manual ICP Analysis of Metal/metalloid particulate from solder Operations. Method No ID 206. Osha, Salt Lake city, Utah 1991.
13. Antonini JM, Clarke RW, Krishna Murthy GG, Sreekanthan P, Jenkis N, Egar TW, *et al*. Freshly generated stainless steel welding fume induces grater lung inflammation in rats as compared to aged fume. *Toxicol Lett* 1998; 98:77-86.
14. Courtney D. Health hazards of soft soldering in electronics industry. *Rev Environ Health* 1985; 5:1-26.
15. Yu Se, Song KS, Chang HK, Ham KJ. Lung fibrosis in Sprague Dawley rats, induced by exposure to manual metal Arc stainless welding fumes. *Toxicol Sci* 2001; 63:99-106.
16. Lee HS, Koh D, Chia HP, Phoon WH. Symptoms, lung function and diurnal variation in peak expiratory flow rate among female solderers in the electronic industry. *Am J Ind Med*. 1994; 26:613-619.
17. Burge PS, Perck W, OBbrien I M, Hawkins R, Green M. Occupational asthma in an electronics factory. *Thorax* 1979; 34:13-18.

Archive of SID