

## Effect of *Matricaria aurea* (Loefl.) Shultz-Bip. Hydroalcoholic Extract on Acetic Acid-Induced Acute Colitis in Rats

\*<sup>1</sup>Mohsen Minaiyan, <sup>2</sup>Nasrollah ghassemi-Dehkordi, <sup>3</sup>Parvin Mahzouni, Meysam Ansari-Roknabady

### Abstract

#### Objective(s)

*Matricaria aurea* is found abundant in Iran and has large similarities in constituents especially essential oils, flavones and flavonoides as well as traditional uses to the main species; *Matricaria recutita* L. Anti-inflammatory, antioxidant and spasmolytic properties of the main species suggest that this plant may have beneficial effects on inflammatory bowel diseases so the present study was carried out.

#### Materials and Methods

Hydroalcoholic extract of plant with doses of 200, 400, 800 mg/kg were administered orally (p.o.) for 5 days and rectally (i.r.) (400 and 800 mg/kg) at 15 and 2 hr before ulcer induction. To induce colitis, 2 ml of acetic acid 4% was instilled intra-colonically to separate groups of male Wistar rats (n= 6). Normal saline (2 ml), prednisolone (4 mg/kg) and hydrocortisone acetate (20 mg/kg) enema were administered to control and reference groups respectively. The tissue injuries were assessed macroscopically and histopathologically.

#### Results

Greater doses of extract (400 and 800 mg/kg) reduced colon weight/length ratio ( $P < 0.01$ ) and the highest test dose (800 mg/kg p.o. or i.r.) was effective to decrease tissue damage parameters including ulcer severity, area and index ( $P < 0.01$ ) as well as inflammation severity and extent, crypt damage and total colitis index ( $P < 0.01$ ) significantly.

#### Conclusion

It is concluded that *Matricaria aurea* extract was effective to protect against acute colitis in acetic acid model and this effect was more significant with the greater doses administered orally or rectally. Further studies are warranted to ascertain the mechanisms that are involved and the responsible active constituents.

**Keywords:** Acetic acid, Experimental colitis, *Matricaria aurea*, Plant extract, Rats

1-Department of Pharmacology and Isfahan Pharmaceutical Sciences Research Center, School of Pharmacy and Pharmaceutical Sciences, Isfahan University of Medical Sciences, Isfahan, Iran

\*Corresponding author: Tel: +98-311-7922623; Fax: +98-311-6680011; email: minaiyan@pharm.mui.ac.ir

2- Department of Pharmacognosy, School of Pharmacy and Pharmaceutical Sciences, Isfahan University of Medical Sciences, Isfahan, Iran

3-Department of Clinical Pathology, School of Medicine, Isfahan University of Medical Sciences, Isfahan, Iran

## Introduction

The interest in the genus *Matricaria* has dramatically increased since its constituents have high therapeutic potencies as antioxidant, anti-inflammatory, analgesic and antimicrobial agents (1).

*Matricaria aurea* (Loefl.) Shultz Bip (Asteraceae) is a fragrant herb growing around the rural areas of southern provinces in Iran. It is particularly the dried flowers heads that are widely used as flavoring agent for cooking with rice, carminative, demulcent and especially for peptic ailments in folk medicine (2). *M. aurea* flowers contain many different flavones and flavonoids, tannins and sesquiterpenes such as  $\alpha$ -bisabolol and farnesene. Because of similarities in chemical constituents and traditional uses, *M. aurea* (golden chamomile) is usually used instead of *M. recutita* L. and sometimes sold as fake herbal as original species (named Babooneh in Iran) (2). Although antioxidant, spasmolytic, anti-inflammatory, antinociceptive and antibacterial effects of chamomile have been shown in different experimental studies (3- 6), our knowledge about pharmacological effects of *M. aurea* is negligible.

Ulcerative colitis and Crohn's disease are known as main inflammatory bowel diseases (IBD). Although the pathophysiology of IBD is not known with certainty, immunological dysregulation and oxidoradicals have been proposed to contribute in the development of tissue injuries (7). In simplistic way, homeostasis is disrupted in patients with IBD because of over-expression of inflammatory cytokines (TNF- $\alpha$ , IL-1, IL-6) and/or under-expression of regulatory or anti-inflammatory cytokines (IL-2, IL-4, IL-10, TGF- $\beta$ ) (8). Attenuating oxidative stress and scavenging the reactive oxygen species (ROS) in IBD patients have proved as therapeutic strategy for several years. Sulfasalazine and 5-ASA derivatives are among the main therapeutic agents with this beneficial property (9, 10). In this context, considering the traditional uses of *Matricaria* genus, the role of oxidative stress in the pathogenesis of IBD and the presence of a number of compounds with antioxidant and anti-inflammatory properties compelled us to

design the present study and investigate the anticolitic effect of *Matricaria aurea* hydroalcoholic extract. For this purpose an animal model of experimentally acute colitis in rats induced by acetic acid was used.

## Materials and Methods

### Animals

Male Wistar rats (225 $\pm$ 25) purchased from Razi Institute (Tehran, Iran) were allowed to adapt to our laboratory environment for one week. They had free access to tap water and rat chow pellets and were housed singly in wire-bottomed cages under uniform and controlled conditions of temperature (20-22 °C), humidity and light/dark (12/12 hr) cycles. The experiments were according to the ethical and research committee protocol of Isfahan University of Medical Sciences, Isfahan, Iran.

### Chemicals

Prednisolone powder and hydrocortisone acetate enema were procured from Iran Hormone Pharmaceutical Co. (Tehran, Iran) and Valeant Pharmaceutical Co. (Saint-Laurent, Canada) respectively. All of the organic solvents were of analytical grade and Merck brand (Darmschtdat, Germany).

### Plant material and preparation of extract

*Matricaria aurea* (Loefl.) Shultz Bip was gathered from Fars province (rural parts of Shiraz, Iran) and authenticated by Dr Rahiminezhad from Science Faculty of Isfahan University, Isfahan, Iran. For preparation of hydroalcoholic extract, dried and finely powdered plant's flowers were wetted by ethanol/water (70/30) and extracted with extra volume of solvent for 48 hr in percolator apparatus. The extract was then separated, filtered and evaporated in a rotary evaporator under reduced pressure till a semisolid extract; yielded 11.6 % (w/w) was obtained (2).

### Grouping

The animals were randomly divided into following groups of 6 rats.

1, 2: Sham groups; received vehicle (normal saline/ 0.5% tween 80) [5 ml/kg, orally (p.o.) and intra-rectally (i.r.)] without colitis induction.

3, 4: Control groups; received vehicle (5ml/kg, p.o. and i.r.) according to the experimental protocol.

5, 6, 7: Extract groups; received low, middle, and high doses of extract (200, 400, and 800 mg/kg) p.o. for 5 days. The last dose was administered 2 hr before colitis induction.

8, 9: Extract groups; received twice middle and high doses of extract (400 and 800 mg/kg) as enema (i.r.) 15 and 2 hr before colitis induction.

10, 11: Reference groups; received prednisolone (4 mg/kg, p.o.) and hydrocortisone acetate enema (20 mg/kg) similar to respective test and control groups.

### **Experimental protocol**

The test samples including solutions or suspensions of drugs or plant extract were freshly prepared and administered to animals in the dose of 5 ml/kg p.o. or i.r. The plant extract was prepared as a suspension in 0.5% tween 80/normal saline.

Acute colitis was induced with acetic acid using a technique introduced by Mascolo *et al* (11). Briefly, rats were fasted for 36 hr with access to water *ad libitum* and observed to ensure healthy before induction of colitis. The rats were lightly anesthetized with ether. A flexible plastic rubber catheter with an outside diameter of 2 mm was inserted 8 cm into the colon *via* the anus. Diluted acetic acid 4% (2 ml) was injected into the colon and the rats were maintained in a head-down position for 2 min to prevent solution leakage. In sham-operated groups, normal saline was instilled. After 24 hr of colitis induction, rats were sacrificed using ether overdose and colon biopsies were used for macroscopic scoring and histopathological examination subsequently.

### **Assessment of colon macroscopic parameters**

The tissue of colon, 8 cm in length and 3 cm proximal to the anus was excised, opened longitudinally and washed in saline buffer. The specimens were weighted and wet weight/length ratio was measured for all the rats. A pathologist unaware of treatments recorded macroscopic scoring parameters. The criteria of the macroscopic score used a

previously validated scoring system from 0-4 according to Morris *et al* (12). The scores were: 0= no, 1= mucosal erythema only, 2= mild mucosal edema, slight bleeding or slight erosion, 3= moderate edema, bleeding ulcers or erosions, 4= severe ulceration, erosions, edema and tissue necrosis. Ulcer area was measured using 3M<sup>®</sup> (USA) scaled surgical transpose tape, which was fixed on a light and transparent sheet. Each cell on the tape was 1 mm<sup>2</sup> in area and the number of cells was counted for determining the ulcer area for each colon (13). Ulcer index was the later parameter, measured by summing the ulcer score and the ulcer area for each tissue specimen (14, 15).

### **Assessment of colon pathologic parameters**

Colon tissue was fixed in 10% formalin, dehydrated, and paraffin embedded, processed and sectioned in 4 µm thick sections, and stained with haematoxylin and eosin (H&E). Inflammation and crypt damage were assessed on H&E-stained, coded sections using a modification of a validated scoring scheme described by Cooper *et al* (16) and Dieleman *et al* (17). Total colitis score was the sum of the 3 subscores (inflammation severity, inflammation extent, and crypt damage). Histologic evaluation and scoring was performed using a Zeiss<sup>®</sup> microscope equipped with a Sony<sup>®</sup> color video camera for digital imaging.

### **Statistical analysis**

Results are expressed as the mean±SEM. Statistical analysis was performed using SPSS 11 statistical software. Differences among groups were examined using parametric one-way ANOVA with Scheffe post hoc test. Kruskal Wallis followed by Mann-Whitney U test analyzed non-parametric data. The minimal level of significance was identified at  $P < 0.05$ .

## **Results**

### **Macroscopic presentation**

Macroscopic damage parameters of the colon after acetic acid treatment revealed colonic mucosal hyperemia, edema, erosion, and ulceration in control groups (Figure 1A). No

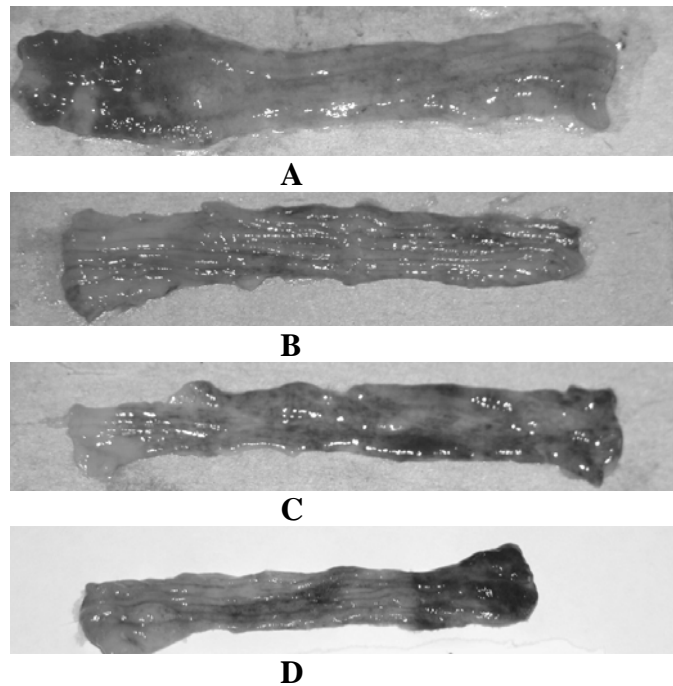


Figure 1. Macroscopic presentation of acetic acid-induced colitis in rats. A: Acute colitis treated by vehicle (normal saline/0.5% tween 80). B: Normal rat treated by vehicle (Sham group). C: Acute colitis treated by oral prednisolon (4 mg/kg) for five days. D: Acute colitis treated by oral *M. aurea* extract (800 mg/kg) for five days.

Table 1. Effects of *Matricaria aurea* hydroalcoholic extract (Ext. 200, 400, 800 mg/kg) on the macroscopic parameters of colitis induced by acetic acid in rats.

Groups	Route of administration	Score 0-4	Area cm <sup>2</sup>	Colitis index	Weight/Length ratio
Sham	Oral	0.0±0.0	0.0±0.0	0.0±0.0	78.3±5.4
Control	Oral	2.8±0.3	6.8±0.3	9.6±0.8	149.6±18.9
Pred.4	Oral	0.8±0.2**	1.6±0.6***	2.4±0.7***	92.2±9.2***
Ext.200	Oral	1.8±0.2	5.1±0.8	6.9±0.9	128.2±18.1
Ext.400	Oral	1.5±0.2*	4.4±0.2**	5.9±0.8*	113±10.6**
Ext.800	Oral	1.2±0.2**	2.5±0.6***	3.7±0.7**	110.2±11.4**
Sham	Rectal	0.0±0.0	0.0±0.0	0.0±0.0	75.4±6.1
Control	Rectal	3.0±0.3	7.0±0.5	10.0±0.8	142.8±13.1
Hydroc.20	Rectal	1.4±0.2**	4.2±0.3**	5.6±0.5**	96.7±6.2***
Ext.400	Rectal	2.2±0.2	6.1±0.2	8.3±0.4	114.2±9.5**
Ext.800	Rectal	1.3±0.3**	2.9±0.5***	4.2±0.4**	97.0±12.8**

The results are expressed as means±SEM, (n= 6). Pred. (prednisolone); Hydroc. (hydrocortisone acetate enema); \**P*< 0.05, \*\* *P*< 0.01, \*\*\* *P*< 0.001 denote significant difference vs control groups.

changes were observed in sham groups suggesting that handling and surgical procedure had no interference with experimental outcomes (Figure 1B). Pretreatment with prednisolone and hydrocortisone acetate enema as reference drugs, reduced the intensity of scores (*P*< 0.01), ulcer area (*P*< 0.001), ulcer index (*P*< 0.001) and wet weight/length ratio (*P*< 0.001) (Table 1 and Figures 1C, 1D and 2). Pretreatment with oral plant's extract reduced the severity of gross lesion scores, ulcer area and indices in such a

manner which greater doses (400, 800 mg/kg) were significantly effective while the lowest dose (200 mg/kg) had no significant effect (Table 1). Plant's extract enema was only effective when the dose of 800 mg/kg was administered rectally. Pretreatments with plant's extract (200 mg/kg was exceptional) and reference drugs were effective to lower weight/length ratio in colon specimens compared to control groups (Table 1).

Effect of *Matricaria aurea* on Acute Colitis

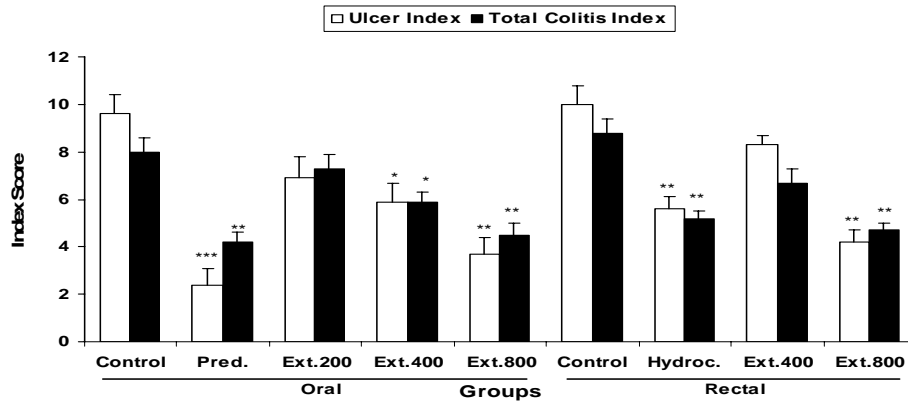


Figure 2. Effect of *Matricaria aurea* extract (Ext. 200, 400, 800 mg/kg) on ulcer index and total colitis index of acetic acid induced colitis in rats. Data are expressed as mean±SEM (n= 6), Pred. (prednisolone, 4 mg/kg), Hydroc. (hydrocortisone acetate enema, 20 mg/kg); \* P< 0.05, \*\*P< 0.01, \*\*\*P< 0.001 denote significant difference vs control groups.

Table 2. Effects of *Matricaria aurea* hydroalcoholic extract (Ext. 200, 400, 800 mg/kg) on the histopathologic parameters of colitis induced by acetic acid in rats. The results are expressed as means±SEM, (n= 6). Pred. (prednisolone), Hydroc. (hydrocortisone acetate enema); \*P< 0.05, \*\* P< 0.01 denote significant difference vs control groups.

Groups	Route of administration	Inflammation severity	Inflammation extent	Crypt damage	Total colitis
Sham	Oral	0.0±0.0	0.0±0.0	0.0±0.0	0.0±0.0
Control	Oral	2.7±0.4	2.7±0.7	2.6±0.4	8.0±0.6
Pred. 4	Oral	1.2±0.4**	1.5±0.4*	1.5±0.3**	4.2±0.4**
Ext. 200	Oral	2.3±0.3	2.5±0.8	2.5±0.5	7.3±0.6
Ext. 400	Oral	1.8±0.3*	2.2±0.4	1.9±0.3*	5.9±0.4*
Ext. 800	Oral	1.3±0.4**	1.7±0.3*	1.5±0.3**	4.5±0.5**
Sham	Rectal	0.0±0.0	0.0±0.0	0.0±0.0	0.0±0.0
Control	Rectal	2.8±0.5	2.8±0.5	2.8±0.7	8.8±0.6
Hydroc. 20	Rectal	1.9±0.2*	1.5±0.3*	1.8±0.3*	5.2±0.3**
Ext. 400	Rectal	2.3±0.6	2.2±0.6	2.2±0.2	6.7±0.6
Ext. 800	Rectal	1.5±0.3**	1.6±0.2*	1.6±0.5*	4.7±0.3**

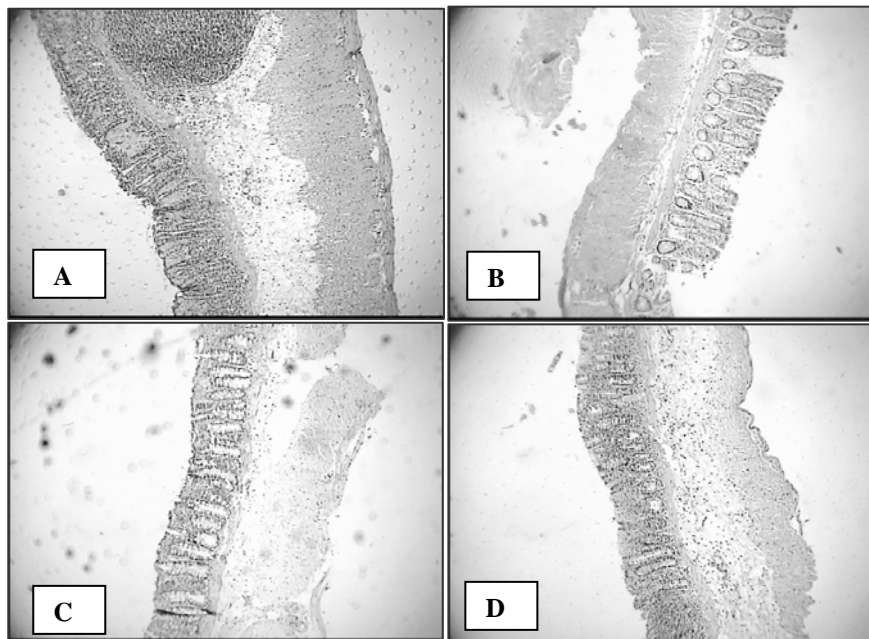


Figure 3. Microscopic presentation of colon tissue in rats. A: Acute colitis induced by acetic acid (4%) and treated by vehicle (normal saline/tween 0.5%). As it is shown, necrotic destruction of mucosa, crypt damage and transmural acute inflammation are obvious B: Normal rats treated by vehicle (Sham group) C: Colitis treated by oral prednisolon (4 mg/kg) for five days D: Colitis treated by oral *M. aurea* extract (800 mg/kg) for five days (H&E sections, low power).

### **Histological evaluation**

Rats with acetic acid-induced colitis and vehicle pretreatment (control groups) showed destruction of epithelium, hemorrhage, edema, inflammatory cellular infiltration, crypt damage and ulceration at mucus and sub-mucosal layers (Figure 3A). No histological damage was seen in sham groups (Figure 3B). As it is shown in Table 2, prednisolone and hydrocortisone enema was effective to reduce histopathological scores including inflammation severity and extent as well as crypt damage (at least  $P < 0.05$ ). The reference drugs were also effective to diminish total colitis index after oral and rectal administration ( $P < 0.01$ ) (Figure 2). Administration of plant's extract with the dose of 800 mg/kg which was invariably effective to reduce histopathologic scores in such a manner, was comparable with reference drugs (Figure 3C). Plant extract enema (400 mg/kg) was not effective to reduce any histologic damage scores (Table 2).

### **Discussion**

We used method of acetic acid that is both rapid and reproducible and produces diffuse colonic inflammation and definite ulcers resembling many histological characteristics of human UC (18). Our results confirmed the suitability of the method since an acute and invariably ulcerative colitis was developed in experimental rats. As it was found oral prednisolone and hydrocortisone acetate enema were both effective to protect against colitis induced by acetic acid denoting the adequacy of glucocorticoids actions irrespective to their route of administration (15). Greater oral doses of plant's extract compared to the lowest oral dose were effective to protect against ulcerative damage suggesting a role for dosage in our experiments. However, more doses should be examined to confirm dose-dependent suggestion. On the other hand, the greatest dose of extract administered orally or as enema was equally effective to protect against colon damage denoting effectiveness of both routes of applying the extract during our experiment. We know that oral doses were

administered daily for 5 days while rectal treatments were made twice for one day before colitis induction. It is likely that twice treatments with test extract enema provided a better availability and/or accessibility for active constituents to reach to the site of action and make an enough opportunity for local protective mechanisms such as scavenging the oxidoradicals and/or counteracting their noxious effects to be involved and eventually result in same outcome for oral and rectal routes of administration. Our findings are in accordance with some other investigations reported same efficacy for oral and intra-rectal route of natural honey (19) and *Capaifera langsdorffii* oleoresin (20) application. The exact mechanism of action has not been clearly delineated but the ulcer protective properties of German chamomile have been ascribed to bisabolol-type constituents on which considerable beneficial pharmacologic effects have been reported (21). *Matricaria aurea* extract contains a number of active constituents, which for some of them anti-inflammatory, anti-oxidant and immunomodulatory properties have been elucidated (22). Flavones and flavonoides as well as tannins, bisabolenes and farenzene are among the active ingredients isolated from the extract in phytochemical analysis. Gums and mucilages with colloidal cytoprotective properties are among other active constituents for which anti-ulcerogenic effects have been suggested (23). It seems that the protective effect of *M. aurea* may be related at least in part, to flavon and flavonoid compounds present in the extract. However, determination of the role of each of these compounds in the anti-ulcerative and anti-inflammatory effects of the extract needs more investigations. Anti-ulcerative effects of *M. aurea* as well as other related species *e.g.* *M. recutita* have been extensively studied in various animal models of ulceration within the gastrointestinal tract (24, 25).

It is suggested that mechanisms such as mast cells stabilization, inhibiting myeloperoxidase, and cyclo-oxygenase activity, inhibition of TNF- $\alpha$  and platelet aggregation as well as anti-spasmodic activities have essential roles in

anticolitic properties of beneficial medicinal plants (26, 27).

### Conclusion

We suggest that *M. aurea* is a promising agent for the treatment of UC and may be used as a dietary supplement for preventing the disease recurrence. More investigations with fractionated extracts in which pro-inflammatory and cytokine biomarkers will be

assessed are strongly recommended to provide sufficient evidences for later preclinical and clinical studies.

### Acknowledgment

This work was supported by Research Council of Isfahan University of Medical Sciences, Isfahan, Iran and conducted as research project No. 386244.

### References

- McKay DL, Blumberg JB. A review of bioactivity and potential health benefits of chamomile tea (*Matricaria recutita* L.). *Phytother Res* 2006; 20:519-530.
- Ghassemi-Dehkordi N. *Matricaria*. In: Iranian Herbal Pharmacopoeia Scientific Committee, editors, Iranian Herbal Pharmacopoeia. 1st ed. Tehran: Iran Ministry of Health & Medical Education Publications; 2002. p. 99-107.
- Ahmed AA, Abou Elela MA. Highly oxygenated bisabolenes and an acetylene from *Matricaria aurea*. *Phytochemistry* 1999; 51:551-554.
- Ali-Shtayeh M, Yaniv Z, Mahajna J. Ethnobotanical survey in the Palestinian area. A classification of the healing potential of medicinal plants. *J Ethnopharmacol* 2000; 73: 221-232.
- Capasso F, Grandolini G. *Fitofarmacia*. 2nd ed. Milan: Springer Veralg; 1999.
- Al-Mustafa AH, Al-Thonibat OY. Antioxidant activity of some Jordanian medicinal plants used traditionally for treatment of diabetes. *Pak J Biol Sci* 2008; 11:351-358.
- Sartor RB. Pathogenesis and immune mechanism of chronic inflammatory bowel diseases. *Am J Gastroenterol* 1997; 92:5S-11S.
- Brzezinski A. Inflammatory bowel diseases. In: Andreoli TE, Carpenter CCJ, Griggs RC, Loscalzo TE, editors. *Cecil essentials of medicine*. 5th ed. Philadelphia: Saunders WB Company; 2001.
- Lih-Brody L, Powell SR, Collier KP, Reddy GM, Cerchia R, Kahn E, *et al*. Increased oxidative stress and decreased antioxidant defences in mucosa of inflammatory bowel disease. *Dig Dis Sci* 1996; 41:2078-2086.
- Bouma C, Strober W. The immunological and genetic basis of inflammatory bowel disease. *Nat Rev Immunol* 2003; 3:521-533.
- Mascolo N, Izzo A, Autore G, Maiello F, Dicarolo G, Capasso F. Acetic acid-induced colitis in normal and essential fatty acid deficient rats. *J Pharmacol Exp Ther* 1995; 272:469-475.
- Morris GP, Beck PL, Herridge MS, Depew WT, Szewczuck MR, Wallace JL. Hapten induced model of inflammation and ulceration in rat colon. *Gastroenterology* 1989; 96:795-803.
- Minaiyan M, Ghannadi AR, Karimzadeh A. Antiulcerogenic effects of ginger (*Zingiber officinale* Roscoe) on cysteamine induced duodenal ulcer in rats. *DARU* 2006; 14:97-101.
- Vogel HG, Vogel WH. *Drug discovery and evaluation (Pharmacological Assays)*. 2nd ed. Berlin: Springer Verlag; 1997.
- Minaiyan M, Ghannadi A, Mahzouni P, Nabi-Meibodi. Anti-ulcerogenic effect of ginger (rhizome of *Zingiber officinale* Roscoe) hydroalcoholic extract on acetic acid- induced acute colitis in rats. *Res Pharm Sci* 2008; 3:15-22.
- Cooper HS, Murthy SNS, Shah RS, Sedergran DJ. Clinicopathologic study of dextran sulfate sodium experimental murine colitis. *Lab Invest* 1993; 69:238-249.
- Dieleman LA, Palmen MJHJ, Akol H, Bloemena E, Pena AS, Meuwissen SGM. Chronic experimental colitis induced by dextran sulfate sodium (DSS) is characterized by Th1 and Th2 cytokines. *Clin Exp Immunol* 1998; 114:385-391.
- MacPherson BR, Pfeiffer CJ. Experimental production of diffuse colitis in rats. *Digestion* 1978; 17:135-150.
- Mahgoub AA, El-Medany AH, Hagar HH, Sabah DM. Protective effect of natural honey against acetic acid-induced colitis in rats. *Trop Gastroenterol* 2002; 23:82-87.
- Paiva LA, Gurgel LA, De Sousa ET, Silveria ER, Silva RM, Santos FA, *et al*. Protective effect of *Copaifera langsdorffii* oleo-resin against acetic acid-induced colitis in rats. *J Ethnopharmacol* 2004; 93:51-56.
- Evans WC. *Trease and evance pharmacognosy*. 15th ed. Edinburgh: Saunders WB; 2002.
- Khayyal MT, El-Ghazaly MA, Kenawy SA, Seif-El-Nasr M, Mahran LG, Kafafi YA, *et al*. Antiulcerogenic effect of some gastrointestinally acting plant extracts and their combinations. *Arzneimittelforschung* 2001; 51:545-553.

23. Gholami A, Aboulhasani Z, Mohagheghzadeh A. Treatment of gastric ulcer by herbal medicine. In: Ebadi M, editor. Pharmacodynamic basis of herbal medicine. 1st ed. Tehran: Rahe Kamal Press Inc; 2007. p. 933-943.
24. Tan PV, Njimi CK, Ayafor JF. Screening of some African medicinal plants for antiulcerogenic activity: part 1. *Phytother Res* 1997; 11:45-47.
25. Borelli F, Izzo AA. The plant kingdom as a source of antiulcer remedies. *Phytother Res* 2000; 14:581-591.
26. El-Abhar HS, Hammad LN, Gawad HS. Modulating effects of ginger extract on rats with ulcerative colitis. *J Ethnopharmacol* 2008; 118:367-372.
27. Jagtap AG, Shirke SS, Phadke AS. Effect of polyherbal formulation on experimental models of inflammatory bowel diseases. *J Ethnopharmacol* 2004; 90:195-204.