

The Effect of Tamoxifen on the Fetal and Neonatal Ovarian Follicles Development in Rats

*¹Hassan Malekinejad, ¹Mahdi Hamidi, ²Rajab-Ali Sadrkhanloo, ²Abbas Ahmadi

Abstract

Objective(s)

The effect of tamoxifen as a selective estrogen receptor modulator which is widely used for treatment of early and metastatic breast cancer was investigated on the folliculogenesis in rat's fetuses and neonates.

Materials and Methods

The pregnant rats assigned into test and control groups. Control group received olive oil and treatment groups received either 17- β -estradiol (10 μ g/kg/day) or tamoxifen (0.4 mg/kg/day) between days 8-13 of pregnancy. On day 20th of pregnancy the rats euthanized and the blood samples were collected for determination of FSH, E₂, and the fetuses fixed for histological studies. Another group of pregnant rats went forward to obtain their neonates and we euthanized the neonates and the genital system was collected for further histopathological analyses on day 5th.

Results

The histological examinations of the fetus's and neonate's ovaries and biochemical data showed significant changes in the rats which treated with tamoxifen. The absence of folliculogenesis and an increase in E₂ level in tamoxifen-treated group which accompanied with sharp decrease of FSH level in comparison with the control group were demonstrated. By contrary, E₂ treated group showed a positive progress in development in terms of the formation of secondary follicles and also supportive connective tissues in comparison with the control group.

Conclusion

In conclusion, this study supports the previous findings showing that tamoxifen has effects on the development of ovaries and therefore, it should be avoided or used with great caution in pregnant women.

Keywords: 17- β -estradiol, Folliculogenesis, FSH, Ovary, Tamoxifen

1- Department of Pharmacology & Toxicology, Faculty of Veterinary Medicine, Urmia University, Urmia, Iran

*Corresponding author: Tel: 0441 2792806; Fax: 0441 2771926; email: h.malekinejad@urmia.ac.ir

2- Department of Histology and Embryology, Faculty of Veterinary Medicine, Urmia University, Urmia, Iran

Introduction

Tamoxifen (TAM) is a selective estrogen receptor modulator (SERM) compound which is used for treatment of breast cancer in women that previously diagnosed with breast cancer. It is also known as selective estrogen receptors (ERs) modulator with nuclear ER α actions in the absence of estrogens, as selective ER α antagonist methyl-piperidinopyrazole antagonizes TAM effect (1). Very well known mechanism of action of TAM is acting as competitive partial agonist/antagonist of estrogen receptors. TAM acts via binding to estrogen receptors and subsequently binding at estrogen responsive genes (2).

In rat the ovarian development begins before birth and among the initial and the main changes, the formation of follicles is noted (3). Like as other mammals, in rats also estrogens play a vital role in physiologic processes by binding to ERs. Some studies showed that both isoforms of ERs protein are expressed in the rat placenta, uterus and ovary (4, 5).

As the localization of each individual receptor could be different than others, ERs also have various localization patterns. For example ER α is dominantly expressed in breast tissue while both ER α and ER β are found in the ovary with different localized points. In the ovaries of different mammalian species expression of ER α has been reported in the germinal epithelium, interstitial cells of growing follicles, and theca cells, whereas ER β expression has been detected dominantly in granulosa and cumulus cells (5). Different signaling pathways between the two ER isoforms in the presence of TAM have been demonstrated. Previous studies showed that the ER α , but not ER β was able to recruit SRC-3 (steroid receptor co-activator) in the presence of TAM and therefore, they concluded that this fact may explain the differential ER isoforms associations with recurrence in human breast cancer (7). There is, however, plenty of studies showing that TAM exerts its effect on ER-positive and negative tissues. For example it has been demonstrated that TAM induces time- and dose-dependent apoptosis in ER-positive MCF-

7 and ER-negative MDA-231 human breast cancer cells (8).

Previous studies also showed that TAM administration could cause disorders in development. For example it has been reported that TAM alters the uterine luminal epithelium morphology and inhibits uterine gland genesis in the developing rodent uterus (9, 10). At the same time other reports indicating that 5 days administration of 100 microgram TAM in male newborn rats resulted to the abnormal development of glans penis construction (11). Equally, there are accumulating data showing developmental toxic effects of E₂ administration during fetal and neonatal periods in rodents, as well (12).

Subjecting of dams on days 1 to 5 of gestation to raloxifene another non-steroidal SERM led to low fetal weights and litter size (13). Additionally it would be worth to be noticed that TAM as a human model of long time use resulted to some histopathological effects including the uterus luminal dilation or obstruction, loss of endometrial glands and myometrium disorganization following long time treatment with TAM in female rats have been reported (14).

Since TAM is able to exert its effects on ER positive and negative organs in one hand and on the other hand TAM may be used in pregnant women in case of necessity, hence in this study we aimed to clarify any potential effect of TAM on folliculogenesis in the fetal and neonatal ovaries that received TAM. In this regard, as TAM administration to mature mice or immature rats resulted in accumulation for the first 4 days, therefore, we chose the administration of TAM during days 8 -13 of gestation, which the primordial germ cells beginning to migrate on day 10 or 11 of gestation in rat (15, 16). Moreover, as the folliculogenesis processes in rats, which normally begin in fetal period and end up on 4th or 5th days of the birth, thus sampling of the ovaries from neonates for the follicles formation analyses took place on day 5. Additionally, the hormonal situ in dams which received medicine also was evaluated.

Materials and Methods

Tamoxifen citrate (TAM) (purity > 97%), 17 β -estradiol (E₂) (purity > 99 %), were purchased from Sigma-Aldrich (Germany). Ethanol and dimethyl sulfoxide (DMSO) were obtained from Merck (Germany). Olive oil was purchased from local drug store. All other chemicals were commercial products of analytical grade.

Animals

The study was conducted on female Wistar rats, 8–10 weeks old, 150–200 g that were kept at the animal center of Urmia University. The rats were housed in ventilated rooms at temperature of 22 \pm 2 °C with a 12 hr light/dark cycle. They were provided with food and water *ad libitum*.

At the first step following acclimatizing, female rats were synchronized by male rat co-caging method. The pregnancy was proved by vaginal smear preparation. The pregnant rats were subjected to the study. All performed experiments on animals were in accordance with the guidance of ethical committee for research on laboratory animals of Urmia University, Iran.

Animal treatment

E₂ and TAM were dissolved in olive oil with the aid of small amount of ethanol. The pregnant rats were assigned to 3 groups (n= 10). The rats in control group received olive oil plus the same volume of ethanol which the test groups received. Animals in the test groups received test compounds including E₂ at pharmacological dose (10 μ g/kg/day) or TAM (0.4 mg/kg/day) by gastric gavage, on days 8–13 of pregnancy (17, 18). The half of each group (n= 5) on day 20 of pregnancy following anesthesia with ketamine (5%, 40 mg/kg, i.p.) and xylazine (2%, 5 mg/kg, i.p.) were euthanized by using CO₂ gas in a special device and immediately female fetuses and in particular the genital system of the fetuses were sampled and stored in formaldehyde (10%) for further histopathological examinations. Additionally the blood samples from dams were collected for hormonal analysis and stored at -20 °C.

The remained half of each group (n= 5) was allowed to finalize the gestation term and on day 5 after birth all female neonates corresponding to the same group were euthanized and again the genital system was sampled for further histopathological analysis.

Determination of E₂ and FSH level

The serum E₂ level was determined through direct and competitive CLIA method (chemiluminescent immunoassay), using LIAISON Estradiol (310400) kit and according to manufacturer's instructions (Diasorin Inc, USA). The limit of detection (LOD) level was found 12 pg/ml. Inter- and intra-assay coefficients of variations were below 5 and 9.3%, respectively.

Additionally, the serum FSH level was measured using LIAISON FSH (312 251) kit and based on manufacturer's instructions (BYK, Sangtec Diagnostica GmbH & Co. KG, Germany). This assay is performed as two-site immunoluminometric assay (sandwich principle). The minimum amount of detection for FSH was 0.25 mIU/ml. Inter- and intra-assay coefficients of variation were found below 4.5 and 8.7 %, respectively.

Histopathological analysis

The entire fetus samples and the ovaries from the neonates were fixed in the 10% buffer phosphate formaldehyde solution. The samples were processed through paraffin embedding and cut equally with rotary microtome (6 μ m) and were stained with hematoxyline and eosin technique and ultimately analyzed under light microscope. The numbers of primordial, primary and secondary follicles were counted for each single ovary and expressed as follicle per ovary.

Statistical analysis

All numerical results are presented as means \pm SD. The differences between the control and treated groups of hormonal changes and the number of different types of follicle were compared by using one-way ANOVA test, which followed with bonferroni posthoc test by means of software Graph Pad

Prism, version 4. $P < 0.05$ was considered as significant difference.

Results

The histological analysis of the fetus's ovaries showed that in the control group gonocytes were distributed as cluster form in the ovary. Moreover, between gonocytes population (mass) a few follicular cells and very few connective tissue fibers were observed, as well (Figure 1-A). In the E₂ treated group, clustering of the cells were more appreciable and the cells were capsulated which representing very primary follicle forming. The connective tissue thickness was remarkably increased and the distribution of the gonocytes in comparison to control group was more detectable (Figure 1-B). Surprisingly, we found that in TAM-treated group no differentiation between gonocytes and other cells was applicable. The cells appeared with piknotic or fragmented nucleus. The epithelial cells lost their normal form and mostly were observed in piknotic form

(Figure 1-C). Moreover, majority of the cells showed fragmentation with hetrochromatic or euchromatic nuclei.

In further step of histological analysis which were performed on the neonatal ovaries, in control group the majority of the cells were found as gonocytes and primary follicles with structured connective tissue. In control group the cells which surrounding the primary follicles were changing from simple squamus to simple caubidal form. Most of the follicles in the control group were found as primary form with hetrochromatic nuclei (Figure 2-A). Very few follicles had euchromatic nuclei with transparent cytoplasm. In the E₂-treated group of neonates density of the primary follicles were increased relatively (Table 1), and a few form of secondary follicles were also observed. The distribution of intra-nuclear material was observed as hetro- and euchromatic forms. The follicular cells were in cuboidal shape and the connective tissue was extended between follicles (Figure 2-B). In TAM-treated group, however, gonocytes were

Table 1. Effect of E₂ and TAM on the number and type of formed follicles in neonates.

Group	Primordial	Primary	Secondary
Control	1492±271.5	839±93.3	ND
E ₂	ND*	684 ± 220.6	27*
TAM	ND *	ND*	ND

The numbers and type of formed follicles per ovary were counted in entire ovary. Stars indicating significant differences ($P < 0.05$) between the control and treated groups at the same column and ND representing of not detected follicles.

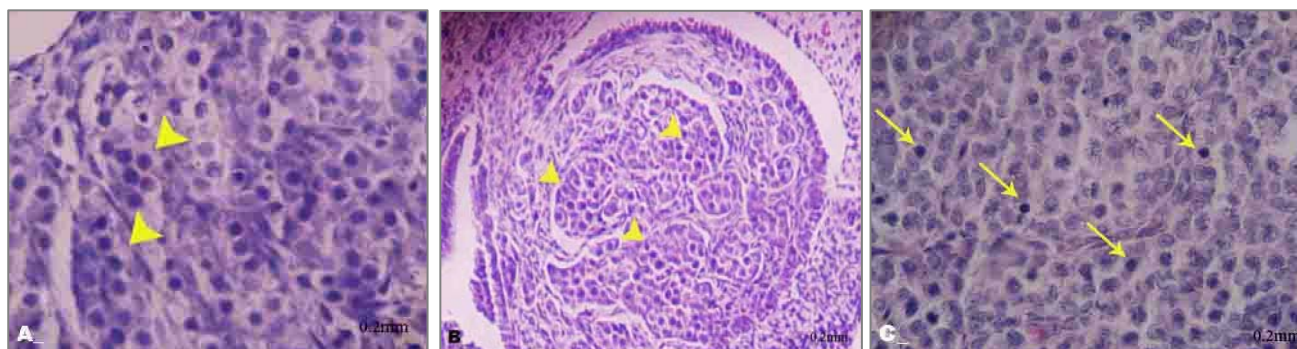


Figure 1. Histopathologic sections from the fetus's ovaries: A) control group, a few clustered follicular cells (arrow) and rarely the connective tissue are observed, H & E, 400X; B) E₂-treated group, the follicular cells more densely clustered (arrows), H & E, 100X; and C) TAM-treated group, there are no clear differentiations between gonocytes and other cells and additionally some cells showing piknotic (solid line arrow) or fragmented nuclei (dashed line arrows), H & E, 400X and scale bars were 0.2 mm

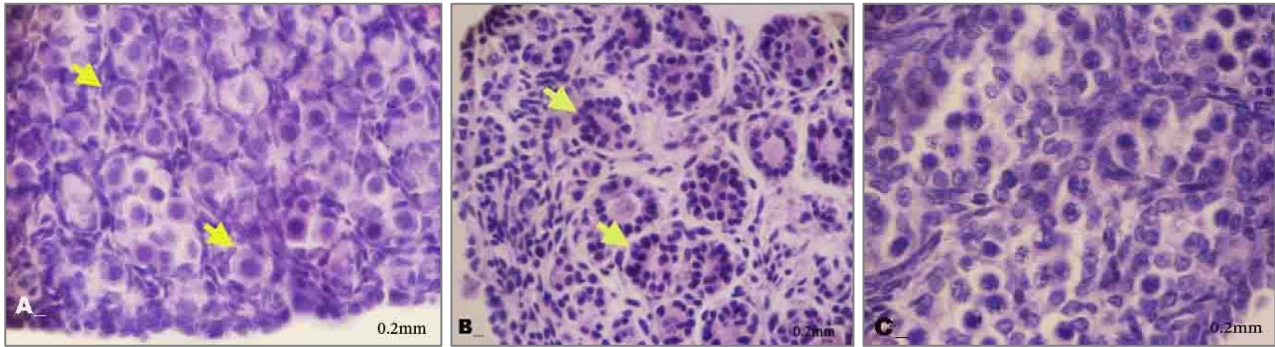


Figure 2. Histopathological sections from the neonate's ovaries: A) control group, the follicular cells are more densely clustered and a few primordial follicles are observed (arrow), H & E, 400X; B) E₂-treated group, the follicular cells are changed from squamous form to cuboidal shape and the secondary follicles are formed (arrow), H & E, 100X; and C) TAM-treated group, no organized follicle observed, H & E, 400X and scale bars were 0.2 mm.

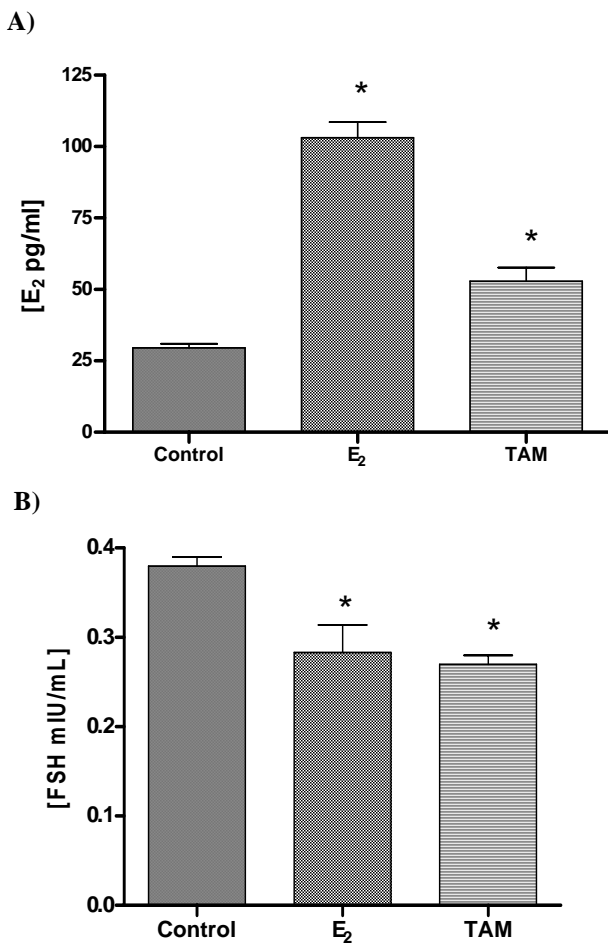


Figure 3. Effect of E₂ and TAM treatment on (A) 17β-estradiol and (B) FSH levels of the serum.

in grouped form along with follicular cells which encapsulated with connective tissue. In the mentioned cells nuclei was fragmented and

vesicular. Very notably, there was found no folliculogenesis signs in the TAM-treated group (Figure 2-C). The cellomic epithelium was not formed which representing a sort of stop in mitosis. The connective tissue was found very weakly formed and more importantly in histological sections of the TAM-treated group remarkable decrease of the capillary vessels was also observed.

The hormonal analyses for E₂ level in serum, following treatment with E₂, TAM at given concentrations revealed that E₂ level in serum increased dramatically (Figure 3-A). Despite of significant increase in E₂ level of TAM-treated group, there was remarkable difference ($P < 0.05$) between E₂- and TAM-treated groups as the serum level of E₂ in the E₂-treated group was found 2-fold higher than that in the TAM-treated group.

We also observed that FSH level in the treated groups of E₂ and TAM, significantly but slightly declined (Figure 3-B). Although, there was no significant difference ($P < 0.05$) between the two treated groups, decreasing of FSH level in the TAM-treated groups was more pronounced than that in the E₂.

Discussion

The purpose of present study was to investigate any potential effect of TAM on folliculogenesis in the fetal and neonatal rats which received the compound via maternal port on days 8-13 of gestation period, when

the germinal cells are migrating to form reproductive organs (16). In order to find any hormonal changes due to treatment regimen in the sera, the concentrations of FSH and E_2 also were measured. Both histological and hormonal analyses were conducted in parallel with E_2 as a positive control and as a compound that TAM acts conventionally as a competitive antagonist for endogenous form of it (19, 20).

Indeed we could demonstrate that TAM in both fetal and neonatal group very dramatically either slowed or stopped the normal folliculogenesis. Although, the present study mainly focused on follicular cells and their differentiation, it should be noted that other cells like epithelial cells along with primordial germ cells (PGC) are migrated to the genital ridge and ultimately differentiated to the follicular cells. As it has been presented in results section, not only the normal processes of folliculogenesis -as we saw in the control group- have not been processed in the TAM-treated group, but some abnormalities also occurred. Observing of the cells with picknotic nuclei and chromatolysis (see Figure 1-C) and abnormal vascularization may indicate either genomic or non-genomic effect of TAM on folliculogenesis. Non-genomic effects of TAM could be due to either its direct effect on the ovary's structure and in particular on the follicular cells regardless of binding to ERs or due to indirectly increasing of E_2 concentration. There are a number of studies indicating direct effect of TAM on various tissues and cell lines (21). Thus, slowed folliculogenesis processes and presence of the cells with piknotic and fragmented nuclear material in the TAM-treated group of current study may be explained by TAM direct effect. In this regard and for interpreting of TAM effect on vascular formation, increasing evidences suggest that TAM lowers new-vascularization and this fact has been demonstrated in various organs of animals and humans (22, 23).

In fact TAM-induced changes in neonates were much remarkable than that in the fetal samples which could be explained by both

long- and critical-time of exposure. It is equally important to consider that the observed changes in the TAM-treated group is unlikely related to indirect and TAM-increased E_2 level, as E_2 itself caused alterations in contrast to TAM. Of course it could not be excluded that E_2 level enhancement due to TAM administration was much lower than that in the E_2 -treated group, thus concentration-dependent effects of E_2 should be taken into consideration, as well (24).

Comparing the TAM-treated group with those received E_2 showed remarkable differences between this two test groups. In both fetal and neonatal groups which were treated with E_2 , despite of the TAM-treated group, all folliculogenesis processes including moving from germinal cells to primordial, primary and secondary follicles and other complimentary events indicated positive and progressive impact of the E_2 (see Table 1). Despite of some previous evidence which indicating deleterious effects of estrodaiol in various tissues, our results with 10 $\mu\text{g}/\text{kg}/\text{day}$ b.w. E_2 on days 8-13 of gestation period showed relatively positive effects on folliculogenesis in rat (25-27). Therefore, this data once again confirms a dose-, organ- and time-dependent effects of estrogens. Additionally, one extremely important factor which influences the E_2 effect is the ER distribution and localization in different tissues. The expression of $ER\alpha$ dominantly in germinal epithelium and $ER\beta$ in granulosa cells which play critical role in folliculogenesis in fetal period might explain and suggest different affinity of estrogens and antiestrogens such as TAM on various ERs and consequently different effects. Previous studies in agreement with this finding demonstrated that E_2 exerts different effects on certain genes regulation via various receptors (28). Another reason for differences between TAM and E_2 treated groups could be various density of ERs expression during developmental period and consequently various affinities of E_2 and TAM to ERs. This different expression pattern of ERs in the reproductive tract of fetal female rat in

gestational development has been demonstrated by RT-PCR and immunohistochemistry methods (29).

On the other hand comparing the E₂-treated group with control group in both fetuses and neonates indicated not only folliculogenesis was processed faster than normal condition, but also vascularization of the ovary was more organized. This finding may be represent the positive effect of E₂ on folliculogenesis which could be mediated by binding to present ERs in various parts of the ovary including granulosa cells which play a vital role in growing and developing of the follicles in terms of structurally and hormonal secretion. Our finding indicating a remarkable presence of capillary vessels in the E₂-treated group in comparison to the control and TAM-treated groups which this datum is in very good accordance with the previous published data demonstrated that the E₂ depletion and TAM treatment both caused negative impact on human breast cancer growth (30).

In order to show any changes in hormonal situ and possible effect of hormonal alteration on folliculogenesis, we measured two key hormones level including E₂ and FSH in serum and indeed the obtained results showed significant changes in both test groups in comparison to the control group. For explanation of this finding and in particular how TAM can enhance the level of E₂, we propose several pathways including: (i) preventing or lowering of endogenous estradiol metabolism by TAM via affecting the cytochrome P450 system as this claim has been demonstrated in neonates that for 6-9 days exposed against TAM and at the end of exposure time the CYP 3A4 activity was reduced, significantly (Murakami *et al*, 2004), (ii) another reason for this finding could be replacement of bound E₂ with administered TAM which leads ultimately to elevation of free E₂ level in serum and (iii) one more

interesting reason could be direct effect of TAM on excessive proliferation of granulosa cells and in turn increasing of E₂ level, which has previously been reported (31, 32).

Moreover, it should be explained that how E₂ level in serum following treatment with E₂ elevated. It is easy to understand that the direct administration of E₂ could elevate E₂ level in serum. Another reason for this increase could be the proliferation of granulosa cells and consequently the production of more E₂ than normal condition.

The alterations in FSH level which is found following E₂ and TAM treatments could be due to physiologic reason of having negative feedback of E₂ level or in another word a sort of physiological regulation which exists between GnRH, FSH, and E₂ level in the body. For interpretation of slight differences between E₂ and TAM on FSH level, it is interesting to mention that hypothalamus as the main biosynthetic gland of the FSH is ER-positive tissue and it could be discussed that due to different pattern of expression and localization of ERs, two studied compounds may produce different effects.

Conclusion

This study clearly and in complete accordance with the previous data demonstrated that the TAM administrations to pregnant rats can cause the genital disorders including biochemical and histopathological alterations. Moreover, useful application of these findings may be extended to the suggestion that the consumption of TAM in gestation period either to be avoided or used under a great caution in women and pregnant animals.

Acknowledgment

The authors are grateful to Mr. S-H Tabatabaie for his generous support. This project was financially supported by Urmia University. The authors declare that they have no conflict of interests.

References

1. Garrido-Gracia JC, Gordon A, Bellido C, Aguilar R, Barranco I, Millan Y, *et al*. The integrated action of oestrogen receptor isoforms and sites with progesterone receptor in the gonadotrope modulates LH secretion: evidence from tamoxifen-treated ovariectomized rats. *J Endocrinol* 2007; 193:107-119.

2. Nichols M. The fight against tamoxifen resistance in breast cancer therapy: a new target in the battle? *Mol Interv* 2007; 7:6-13.
3. Rajah R, Glaser EM, Hirshfield AN. The changing architecture of the neonatal rat ovary during histogenesis. *Dev Dyn* 1992; 194:177-192.
4. Al-Bader M. Estrogen receptors alpha and beta in rat placenta: detection by RT-PCR, real time PCR and Western blotting. *Reprod Biol Endocrinol* 2006; 4:13.
5. Hiroi H, Inoue S, Watanabe T, Goto W, Orimo A, Momoeda M, *et al.* Differential immunolocalization of estrogen receptor alpha and beta in rat ovary and uterus. *J Mol Endocrinol* 1999; 22:37-44.
6. Sar M, Welsch F. Differential expression of ER α and β in the rat ovary. *Endocrinology* 1999; 140:963-971.
7. Mc Ilroy M, Fleming FJ, Buggy Y, Hill AD, Young LS. Tamoxifen-induced ER-alpha-SRC-3 interaction in HER2 positive human breast cancer; a possible mechanism for ER isoform specific recurrence. *Endocr Relat Cancer* 2006; 13:1135-1145.
8. Kang Y, Cortina R, Perry RR. Role of c-myc in tamoxifen-induced apoptosis estrogen-independent breast cancer cells. *J Natl Cancer Inst* 1996; 88:279-284.
9. Medlock KL, Branham WS, Sheehan DM. Effects of toremifene on neonatal rat uterine growth and differentiation. *Biol Reprod* 1997; 56:1239-1244.
10. Poulet FM, Roessler ML, Vancutsem PM. Initial uterine alterations caused by developmental exposure to tamoxifen. *Reprod Toxicol* 1997; 11:815-822.
11. Deveci E, Onen A, Tacar O, Yildirim A. The effect of tamoxifen on the neonatal development of rat glans penis. *Clin Exp Obstet Gynecol* 1997; 24:237-239.
12. Jung EY, Lee BJ, Yun YW, Kang JK, Baek IJ, Jurg MY, Lee YB, *et al.* Effects of exposure to genistein and estradiol on reproductive development in immature male mice weaned from dams adapted to a soy-based commercial diet. *J Vet Med Sci* 2004; 66:1347-1354.
13. Clarke DO, Griffey KI, Buelke-Sam J, Francis PC. The selective estrogen receptor modulator, raloxifene: reproductive assessments following preimplantation exposure in mated female rats. *Reprod Toxicol* 1998; 12:247-259.
14. Karlsson S. Histopathology and histomorphometry of the urogenital tract in 15-month old male and female rats treated neonatally with SERMs and estrogens. *Exp Toxicol Pathol* 2006; 58:1-12.
15. Robinson SP, Langan-Fahey SM, Johnson DE, Jordan VC. Metabolites, pharmacodynamics, and pharmacokinetics of tamoxifen in rats and mice compared to the breast cancer patient. *Drug Metab Dispos* 1991; 19:36-43.
16. Suckow MA, Weisbroth HS, Franklin CL. The laboratory rat. Amsterdam: Academic Press: College of Laboratory Animal Medicine Science, Elsevier; 2006.
17. Matsuura S, Itakura A, Ohno Y, Nakashima Y, Murata Y, Takeuchi M, *et al.* Effects of estradiol administration on fetoplacental growth in rat. *Early Hum Dev* 2004; 77:47-56.
18. Acar D, Cayan S, Aktas S, Tek M, Akbay E. The effect of tamoxifen on bladder functions and histology, and the role of estrogen receptor beta in a rat chemical cystitis model. *Neurourol Urodyn* 2007; 26:309-316.
19. Liu X, Pisha E, Tonetti DA, Yao D, Li Y, Yao J, *et al.* Antiestrogenic and DNA damaging effects induced by tamoxifen and toremifene metabolites. *Chem Res Toxicol* 2003; 16:832-837.
20. White IN. Anti-oestrogenic drugs and endometrial cancers. *Toxicol Lett* 2001; 120:21-29.
21. Nazarewicz RR, Zenebe WJ, Parihar A, Larson SK, Alidema E, Choi J, *et al.* Tamoxifen induces oxidative stress and mitochondrial apoptosis via stimulating mitochondrial nitric oxide synthase. *Cancer Res* 2007; 67:1282-1290.
22. Geraldles P, Gosselin H, Tanguay JF, Clement R, Calderone A. Tamoxifen treatment of myocardial infarcted female rats exacerbates scar formation. *Pflugers Arch* 2007; 454:385-393.
23. Tsang SY, Yao X, Chan HY, Chan FL, Leung CS, Yung LM, *et al.* Tamoxifen and estrogen attenuate enhanced vascular reactivity induced by estrogen deficiency in rat carotid arteries. *Biochem Pharmacol* 2007; 73:1330-1339.
24. Castillo C, Ceballos G, Rodriguez D, Villanueva C, Medina R, Lopez J, *et al.* Effects of estradiol on phenylephrine contractility associated with intracellular calcium release in rat aorta. *Am J Physiol Cell Physiol* 2006; 291:1388-1394.
25. Cavalieri E, Frenkel K, Liehr JG, Rogan E, Roy D. Estrogens as endogenous genotoxic agents-DNA adducts and mutations. *J Natl Cancer Inst Monog* 2000; 27:75-93.
26. Huseby RA. Demonstration of a direct carcinogenic effect of estradiol on leydig cells of the mouse. *Cancer Res* 1980; 40:1006-1013.
27. Stack DE, Byun J, Gross ML, Rogan EG, Cavalieri EL. Molecular characteristics of catechol estrogen quinones in reactions with deoxyribonucleosides. *Chem Res Toxicol* 1996; 9:851-859.
28. Haeger P, Andres ME, Forray MI, Daza C, Araneda S, Gysling K. Estrogen receptors alpha and beta differentially regulate the transcriptional activity of the urocortin gene. *J Neurosci* 2006; 26:4908-4916.

29. Okada A, Ohta Y, Buchanan DL, Sato T, Inoue S, Hiroi H, *et al*. Changes in ontogenetic expression of estrogen receptor alpha and not of estrogen receptor beta in the female rat reproductive tract. *J Mol Endocrinol* 2002; 28:87-97.
30. Kristensen CA, Hamberg LM, Hunter GJ, Roberge S, Kierstead D, Wolf GL, *et al*. Changes in vascularization of human breast cancer xenografts responding to antiestrogen therapy. *Neoplasia* 1999; 1:518-525.
31. Murakami T, Sato A, Inatani M, Sakurai H, Yumoto R, Nagai J, *et al*. Effect of neonatal exposure to 17 beta-estradiol and tamoxifen on hepatic CYP3A activity in developmental periods in rat. *Drug Metab Pharmacokinet* 2004; 19:96-102.
32. Terada S, Uchide K, Suzuki N, Akasofu K. A follicular cyst during tamoxifen therapy in a premenopausal breast cancer woman. *Gynecol Obstet Invest* 1993; 5:62-64.