

Testicular morphology of male rats exposed to *Phaleria macrocarpa* (Mahkota dewa) aqueous extract

Saadat Parhizkar ¹, Suriani Binti Zulkifli ², Mohammad Aziz Dollah ^{2*}

¹ Medicinal Plants Research Centre, Yasuj University of Medical Sciences, Yasuj, Iran

² Biomedical Department, Faculty of Medicine and Health Sciences, University Putra Malaysia, Malaysia

ARTICLE INFO

Article type:

Original article

Article history:

Received: Jul 7, 2013

Accepted: Nov 2, 2013

Keywords:

Herbal medicine

Infertility

Phaleria macrocarpa

Seminiferous tubules

Spermatogenesis

ABSTRACT

Objective(s): This study was designed to investigate the effect of *Phaleria macrocarpa* aqueous extract (PM) on spermatogenesis by observing the histological changes of testes in adult male rats.

Materials and Methods: PM was prepared by boiling the dried slices of *P. macrocarpa* fruits followed by filtering, centrifugation and freeze-drying to obtain the powder form. Eighteen Sprague Dawley adult male rats were divided into three groups (six in each group), designated as treatment (240 mg/kg PM), negative control (distilled water) and positive control (4mg/kg testosterone) and administered via intragastric gavage for seven weeks. In the sixth week of supplementation period, each male rat was introduced to five female rats. Afterward, all rats were sacrificed and the testes were removed for histological studies.

Results: PM significantly increased the number of cell and the thickness of seminiferous tubules of male rats ($P<0.05$). However, there was no significant effect on the volume and size of testes. The mean of spermatogonia cells numbers of PM groups differed significantly from the negative and positive groups ($P<0.05$).

Conclusion: PM showed potential value as an attractive alternative for improving sexual strength by increasing the number of spermatogonia cell and the thickness of the seminiferous tubules. Perhaps, PM could be suggested to be one of the herbal remedies that can improve men fertility. The results may have some clinical implication in the management of infertility.

► Please cite this paper as:

Parhizkar S, Zulkifli SB, Dollah MA. Testicular morphology of male rats exposed to *Phaleria macrocarpa* (Mahkota dewa) aqueous extract. Iran J Basic Med Sci 2014; 17:384-390.

Introduction

If a couple is unable to conceive a child after one year of unprotected intercourse, they are considered infertile. In 2010, almost 50 million couples worldwide were unable to have a child after five years (1). When broken down into statistics, in 30% of the cases, the abnormality is found only in the man, while abnormalities detected in both partners occur in another 20%. Therefore, male factor infertility accounts for 50% of couples with fertility problems (2).

Male fertility requires the production of large numbers of normal and mature spermatozoa by the testes through a complex process which is called spermatogenesis (3). There is a decline in the number of mature sperms in seminiferous tubule due to aging. So, it can be said that aging affects the process of spermatogenesis and fertility (4). The desire to have a child has led many couples to seek for the assistance of the herbalists, ritual experts, and clinics (5).

Nowadays, herbal medicine has gained much attention through its benefit for the treatment of

cancer, diabetes, heart disease, etc. (6). According to the World Health Organization (WHO), 80% of the world's population use plant-based remedies as their primary form of healthcare (7). Plants also become the basic of traditional medicine system, which has been used for thousands of year in countries such as China and India (8, 9). Many people and health care providers are using herbal medicine as alternative treatments for ailments. Mostly, the applications of traditional medicine have been passed from one generation to the next (10). It has been used without having scientific knowledge of their medical properties. Therefore, many researchers have investigated the uses, medical properties, and side effects of various medicinal plants to provide the public with a better understanding of the medicinal plants (11-13). The utilization of herbs as medicine has been common almost all over the world. This practice is due to the general public believes that traditional herbs provide some measure of benefit over and above the chemical medical approaches (14).

*Corresponding author: Mohammad Aziz Dollah. Biomedical Department, Faculty of Medicine and Health Sciences, University Putra Malaysia, 43400 Serdang, Selangor, Darul Ehsan, Malaysia. Tel: +603-89472039; Fax: +603-89472336; email: azizdollah2000@gmail.com



Figure 1. a) *Phaleria macrocarpa* fresh fruit



b) *Phaleria macrocarpa* dried fruit slices

Phaleria macrocarpa (Mahkota Dewa) is one of the herbs that have been used in traditional herbal medicine that was originally found in Papua, Indonesia (Figure 1 a, b). It is commonly used for the treatment of various ailments such as cancer, diabetes, hypercholesterolemia, hypertension, heart disease, allergy, etc (15). Its fruits contain natural chemical compounds like alkaloid, saponin, flavoid, and polyphenol and each of the compounds has its own function. Local people believe that *P. macrocarpa* can improve sexual strength and libido behavior in men (16). Unfortunately, there is very little published information on the potential of *P. macrocarpa* in improving fertility in males (17, 18). In order to study the effect of *P. macrocarpa* on spermatogenesis in rats, this experiment was designed and the effect of its aqueous extract on male fertility was determined by histopathological examination through measurement of the number of spermatogonia cells and the thickness or the layer of seminiferous tubules in the testes.

Materials and Methods

Extraction of *Phaleria macrocarpa*

P. macrocarpa (Voucher no. SK1929/11) fresh fruits were supplied by Dr Mohammad Aziz bin Dollah. Aqueous extracts as it has been used traditionally, was obtained from 250 g of dried MP fruits slices were soaked in 4 lit of hot water and boiled until the volume of water become half of its initial amount. After that, the mixture solution was filtered and the filtrate was centrifuged at 3000 rpm for 15 min. The supernatant was freeze-dried to obtain crystal or powder form of the extract. The powder of the extract was weighted and kept in the freezer at -20°C until used. The extraction process was repeated for about 3 kg of dried fruit slices.

Experimental animals

Eighteen male and ninety female Sprague Dawley rats (two months old and body weight 250-300 g) were used. They were kept in the animal house of Faculty of Medicine and Health Sciences,

University Putra Malaysia, Malaysia under room temperature (29-32°C), with 70-80% humidity, and automatic 12 hr-12 hr light-dark cycle. The rats were evaluated to be diseases-free and have no deformities. Animals were acclimatized for one week before starting the treatments. Animals were fed with pellet and drinking water was given *ad libitum*.

The protocol of the study was approved by animal care and use committee (ACUC) in accordance with "Guide for care and use of laboratory animals" set by ACUC of Faculty of Medicine and Health Sciences, University Putra Malaysia.

Experimental design

There are three treatment groups in this study: negative control, positive control and supplemented with aqueous extract of *P. macrocarpa*. In negative control, distilled water was used as supplement and in positive control, commercial testosterone drug (Andriol® Testocap™) was used as supplement. The PM-supplemented groups was given 240 mg/kg (this dose had been administered for renal protective in diabetic rats) of aqueous extract of *P. macrocarpa* (19). The *P. macrocarpa* extract was weighted using electronic balance (AND GF3000, USA) and reconstituted in distilled water. The working solution for the commercial drug was used directly from the original product that was purchased from Schering-plough Sdn. Bhd. Selangor, Malaysia. All of the working solutions were kept at -4°C. The working solutions were prepared once a week to prevent any deactivation of the active compound in the extract and to maintain the quality of the working solution. The rats in each group were force fed with working solution according to their treatment groups (distilled water, 240 mg/kg PM, Andriol® Testocap™) for seven weeks.

Assessed parameters

Testes volume

Testes are irregularly shaped objects. Thus, we used the water replacement method as it is the most common technique for the measurement of

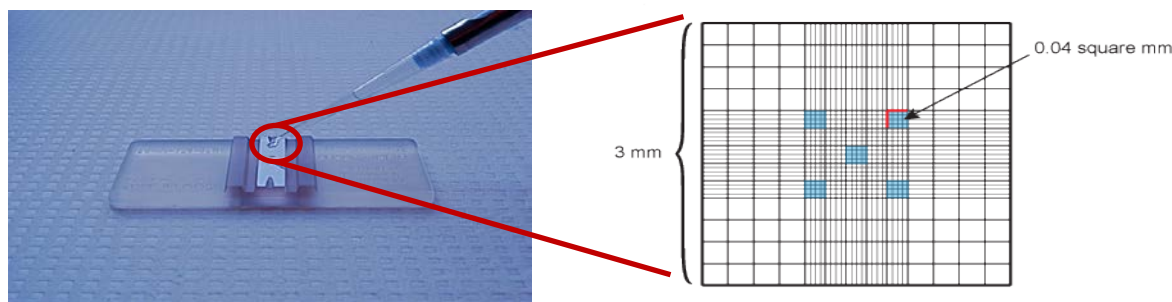


Figure 2. Haemocytometer showing the counting area (blue) for sperm count and motility

irregularly shaped objects (20). A graduated cylinder was filled with certain amount of water. The testis was then carefully placed into the graduated cylinder. The volume of the testis was calculated by subtracting the final and initial volume of water.

Testes size

The length and the width of the testes was measured using a ruler. The size measurement of the testes was done according to the previous method by Benjamin and Heideman (21). The size of testes was estimated using following formula for a prorate spheroid:

$$\text{Size of testis} = \text{width}^2 \times \text{length} \times 0.523$$

Post-mortem and testis tissue histological study

At the end of the experiment, the rats were sacrificed under chloroform anaesthesia and cervical dislocation. An incision was made into the abdominal cavity until the border near the tail of the rats. Fresh testes were removed from the rats and immediately fixed in 10% formalin in specimen containers for 3 days. The testes were cut laterally and longitudinally to examine the internal structure. Routine histological processes were employed for paraffin inclusion, sectioning and hematoxylin-eosin staining as follows. The specimens were fixed in 10% formalin for 72 hr. Later, they were dehydrated in graded levels of ethanol, cleared in xylene, and embedded in paraffin wax for sectioning. The 5 μm thick sections were cut, mounted on glass slides, and stained with hematoxylin and eosin for light microscopy.

Evaluation of histopathological changes

The histopathological changes were evaluated according to the previously reported methods (22, 23). Quantitative analysis of reproductive parameters was carried out by determination of the numbers of spermatogonia cells and seminiferous tubules thickness in testes. Sperm count was done using the haemocytometer under light microscope. A cover slip was placed on the haemocytometer before a drop with 10 μl of caudal epididymal sperm solution was loaded under the cover slip. The haemocytometer was placed under the light microscope and viewed under $\times 400$ magnification.

Sperm count was done by counting 4 \times 4 squares (horizontally or vertically) as shown in Figure 2 and calculated using the formula below:

$$\text{Sperm count} = \text{total no. of sperm in 5 squares} \times 50,000 \times 100 \text{ (cells/ml)}$$

Counting was only done for sperm heads that was found within the squares areas.

Statistical analysis

Data analysis was performed using Statistical Analysis System (SAS) version 9.2. Data of histopathological changes (numbers of spermatogonia cells and seminiferous tubules thickness in testes) were subjected to analysis of variance (ANOVA) to analyze the significance of the treatment effect and the mean \pm SD data among groups was compared using Duncan Multiple Range Test. F value is considered significant if $P < 0.05$.

Results

Testes volume

The testes volume of the rats treated with PM, Andriol Testocaps™, and distilled water did not show any change following the treatment period. Mean value of the testes volume of all groups is presented graphically in Figure 3. The testes volume for all treatment groups was 1.83 ml which was within the normal range and there was no difference in testis

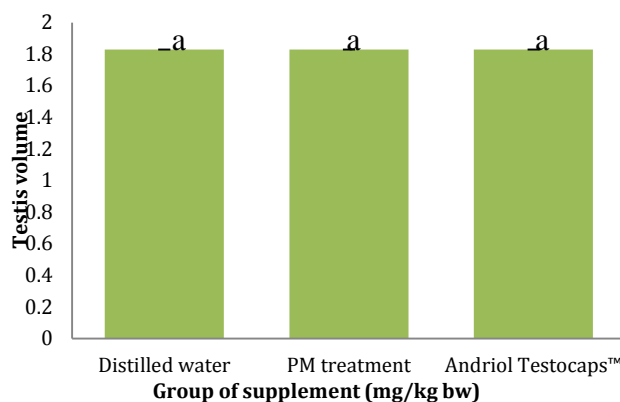


Figure 3. Means \pm SD of testes volume in rats after 6 weeks of administration of *Phaleria macrocarpa* aqueous extract and in rats of the control groups

abc: different superscript indicated significant at $P < 0.05$ as compared to control group

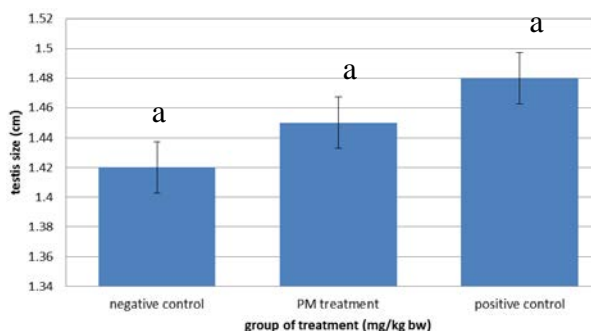


Figure 4. Means±SD of testes size in rats after 7 weeks of administration of *Phaleria macrocarpa* aqueous extract and in rats of the control groups

abc: different superscript indicated significant at $P<0.05$ as compared to control group

volume of treated groups as compared to control group. Treatment with *P. macrocarpa* fruit aqueous extract showed no effect on the testes volume in the mature male rats following the experimental period. Administration of PM did not change the testes volume when compared to the values of before treatment despite of the noticeable changes in some other genital organs of the rats.

Testes size

Mean value of the testes size after administration of PM, Andriol Testocaps™ and distilled water were shown in Figure 4. Statistical analysis using ANOVA indicated that there was no significant difference among the testes size of all treatment groups.

Spermatogonia cells number

Mean of the spermatogonia cells number of all groups are presented in Figure 5. Regarding the spermatogonia cell number of rats, there was a significant difference between rats treated with PM and control groups ($P<0.05$). Although an increment in number of spermatogonia was observed in positive control group, but it did not significantly differ from that of negative control.

Fertility has been linked to the sperm production. Here, although the volume or size and hormone level of testes were not improved significantly, but the quality of testes such as sperm production was the most concern issue. The quality of testes was determined by measuring spermatogonia cells number and the thickness of seminiferous tubules. Data of the spermatogonia cells number and the thickness of seminiferous tubule for distilled water (negative control) was 54.33 ± 3.13 cells and $46.67\pm4.21\mu\text{m}$.

Totally a substantial increase in spermatogonia cells was observed in rats treated with PM and Andriol testocaps™ (Figure 6 a, b and c).

Thickness of seminiferous tubules

Based on the finding, the mean thickness of seminiferous tubules value for distilled water (negative control), PM, Andriol Testocaps™ (positive

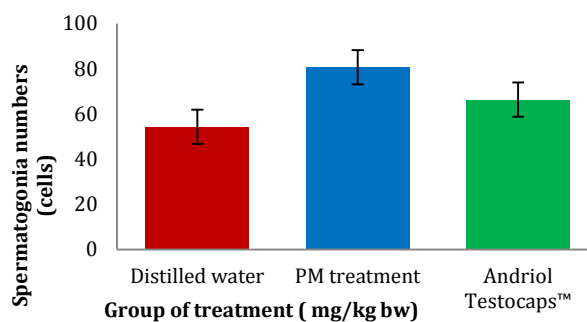


Figure 5. Means + SD of spermatogonia cell numbers in rats after 7 weeks of administration of *Phaleria macrocarpa* aqueous extract and in rats of the control groups

abc: different superscript indicated significant at $P<0.05$ as compared to control group

control) were 46.67, 80.66 and 50 μm , respectively (Figure 7). This indicates that the mean of the seminiferous tubules thickness of PM-treated rats differed significantly from those of the control groups ($P<0.05$). A substantial increase in the thickness of seminiferous tubules also was observed in rats treated with PM (Figure 6 a, b and c).

Discussion

The results of this study showed that the oral administration of 240 mg/kg of *P. macrocarpa* aqueous extract for seven weeks in male adult rats lead to the improvement of rats' fertility as evidenced by significant increment of spermatogonia cells number and thickness of seminiferous tubules.

The testes volume for all treatment groups were within the normal range according to the previous studies (24-26).

Supplementation with PM did not change the testes volume when compared to these values before treatment despite of the noticeable changes in some other genital organs of the rats. This might attribute to the age, stress and biological variation that may affect the testes volume as reported before (20). Besides, perhaps the dosage or duration of supplementation was not adequate or sufficient enough to produce any significant effects that could change the testes volume. Thus, long term supplementation period may produce better effects. It is however noted that the testes volume is a less sensitive indicator than testes weight in detecting the reproductive performance of rats because testes weight is one of the markers of possible alteration in androgen status (14, 25). Similar studies on royal jelly and *Nigella sativa* did not show any clear improvement of male fertility (testes) in rats (27, 28).

Supplementation with *P. macrocarpa* fruit aqueous extract slightly improved the size of testes in the mature male rats which was not statistically significant. Similar result was shown by Al-Sa'aidi *et al* who reported that use of alcoholic extract of *Nigella sativa* resulted in an increase in the testes size (28). Another study has shown that a decrease or increase in the testes size was most likely attributed to the testosterone level (28). Thus, the testes size was

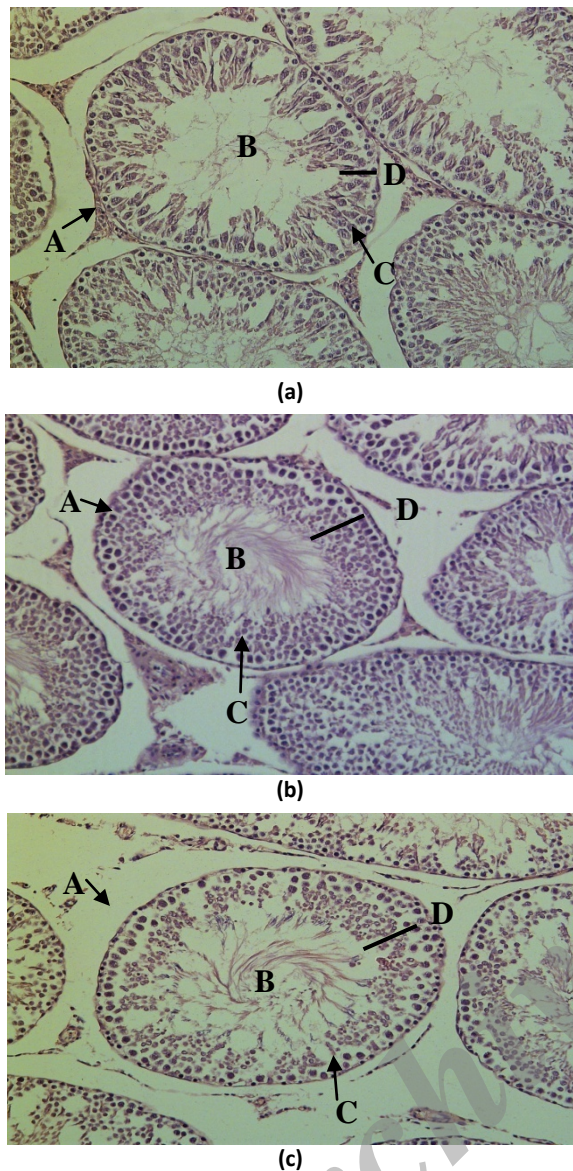


Figure 6. Photomicrographs showing representative seminiferous tubules in rats of (a): Negative control group (b): Rats treated with 240 mg/kg of aqueous extract *Phaleria macrocarpa* (c): Positive control group treated with Andriol Testocaps™ (H&E staining (X200))

A = Seminiferous epithelium;
B = Lumen;
C = Spermatogonia;
D = Thickness of tubular wall

stable and further increased dosage could not increase the testes size. Benjamin and Heideman found that age, stress and biological variation could inhibit the testes growth (21). The testes size was positively correlated with seminiferous tubule that was supported by Todd and Adrian who proved that an increase in seminiferous tubules can lead to increase in the testes size (30). Spermatogonia cells number and the thickness of seminiferous tubule for distilled water (negative control) were within the normal range in rats (28, 30-32).

According to Djannah, *P. macrocarpa* fruit contains alkaloid, flavonoid and saponin which can influence the microanatomic structure of the testis of male mouse (33). Gauthaman *et al* has shown that saponin component of plants enhances aphrodisiac properties because they have stimulatory effect on androgen production (34). Rosen and Ashton reported that aphrodisiacs are substances which can enhance sex drive (libido) (35). Besides, the saponin has the potency to increase the levels of testosterone (36). The increment in the sperm concentration was mainly due to the increase in testosterone levels in the testicular tissue. Testosterone is not only important in maturation of sperms but also is the main hormone responsible for spermatogenesis and spermiogenesis in seminiferous tubules (37). Similar study has done by Al-Sa'aidi *et al* who reported that use of alcoholic extract of *N. sativa* had resulted in an increase in spermatogonia cells (28).

In this histopathological study, there was an improvement in the thickness of seminiferous tubules in the PM-treated mature male rats. Seminiferous tubules comprise 80% of testicular mass, so the morphological measurement of seminiferous tubules is important in the studies of the testis tissues (38). The standard errors of the mean of the values are small and indicated that the thickness of different seminiferous tubules were almost uniform following measurement of 6 seminiferous tubules collected. This was sufficient for the estimation of the average of seminiferous tubules in rats which was supported by other researchers (28, 39). They reported that testosterone is essential for spermatogenesis from spermatogonium to spermatide. Thus, testosterone increases the thickness of the seminiferous tubules in testes. The result of this study was in agreement with Al-Sa'aidi *et al* who reported similar effects of alcoholic extract of *N. sativa* which could lead to clear improvement of male rats' fertility by increasing the diameter and wall thickness of seminiferous tubules (28).

The testes of normal rats were formed by seminiferous tubules surrounded by tunica albuginea. There are interstitial connective tissues between the tubules. The seminiferous tubules are uniform in size and shape and lined by regularly arranged rows of spermatogenic cells of different stages of maturation. Following treatment with PM, both of the number of spermatogonia cells and thickness of seminiferous tubules were increased significantly ($P < 0.05$). Dixon and Le reported that the blood testes barrier was possibly an important aspect when considering reproductive and mutagenic effect of drugs and environmental chemicals (40). Thus, the present study has demonstrated that aqueous extract of PM was able to pass through the blood testes barrier and gain access to the germ cells in the seminiferous tubules.

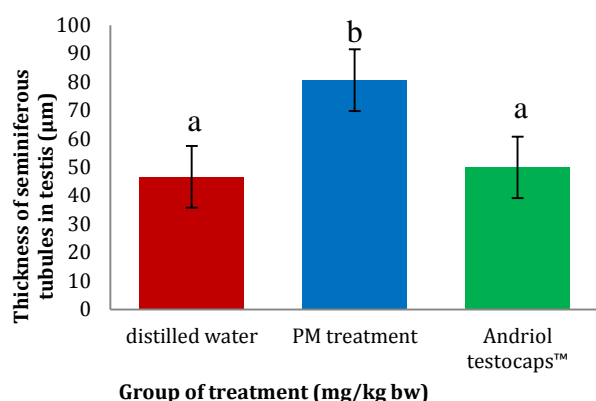


Figure 7. Means of seminiferous tubule in rats after 7 weeks of administration of *Phaleria macrocarpa* aqueous extract and in rats of the control groups
abc: different superscript indicated significance at $P < 0.05$ as compared to control group

Conclusion

PM supplementation has caused a significant increase in the mean of spermatogonia cells number and thickness of seminiferous tubule in adult male rats but has no significant influence on testes volume and testis size. Therefore, *P. macrocarpa* fruit extract improved the overall male reproductive performance. The results may have some clinical implication in the management of infertility. Thus, PM can be an attractive alternative to be used for improving the fertility in male.

Acknowledgment

This study was part of a student thesis and supported by University Putra Malaysia. The authors would like to thank Department of Biomedical Sciences, Physiology and Pathology Laboratory, University Putra Malaysia for their valuable technical support.

Conflict of interest

The authors declare no conflict of interest for the present research outcome.

References

- Mascarenhas MN, Flaxman SR, Boerma T, Vanderpoel S, Stevens GA. National, regional, and global trends in infertility prevalence since 1990: a systematic analysis of 277 health surveys. *PLoS Med* 2012; 9: e1001356.
- Seli E, Sakkas D. Spermatozoal nuclear determinants of reproductive outcome implications for ART. *Hum Reprod Update* 2005; 11:337-349.
- Lin Q, Sirotkin A, Skoultchi AI. Normal spermatogenesis in mice lacking the testis-specific linker histone H1t. *Mol Cell Biol* 2000; 20:2122-2128.
- Holstein AF, Schulze W, Davidoff M. Understanding spermatogenesis is a prerequisite for treatment. *Reprod Biol Endocrin* 2003; 1:107.
- Tabong PTN, Adongo PB. Understanding the social meaning of infertility and childbearing: a qualitative study of the perception of childbearing and childlessness in Northern Ghana. *PLoS One* 2013; 8: e54429.
- Schwartsmann G, Ratain MJ, Cragg GM, Wong JE, Saijo N, Parkinson DR, et al. Anticancer drug discovery and development throughout the world. *J Clin Oncol* 2002; 20:47s-59s.
- World health Organization. Research guidelines for evaluating safety and efficacy of herbal medicines. Manila: 2002.
- Chang HM, But PH. Pharmacology and applications of Chinese Materia Medica. 1&2. Singapore: World Scientific Publishing;1986.
- Kapoor LD. CRC handbook of Ayurvedic Medicinal Plants. Boca Raton. Florida: CRC Press, USA; 1990.
- Koehn FL, Carter GT. The Evolving role of Natural products in drug discovery. *Nat Rev Drug Discov* 2005; 4:206-220.
- Zhang X. Integration of traditional and complementary medicine into national health care systems. *J Manipulative Physiol Ther* 2000; 23:139-140.
- Drew A, Myers S. Safety issues in herbal medicine: implications for the health professions. *Med J Aust* 1997; 166:538-541.
- Li L. Opportunity and challenge of traditional Chinese medicine in face of the entrance to World Trade Organization. *Chin Inform Trad Chin Med* 2000; 7:7-8.
- Richardson MA, Sanders T, Palmer JL, Greisinger A, Singletary SE. Complementary/ alternative medicine use in a comprehensive cancer centre and the implications for oncology. *J Clin Oncol* 2000; 18:2505-2514.
- Winarto WP. Mahkota dewa: The conservation and usage for medicinal treatment. Jakarta: Penebar Swadaya. Indonesia: 2002.
- Zhang Y, Xu X, Liu H. Chemical constituents from Mahkota dewa. *J Asian Nat Prod Res* 2006; 8:119-123.
- Parhizkar S, Zainudin CZ, Dollah MA. Effect of haleria macrocarpa on sexual function of rats. *Avicenna J Phytomed* 2013; 3:371-377.
- Parhizkar S, Yusoff MJ, Dollah MA. Effect of *Phaleria macrocarpa* on sperm characteristics in adult rats. *Adv Pharm Bull* 2013; 3:345-352.
- Setiawati ES, Ismaulidiya FR. *Phaleria macrocarpa* (Scheff.) Boerl improved renal histological changes in alloxan-induced diabetic rats. *Int J Med Plants Altern Med* 2013; 1:87-92.
- Hughes SW. Archimedes revisited: a faster, better, cheaper method of accurately measuring the volume of small objects. *Phys Educ* 2005; 40:468-474.
- Benjamin SM, Heideman PD. Reduced body mass, food intake and testes size in response to short photoperiod in adult F344 rats. *BMC Physiol* 2002; 2:11.
- Lalit KK, Anand SG. Effect of aging on volume, structure, total leydig cell content of testes. *Int J Fertil* 1974; 19:40.
- Masuaki Y, Fumiyuki M, Hidehiro W, Nabuhiro T, Manabu M. Visualization of seminiferous tubules in rat testes in normal and diseased conditions by high resolution MRI. *Magn Reson Med* 2009; 62:637-644.
- Rabia L, Ghulam ML, Muhammad A. Effect of amlodipine on serum testosterone, testicular weight and gonado-somatic index in adult rats. *J Ayub Med Coll Abbottabad* 2008; 20:8-10.
- Sohrabi D, Alipour M, Mellati Awsat A. Effect of Metronidazole on spermatogenesis, plasma

gonadotropins and testosterone in male rats. Iran J Pharm Res 2007; 6:279-283.

25. Dorostghoal M, Dezfoolian A, Sorooshnia F. Effects of maternal lead acetate exposure during lactation on postnatal development of testis in offspring wistar rats. Iran J Basic Med Sci 2011; 14:122-131.

26. Hassan AA. Effect of royal jelly on the sexual efficiency in adult male rats. Iraqi J Vet Sci 2009; 23:155-160.

27. Al-Sa'aidi JAA, Al-Khuzai ALD, Al-Zobaydi NFH. Effect of alcoholic extract of *Nigella sativa* on fertility in male rats. Iraqi J Vet Sci 2009; 23:123-128.

28. Simanainen U, McNamara K, Davey RA, Zajac JD Handelsman DJ. Severe subfertility in mice with androgen receptor inactivation in sex accessory organs but not in testis. Endocrinology 2008; 149:3330-3338.

29. Todd TB, Adrian SD. Endocrine effects of marijuana. J Clin Pharmacol 2002; 42:90S-96S.

30. Lee YJ. Effects of tocotrienols on sperm parameters, testes weight and ultrastructure in Sprague Dwaley rats. Bachelor thesis, Universiti Putra Malaysia, Malaysia: 2010.

31. Wazir FU, Wazir IU, Javeed M, Fida M, Saeed M, Jahanzeb K, et al. Morphological changes induced by cottonseed flour in rat testes. Peshawar: ELBiomedical W122 press; Pakistan, 2006.

32. Djannah SN. The Influence of *Phaleria macrocarpa* to the Structure of Microanatomy Testis of Male Mouse (*Rattus norvegicus* L.). Bachelor Thesis. University Yogyakarta, Indonesia: 2009.

33. Gauthaman K, Adaikan PG, Prasad RN. Aphrodisiac properties of *Tribulus Terrestris* extract (Protodioscin) in normal and castrated rats. Life Sci 2002; 71:1385-1396.

34. Rosen RC, Ashton AK. Prosexual drugs: Empirical status of the "new aphrodisiac". Arch Sex Behav 1993; 22:521-543.

35. Koumanov F, Bozadjieva E, Andreeva M, Platonva E, Ankov V. Clinical trial of Tribestan. In Experiment medicine. 2nd ed. London: Academic press; 1982. p. 2-4.

36. Hadley ME. Endocrinology. In: Hormone Physiology. Maryland: Prentice hall, Inc; 2000. p. 422-444.

37. Sakamoto H, Yajima T, Nagata M, Okumura T, Suzuki K, Ogawa Y. Relationship between testicular size by ultrasonography and testicular function. Measurement of testicular length, width and depth in patient with infertility. Int J Urol 2008; 15:529-533.

38. Liu Z, Chang Q, Xu ZL, Zhang ZG. Stereological measurement of rat's seminiferous tubule. Chinese Med J 2009; 21:2643-2646.

39. Dixon RL, Lee IP. Possible role of blood testes barrier in dominant lethal testing. Environ Health Perspect 1977; 6:59-63.