

Antioxidant effects of proanthocyanidin from grape seed on hepatic tissue injury in diabetic rats

Esrafil Mansouri ^{1*}, Layasadat Khorsandi ¹, Hassan Ali Abedi ²

¹ Department of Anatomical Sciences, Cellular and Molecular Research Center, Faculty of Medical Sciences, Jundishapur University of Medical Sciences, Ahvaz, Iran

² Department of Physiology, Faculty of Medical Sciences, Jahrom University of Medical Sciences, Jahrom, Iran

ARTICLE INFO	ABSTRACT
<p>Article type: Short communication</p>	<p>Objective(s): Diabetes plays an important role in the induction of the liver injury. Grape seed proanthocyanidin (GSP) have a wide range of medicinal properties against oxidative stress. In this study we evaluated antioxidant effects of GSP on liver in streptozotocin-induced diabetic rats.</p> <p>Materials and Methods: Thirty male Sprague-Dawley rats were divided into three groups: control, untreated diabetic and diabetic rats treated with GSP. Diabetes was induced in rats by intraperitoneal injection of streptozotocin (50 mg/kg). GSP were administered via oral gavage (200 mg/kg) for 4 weeks.</p> <p>Results: GSP produced significant hepatoprotective effects by decreasing activities of serum aminotransferases and alkaline phosphatase, and decreasing liver malondialdehyde and bilirubin ($P<0.05$) levels. It increased liver superoxide dismutase, catalase and glutathione peroxidase activities and albumin level ($P<0.05$). Administration of GSP significantly ameliorated structural changes induced in liver of diabetic rats.</p> <p>Conclusion: GSP have protective effects against hepatic tissue injury due to antioxidant properties.</p>
<p>Article history: Received: Jul 6, 2013 Accepted: Dec 10, 2013</p>	
<p>Keywords: Antioxidant enzyme Diabetes GSP Hepatic tissue</p>	

► Please cite this paper as:

Mansouri E, Khorsandi L, Abedi HA. Antioxidant effects of proanthocyanidin from grape seed on hepatic tissue injury in diabetic rats. Iran J Basic Med Sci. 2014; 17:460-464.

Introduction

Diabetes mellitus (DM) is a group of metabolic disorders in which the main characteristic is hyperglycemia (1). Diabetic patients, especially those with uncontrolled blood sugar have a high incidence of liver dysfunction (2) which is characterized by an increase in alanine and aspartate aminotransferases (ALT & AST) (3). Oxidative stress is the result of an imbalance between radical-generating and radical-scavenging systems which could be due to enhanced free radical generation or decreased activity of antioxidants or both. During diabetes, constant hyperglycemia will increase the generation of free radicals especially reactive oxygen species (ROS) through glucose auto-oxidation and protein glycosylation (4). Herbal remedies have been used as efficient and secure alternative treatments for hyperglycemia and liver toxicity. There is an increasing concern regarding the herbal remedies due to their effectiveness, minimal side effects and relatively low cost. The use of herbal remedies or their extracts are widely recommended, even when biological effects of their compositions are unclear (5). Natural grape seed proanthocyanidins are

biologically active polyphenolic flavonoids which are known as oligomeric proanthocyanidins. These proanthocyanidins have demonstrated a marked spectrum of biological, pharmacological, therapeutic, and chemoprotective properties against oxygen free radicals and oxidative stress (6). A previous study demonstrated that proanthocyanidin has protective effects against liver injury induced by stress oxidative of doxorubicin (7). Considering these properties of grape seed proanthocyanidins (GSP), this study was designed to evaluate the hepatoprotective effects of GSP on streptozotocin-induced diabetes in rats.

Materials and Methods

Fifty male Sprague-Dawley rats weighing 150-170 g were obtained from Central Animal House of Ahvaz Jundishapur University of Medical Science (AJUMS) Ahvaz, Iran. All animals were maintained in controlled environment (12 hr light/dark cycle). All experimentals were carried out in accordance with the guidelines of the Ethics Committee of Ahvaz Jundishapur University of Medical Sciences, Ahvaz,

*Corresponding author: Esrafil Mansouri. Department of Anatomical Sciences, Cellular and Molecular Research Center, Faculty of Medical Sciences, Jundishapur University of Medical Sciences, Ahvaz, Iran. Tel: +98-9111183028; Fax: +98-6113332036; email: esrafilmansori@yahoo.com

Iran. Rats were divided into five groups of 10 rats each. These groups were divided as follows: group 1: control, group 2: diabetic rats, and groups 3-5: diabetic rats receiving GSP. All animals were kept under observation for one week prior to the start of the treatment.

Chemicals

GSP (95% pure) were purchased from Hangzhou Joymore Technology Co Ltd (China). The other chemicals and reagents were obtained from Sigma-Aldrich Chemical Co (St Louis, USA).

Induction of diabetes

Streptozotocin (STZ) was freshly dissolved in citrate buffer (0.1 M, pH 4.5). Diabetes was induced by a single intraperitoneal injection of STZ (50 mg/kg body weight) after overnight fasting. Control rats were injected with vehicle buffer only. Blood samples were obtained from the tail vein 72 hr after STZ injection and fasting blood glucose levels were determined with a glucose strip test in a glucometer (Easy Gluco Blood Glucose Monitoring system, Infopia, Korea). Rats with fasting blood glucose (FBS) level above 250 mg/dl were used as the diabetic animals.

Animal treatment

Treatment of the rats was started after measuring the blood glucose. Rats in the treated diabetic groups (groups 3-5) respectively received GSP 50, 100 and 200 mg/kg body weight. The GSP was dissolved in normal saline solution and given via oral gavage for 4 weeks (8-10 AM every day).

At the end of the experiment, the optimal dose was selected following the measurement of FBS by glucometer. Since the FBS of the group treated with the dose of 200 mg/kg was less than other groups, this dose was selected as the optimal dose (Table 1).

Biochemical assay

At the end of the experiment, six rats were randomly selected from each group, and were sacrificed under ether anesthesia. Blood samples were collected from the left ventricle and the sera were prepared following centrifuging at 2500×g for 15 min at 30°C. Serum biomarkers of the liver function including ALT, AST, alkaline phosphatase (ALP), albumin, and total bilirubin were measured using commercially available kits (Pars Azmon, Iran).

Table 1. The effect of different doses Grape seed proanthocyanidin on fasting blood glucose

Groups	FBS (mg/dl)
Control	97.16±3.15
Diabetic	437.16±24.11 ^a
GSP (50 mg/kg)	284.33±12.11 ^a
GSP (100 mg/kg)	254.33±25.31 ^a
GSP (200 mg/kg)	108.32±5.42 ^b

Each value is expressed as mean±SE (n=6), ^a Means differ significantly among diabetic, GSP (50,100 mg/kg) and control groups ($P<0.05$), ^b Means did not differ significantly between GSP (200 mg/kg) and control groups ($P>0.05$)

GSP: grape seed proanthocyanidin; FBS: fasting blood glucose

Preparation of liver homogenate

Following the sacrifice, the livers were immediately removed and washed with isotonic saline. Then, the liver tissue was minced and a homogenate was prepared with 5% (w/v) potassium phosphate buffer (0.1 M, pH 7.4) using a homo-genizer (Heidolph Silentcroscher M, Germany). The homogenate was then centrifuged at 16000×g for 20 min to remove nuclei and cell debris. The supernatant was used for the lipid peroxidation and antioxidant activity measurement.

Measurement of antioxidant activity

According to the method previously described (6) 0.5 ml of the supernatant was added to 1.5 ml trichloroacetic acid (TCA) (10%). After centrifugation (4000×g for 10 min), 1.5 ml of supernatant was mixed with 2 ml thiobarbituric acid (TBA) (0.67%) and was kept for 30 min at 100°C. They were allowed to cool after that, 2 ml of n-butanol was added to the solution then the mixture was vigorously vortexed and centrifuged at 4000× g for 15 min. Finally, the pink supernatant absorbance was read at 535 nm using a blank containing all the reagents except for the tissue homogenate. Values were expressed as nmol/mg protein. As 99% of the TBARS is malondialdehyde (MDA), TBARS concentrations of the samples were calculated from a standard curve using 1,1,3,3-tetramethoxypropane.

Catalase (CAT) activity was measured as previously described (6). The final reaction volume was 1 ml, containing 50 mM potassium phosphate (pH 7.0), 19 mM H₂O₂, and a 20-50 μl sample. The reaction was initiated by adding H₂O₂, and the absorbance were measured at 240 nm (25°C) for 30 sec. Catalase activity was calculated using the molar extinction coefficient of 43.6 M⁻¹ cm⁻¹ for H₂O₂. The level of CAT was expressed in terms of μmol H₂O₂ consumed/min per milligram of protein.

Table 2. Effect of GSP (200 mg/kg) on biochemical and antioxidant activity data in experimental groups

Parameters	Groups		
	Control	Diabetic	Diabetic+GSP
ALT (U/l)	65.78±2.39	126.81±2.36 ^a	85.38±2.76 ^b
AST (U/l)	106.21±3.31	146.35±2.24 ^a	116.84±2.84 ^b
ALP (U/l)	105.01±2.82	195.42±3.99 ^a	134.28±2.33 ^b
Alb g/dl	4.36±.16	2.12±.07 ^a	3.96±.09 ^b
Total bilirubin (mg/dl)	.39±.01	97±.02 ^a	.81±.02 ^b
SOD (U/mg protein)	15.98±2	10.45±2.02 ^a	13.68±1.91 ^b
GPx (U/mg protein)	18.34±2.44	12.94±2 ^a	16.96±1.85 ^b
CAT (U/mg protein)	204.65±10.53	165.62±11.26 ^a	193.28±9.98 ^b
MDA (nmol/mg protein)	19.08±2.05	29.42±3.29 ^a	22.30±2.7 ^b

Each value is expressed as mean±SE (n=6), ^a Means differ significantly among diabetic and control groups ($P<0.05$), ^b Means differ significantly between diabetic+GSP and diabetic group ($P<0.05$)

ALT: alanine aminotransferases; AST: aspartate aminotransferases
ALP: alkaline phosphatase; Alb: albumin; SOD: superoxide dismutase; GPx: glutathione peroxidase; CAT: catalase; MDA: malondialdehyde

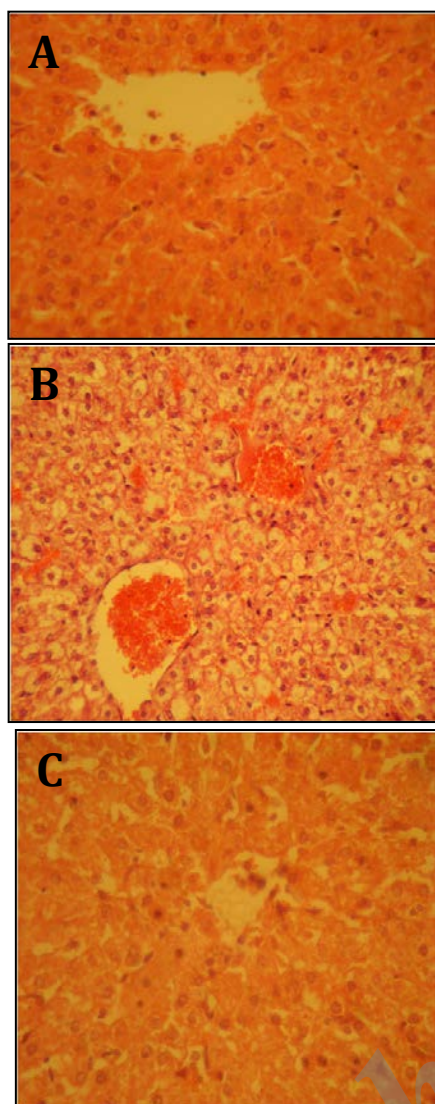


Figure 1. Histologic appearance of the liver tissue from different groups. (A) control group, (B) diabetic group, (C) Diabetic group with GSP (200 mg/kg) (H&E, 300x)

Superoxide dismutase (SOD) and glutathione peroxidase (GPX) activities were determined using the diagnostic kits RANSOD and ANSEL (RANDOX, UK) and were expressed as unit/mg protein. Protein content of the samples was measured by the method of Bradford (8).

Histological examinations

The livers were fixed in 10% neutral buffered formalin, dehydrated with 50–100% ethanol solutions, and then embedded in paraffin. Tissues were sectioned at 5 μ m thickness, followed by haematoxylin-eosin staining before subjecting to photomicroscopic observation.

Statistical analysis

Data are expressed as mean \pm SE. Statistical significance of differences was assessed by one-way ANOVA using SPSS for Windows (version 15)

followed by Tukey's *t*-test. $P < 0.05$ was assumed as statistically significant.

Results

Biochemical assay

The effects of GSP on serum levels of the markers of the liver injury (ALT, AST, ALP, bilirubin and albumin) in diabetic rats, are shown in Table 2. ALT, AST, ALP and bilirubin contents in serum of diabetes group were found to be significantly increased as compared to control group ($P < 0.05$) and these parameters in treated group were significantly decreased as compared to diabetes group ($P < 0.05$). The serum albumin level in diabetes group was significantly decreased as compared to control group ($P < 0.05$) and this parameter was significantly increased in treated group ($P < 0.05$).

Antioxidant activity changes

The effects of GSP on SOD, GPx, CAT and MDA levels in the rats livers are shown in Table 1. In diabetic rats, the activities of SOD, GPx and CAT were significantly decreased, while the MDA level was significantly increased as compared with the control rats ($P < 0.05$). Treatment of diabetic rats with GSP, significantly increased the activities of SOD, GPx and CAT and decreased MDA level in the liver ($P < 0.05$).

Histological changes

Figure 1 shows the structure of hepatocytes in the experimental animals. The morphology of the liver in control group was normal and pathological changes were not observed, hepatocytes made up interconnected plates and the plates arranged radially around the central vein. The spaces between these plates contain liver sinusoids. Pathologic alterations were observed in the animals of diabetic group. Hepatocytes relative lost their usual concentric arrangement and the sinusoids were congested. In this group, the hepatocytes showed clear grades of cloudy swelling with cytoplasmic vacuoles and pycnotic nuclei were seen in some cells (Figure 1B). Treatment with GSP showed marked improvement in hepatocytes structure. Also, nuclei and cytoplasm had normal structure. Hepatocytes arrangement and sinusoids congestion largely returned to normal as compared with the diabetic rat (Figure 1C).

Discussion

Our results demonstrated that FBS was significantly decreased in diabetic rats treated with GSP. It may be due to the potential of GSP in increasing insulin level in the blood and so decreasing glucose levels in diabetic rats (9). In the present study, significant reduction in serum albumin level and elevations of the levels of the liver injury markers (ALT, AST, ALP, and bilirubin) indicate the hepatocytes injury in experimental

diabetes. Individuals with diabetes have a higher incidence of liver function test abnormalities than those who are not diabetic (10). The data of this study also indicated that daily treatment with GSP considerably improves biochemical status of diabetic rats. Liver function tests (LFTs) are generally used in clinical practice to screen the liver diseases, monitor the development of known diseases, and monitor the effects of drugs that may cause hepatotoxicity. The most common LFTs include the serum aminotransferases, alkaline phosphatase, bilirubin, and albumin (10). Hepatocyte injury or hepatotoxicity results in the release of the liver enzymes into the blood circulation, thus increases liver enzymes level (11). Diabetes induced by STZ in rats causes liver tissue injury, which is associated with the elevation of serum hepatic enzymes, such as ALT and AST (12).

The above mentioned enzymes turned back to their normal serum levels after treatment with GSP perhaps due to prohibition of intracellular enzyme permeation created by cell membrane stability or cellular regeneration. Efficient adjustment of bilirubin and albumin indicates early recovery of functional and secretory activities of hepatic cells (13). In this study, significant reduction of antioxidant enzymes (SOD, GPx, CAT) activity as well as significantly increased MDA level show oxidative stress of the liver in experimental diabetes. Lipid peroxidation is generally used as a marker of tissue oxidative stress, in which oxygen reacts with polyunsaturated fatty acids and creates lipid products such as MDA and 4-HNE, and increase production of free radicals, leading to the injury of cell membrane, cell necrosis and inflammation (14). SOD and CAT are two major scavenging antioxidants which eliminate free radicals *in vivo*. A reduction in the activity of these antioxidants provides abundant accessibility of superoxide anion (O_2^-) and hydrogen peroxide (H_2O_2), which subsequently produce hydroxyl radicals ($-OH$), due to the production and proliferation of lipid peroxidation. SOD dismutates the O_2^- free radical to H_2O_2 , which is then turns to H_2O by CAT or GPx (16). It has been demonstrated that the activity of these antioxidant enzymes (SOD, CAT, GPx) is reduced in diabetic rats (6). Our observations also showed that daily treatment with GSP significantly increased antioxidant enzymes activities and markedly decreased MDA level. These results are similar to a previous study (6).

Histological changes

Last evaluations indicated notable alterations in the liver structure such as fatty change in short term (3). In the present study, oral administration of GSP improved structural changes induced by diabetes. This preservation by GSP may be due to both inhibition of metabolism and/or detoxification of cytotoxic radicals. In addition, its presumed

contribution to DNA repair may be the other important attribute, which plays a role in its protective effects. This effect possibly involves the inhibition of neutrophil infiltration and lipid peroxidation, thus restoring oxidant and antioxidant activity (14). Our findings are in agreement with a previous study (7).

Conclusion

The results demonstrate that GSP can improve serum biomarkers and histopathologic changes of damaged liver tissue in diabetic rats. It is therefore likely that GSP is prophylactic against diabetic complications and ameliorates diabetic hepatopathy through its antioxidant properties.

Acknowledgment

The authors would like to thank all the staffs of Cellular and Molecular Research Center of AJUMS. This work was supported by a grant from Deputy of Research and Technology Development of AJUMS (research project No. U-91225).

References

1. Abdelaziz EA. Pathological and biochemical studies on the effect of trigonella foenum- graecum and lupines termis in alloxan induced diabetic rats. *World Appl Sci J* 2011; 12:1839-1850.
2. Tolman KG, Fonseca V, Dalpiaz A, Tan MH. Spectrum of liver disease in type 2 diabetes and management of patients with diabetes and liver disease. *Diabetes Care* 2007; 30:734-743.
3. Zafar M, Naqvi S, Kaimkhani MA. Altered liver morphology and enzymes in streptozotocin induced diabetic rats. *Int J Morphol* 2009; 27:719-725.
4. Moussa SA. Oxidative stress in diabetes mellitus. *Romanian J Biophys* 2008; 18:225-236.
5. Gupta RK, Kesari AN, Murthy PS, Chandra R, Tandon V, Watal G. "Hypoglycemic and antidiabetic effect of ethanolic extract of leaves of a nonasquamosa L. in experimental animals. *J Ethnopharmacol* 2005; 99:75-81.
6. Mansouri E, Panahi M, Ghaffari MA, Ghorbani A. Effects of grape seed proanthocyanidin extract on oxidative stress induced by diabetes in rat kidney. *Iran Biomed J* 2011; 15:100-106.
7. Al-Sowayan NS, Kishore U. Prophylactic efficacy of a combination of proanthocyanidin and vitamin E on hepatotoxicity induced by doxorubicin in rats. *Int Res J Pharm* 2012; 2:161-169.
8. Bradford MM. A rapid and sensitive method for the quantitation of microgram quantities of protein utilizing the principle of protein-dye binding. *Analytical Biochem.* 1976; 72:248-54.
9. His SC, Kao YP, Wang PY, Chao HM, Huang CH, Liu HS, *et al*. Grape seed procyanidins improve diabetic symptoms in mice with streptozotocin-induced diabetes. *Open Physiol J* 2009; 2:6-13.
10. Harris EH. Elevated liver function tests in type 2 diabetes. *Clin Diabetes* 2005; 23:115-119.
11. Kamel ZH, Daw I, Marzouk M. Effect of cichorium endivia leaves on some biochemical parameters in

streptozotocin-induced diabetic rats. *Aust J Basic Appl Sci* 2011; 5:387-396.

12. Maiti R, Jana D, Das UK, Ghosh D. Antidiabetic effect of aqueous extract of seed of *Tamarindus indica* in streptozotocin-induced diabetic rats. *J Ethnopharmacol* 2004; 92:85-91.

13. Issabeagloo E, Ahmadpoor F, Kermanizadeh P, Taghizadieh M. Hepatoprotective effect of green tea on hepatic injury due to leflunomide in rat. *Asian J*

Exp Biol Sci 2012; 3:136-141.

14. Al-Rawi NH. Oxidative stress, antioxidant status and lipid profile in the saliva of type 2 diabetics. *Diab Vasc Dis Res* 2011; 8:22-28.

15. Chis IC, Ungureanu MI, Marton A, Simedrea R, Muresan A, Postescu ID, *et al.* Antioxidant effects of a grape seed extract in a rat model of diabetes mellitus. *Diab Vasc Dis Res* 2009; 6:200-204.

Archive of SID