Iranian Journal of Basic Medical Sciences

ijbms.mums.ac.ir

# Effect of *Nigella sativa* on ischemia-reperfusion induced rat kidney damage

Shahrzad Havakhah [1], Hamid R Sadeghnia [2], Mosa-Al-Reza Hajzadeh [3], Nama Mohammadian Roshan [4], Somayeh Shafiee [1], Hossein Hosseinzadeh [5], Narges Mohareri [6], Abolfazl Khajavi Rad [7]*

[1] Department of Physiology, School of Medicine, Mashhad University of Medical Sciences, Mashhad, Iran
[2] Pharmacological Research Center of Medicinal Plants, School of Medicine, Mashhad University of Medical Sciences, Mashhad, Iran
[3] Neurocognitive Research Center, School of Medicine, Mashhad University of Medical Sciences, Mashhad, Iran
[4] Department of Pathology, Ghaem Hospital, Mashhad University of Medical Sciences, Mashhad, Iran
[5] Pharmaceutical Research Center, School of Pharmacy, Mashhad University of Medical Sciences, Mashhad, Iran
[6] Department of Pharmacodynamy and Toxicology, School of Pharmacy, Mashhad University of Medical Sciences, Mashhad, Iran
[7] Neuroinflammation Research Center, School of Medicine, Mashhad University of Medical Sciences, Mashhad, Iran

**ARTICLE INFO**

***Article type:***
Original article

***Article history:***
Received: Sep 17, 2014
Accepted: Dec 31, 2014

***Keywords:***
Comet assay
Ischemia-reperfusion injury (IRI)
Kidney
*Nigella sativa*
Oxidative stress

**ABSTRACT**

***Objective(s):*** There are a few previously reported studies about the effect of *Nigella sativa* oil on renal ischemia-reperfusion injury (IRI). The aim of the present study was to test the hypothesis whether pre- or post-treatment with *N. sativa* hydroalcoholic extract (NSE) would reduce tissue injury and oxidative damages in a clinically relevant rat model of renal IRI.
***Materials and Methods:*** IRI was induced by clamping of bilateral renal arteries for 40 min fallowed by reperfusion for 180 min. NSE was prepared in a Soxhlet extractor and administrated with doses of 150 mg/kg or 300 mg/kg at 1 hr before ischemia induction (P-150 and 300) or at the beginning of reperfusion phase (T-150 and 300), via jugular catheter intravenously. The kidneys were then removed and subjected to biochemical analysis, comet assay or histopathological examination.
***Results:*** The kidneys of untreated IRI rats had a higher histopathological score ($P<0.001$), while in P-150, as well as T-150 and T-300 groups tubular lesions significantly decreased ($P<0.001$). Pre- and post-treatment with NSE also resulted in a significant decrease in malondialdehyde (MDA) level ($P<0.001$) and DNA damage ($P<0.001$) that were increased by renal I/R injury. NSE treatment also significantly restore ($P<0.01$) the decrease in renal thiol content caused by IRI.
***Conclusion:*** The present study shows *N. sativa* extract has marked protective action against renal IRI, which may be partly due to its antioxidant effects.

► *Please cite this paper as:*
Havakhah Sh, Sadeghnia HR, Hajzadeh MR, Mohammadian Roshan N, Shafiee S, Hosseinzadeh H, Mohareri N, Khajavi Rad A. Effect of *Nigella sativa* on ischemia-reperfusion induced rat kidney damage. Iran J Basic Med Sci 2014; 17:986-992.

## Introduction

Renal ischemic-reperfusion injury (IRI) is a complex pathophysiological process that occurs after cardiac arrest, kidney transplantation, hemi nephrectomy and vascular surgery. IRI causes renal cell death, acute kidney injury (AKI), formerly known as "acute renal failure", acute tubular necrosis (ATN), acute rejection, delayed graft function, and chronic allograft dysfunction. Basic mechanisms of renal ischemic-reperfusion injury are multifactorial and interrelated including anoxia, free radicals generation especially during reperfusion and inflammation responses (1).

Ethnobotanicals are important for pharmacological research and drug development, not only when plant constituents are used directly as therapeutic agents, but also as founding materials for the synthesis of drugs or as models for pharmacologically active compounds. It is estimated that about 25% of the drugs prescribed worldwide are derived from plants (2).

*Nigella sativa*, which belongs to the Ranunculaceae family, commonly grows in Eastern Europe, Mediterranean regions, the Middle East, and Western Asia. Seeds of *N. sativa*, also known as black cumin (English), black caraway (USA) and shonaiz (Persian), frequently used in folk medicine for promoting health and treatment of many diseases such as asthma, rheumatic diseases, microbial infections and cancer (3). Recent clinical and experimental researches have shown many pharmacological properties, like immunomodulatory (4), anti-inflammatory (5), antioxidant (6), anticarcinogenic (7), antihypertensive (8), anti-ischemic (9) and renal calculi prevention (10).

Hosseinzadeh and Montahaei showed that acute administration of aqueous or ethanolic extract of *N. sativa* and thymoquinone following 60 min warm renal ischemia, significantly improved oxidative stress markers in kidney tissue (11). It has been shown that pre- and post-treatment with *N. sativa* seed oil significantly protect oxidative damage and prevent tissue damage following renal IRI (12).

**Corresponding author:* Abolfazl Khajavi Rad. Department of Physiology, School of Medicine, Mashhad University of Medical Sciences, Mashhad, Iran. Tel: +98-513-8002229; Fax: +98-513-8828564; email: khajavirada@mums.ac.ir

Archive of SID

www.SID.ir

Moreover, treatment with *N. sativa* oil 6 hr prior to ischemia-reperfusion and at the beginning of reperfusion reduced renal oxidative stress markers and tubular necrosis score (9). Science there is no previously reported study on the effect of hydroalcoholic extract of *N. sativa* (NSE) on histological and DNA damages induced by renal I/R injury, the present study was designed to test whether pre- or post-treatment with NSE would reduce tissue injury and oxidative damages in a clinically relevant rat model of renal IRI.

## Material and Methods

### *Animals*

Adult male Wistar rats weighting 250-300 g from the Central Animal House of Mashhad University of Medical Sciences (Mashhad, Iran), were used throughout the study. The animals were housed in the same room under a constant temperature (22± 2˚C) and standard conditions of a 12 hr light/dark cycle with free access to food pellets and tap water, available *ad libitum*.

The experimental protocol was approved by the Animal Care and Use Committee, Mashhad University of Medical Sciences and was performed in accordance with the National Institutes of Health Guidelines for the Care and Use of Laboratory Animals.

### *Preparation of hydroalcoholic extract of N. sativa (NSE)*

The seeds of *N. sativa* were obtained from Medicinal Plants Division of Imam Reza Pharmacy (herbarium No. 80140). They were washed, dried, and crushed to a powder with an electric microniser. The powdered seeds (100 g) were extracted in a Soxhlet extractor with ethanol (70%). The resulting extract was concentrated under reduced pressure and kept at -20˚C until use (yielded 32%).

### *Chemicals*

5, 5´-dithiobis-2-nitrobenzoic acid (DTNB), 2-thiobarbituric acid (TBA), trichloroacetic acid (TCA), ethylenediaminetetraacetic acid disodium salt ($Na_2EDTA$), t-octylphenoxypoly-ethoxyethanol (Triton X-100), tris (hydroxymethyl) aminomethane (Trizma base), sodium lauroylsarcosinate (sarkosyl, SLS), sodium dodecyl sulphate (SDS), dimethylsulfoxide (DMSO), ethanol, sodium hydroxide (NaOH) and potassium chloride (KCl) were obtained from Merck (Darmstadt, Germany). Low melting point (LMP) agarose and normal melting point (NMP) agarose were purchased from Fermentas (Glen Burnie, MD). LMP and NMP agarose were diluted in physiological saline to 0.5% and 1%, respectively.

### *Study design and induction of renal IRI*

The rats were randomly assigned to one of the following six experimental groups, each consisting of eight animals: control group (sham-operated animals) underwent all surgical procedures similar to all other groups, except that the renal artery was not clamped; Ischemia-reperfusion injury (IRI) group underwent both renal arteries clamped for 40 min (ischemia phase) and fallowed by reperfusion for 180 min (reperfusion phase); Preventive-150 group (P-150) underwent 40 min ischemia and NSE was injected with a dose of 150 mg/kg at 1 hr before ischemia induction (control phase); Preventive-300 group (P-300) underwent 40 min ischemia and NSE was injected with a dose of 300 mg/kg at the beginning of control phase; Treatment-150 group (T-150) underwent 40 min ischemia and NSE was injected with a dose of 150 mg/kg at the beginning of reperfusion phase and Treatment-300 group (T-300) underwent 40 min ischemia and extract was injected with a dose of 300 mg/kg at the beginning of reperfusion phase.

Rats were anaesthetized with intraperitoneal (IP) injection of sodium pentabarbital (70 mg/kg) under sterile condition. At first the neck exposed in midline and jugular vein and carotid artery dissected from the surrounding tissues and canulated for infusion of fluids and extract and connected to power lab system for monitoring and collecting blood samples, respectively. A midline incision was made, kidneys were exposed and renal arteries dissected from surrounding tissues. Ischemia was induced by bilateral renal artery clamping for 40 min with smooth vascular clamps. After the clamps were removed, the kidneys were inspected for restoration of blood flow. After bilateral nephrectomies were carried out, the half of both kidneys were stored at -70˚C for biochemical analysis and comet assay, whereas the other half of kidneys were fixed in 10% formalin for histopathological examination.

### *Histopathological examination*

Formalin-fixed tissue samples were embedded in paraffin, cut at 5 µm, and stained with hematoxylin and eosin (H & E). Tubular injury was scored in a blinded manner by estimation of the percentage of tubules in the outer medulla and corticomedullary junction that showed epithelial necrosis, debris or cast as follows: Grade 0, no morphologic changes; grade 1, <25%; grade 2, <50% and grade 3, <75% involved. More than 20 consecutive fields were examined under ×400 magnification and averaged per slide (13).

### *Thiobarbituric acid reactive species measurement*

Renal lipid peroxides formation was measured as malondialdehyde (MDA), which is the end product of lipid peroxidation and reacts with thiobarbituric acid (TBA) as a TBA reactive substance (TBARS) to produce a pink colored complex which has peak

Archive of SID


www.SID.ir

absorbance at 535 nm (14). In brief, 1 ml of homogenate sample was mixed with 2 ml of TCA-TBA-HCl reagent (15% TCA, 0.67% TBA, and 0.25 N HCl) and heated for 45 min in a boiling water bath. After cooling, the mixture was centrifuged at 3000 rpm for 10 min. The supernatant was collected, and the absorbance was read against blank, at 535 nm. The amount of MDA produced was calculated, using a molar absorption coefficient of $1.56\times10^5$ $M^{-1}cm^{-1}$ and expressed as nmol/g tissue (15).

***Total sulfhydryl (SH) groups measurement***

Total thiol content was estimated based on the Ellman method (16). In this method, SH groups react with chromogenic DTNB and produce a yellow-colored dianion (5-thio-2- nitrobenzoic acid, TNB), which has peak absorbance at 412 nm. Briefly, 1 ml Tris-EDTA buffer (0.1 M Tris, 10 mM EDTA, pH=8.6) was added to 50 µl homogenate sample in 2 ml cuvettes. Sample absorbance was read at 412 nm against Tris-EDTA buffer alone ($A_1$), then 20 µl DTNB reagent (10 mM in methanol) was added to the mixture. Following 15 min incubation at room temperature, the sample absorbance was read again ($A_2$). DTNB reagent absorbance was also read as a blank (B). Total thiol concentration was calculated by the following equation and expressed as nmol/mg tissue (15).

Total thiol concentration (mM)= $(A_2-A_1-B) \times (1.07/0.05)$ 13.6

***Single cell gel electrophoresis (SCGE, Comet) assay***

The *in vivo* alkaline SCGE assay was conducted based on the method described previously (17). After weighing, the samples were minced, suspended at a concentration of 0.5 g/ml in chilled homogenizing buffer containing 0.075 M NaCl and 0.024 M $Na_2EDTA$ (pH 7.5), and then homogenized gently at 500-800 rpm in ice. To obtain nuclei, the homogenate was centrifuged at 700 g for 10 min at 0˚C, and the precipitate was resuspended in chilled homogenizing buffer at 0.5 g/ml and allowed to settle; precipitated clumps were then removed. 80 µl NMP agarose was quickly layered on conventional slides, covered with a cover slip, and then the slides were placed on ice to allow agarose to gel. Five microliters of the nucleus suspension, prepared as above, was mixed with 75 µl LMP agarose and the mixture was quickly layered over the NMP agarose layer after removal of the cover slip. Finally, another layer of LMP agarose was added on top. The slides were immersed immediately in a chilled lysing solution (pH = 10) made up of 2.5 M NaCl, 100 mM $Na_2EDTA$, 10 mM Trizma, 1% sarkosyl, 10% DMSO, and 1% Triton X-100 and kept at 0˚C in the dark overnight. Then, the slides were placed on a horizontal gel electrophoresis platform and covered with a prechilled alkaline solution made up of 300 mM NaOH and 1 mM $Na_2EDTA$ (pH > 13). They were left in the solution in the dark at 0˚C for 40 min and then electrophoresed at 0˚C in the dark for 30 min at 25 V and approximately 300 mA. The slides were rinsed gently three times with 400 mM Trizma solution (adjusted to pH 7.5 with HCl) to neutralize the excess alkali, stained with 50 µl of 20 µg/ml ethidium bromide and covered with a cover slip. For comet analysis, 100 nuclei were randomly selected from two replicated slides (50 nuclei on each slide), examined and photographed through a fluorescence microscope (Nikon, Japan), at 400x magnification equipped with an excitation filter of 520-550 nm and a barrier filter of 580 nm. Undamaged cells resemble an intact nucleus without a tail, and damaged cells have the appearance of a comet. The percent of DNA in the comet tail (% tail DNA), which is an estimation of DNA damage, was analyzed using the computerized image analysis (CASP) software.

***Statistical analysis***

Data are presented as mean±SEM. Statistical analysis was performed using one-way ANOVA followed by Tukey-Kramer *post-hoc* test. The *P*-values less than 0.05 were considered to be statistically significant.

## Results

***NSE ameliorates renal histologic damage following IRI***

The histopathologic changes were graded and summarized as % renal tissue damage in Figure 1G. There were significant tubular changes including loss of brush border, dilation of renal tubules, cast formation as well as degeneration and necrosis of renal tubular epithelial cells following IRI compared with the sham group (Figure 1A-G). In contrast, pretreatment with low dose of NSE (P-150), as well as treatment with NSE (T-150 and T-300) significantly ameliorated tubular lesions from grade 2 (<50% renal tissue damage in IRI group) to grade 1 (<25% injury) (Figure 1A-G).

***NSE reduces renal lipid peroxidation following IRI***

The renal MDA content was elevated (about 38%) following induction of renal IRI compared to the normal sham-operated group (Figure 2; $P<0.05$). However, NSE pretreatment resulted in a significant decrease in MDA level compared to the IRI group ($P<0.05$). As shown in Figure 2, NSE at doses of 150 mg/kg and 300 mg/kg decreased renal TBARS levels about 44.5% ($P<0.001$) and 25% ($P<0.05$) following IRI, respectively. Further however, renal MDA content was not significantly affected by treatment with concentrations up to 300 mg/kg NSE.

***NSE increases renal total thiol content following IRI***

Renal IRI resulted in a significant decrease in renal thiol content when compared to normal sham-

Archive of SID


www.SID.ir

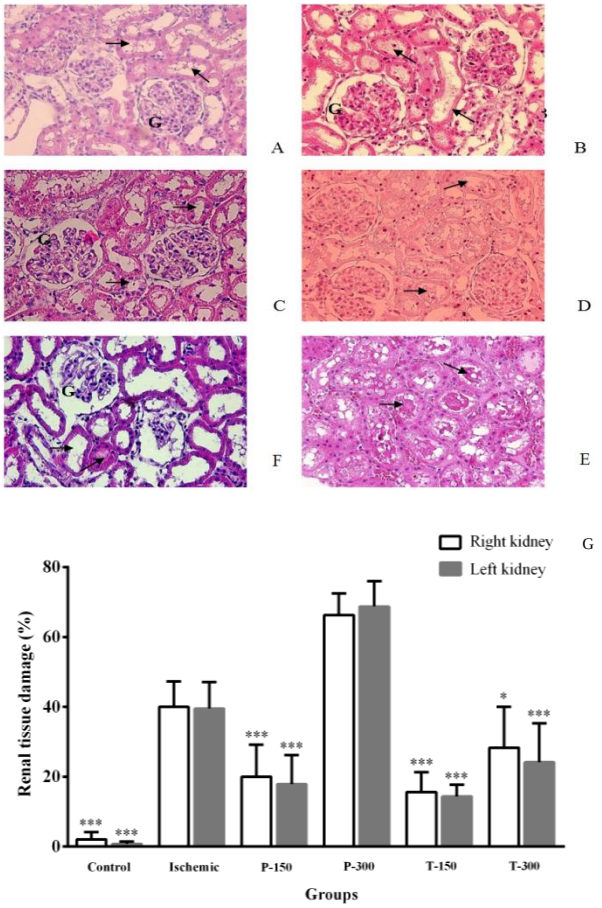


**Figure 1A-G.** Effect of *Nigella sativa* hydroalcoholic extract (NSE) on histologic changes induced by renal ischemia-reperfusion injury (IRI). Rat's kidney sections were stained by hematoxylin and eosin (H & E) and examined using a light microscope (×400). Arrow heads show kidney tubules and G represents renal glomeruli. Rats treated with NSE (150 and 300 mg/kg) 1 hr prior (P-150 and P-300) and right after (T-150 and T-300) the reperfusion. A: Control (sham) group with normal renal morphology, B: IRI group with the distinctive pattern of ischemic renal injury (dilation of renal tubules, cast formation as well as tubular epithelial cells necrosis), C: P-150 group with relatively well-preserved architecture and focal tubular necrosis, D: P-300 group with greater tubular necrosis, E: T-150 group with relatively well-preserved architecture and cast formation, F: T-300 group with lower degree of vacuolization and cast formation, G: Histopathological score in experimental groups, values are mean±SEM (n = 8 per group) and analyzed using one-way ANOVA followed by Tukey-Kramer post-hoc test. * $P<0.05$ and *** $P<0.001$ compared to IRI group

operated rats ($P<0.01$; Figure 3). As Figure 3 illustrates, renal thiol content was not significantly increased following NSE pre-treatment in comparison with IRI group ($P>0.05$). On the other hand, a significant restoration in the total thiol levels was observed in NSE treated rats, as compare to IRI group.

### *NSE decreases oxidative DNA damage following renal IRI*

Figure 4A-D shows represented comet images from different treatment group. A significant increase in the % tail DNA was seen in nuclei of renal

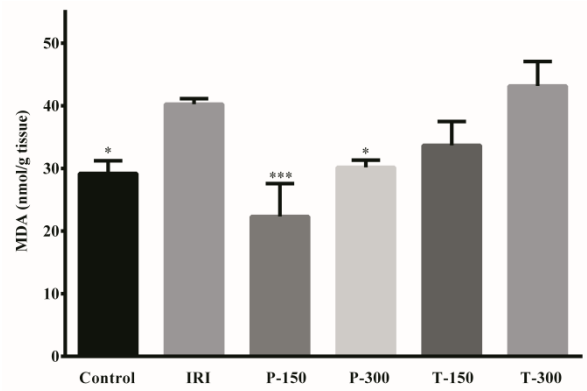


**Figure 2.** Effect of *Nigella sativa* hydroalcoholic extract (NSE) on tissue malondialdehyde (MDA) level following renal ischemia-reperfusion injury (IRI). Rats treated with NSE (150 and 300 mg/kg) 1 hr prior (P-150 and P-300) and right after (T-150 and T-300) the reperfusion. Values are mean±SEM (n = 8 per group) and analyzed using one-way ANOVA followed by Tukey-Kramer post-hoc test. * $P<0.05$ and *** $P<0.001$ compared to IRI group

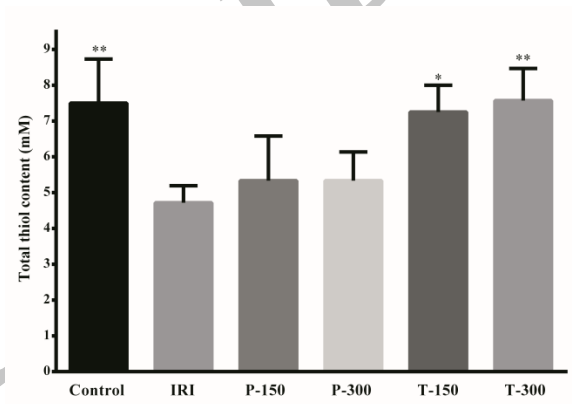


**Figure 3.** Effect of *Nigella sativa* hydroalcoholic extract (NSE) on tissue thiol content following renal ischemia-reperfusion injury (IRI). Rats treated with NSE (150 and 300 mg/kg) 1 hr prior (P-150 and P-300) and right after (T-150 and T-300) the reperfusion. Values are mean ± SEM (n = 8 per group) and analyzed using one-way ANOVA followed by Tukey-Kramer post-hoc test. * $P<0.05$ and ** $P<0.01$ compared to IRI group

ischemic group, as compared to those of saline-treated sham-operated animals ($P<0.001$; Figure 4F). The ischemic-induced DNA damage in NSE-treated animals was decreased about 3.6 fold (150 mg/kg) and 3.2 fold (300 mg/kg) as compared to that of ischemic animals alone ($P<0.001$; Figure 4E). On the other hand, pretreatment with NSE did not significantly decrease DNA damage induced by ischemic insult (Figure 4E).

## Discussion

The aim of the present study was to test whether pre- and post-treatment with *N. sativa* hydro-alcoholic extract would reduce tissue injury and oxidative damages in a clinically relevant rat model of kidney ischemia/reperfusion injury. The results demonstrated that IRI produced significant changes in the renal histopathologic features, induced lipid peroxidation, reduced the total thiol levels and

Archive of SID


www.SID.ir

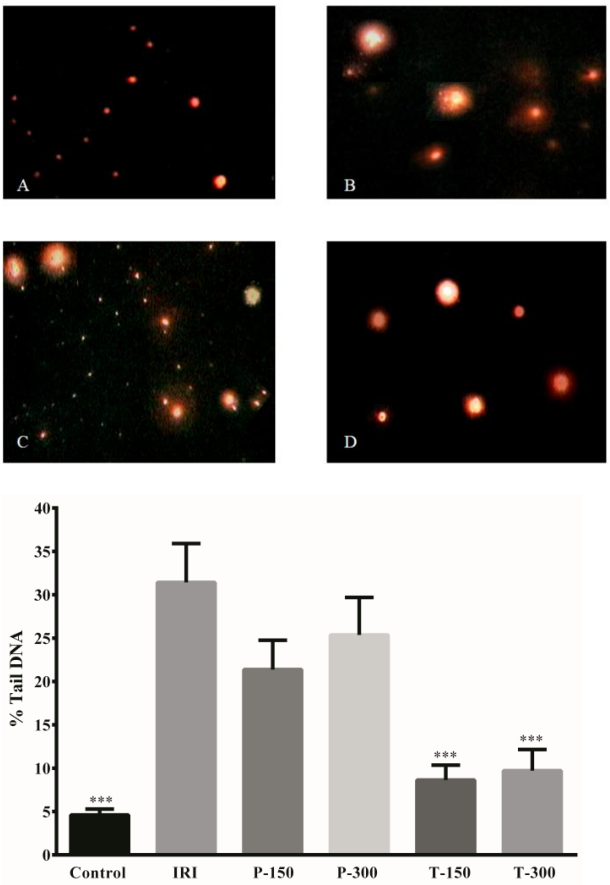


**Figure 4 A-E.** Effect of *Nigella sativa* hydroalcoholic extract (NSE) on DNA damage following renal ischemia-reperfusion injury (IRI). Rats treated with NSE (150 and 300 mg/kg) 1 h prior (P-150 and P-300) and right after (T-150 and T-300) the reperfusion. Nuclei from tissue homogenates were stained by editium bromide and examined using a fleourecent microscope (×400). A-D: Representative photomicrographs of comets showing NSE restores DNA integrity of ischemic injured cells. A: Control (sham), B: IRI, C: P-300 and D: T-300 groups. E: Bar graph showing the mean percentage of DNA in comet tails. Values are mean ± SEM and analyzed using one-way ANOVA followed by Tukey-Kramer post-hoc test. *** $P<0.001$ compared to IRI group

caused oxidative DNA damages. Pre- and post-treatment with NSE significantly attenuated renal oxidative stress and preserved the normal morphology of kidney.

IRI is an important cause of acute kidney injury (AKI), formerly known as acute renal failure, in native and transplanted kidneys. AKI is a complex syndrome characterized by vasoconstriction, glomerular injury with major reductions in glomerular filtration rate, extensive tubular damages and tubular cell necrosis (18). Most of these tubular and glomerular damages occur during the reperfusion phase following ischemia, and generation of reactive oxygen species (ROS). ROS are capable of reacting with lipids, proteins and nucleic acids leading to lipid peroxidation, impairments of enzymatic processes and DNA damages, thereby, inhibiting transcription and repair. Ahmadiasl *et al* have shown that in the rat model of renal IRI, there is significant increase in renal oxidative stress that leads to both structural and functional damages (19).

Lipid peroxidation, mediated by ROS, is an essential cause of destruction and damage to cell membranes following renal IRI (18). In the present study there was an increase in MDA content of renal tissue in the IRI group compared with sham-operated rats. These data are in good agreement with the work of Bayrak *et al* who found high lipid peroxidation after renal I/R injury in rats (12). Our study also showed that NSE could reverse the increase of MDA levels to a considerable extent. Among all endogenous antioxidant mechanisms, thiols constitute the major portion of the total body antioxidants and they play a significant role in defense against ROS. Total thiols composed of both intracellular and extracellular thiols either in the free form as oxidized, reduced glutathione, or thiols bound to proteins, which scavenge oxygen free radicals (20). We observed a significant decrease in thiols content during ischemia/reperfusion injury. Such reduction in total thiol levels has shown to occur in the kidney after a period of IRI leading to oxidative stress and cellular damages (21). Moreover, we showed that thiol groups increased following NSE treatment, thereby confirming its antioxidant role in IRI. These findings are in agreement with those of Hosseinzadeh *et al*, reporting that warm ischemia for 60 min followed by reperfusion for 90 min causes a significant increase in renal lipid peroxidation along with considerable reduction in tissue thiol level (21). We found that IRI caused renal oxidative stress, oxidative DNA damage and structural injury significantly. Consistent with these findings, Simon *et al* demonstrated that aortic occlusion-induced kidney ischemia/reperfusion injury increased kidney oxidative DNA base damage which coincided with histopathology and apoptosis (22).

Other reports about modulatory effect of *N. sativa* against ischemic reperfusion injuries show that it improves rat cardiac musculature, mitochondrial dysfunction and subsequent lipid peroxidation post I/R insult (23). The *in vivo* and *in vitro* inhibitory effects of *N. sativa* against cerebral IRI are also reported (24-26). Ameliorating effects of different extracts of *N. sativa* (aqueous, hydroalcoholic, chloroform and petroleum ether) in middle cerebral artery occluded rat were shown via reduction in lipid peroxidation and elevation in glutathione and antioxidant enzymes, superoxide dismutase and catalase (27, 28). Hobbenaghi *et al* also found that *N. sativa* extract decreases hippocampal neurons edema and astrocytes death following global cerebral IRI in rats (24). Similarly, in a rat model of gastric mucosal I/R injury, *N. sativa* normalizes the level of lipid peroxidation, glutathione, superoxide dismutase and lactate dehydrogenase (29). Moreover, Yildiz *et al* also showed that *N. sativa* seed oil prevents histological liver damage induced by IRI via decreasing oxidative stress biomarkers (30). Moreover, NSE reduces tissue

Archive of SID


www.SID.ir

damages in rat ovaries subjected to IRI by attenuating oxidative and inflammatory responses (31). It was shown that inflammatory responses play critical roles in ischemic renal injury (18) Using $^{18}$F-fluoro-deoxy-D-glucose-positron emission tomography ($^{18}$FDG-PET) imaging, Entok *et al* demonstrated that *N. sativa* (500 mg/kg) and essential oil (5 ml/kg) treatment caused a significant reduction in lipopolysaccharides-induced lung and liver acute inflammation. This anti-inflammatory effect coincides with decreased tissue levels of MDA, nitric oxide and DNA fragmentation and also conserved antioxidant enzymes, superoxide dismutase and catalase activities (32). Bayrak *et al* showed that pre- and post-treatment with *N. sativa* seed oil significantly reduced renal histopathological score, improved renal function and serum and tissue anti-oxidative parameters following IRI (12). In the same manner, Yildiz *et al* confirmed that pre-treatment with *N. sativa* oil was effective against renal IRI by reducing serum urea and creatinine levels as well as decreasing the tubular necrosis score and improving blood and renal oxidative and antioxidative status (9). Our study has several differences and advantages to other studies. It is well documented that ischemic acute renal failure (ARF) is associated with high mortality in humans and current therapy is limited to supportive measures and preventive strategies, none of which have been definitively shown to alter mortality (33). We administrated NSE intravenously with increasing doses (150 and 300 mg/kg) either 1 hr before induction of ischemia or at the beginning of the reperfusion phase, to better understanding the time course of drug action, unlike the study of Bayrak *et al* (12) which *N. sativa* essential oil was administrated orally with single dose for 7 consecutive days prior to surgery (0.3 ml) or right after ischemia (0.6 ml). The constituents of *N. sativa* essential oil are quite different from NSE. It has also been shown that acute renal failure from ischemia-reperfusion is associated with tubule cell apoptosis (34). This study focuses on possible protective effects of NSE on DNA damage using comet assay as an index of apoptotic cell death.

## Conclusion

In the present study, *N. sativa* hydroalcoholic extract had marked protective action against renal IRI. These findings are important as there is no previously reported study on the effect of NSE on histological and DNA damages induced by renal IRI. In conclusion, in view of previous reports regarding potent antioxidant and anti-inflammatory and our data, NSE seems to be a highly promising nephroprotective agent against renal I/R injury.

## Acknowledgment

This work was supported by a grant from Vice Chancelor for Research and Technology of Mashhad University of Medical Sciences (MUMS), as a part of MSc thesis presented by the first author.

## References

1. Bonventre JV, Yang L. Cellular pathophysiology of ischemic acute kidney injury. J Clin Invest 2011; 121:4210-4221.
2. Wachtel-Galor S, Benzie IFF. Herbal medicine: An introduction to Its history, usage, regulation, current trends, and research needs. In: Benzie IFF, Wachtel-Galor S, editors. Herbal Medicine: Biomolecular and Clinical Aspects. 2nd ed. Boca Raton (FL): CRC Press; 2011.
3. Randhawa MA, Alghamdi MS. Anticancer activity of *Nigella sativa* (black seed) - a review. Am J Chin Med 2011; 39:1075-1091.
4. Salem ML. Immunomodulatory and therapeutic properties of the *Nigella sativa* L. seed. Int Immunopharmacol 2005; 5:1749-1770.
5. Houghton PJ, Zarka R, de las Heras B, Hoult JR. Fixed oil of *Nigella sativa* and derived thymoquinone inhibit eicosanoid generation in leukocytes and membrane lipid peroxidation. Planta Med 1995; 61:33-36.
6. Burits M, Bucar F. Antioxidant activity of *Nigella sativa* essential oil. Phytother Res 2000; 14:323-328.
7. Ait Mbarek L, Ait Mouse H, Elabbadi N, Bensalah M, Gamouh A, Aboufatima R, *et al*. Anti-tumor properties of blackseed (*Nigella sativa* L.) extracts. Braz J Med Biol Res 2007; 40:839-847.
8. el Tahir KE, Ashour MM, al-Harbi MM. The cardiovascular actions of the volatile oil of the black seed (*Nigella sativa*) in rats: elucidation of the mechanism of action. Gen Pharmacol 1993; 24:1123-1131.
9. Yildiz F, Coban S, Terzi A, Savas M, Bitiren M, Celik H, *et al*. Protective effects of *Nigella sativa* against ischemia-reperfusion injury of kidneys. Ren Fail 2010; 32:126-131.
10. Hadjzadeh MA, Khoei A, Hadjzadeh Z, Parizady M. Ethanolic extract of *Nigella sativa* L seeds on ethylene glycol-induced kidney calculi in rats. Urology J 2007; 4:86-90.
11. Hosseinzadeh H, Montahaei R. Protective effect of *Nigella sativa* L. extracts and thymoquinone, its active constituent, on renal ischemia-reperfusion-induced oxidative damage in rats. Pharmacologyonline 2007; 1:176-189.
12. Bayrak O, Bavbek N, Karatas OF, Bayrak R, Catal F, Cimentepe E, *et al*. *Nigella sativa* protects against ischaemia/reperfusion injury in rat kidneys. Nephrol Dial Transplant 2008; 23:2206-2212.
13. Kojima I, Tanaka T, Inagi R, Kato H, Yamashita T, Sakiyama A, *et al*. Protective role of hypoxia-inducible factor-2alpha against ischemic damage and oxidative stress in the kidney. J Am Soc Nephrol 2007; 18:1218-1226.
14. Buege JA, Aust SD. Microsomal lipid peroxidation. Methods Enzymol 1978; 52:302-310.
15. Sadeghnia HR, Kamkar M, Assadpour E, Boroushaki MT, Ghorbani A. Protective effect of safranal, a constituent of crocus sativus, on quinolinic acid-induced oxidative damage in rat hippocampus. Iran J Basic Med Sci 2013; 16:73-82.

Archive of SID


www.SID.ir

16. Ellman GL. Tissue sulfhydryl groups. Arch Biochem Biophys 1959; 82:70-77.
17. Hosseinzadeh H, Abootorabi A, Sadeghnia HR. Protective effect of Crocus sativus stigma extract and crocin (trans-crocin 4) on methyl methanesulfonate-induced DNA damage in mice organs. DNA Cell Biol. 2008; 27:657-664.
18. Devarajan P. Update on mechanisms of ischemic acute kidney injury. J Am Soc Nephrol 2006; 17:1503-1520.
19. Ahmadiasl N, Banaei S, Alihemmati A. Combination antioxidant effect of erythropoietin and melatonin on renal ischemia-reperfusion injury in rats. Iran J Basic Med Sci 2013; 16:1209-1216.
20. Prakash M, Shetty MS, Tilak P, Anwar N. Total thiols: Biomedical importance and their alteration in various disorders. Online J Health Allied Scs 2009; 8:2.
21. Hosseinzadeh H, Sadeghnia HR, Ziaee T, Danaee A. Protective effect of aqueous saffron extract (*Crocus sativus* L.) and crocin, its active constituent, on renal ischemia-reperfusion-induced oxidative damage in rats. J Pharm Pharm Sci 2005; 8:387-393.
22. Simon F, Scheuerle A, Groger M, Stahl B, Wachter U, Vogt J, *et al*. Effects of intravenous sulfide during porcine aortic occlusion-induced kidney ischemia/reperfusion injury. Shock 2011; 35:156-163.
23. Seif AA. *Nigella sativa* attenuates myocardial ischemic reperfusion injury in rats. J Physiol Biochem 2013; 69:937-944.
24. Hobbenaghi R, Javanbakht J, Sadeghzadeh S, Kheradmand D, Abdi FS, Jaberi MH, *et al*. Neuroprotective effects of *Nigella sativa* extract on cell death in hippocampal neurons following experimental global cerebral ischemia-reperfusion injury in rats. J Neurol Sci 2014; 337:74-79.
25. Hosseinzadeh H, Parvardeh S, Asl MN, Sadeghnia HR, Ziaee T. Effect of thymoquinone and *Nigella sativa* seeds oil on lipid peroxidation level during global cerebral ischemia-reperfusion injury in rat hippocampus. Phytomedicine 2007; 14:621-627.
26. Mousavi SH, Tayarani-Najaran Z, Asghari M, Sadeghnia HR. Protective effect of Nigella sativa extract and thymoquinone on serum/glucose deprivation-induced PC12 cells death. Cell Mol Neurobiol 2010; 30:591-598.
27. Akhtar M, Maikiyo AM, Najmi AK, Khanam R, Mujeeb M, Aqil M. Neuroprotective effects of chloroform and petroleum ether extracts of *Nigella sativa* seeds in stroke model of rat. J Pharm Bioallied Sci 2013; 5:119-125.
28. Akhtar M, Maikiyo AM, Khanam R, Mujeeb M, Aqil M, Najmi AK. Ameliorating effects of two extracts of *Nigella sativa* in middle cerebral artery occluded rat. J Pharm Bioallied Sci 2012; 4:70-75.
29. El-Abhar HS, Abdallah DM, Saleh S. Gastroprotective activity of *Nigella sativa* oil and its constituent, thymoquinone, against gastric mucosal injury induced by ischaemia/reperfusion in rats. J Ethnopharmacol 2003; 84:251-258.
30. Yildiz F, Coban S, Terzi A, Ates M, Aksoy N, Cakir H, *et al*. *Nigella sativa* relieves the deleterious effects of ischemia reperfusion injury on liver. World J Gastroenterol 2008; 14:5204-5209.
31. Bayir Y, Karagoz Y, Karakus E, Albayrak A, Sengul O, Can I, *et al*. *Nigella sativa* reduces tissue damage in rat ovaries subjected to torsion and detorsion: oxidative stress, proinflammatory response and histopathological evaluation. Gynecol Obstet Invest 2012; 74:41-49.
32. Entok E, Ustuner MC, Ozbayer C, Tekin N, Akyuz F, Yangi B, *et al*. Anti-inflammatuar and anti-oxidative effects of *Nigella sativa* L.: 18FDG-PET imaging of inflammation. Mol Biol Rep 2014; 41:2827-2834.
33. Bonventre JV, Weinberg JM. Recent advances in the pathophysiology of ischemic acute renal failure. J Am Soc Nephrol 2003; 14:2199-2210.
34. Supavekin S, Zhang W, Kucherlapati R, Kaskel FJ, Moore LC, Devarajan P. Differential gene expression following early renal ischemia/reperfusion. Kidney Int 2003; 63:1714-1724.

Archive of SID


www.SID.ir