

Time course changes of oxidative stress and inflammation in hyperoxia-induced acute lung injury in rats

Shouli Yu^{1*}, Min Shi², Changting Liu², Qinghui Liu², Jun Guo², Senyang Yu², Tingshu Jiang³

¹ Department of quality management, Yantai Yuhuangding Hospital Affiliated to Qingdao University, Yantai City, Shandong Province, China

² Department of Nanlou, Respiratory Disease, Chinese PLA General Hospital, Beijing, China

³ Respiratory Department, Yantai Yuhuangding Hospital Affiliated to Qingdao University, Yantai City, Shandong Province, China

ARTICLE INFO	ABSTRACT
<p>Article type: Original article</p> <p>Article history: Received: Jan 28, 2014 Accepted: May 25, 2014</p> <p>Keywords: Acute lung injury Hyperoxia Inflammation Oxidative stress</p>	<p>Objective(s): Therapies with high levels of oxygen are commonly used in the management of critical care. However, prolonged exposure to hyperoxia can cause acute lung injury. Although oxidative stress and inflammation are purported to play an important role in the pathogenesis of acute lung injury, the exact mechanisms are still less known in the hyperoxic acute lung injury (HALI).</p> <p>Materials and Methods: In this study, we investigated the time course changes of oxidative stress and inflammation in lung tissues of rats exposed to >95% oxygen for 12-60 hr.</p> <p>Results: We found that at 12 hr after hyperoxia challenge, the activities of superoxide dismutase and glutathione peroxidase were significantly reduced with remarkably increased lipid peroxidation. At 12 hr, NF-κB p65 expression was also upregulated, but Iκ-Bα expression showed a remarkable decline. Significant production of inflammatory mediators, e.g. interleukin-1β, occurred 24 hr after hyperoxia exposure. In addition, the expression of intracellular adhesion molecule 1 expression and the activity of myeloperoxidase were significantly increased at 24 hr with a peak at 48 hr.</p> <p>Conclusion: Our data support that hyperoxia-induced oxidative damage and NF-κB pathway activation implicate in the early phase of HALI pathogenesis.</p>

► Please cite this paper as:

Yu Sh, Shi M, Liu Ch, Liu Q, Guo J, Jiang T, Yu S. Time course changes of oxidative stress and inflammation in hyperoxia-induced acute lung injury in rats. Iran J Basic Med Sci 2015; 18:98-103.

Introduction

Oxygen therapy (oxygen concentration >60%) is a common medical intervention to critical care patients in order to improve the arterial partial pressure of oxygen and satisfy tissue oxygen demands. Nevertheless, overexposure to high oxygen concentrations may cause serious lung damages (1). Hyperoxic acute lung injury (HALI), a major subtype of lung damages resulting from oxygen poisoning, can develop severe respiratory failure and death. HALI is characterized by the pathological features as diffuse alveolar epithelial damage, vascular endothelial cell swelling, increased pulmonary microvascular permeability, and infiltration of a large number of neutrophils into the lung (2).

Upregulated oxidative stress and reactive chemical species have been intimately associated with the pathogenesis of high-concentration oxygen-related lung damages (3-5). However, HALI is a complex process involving multiple factors that act in concert. Until now, there has not been a systemic study to assess the molecular events during the initiation and development of the mechanistic bases responsible for HALI. It has been suggested that transcription factor activation, proinflammatory cytokine expression, adhesion

molecule involvement, and neutrophil accumulation plays an important role in the development of acute lung injury induced by such endotoxin, ischemia reperfusion, burn, and oleic acid (6), but whether these immunological and molecular events are involved in the occurrence and development of HALI as well as how they are cross-regulated are less known. Rats have been widely used as a model for lung disease studies (7-9). To answer these questions, herein we established a HALI model in healthy rats and systemically investigated these events *in vivo* following hyperoxia. The data will undoubtedly shed light on the further study on the pathogenesis of HALI.

Materials and Methods

Animals

Animal care and experimental manipulation were approved by the Institutional Committee on Animal Care and Use. Eighty male Sprague-Dawley rats with a weight range from 200 to 280 g were obtained from Chinese PLA General Hospital Laboratory Animal Center (Beijing, China) and allowed to acclimate to new environment for 2 weeks. The rats were given free access to standard rodent food and tap water.

*Corresponding authors: Shouli Yu. Department of quality management, Yantai Yuhuangding Hospital Affiliated to Qingdao University, email: ytysl@sina.com; Tingshu Jiang, Respiratory Department, Yantai Yuhuangding Hospital Affiliated to Qingdao University, email: fengqiaoyebo@163.com

HALI model

After acclimation, the animals were randomly assigned to one of two groups (n=40 each). One group was exposed to high levels of oxygen (hyperoxia group). Another group served as control exposed to a normal level of oxygen (normoxia group). Exposure to hyperoxia was performed in an airtight plastic chamber with flow rates of oxygen around 5.0 l/min that maintained $\geq 95\%$ oxygen over the course. The oxygen level was constantly monitored with an oxygen sensor. To control the exhaled carbon dioxide levels lower than 0.5%, granular soda lime was used in the chamber.

Sample collection

At 12, 24, 36, 48, and 60 hr after the start of the experiment, eight rats from each group were randomly taken out and given an intraperitoneal injection of 3% pentobarbital sodium (20 mg/kg) to induce anesthesia. About 1 ml common carotid artery blood was collected for the arterial blood gas analysis and then the rats were euthanized.

The whole lung tissue was removed, weighed, and the lung coefficient calculated (lung coefficient = lung wet weight / body weight $\times 100$). The right superior lobe and right middle lobe were excised, liquid nitrogen frozen, and stored at -70°C for later Western blotting analysis. The right inferior lobe was fixed in 4% formaldehyde solution for pathological examination. The inferior lobe of right lung was weighed and dried in an oven at 80°C to calculate the pulmonary wet/dry ratio.

Bronchoalveolar lavage fluid (BALF) was collected in the left lung through a tracheal cannula with cold saline, and about 85% BALF was recovered (~5 ml). A small portion of the BALF was used for white blood cell count, neutrophil percentage, and total protein concentration, and the remainder was immediately spun at 3,000 rpm $\times 15$ min for supernatant and stored at -70°C .

Measurements of antioxidant enzymes, myeloperoxidase, and lipid peroxidation

Frozen lung tissues were homogenized in 10% saline at 4°C and centrifuged at 1500 rpm $\times 15$ min to collect supernatant. Superoxide dismutase (SOD), glutathione peroxidase (GSH-Px), and malondialdehyde (MDA) as an indicator of lipid peroxidation (10) were measured in lung tissues and BALF. Myeloperoxidase (MPO) activity in lung tissues was also determined.

SOD was determined by xanthine oxidase method. GSH-Px was measured by a coupled reaction with glutathione reductase. MDA was measured using a thiobarbituric acid reaction method. MPO was assayed using the H_2O_2 reaction system. All assay kits for SOD, GSH-Px, MDA, and MPO were from

Nanjing Jiancheng Biological Engineering Institute, Nanjing, China.

Lactate dehydrogenase (LDH) activity assay

LDH activity was measured spectrophotometrically using 2,4-dinitrophenylhydrazine as a chromogen as previously described (6).

Measurement of inflammatory mediators

Tumor necrosis factor- α (TNF- α), interleukin-1 β (IL-1 β), and keratinocyte-derived chemokine (KC) were measured using radioimmunoassay kits (PLA General Hospital Science and Technology Development Center RIA Institute, Beijing, China) according to the manufacturer's instructions.

Western blotting

Denatured lung tissue samples were separated by SDS-PAGE, followed by electrotransfer onto a PVDF membrane. After blocking with 5% non-fat milk, the immunoblot was performed by incubation with primary antibodies, mouse anti-NF- κB p65, rabbit anti-I κB - β , or mouse anti-intracellular adhesion molecule 1 (ICAM-1) (all 1/500 dilution) (Santa Cruz Biotechnology, Santa Cruz, USA), followed by incubation with horseradish peroxidase-conjugated secondary antibodies. The immunocomplexes were visualized by chemiluminescence method.

Statistical analysis

All data were analyzed by one-way analysis of variance using SPSS 11 software. The data were expressed as the mean \pm standard deviation. $P < 0.05$ was considered statistically significant.

Results

General animal observation

Throughout the observational period of the study, the rats in the normoxia group did not show any abnormal behaviors, and no pathologic manifestation and statistically significant changes in the immunological and biochemical measure parameters were seen in the normoxia group.

Hyperoxic rats tolerated well until 12 hr. After that, the rats exhibited less physical activity, apathy, dull hair, tachypnea, and cyanotic appearance in the extremities. All these symptoms became severer following prolonged hyperoxia challenge. However, no animals died before the collection of lung samples.

Histopathologic changes in HALI

Hyperoxia-induced lung injury was evaluated by a series of measure parameters including arterial oxygen partial pressure (PaO_2), wet to dry (W/D) ratio, lung coefficient, pulmonary permeability index (= plasma protein content / BALF protein content), total protein concentration, and LDH activity in BALF. Lung injury was also evaluated based on the polymorphonuclear neutrophil infiltration by

determining white blood cell count and percentage of neutrophils in BALF. After hyperoxia exposure for

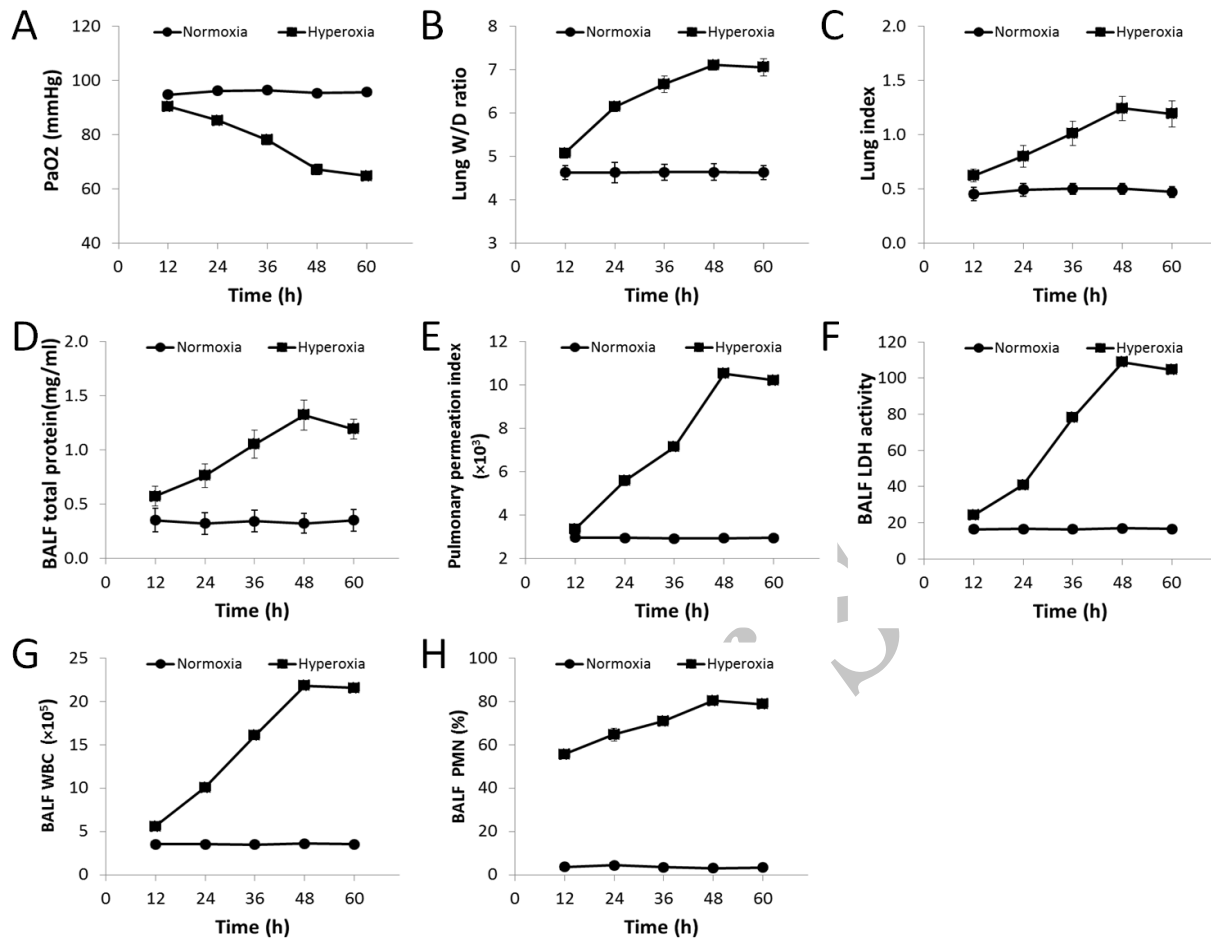


Figure 1. Histopathologic changes in hyperoxic acute lung injury (HALI). Rats were exposed to hyperoxia or room air for 12-60 hr. All error bars were the standard deviations (SD) of the means

12-60 hr, PaO₂ dropped gradually, and there was a significant difference in PaO₂ between the hyperoxia and the normoxia groups during the observational period (all $P_s > 0.05$). Accordingly, other lung injury index, LDH activity, white blood cell count, and neutrophil % in BALF were increased significantly since 12 hr after hyperoxia exposure (all $P_s < 0.05$) and peaked at about 48 hr. Later on at 60 hr, lung W/D ratio and lung coefficient as indicators of pulmonary edema began to decline, but they had no significant difference from 48 hr exposure. Lung pathology revealed alveolar structure disruption, massive PMN infiltration, lung parenchyma wrath bleeding and edema (Figure 1A-HR).

Oxidative stress in HALI

To understand the oxidative stress status in hyperoxia-exposed rats, we assessed SOD and GSH-Px activities and MDA levels in lung homogenate and BALF. Figure 2A-D showed a gradual but significant decline in SOD and GSH-Px activities in lung homogenate and BALF throughout the experimental

period of hyperoxia exposure (all $P_s < 0.05$). On the contrary, hyperoxia induced a significant gradual increase in MDA levels in lung homogenate and BALF (all $P_s < 0.05$) (Figure 2E and HR), indicating hyperoxia induces oxidative stress and oxidative damage at the very early stage of HALI development.

Inflammatory mediators in HALI

When compared to the normoxia group, the hyperoxic rats showed significantly increasing levels of TNF- α , IL-1 β , and KC in lung homogenate and BALF after 24-60 hr hyperoxia exposure (all $P_s < 0.05$) with a peak at 36 hr for TNF- α and IL-1 β and a peak at 48 hr for KC (Figure 3), suggesting that hyperoxia enhances the production of such inflammatory mediators as TNF- α , IL-1 β , and KC in the lung inflammation.

NF- κ B pathway activation in HALI

NF- κ B pathway is important in the control of the production of proinflammatory mediators. Therefore, we further assessed the expression levels

of NF- κ B p65 and I κ -B α in lung tissues of rats exposed to hyperoxia for 12-60 hr. Western blot

analysis showed that hyperoxia induced significantly increased NF- κ B p65 expression throughout the

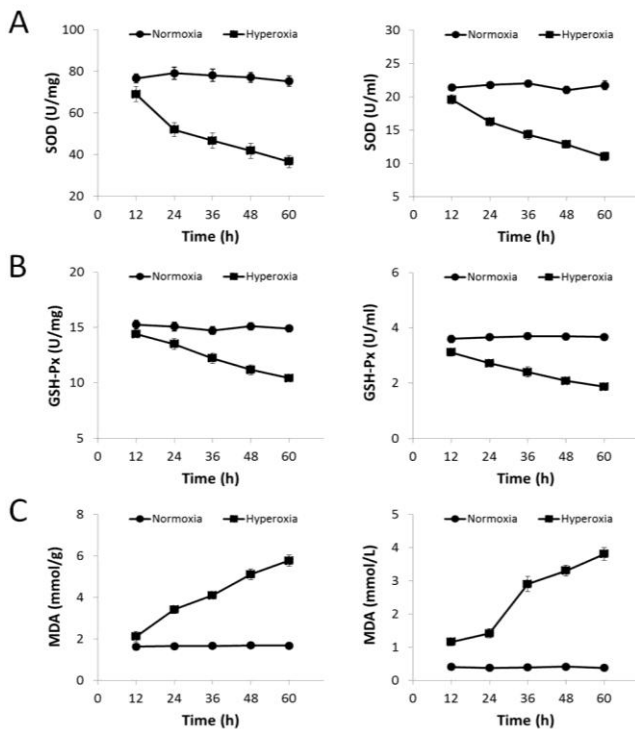


Figure 2. Time course changes of oxidative stress induced by hyperoxia. Rats were exposed to hyperoxia or room air for 24-60 hr, then the SOD (A) and GSH-Px activities (B) and MDA levels (C) in lung homogenate and BALF were measured as described in Materials and Methods. All error bars were the standard deviations (SD) of the means

experimental period (12-60 hr, P s<0.05) with a peak at 24 hr when compared to the normoxia group (Figure 4A and B). On the contrary, hyperoxia exposure remarkably reduced I κ -B α protein expression throughout the observational period with the maximum decrease at 24 hr after exposure (Figure 4A and C), suggesting that hyperoxia activates the NF- κ B signaling pathway.

ICAM-1 expression in HALI

Western blot data showed that ICAM-1 expression was significantly increased in lung tissues 24-60 hr after hyperoxia exposure (all P s<0.05) with a peak at about 48 hr (Figure 4A and D).

Increased MPO activity in HALI

MPO is associated with PMN infiltration. Figure 4 showed that after hyperoxia exposure for 12-60 hr, MPO activity in the lung homogenates was significantly upregulated (all P s<0.05) with a peak at 48, in agreement with the time point for high expression of ICAM-1.

Discussion

We successfully established a rat model of HALI as characterized by such pathologic changes as disrupted lung architecture and infiltrated

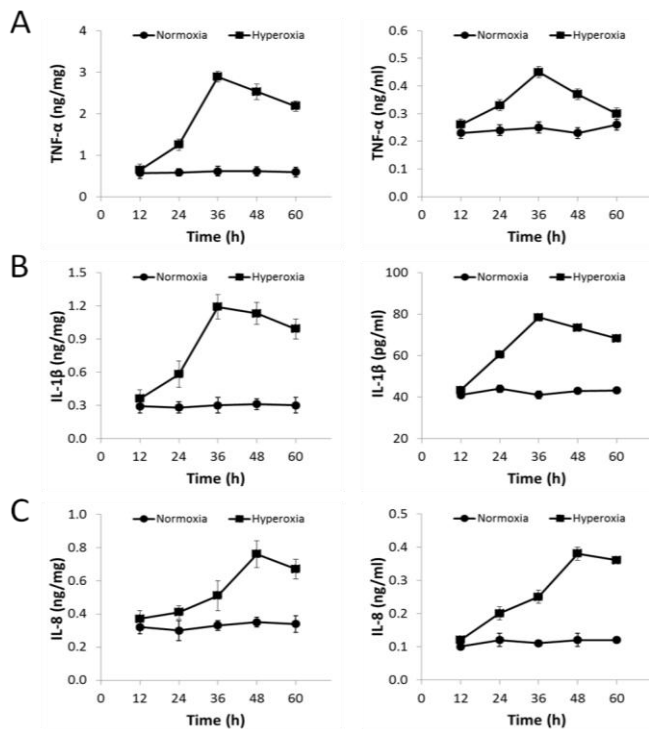


Figure 3. Hyperoxia-induced changes in the production of TNF- α , IL-1 β , and KC. Rats were exposed to hyperoxia or room air for 24-60 hr, then TNF- α (A), IL-1 β (B), and KC (C) in lung homogenate and BALF were assayed by ELISA. All error bars were the standard deviations (SD) of the means

neutrophils in the lung with edema, and demonstrated that oxidative stress and inflammatory injury implicate in the affected lung tissues as early as 12 hr after hyperoxia challenge.

When exposed to high levels of oxygen for certain period of time, the body will lose the ability to scavenge excessive ROS, resulting in alveolar epithelial and pulmonary vascular endothelial membrane injury, lipid peroxidation, hyperpermeability, and intracellular edema (11). We found that there is a significant gradual increase in lipid peroxidation in the lung after exposure to hyperoxia for 12-60 hr, suggesting that oxidative damage appears shortly after oxygen intoxication and further exacerbate if high levels of oxygen could not be removed in time. On the contrary, we found that in contrast to increased lipid peroxidation, SOD and GSH-Px activities were significantly down regulated in the lung tissues following hyperoxia exposure, suggesting that the pathogenesis of hyperoxia-induced lung injury could be at least partially attributed to the development of an oxidant/antioxidant imbalance.

ROS and free radicals have direct deleterious effects on the lung tissues, e.g., lipid peroxidation, protein oxidation, and DNA damage. They can also activate NF- κ B pathway as secondary signaling messengers and consequently amplify the

downstream inflammatory cascades (12). We found that at 12 hr after hyperoxia exposure the expression levels of NF- κ B p65 were significantly increased by approximately 2.7-fold when compared to the

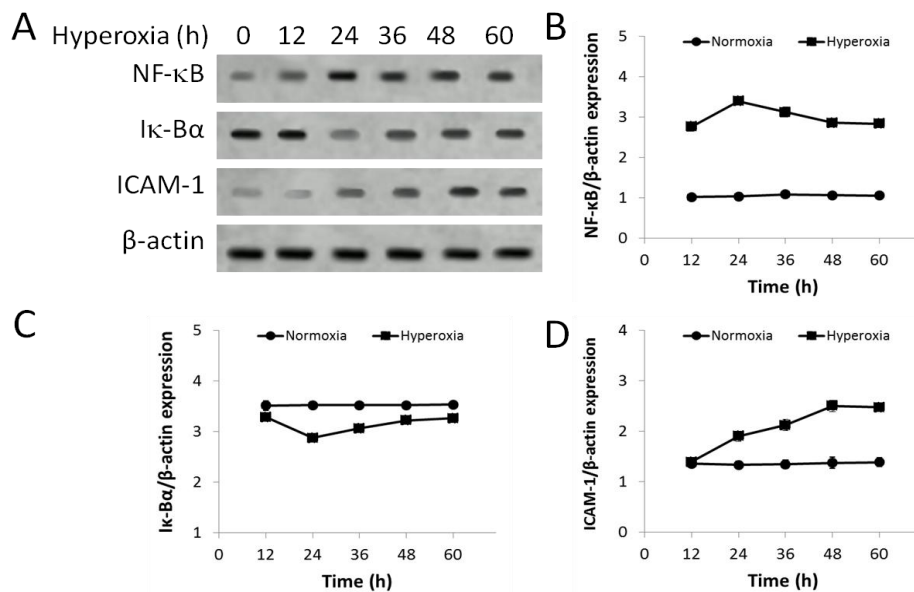


Figure 4. The protein expression levels of NF- κ B p65, I κ -B α , and ICAM-1 in lung tissues of rats exposed to hyperoxia for 12-60 hr. (A) Lung homogenates were assayed by Western blot for NF- κ B p65, I κ -B α , and ICAM-1 protein expression. (B-D) The density of protein bands was quantitated and normalized to that of the corresponding loading control β -actin. All error bars were the standard deviations (SD) of the means

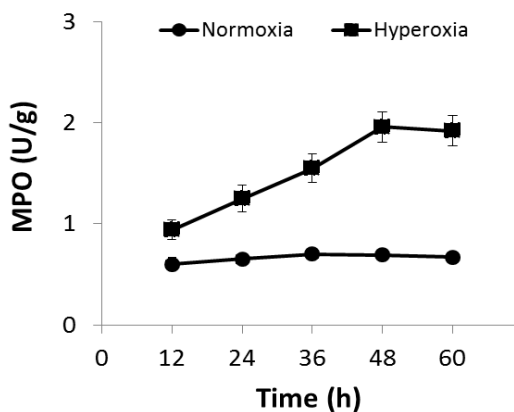


Figure 5. MPO activity in the lung homogenates of rats exposed to hyperoxia for 12-60 hr. All error bars were the standard deviations (SD) of the means

normoxia group and the I κ -B α protein expression levels were remarkably reduced at the time point after hyperoxia exposure. Sequential I κ -B α phosphorylation and NF- κ B nuclear translocation result in the expression of various inflammatory mediators, which are important players in the hyperoxia-mediated lung inflammation. Furthermore, some inflammatory mediators, i.e., TNF- α and IL-1 β , could in turn enhance NF- κ B signaling via a positive feedback loop.

As ROS and free radicals, TNF- α and IL-1 β can not only produce direct destructive effects on alveolar epithelial and vascular endothelial cells,

they can also cause indirect cytotoxicity through the induction of other harmful inflammatory mediators, which work together leading to cell damage and pulmonary edema (13, 14). KC is thought of so far the most effective chemoattractant for PMN. Our data indicate the role of TNF- α and IL-1 β levels peaked at 36 hr and elevated KC peaked at 48 hr following hyperoxia suggesting that they may play a differential role at the different stages of HALI formation (15-17). The delayed increase in the KC was correlated with the increase in ICAM-1 expression and MPO activity.

ICAM-1 is important PMN aggregation and endothelial cell adhesion and migration (18). The present study showed that hyperoxia-induced ICAM-1 expression was significantly elevated 24hr later, in good correlation with upregulated NF- κ B expression at 12-24 hr after hyperoxia. Also, pulmonary neutrophil accumulation was correlated with BALF ICAM-1 protein expression, both reaching the maximum levels at about 48 hr, suggesting that ICAM-1 might promote neutrophil migration in lungin the occurrence and development of HALI. Accumulated neutrophils in lung could release lysosomal enzymes and other proteolytic enzymes including MPO that hurt lung tissue cells and cause respiratory burst. Moreover, neutrophils could generate large amounts of superoxide anion and hydrogen peroxide, resulting in pulmonary tissue injury (19). It has been reported that neutrophil

infiltration is one of the main pathological changes in lung inflammation such as HALI.

Taken together, hyperoxia exposure induces a series of cellular and molecular events including oxidative stress and inflammation that damage rat lung tissues. In addition to its direct toxicity, excessively generated ROS can activate NF- κ B and enhance transcription of downstream inflammatory mediators, and further promote PMN aggregation and respiratory burst, which worsen lung injury. During the complex inflammatory reaction chains, NF- κ B pathway activation plays a central role in the pathogenesis of HALI.

Acknowledgment

We appreciate all the helps and suggestions from other members of the laboratory.

References

- Dang H, Yang L, Wang S, Fang F, Xu F. Calcitonin gene-related peptide ameliorates hyperoxia-induced lung injury in neonatal rats. *Tohoku J Exp Med* 2012; 227:129-138.
- Fok TF, Gu GJ, To KF, Xu F, Ng PC, Yin J. Oxygen consumption by lungs with acute and chronic injury in a rabbit model. *Intensive Care Med* 2001; 27:1532-1538.
- Saugstad OD. Mechanisms of tissue injury by oxygen radicals: implications for neonatal disease. *Acta Paediatr* 1996; 85:1-4.
- Tao W, Shu YS, Miao QB, Zhu YB. Attenuation of hyperoxia-induced lung injury in rats by adrenomedullin. *Inflammation* 2012; 35:150-157.
- Xu F, Fok TF, Yin J. Hyperoxia-induced lung injury in premature rat: description of a suitable model for the study of lung diseases in newborns. *Chin Med J* 1998; 111:619-624.
- Chen ZT, Li SL, Cai EQ, Wu WL, Jin JS, Zhu B. LPS induces pulmonary intravascular macrophages producing inflammatory mediators via activating NF- κ B. *J Cell Biochem* 2003; 89:1206-1214.
- Jungraithmayr W, Jang JH, Schrepfer S, Inci I, Weder W. Small animal models of experimental obliterative bronchiolitis. *Am J Respir Cell Mol Biol* 2013; 48:675-684.
- Porzionato A, Zaramella P, Macchi V, Sarasin G, Di Giulio C, Rigon A, et al. Cyclosporine and hyperoxia-induced lung damage in neonatal rats. *Respir Physiol Neurobiol* 2013; 187:41-46.
- Samareh Fekri M, Poursalehi HR, Najafipour H, Dabiri S, Shokoohi M, Siahposht Khacheki A, et al. Pulmonary complications of gastric fluid and bile salts aspiration, an experimental study in rat. *Iran J Basic Med Sci* 2013; 16:790-796.
- Pryor WA, Godber SS. Noninvasive measures of oxidative stress status in humans. *Free Radic Biol Med* 1991; 10:177-184.
- Cochrane CG. Cellular injury by oxidants. *Am J Med* 1991; 91:23S-30S.
- Haddad JJ. Science review: redox and oxygen-sensitive transcription factors in the regulation of oxidant-mediated lung injury: role for hypoxia-inducible factor-1 α . *Critic Care* 2003; 7:47-54.
- Chollet-Martin S, Jourdain B, Gibert C, Elbim C, Chastre J, Gougerot-Pocidallo MA. Interactions between neutrophils and cytokines in blood and alveolar spaces during ARDS. *Am J Respir Critic Care Med* 1996; 154:594-601.
- Pittet JF, Mackersie RC, Martin TR, Matthay MA. Biological markers of acute lung injury: prognostic and pathogenetic significance. *Am J Respir Critic Care Med* 1997; 155:1187-1205.
- D'Angio CT, LoMonaco MB, Chaudhry SA, Paxhia A, Ryan RM. Discordant pulmonary proinflammatory cytokine expression during acute hyperoxia in the newborn rabbit. *Exp lung Res* 1999; 25:443-465.
- Desmarquest P, Chadelat K, Corroyer S, Cazals V, Clement A. Effect of hyperoxia on human macrophage cytokine response. *Respir Med* 1998; 92:951-960.
- Horinouchi H, Wang CC, Shepherd KE, Jones R. TNF alpha gene and protein expression in alveolar macrophages in acute and chronic hyperoxia-induced lung injury. *Am J Respir Cell Mol Biol* 1996; 14:548-555.
- Nathens AB, Bitar R, Watson RW, Issekutz TB, Marshall JC, Dackiw AP, et al. Thiol-mediated regulation of ICAM-1 expression in endotoxin-induced acute lung injury. *J Immunol* 1998; 160:2959-2966.
- Boxer LA, Axtell R, Suchard S. The role of the neutrophil in inflammatory diseases of the lung. *Blood Cells* 1990; 16:25-40.