

Effects of *Ginkgo biloba* extract on the structure of Cornu Ammonis in aged rat: A morphometric study

Mohammad Hosseini-sharifabad¹, Morteza Anvari¹

¹ Department of Biology and Anatomical Sciences, Shahid Sadoughi University of Medical Sciences, Yazd, Iran

ARTICLE INFO

Article type:

Short communication

Article history:

Received: Sep 15, 2014

Accepted: Aug 25, 2015

Keywords:

Aging

Dendrite

Ginkgo biloba

Hippocampus

Volume

ABSTRACT

Objective(s): Growing evidence indicates that extract of *Ginkgo biloba* (EGb) attenuates hippocampal-dependent memory deficit in aged individuals; however, very little is known about the effect of EGb on the structure of hippocampus. Therefore we examined the EGb-induced morphological changes of the Cornu Ammonis (CA) region in aged rats.

Materials and Methods: Sixteen aged male Wistar rats, 24 months old, were randomly divided into experimental and control groups. Experimental group was orally administered EGb (100 mg/kg/d for 8 weeks), and the control group received a similar volume of water. The volume estimation of CA hippocampal field was done by Cavalieri principle and a quantitative Golgi study was also used for analysis of dendritic arborizations of CA3 and CA1 pyramidal cells.

Results: Results revealed that EGb-treated aged rats had greater volumes than control animals in the layers of pyramidal and radiatum lacunosum moleculare in both CA3 and CA1 subfields. The neurons of CA3 and CA1 in experimental rats had more dendritic segments and larger total dendritic length compared to the control. The results also showed that the aged rats treated by EGb had more numerical branching density in the apical dendrites of CA3 and CA1 pyramidal cells.

Conclusion: The results of the present study show that long-term administration of EGb could produce morphometrical changes in hippocampal pyramidal cells in aged rats. Results also provide a neuroanatomical basis for memory improvement due to chronic treatment with EGb.

► Please cite this article as:

Hosseini-sharifabad M, Anvari M. Effects of *Ginkgo biloba* extract on the structure of Cornu Ammonis in aged rat: A morphometric study. Iran J Basic Med Sci 2015; 18:932-937.

Introduction

The hippocampal formation, a well-defined region of brain involved in the spatial learning performance, is especially vulnerable to the process of aging and shows early signs of age-related changes in the function and structure (1, 2). Previous studies indicated a decrease in the volume of the hippocampus during normal aging (3, 4). Other investigations showed that the dendritic atrophy occurs in the hippocampus during normal aging (5, 6). Furthermore, the reductions in the cerebral blood flow (7) and in the cerebral levels of many blood-borne trophic factors (8, 9) are also reported in the aged in comparison with young animals. Such changes in the hippocampus are suggested to represent a neurobiological substrate of hippocampal-dependent memory deficits (10, 11).

Nowadays, a major focus in research on aging is concentrated on finding drugs to improve declining memory. The extract of *Ginkgo biloba* (EGb) leaves is one of the most common phytomedicines in many countries and preparations from the leaf of *G. biloba* have been therapeutically used to treat decreased cerebral blood flow, memory loss and mental confusion

(12–15). The EGb could also improve performance in cognitive tasks in old animals (16–18).

The standardized EGb, code-named "EGb 761", contains 24% flavonoids (quercetin, kaempferol and isorhamnetin) and 6% terpenoids (ginkgolides A, B and C and bilobalides) proanthocyanidins, and organic acids (19, 20). EGb has a relatively low molecular weight also, and it passes through the blood-brain barrier and induces a wide range of pharmacological actions on the central nervous system (21). The beneficial effects of EGb 761 were supported by a variety of *in vitro* and *in vivo* studies (22). It improves the local cerebral blood flow by its anti-platelet activating factor (PAF) activity (23), neutralizes oxidative free radicals through antioxidative properties (24, 25), acts as anti-stress agent by inhibiting corticosteroid synthesis (26), and stimulates cell growth by growth factor upregulation (27).

In spite of numerous studies that indicated the positive effects of EGb on neurobiological substrate of memory improvement, very little is known about the effect of EGb on the structure of hippocampus. It is well known that the hippocampal dendritic systems play a critical role in spatial learning and memory.

*Corresponding author: Mohammad Hosseini-sharifabad. Department of Biology and Anatomical Sciences, Research Center of Herbal Medicine, Shahid Sadoughi University of Medical Sciences, Yazd, Iran. Tel: +98-353-6240691-5; Fax: +98-353-6238561; email: m_hosseini@ssu.ac.ir

On the basis of this background, the experiments reported here were designed to determine whether long-term administration of EGb has a positive impact on the structures of hippocampus in aged rats. In this study, Cavalieri principle (28), was employed to estimate the volumes of constituents' layers of Cornu Ammonis (CA) and a quantitative Golgi study was used to analysis of dendritic branches of hippocampal pyramidal cells.

Materials and Methods

Animals and treatment

Male albino Wistar rats aged 24 months weighing 570–600 g, acquired from the animal house of Isfahan Medical School, Isfahan, Iran, were maintained in standard laboratory conditions with food and water *ad libitum* under a 12:12 light-dark cycle (lights on at 7:00 Am). The animals were randomly divided into experimental and control groups (n=8 in each group). The animals in experimental group orally received EGb leaves (Ginkgol, Goldaru phytolaboratory, Isfahan, Iran) in the single dose of 100 mg/kg per day for 8 weeks (21, 26). The control group, was administered a similar volume of water. Solution of EGb in water was prepared fresh daily and administered orally in a volume of 2 ml/kg body weight. All animal experiments and housing was performed in accordance with rules approved by the Ethical Committee of Shahid Sadoughi Medical University of Iran.

Histological procedure

At the end of the experimental period, all rats were deeply anesthetized intraperitoneally with urethan (Merk, Germany). They were transcardially perfused with a phosphate-buffered solution of 4% formaldehyde and 1% glutaraldehyde and decapitated. The brains were removed and divided in the midsagittal direction. Right hemispheres were selected for stereological and morphometric analyses of hippocampus. Brains were coded so that the investigators were not aware of the groups. Each hemisphere was serially sectioned in a coronal plane at 100 μ m with a calibrated vibratome (Diapath, Italy) and the sections were collected along the entire extent of the hippocampus.

Volume estimation

Starting at a random position, every 5th section with an interval of 500 μ m was taken. The sections were mounted on object glasses and dried at room temperature. The dry sections were stained using hematoxylin: dipped in distilled water, 4 min in hematoxylin, and washed in running tap water for 10 min. After rinsing they were dehydrated in 70% (10 min), 96% (2 \times 5 min) and 99% ethanol (2 \times 8 min), cleared 15 min in xylene; and coverglasses were mounted.

Discrimination between the different subdivisions of the hippocampal formation was made according to

cell morphology (Figure 1). The volumes of the constituent layers of CA i.e. oriens, pyramidal and radiatum lacunosum moleculare, were estimated on the basis of the Cavalieri principle (28). The cross sectional areas of the layers were estimated by point-counting principle with a projection microscope (Zeiss, Germany) using a 4x objective lens at a final magnification of 64 \times . A grid of systematic uniform test points, 30 mm apart, was randomly superimposed on each image. Each point represented an area, $a(p) = 0.22 \text{ mm}^2$, in the section plane. The number of points hitting the layers, ΣP , was multiplied with the area associated with each point, $a(p)$, to obtain an unbiased estimate of sectional area of each profile. The reference volume, $V(\text{ref})$, was calculated from the following relationship, where t represents the intersection distance; $V(\text{ref}) = t \cdot \Sigma P \cdot a(p) = t \cdot \Sigma A$

No areal shrinkage correction was used in the study because of the insignificant magnitude of the shrinkage and because no difference in shrinkage was found between groups (mean areal shrinkage of 5% was detected).

Morphometric analysis

Sections were processed according to a modified version of the single-section Golgi impregnation procedure (29). Hippocampal sections were incubated in 3% potassium dichromate in distilled water overnight. After rinsing in distilled water, the sections were mounted on plain slides and a coverslip was glued over the sections at four corners. They were incubated in 1.5% silver nitrate in distilled water overnight in darkness. On the following day, the slide assemblies were dismantled, tissue sections rinsed in distilled water and then dehydrated first in 95% ethanol followed by absolute ethanol. The sections were then cleared in xylene, mounted onto gelatinized slides and coverslipped.

From the hippocampal pyramidal cell layer, 10 pyramids of the CA3 and CA1 regions were selected and

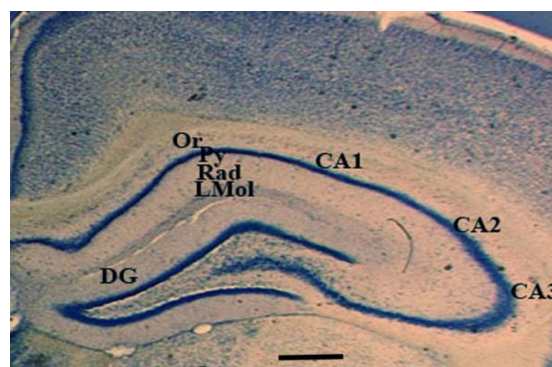


Figure 1. Low magnification micrograph of a hematoxylin stained section through the hippocampus of rat shows its different subregions and the layers of Cornu Ammonis. DG; Dentate gyrus CA; Cornu Ammonis, Or; Oriens, Py; Pyramidal, Rad; Radiatum LMol; Lacunosum+Molecular. Scale bar indicates 400 μ m

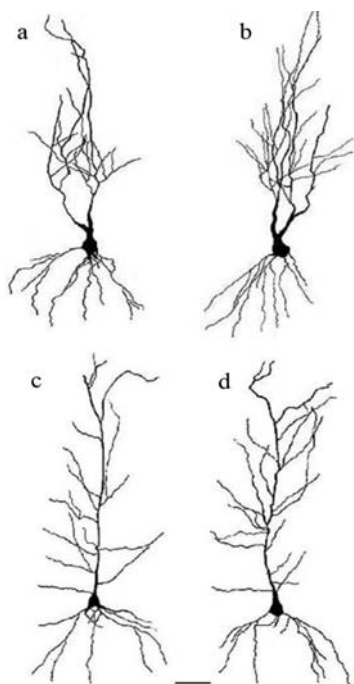


Figure 2. Camera lucida drawing of Golgi-impregnated CA3 (a, b) and CA1 pyramidal cells (c,d). Neurons from control rats are shown in the left column (a,c), from extract of *Ginkgo biloba* (EGb)-treated rats in the right column (b, d). Note an increase in the dendritic arborizations in EGb-treated aged rats compared with controls. Scale bar=50 μm (applies to all frames)

pooled per animal in a single group. The morphological criteria used for selecting the neurons to be measured were as follows (30): (i) dark and consistent impregnation throughout the extent of dendrites; (ii) cell bodies located in the middle part of the section thickness in order to minimize branch segments cut off at the plan of the section; and (iii) relative isolation from other neighboring impregnated cells, blood vessels and silver deposits. Because these criteria were fulfilled solely by apical dendrites, the basal dendritic trees of pyramidal cells were not included in the estimations. The presence of cut terminal segments on a neuron was not considered as a criterion for its exclusion from the estimations because the elimination of these neurons would have biased the sample towards smaller neurons. Since, we found that in the Golgi sections of experimental and control rats there was a similar percentage of cut branches (10%), the likelihood that these cut branches could have interfered with the final results is negligible. We observed on average 8% shrinkage of the sections in each group and these values were employed as a correction factor for the length measurements.

The apical dendritic trees of CA3 and CA1 pyramidal cells were traced by hand with the aid of a camera lucida (Leitz Orthoplan, Wetzlar, Germany), at a final magnification of ×640. The centrifugal ordering of dendritic trees was used to estimate the number of dendritic segments per cell (31). The total number of

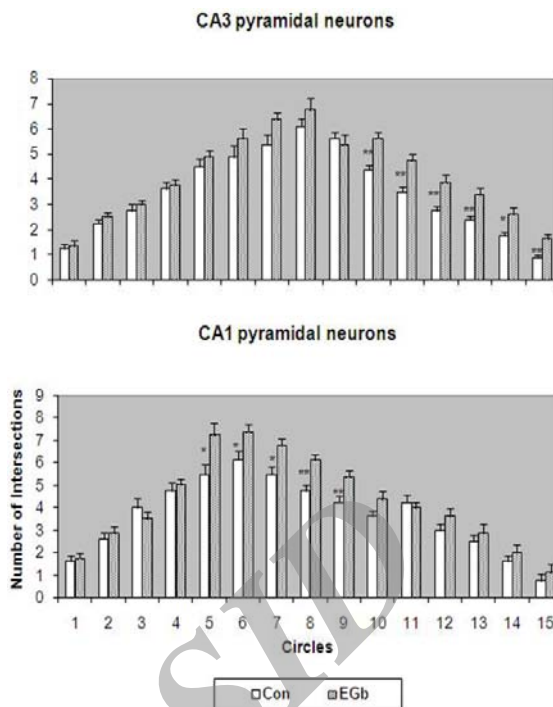


Figure 3. Graphic representation of the dendritic branching density of CA3 and CA1 hippocampal neurons of extract of *Ginkgo biloba* (EGb)-administrated aged rats and control (Con). Vertical bars represent SEM. * $P<0.05$, ** $P<0.01$

segments per cell was calculated by summing the number of dendritic segments of all orders. For metric analysis, the dendritic length was measured using a Zeiss interactive digitizing analysis system (Zeiss, Germany). The branching density of dendritic trees was evaluated by applying the concentric circle method. A grid of concentric was placed over the camera lucida drawing of the dendritic field and the number of dendritic intersections crossing each concentric ring was counted. The concentric rings were calculated at intervals of 25 μm for both CA3 and CA1 pyramidal cells. Whenever the dendrites extended beyond 375 μm (circle 15), they were included in circle 15.

Statistical analysis

Student’s t-test was performed on data from the experimental and control rats. Differences were considered to be significant for $P<0.05$.

Results

The results showing the effect of EGb on the volumes of the layers of the CA are represented in the Table 1. Statistical analysis revealed significant effect of EGb on the volume of the layers of CA except in the oriens layer. Comparisons revealed that EGb-treated aged rats had greater volumes than controls in the layers of pyramidal and radiatum lacunosum moleculare in CA3 and CA1 pyramidal fields (Table 1). This study also showed that the volume of

Table 1. Volumes of the layers (mm³) of the Cornu Ammonis (CA) in the extract of *Ginkgo biloba* (EGb)-treated rats and respective controls. All values expressed as mean (SD)

Hippocampal field	Control (n=8)	EGb-treated (n=8)	P
CA3			
Oriens layer	3.2 (0.25)	3.04 (0.29)	0.23
Pyramidal layer	2.25 (0.20)	2.5 (0.21)	0.03
Radiatum + lacunosum moleculare layer	5.78 (0.46)	6.28 (0.38)	0.03
CA1			
Oriens layer	3.36 (0.37)	3.04 (0.49)	0.16
Pyramidal layer	1.93 (0.19)	2.26 (0.24)	0.007
Radiatum + lacunosum moleculare layer	6.34 (0.87)	7.48 (0.58)	0.009
Whole Hippocampus	33.01 (2.66)	36.28 (2.81)	0.03

the whole hippocampal formation was significantly larger in EGb-treated aged rats than their controls (Table 1).

A significant increase of the dendritic branches of CA3 and CA1 pyramidal cells was present in sections from the EGb-treated aged rats as compared to the controls (Figure 2). Student's t-test revealed significant effect of treatment on the total number of segments per cell in both CA3 and CA1 pyramidal cells (Table 2). The dendritic segment number of CA3 and CA1 pyramidal cells was respectively 15.6% and 15.2% higher in the experimental group than in controls. Results also showed that, in these neurons, the total dendritic length was larger in the EGb-treated compared to control animals.

Statistical analyses revealed significant effect of treatment on the dendritic branching density of CA3 pyramidal cells in circles 10–15 (Figure 3); in addition, it indicated a significant difference in the dendritic branching density of CA1 pyramidal cells in circles 5–9 (Figure 3). In both cases, the dendritic intersections were greater in EGb-treated than in the control aged rats.

Discussion

The present study was designed to determine whether chronic administration of EGb affects the structure of CA and the morphology of hippocampal pyramidal cells in aged rats. Our study showed that, 8 week treatment with EGb increases the volumes of the layers of pyramidal and radiatum lacunosum moleculare in CA3 and CA1 pyramidal fields and the whole hippocampus in aged rats.

Quantitative morphological analysis also indicated that there were increases in both the number and the length of dendritic segments associated with an increase in the dendritic branching density of CA3 and

CA1 pyramidal cells in EGb-treated aged rats.

Although in this study we did not investigate the mechanisms underlying the beneficial effects of EGb on the morphology of CA structure of aged rats, several lines of evidence could help to explain the neuroprotective effects of EGb. Previous studies showed that chronic administration of EGb 761 inhibits stress-induced corticosterone hypersecretion (26). It is reported that hippocampal neurons contain high levels of corticosteroid receptors (32) and it also demonstrated that glucocorticoids are regulators of neurotrophins in the hippocampus (33). Therefore, it could be proposed that a decrease in exposure to glucocorticoid concentrations following a chronic treatment with EGb has a neuroprotective effect and lowers neurotoxicity and neuronal degeneration particularly in the CA3 subfield (34).

In addition, early studies revealed that treatment with EGb 761 increased the local cerebral blood flow in nearly all brain regions (35), and it may lead to elevated levels of many blood-borne trophic factors in these regions. It is reported that growth hormone (GH) stimulates most target cells to grow in size, and GH receptors are present in the brain (36). Thus, it is reasonable to speculate that the observed increase in both the hippocampal size and the extent of dendritic arbors might be the result of availability of neurotrophic factors such as GH.

Positive effects of EGb on the structure of hippocampal neurons may be related to its antioxidant properties (24, 25), antiapoptotic effect (37, 38) and inhibition of beta amyloid production and aggregation (39, 40). Protective effects of EGb have been shown after experimentally ischemia (41, 42), for nitric oxide-induced toxicity (43) and β -amyloid-induced cell death in hippocampal cells (44).

In the present study, we used the total EGb because

Table 2. Comparison of dendritic trees (mean \pm SD) of extract of *Ginkgo biloba* (EGb)-treated and control rats

	Control (n=8)	EGb-treated (n=8)	P
CA3 pyramidal cells			
Total no. segment	28.9 \pm 3.2	33.4 \pm 2.9	0.011
Total dendritic length(μ m)	1745 \pm 167	2040 \pm 162	0.003
CA1 pyramidal cells			
Total no. segment	38.1 \pm 2.2	43.9 \pm 4.8	0.008
Total dendritic length(μ m)	2074 \pm 160	2315 \pm 201	0.019

various chemical constituents of EGb, although active in pharmacological models, do not generally reproduce the actions of the total extract (21).

While neuroprotective effects of EGb and its components have been well documented only a few studies have examined the effect of EGb on the structure of central nervous system. Barkats *et al* (45) examined the effects of EGb 761 on age-related changes in the projection fields of hippocampal mossy fibers in old female mice. They reported that treatment with EGb 761 (50 mg/kg/day) for 7 months led to a significant increase in the projection field of intra- and infrapyramidal mossy fibers in the CA3 field and to a significant decrease in the area of the stratum radiatum.

Our findings on old male Wistar rats is in agreement with the result of Barkat's study (45), where they found significant increase in the number of CA3 dendritic arbors following long-term treatment with EGb. However, they found a significant reduction in the area of the stratum radiatum, which is in conflict with our results showing a significant increase in the volume of radiatum layer in the CA3 region of EGb-treated aged rats. This discrepancy could be related to several possible factors particularly the methodology employed to estimate the size of the CA3 layer. Although the size of a layer may be estimated in a number of ways, volume measurement, which was used in our study, provides a 3-dimensional analysis of structures based on observations made on two-dimensional sections. Other parameters including transsectional area depend not only upon size, but also on assumptions about the structure of the shape and orientation (28).

Conclusion

Our results showed that long-term administration of EGb in the aged Wistar rats had neuroprotective effects and enhanced dendritic arbors in CA pyramidal cells of hippocampus. The precise mechanisms responsible for this efficacy of *G. biloba* remain to be clarified. Findings of our study provide a neuroanatomical basis that is useful in explaining improvements in hippocampal-dependent cognitive tasks in both humans and experimental animals treated with EGb. The findings of the present study also support therapeutic potential of EGb in age-associated neurodegenerative diseases.

Acknowledgment

This study was funded by research deputy of Shahid Sadoughi University of Medical Sciences, (Research project No.1520). The authors gratefully acknowledge, research center of herbal medicine, Shahid Sadoughi University of Medical Sciences, Yazd, Iran, for providing working facilities.

References

- Shankar SK. Biology of aging brain. *Indian J Pathol Microbiol* 2010; 53:595-604.
- Driscoll I, Sutherland RJ. The aging hippocampus: navigating between rat and human experiments. *Rev Neurosci* 2005; 16:87-121.
- Bartzokis G, Beckson M, Lu PH, Nuechterlein KH, Edwards N, Mintz J. Age-related changes in frontal and temporal lobe volumes in men: a magnetic resonance imaging study. *Arch Gen Psychiatry* 2001; 5:461-465.
- Chételat G, Fouquet M, Kalpouzos G, Degenhien I, De la Sayette V, Viader F, *et al*. Three-dimensional surface mapping of hippocampal atrophy progression from MCI to AD and over normal aging as assessed using voxel-based morphometry. *Neuropsychologia* 2008; 46:1721-1731.
- Von Bohlen und Halbach O, Zacher C, Gass P, Unsicker K. Age-related alterations in hippocampal spines and deficiencies in spatial memory in mice. *J Neurosci Res* 2006; 83:525-531.
- Markham JA, McKian KP, Stroup TS, Juraska JM. Sexually dimorphic aging of dendritic morphology in CA1 of hippocampus. *Hippocampus* 2005; 15:97-103.
- Small SA, Chawla MK, Buonocore M, Rapp PR, Barnes CA. Imaging correlates of brain function in monkeys and rats isolates a hippocampal subregion differentially vulnerable to aging. *Proc Natl Acad Sci USA* 2004; 101:7181-7186.
- Schulte-Herbrüggen O, Eckart S, Deicke U, Kühl A, Otten U, Danker-Hopfe H, *et al*. Age-dependent time course of cerebral brain-derived neurotrophic factor, nerve growth factor, and neurotrophin-3 in APP23 transgenic mice. *J Neurosci Res* 2008; 86:2774-2783.
- Sonntag WE, Lynch C, Thornton P, Khan A, Bennett S, Ingram R. The effects of growth hormone and IGF-1 deficiency on cerebrovascular and brain ageing. *J Anat* 2000; 197:4:575-585.
- Crepel V, Epsztein J, Ben-Ari Y. Ischemia induces short- and long-term remodeling of synaptic activity in the hippocampus. *J Cell Mol Med* 2003; 7:401-407.
- Silhol M, Bonnichon V, Rage F, Tapia-Arancibia L. Age-related changes in brain-derived neurotrophic factor and tyrosine kinase receptor isoforms in the hippocampus and hypothalamus in male rats. *Neuroscience* 2005; 132:613-624.
- Jiang L, Su L, Cui H, Ren J, Li C. *Ginkgo biloba* extract for dementia: a systematic review. *Shanghai Arch Psychiatry* 2013; 25:10-21.
- Hoerr R, Grass-Kapanke B, Tribanek M, Kaschel R. Effects of *Ginkgo biloba* extract EGb 761(R) on cognition and quality of life in subjects with very mild cognitive impairment. *Int J Psychol* 2008; 43:404.
- Ihl R, Tribanek M, Napryeyenko O. A 240-mg once-daily formulation of *Ginkgo biloba* extract EGb 761(R) is effective in both Alzheimer's Disease and Vascular Dementia: Results from a randomized controlled trial. *Alzheimers Dement* 2008; 4:T165-T166.
- Elsabagh S, Hartley DE, Ali O, Williamson EM, File SE. Differential cognitive effects of *Ginkgo biloba* after acute and chronic treatment in healthy young volunteers. *Psychopharmacology* 2005; 179:437-446.
- Blecharz-Klin K, Piechal A, Joniec I, Pyrzanowska J, Widy-Tyszkiewicz E. Pharmacological and biochemical effects of *Ginkgo biloba* extract on learning, memory

- consolidation and motor activity in old rats. *Acta Neurobiol Exp (Wars)* 2009; 69:217-231.
17. Gong QH, Wu Q, Huang XN, Sun AS, Nie J, Shi JS. Protective effect of *Ginkgo biloba* leaf extract on learning and memory deficit induced by aluminum in model rats (in Chinese). *Chin J Integr Med* 2006; 12:37-41.
 18. Augustin S, Rimbach G, Augustin K, Schliebs R, Wolfram S, Cermak R. Effect of a short- and long-term treatment with *Ginkgo biloba* extract on amyloid precursor protein levels in a transgenic mouse model relevant to Alzheimer's disease. *Arch Biochem Biophys* 2009; 481:177-182.
 19. Mahadevan S, Park Y. Multifaceted therapeutic benefits of *Ginkgo biloba* L.: chemistry, efficacy, safety, and uses. *J Food Sci* 2008; 73;R14-19.
 20. Xie J, Ding C, Ge Q, Zhou Z, Zhi X. Simultaneous determination of ginkgolides A, B, C and bilobalide in plasma by LC-MS/MS and its application to the pharmacokinetic study of *Ginkgo biloba* extract in rats. *J Chromatogr B Analyt Technol Biomed Life Sci* 2008; 864:87-94.
 21. DeFeudis FV, Drieu K. *Ginkgo biloba* extract (EGb 761) and CNS functions: basic studies and clinical applications. *Curr Drug Targets* 2000; 1:25-58.
 22. Ahlemeyer B, Kriegelstein J. Neuroprotective effects of the *Ginkgo biloba* extract. *Cell Mol Life Sci* 2003; 60:1779-1792.
 23. Smith PF, MacLennan K, Darlington CL. The neuroprotective properties of the *Ginkgo biloba* leaf: a review of the possible relationship to platelet-activating factor (PAF). *J Ethnopharmacol* 1996; 50:131-139.
 24. Kampkötter A, Pielarski T, Rohrig R, Timpel C, Chovolou Y, Wätjen W, et al. The *Ginkgo biloba* extract EGb761 reduces stress sensitivity, ROS accumulation and expression of catalase and glutathione S-transferase 4 in *Caenorhabditis elegans*. *Pharmacol Res* 2007; 55:139-147.
 25. Smith JV, Luo Y. Studies on molecular mechanisms of *Ginkgo biloba* extract. *Appl Microbiol Biotechnol* 2004; 64:465-472.
 26. Marcilhac A, Dakine N, Bourhim N, Guillaume V, Grino M, Drieu K, et al. Effect of chronic administration of *Ginkgo biloba* extract or Ginkgolide on the hypothalamic-pituitary-adrenal axis in the rat. *Life Sci* 1998; 62:2329-2340.
 27. Zheng SX, Zhou LJ, Chen ZL, Yin ML, Zhu XZ. Bilobalide promotes expression of glial cell line-derived growth neurotrophic factor and vascular endothelial growth factor in rat astrocytes. *Acta Pharmacol Sin* 2000; 21:151-155.
 28. Gundersen HJG, Bendtsen TF, Korbo L, Marcussen N, Moller A, Nielsen K, et al. Some new, simple and efficient stereological methods and their use in pathological research and diagnosis. *APMIS* 1988; 96:379-394.
 29. Gabbott PL, Somogyi J. The 'single' section Golgi impregnation procedure: Methodological description. *J Neurosci Methods* 1994; 11:221-230.
 30. De Ruiter JP, Uylings HBM. Morphometric and dendritic analysis of fascia dentata granule cells in human aging and senile dementia. *Brain Res* 1987; 402:217-229.
 31. Uylings HB, Van Pelt J. Measures for quantifying dendritic arborizations. *Network* 2002; 13:397-414.
 32. De Kloet ER, Vreugdenhil E, Oitzl MS, Joëls M. Brain corticosteroid receptor balance in health and disease. *Endocr Rev* 1998; 19:269-301.
 33. Schaaf MJ, De Kloet ER, Vreugdenhil E. Corticosterone effects on BDNF expression in the hippocampus. Implications for memory formation. *Stress* 2000; 3:201-208.
 34. Sapolsky RM. Glucocorticoids, stress and their adverse neurological effects: Relevance to aging. *Exp Gerontol* 1999; 34:721-32.
 35. Ahlemeyer B, Kriegelstein J. Pharmacological studies supporting the therapeutic use of *Ginkgo biloba* extract for Alzheimer's disease. *Pharmacopsychiatry* 2003; 36:S8-14.
 36. Fonte V, Kipp DR, Yerg J, Merin D, Forrestal M, Wagner E, et al. Suppression of in vivo beta-amyloid peptide toxicity by overexpression of the HSP-16.2 small chaperone protein. *J Biol Chem* 2008; 283:784-791.
 37. Altiok N, Ersoz M, Karpuz V, Koyuturk M. *Ginkgo biloba* extract regulates differentially the cell death induced by hydrogen peroxide and simvastatin. *Neurotoxicology* 2006; 27:158-163.
 38. Lu G, Wu Y, Mak YT, Wai SM, Feng ZT, Rudd JA, et al. Molecular evidence of the neuroprotective effect of *Ginkgo biloba* (EGb761) using bax/bcl-2 ratio after brain ischemia in senescence-accelerated mice, strain prone-8. *Brain Res* 2006; 1090:23-28.
 39. Bate C, Tayebi M, Williams A. Ginkgolides protect against amyloid- β 1-42-mediated synapse damage in vitro. *Mol Neurodegen* 2008; 3:1-9.
 40. Colciaghi F, Borroni B, Zimmermann M, Bellone C, Longhi A, Padovani A, et al. Amyloid precursor protein metabolism is regulated toward alpha-secretase pathway by *Ginkgo biloba* extracts. *Neurobiol Dis* 2004; 16:454-460.
 41. Domorakova I, Burda J, Mechirova E, Ferikova M. Mapping of rat hippocampal neurons with NeuN after ischemia/reperfusion and *Ginkgo biloba* extract (EGb 761) pretreatment. *Cell Mol Neurobiol* 2006; 26:1193-1204.
 42. Chandrasekaran K, Mehrabian Z, Spinnewyn B, Chinopoulos C, Drieu K, Fiskum G. Bilobalide, a component of the *Ginkgo biloba* extract (EGb 761), protects against neuronal death in global brain ischemia and in glutamate-induced excitotoxicity. *Cell Mol Biol (Noisy-le-grand)* 2002; 48:663-669.
 43. Bastianetto S, Zheng WH, Quirion R. The *Ginkgo biloba* extract (EGb 761) protects and rescues hippocampal cells against nitric-oxide induced toxicity: involvement of its flavonoid constituents and Protein Kinase C. *J Neurochem* 2000; 74:2268-2277.
 44. Ramassamy C, Longpré F, Christen Y. *Ginkgo biloba* extract (EGb 761) in Alzheimer's disease: is there any evidence? *Curr Alzheimer Res* 2007; 4:253-262.
 45. Barkats M, Venault P, Christen Y, Cohen-Salmon C. Effect of long-term treatment with EGb 761 on age-dependent structural changes in the hippocampi of three inbred mouse strains. *Life Sci* 1995; 56:213-222.