

## Effect of bone marrow derived mesenchymal stem cells on lung pathology and inflammation in ovalbumin-induced asthma in mouse

Maryam Mohammadian <sup>1</sup>, Mohammad Hosein Boskabady <sup>2</sup>, Iraj Ragerdi Kashani <sup>3</sup>, Gila Pirzad Jahromi <sup>4</sup>, Amene Omidi <sup>3</sup>, Amir Kavian Nejad <sup>5</sup>, Safoura Khamse <sup>1</sup>, Hamid Reza Sadeghipour <sup>1\*</sup>

<sup>1</sup> Department of Physiology, School of Medicine, Tehran University of Medical Sciences, Tehran, Iran

<sup>2</sup> Neurogenic Inflammation Research Center and Department of Physiology, School of Medicine, Mashhad University of Medical Sciences, Mashhad, Iran

<sup>3</sup> Department of Anatomy, School of Medicine, Tehran University of Medical Sciences, Tehran, Iran

<sup>4</sup> Neuroscience Research Center, Baqiyatallah University of Medical Sciences, Tehran, Iran

<sup>5</sup> Department of Emergency Medical Services, School of Nursing and Midwifery, Shahid Beheshti University of Medical Sciences, Tehran, Iran

ARTICLE INFO	ABSTRACT
<p><b>Article type:</b> Original article</p> <p><b>Article history:</b> Received: May 21, 2015 Accepted: Jul 23, 2015</p> <p><b>Keywords:</b> Inflammation Lung pathology Ovalbumin- induced asthma Stem cells</p>	<p><b>Objective(s):</b> Bone marrow-derived mesenchymal stem cells (BMSCs) have attracted significant interest to treat asthma and its complication. In this study, the effects of BMSCs on lung pathology and inflammation in an ovalbumin-induced asthma model in mouse were examined.</p> <p><b>Materials and Methods:</b> BALB/c mice were divided into three groups: control group (animals were not sensitized), asthma group (animals were sensitized by ovalbumin), asthma+BMSC group (animals were sensitized by ovalbumin and treated with BMSCs). BMSCs were isolated and characterized and then labeled with Bromodeoxyuridine (BrdU). After that the cells transferred into asthmatic mice. Histopathological changes of the airways, BMSCs migration and total and differential white blood cell (WBC) count in bronchoalveolar lavage (BAL) fluid were evaluated.</p> <p><b>Results:</b> A large number of BrdU-BMSCs were found in the lungs of mice treated with BMSCs. The histopathological changes, BAL total WBC counts and the percentage of neutrophils and eosinophils were increased in asthma group compared to the control group. Treatment with BMSCs significantly decreased airway pathological indices, inflammatory cell infiltration, and also goblet cell hyperplasia.</p> <p><b>Conclusion:</b> The results of this study revealed that BMSCs therapy significantly suppressed the lung pathology and inflammation in the ovalbumin induced asthma model in mouse.</p>

► Please cite this article as:

Mohammadian M, Boskabady MH, Ragerdi Kashani I, Pirzad Jahromi G, Omidi A, Kavian Nejad A, Khamse S, Sadeghipour HR. Effect of bone marrow derived mesenchymal stem cells on lung pathology and inflammation in ovalbumin-induced asthma in mouse. Iran J Basic Med Sci 2016; 19:55-63.

### Introduction

Bronchial asthma is a chronic inflammatory disorder of the airways characterized by airways inflammation, bronchospasm and increased mucus production inside the airways (1). Chronic inflammation causes tissue damage and repeated tissue damage and repair leads to structural changes of the airways, including subepithelial fibrosis, goblet cell hyperplasia, increased airway smooth muscle mass and angiogenesis, collectively known as airway remodeling (2). Airway remodeling results in thickening of airway walls and, consequently leads to narrowing of airways and obstruction of airflow (3). Currently, anti-inflammatory agents such as corticosteroids are the main therapeutic strategy for

asthma. These agents reduce inflammation and have great potential in preventing structural changes (4). However, many patients with severe persistent asthma do not respond to this type of therapy. Furthermore, it appears that these drugs are not able to reduce or reverse airway remodeling (5) and most importantly, long-term therapy with corticosteroids may leads to many side effects (6). Therefore, it is crucial to explore new therapeutic approaches that can reduce lung remodeling with fewer side effects. In recent years, cell therapy has attracted attention of researchers to treat asthma and its complications. Bone marrow-derived mesenchymal stem cells (BMSCs) are the multipotent stromal cells that can differentiate into multiple cell types including osteoblasts, chondrocytes, myocytes, and adipocytes

\*Corresponding author: Hamid Reza Sadeghipour. Department of Physiology, School of Medicine, Tehran University of Medical Sciences, Tehran, Iran. Tel/Fax: +98-2166419484; email: sadeghipour@tums.ac.ir

(7) and can regulate immune and inflammatory responses (8). These cells do not express major histocompatibility complex (MHC) class II, thus, they can escape immune surveillance and can be used without the prior immunological modifications (9). BMSCs express several cytokine and chemokine receptors causing them to migrate into the inflamed tissue (10). In addition, the activity of these cells is regulated by environmental factors like, increased levels of pro-inflammatory cytokines in the tissues lead to increased secretion of anti-inflammatory factors by BMSCs, conversely, decreased levels of pro-inflammatory cytokines in the tissues lead to decreased secretion of anti-inflammatory factors by these cells. The migration of BMSCs into the inflamed area and specific activity of these cells prevent infection and toxicity which occur during the treatment with steroids (9).

Furthermore, the beneficial effects of BMSCs in reducing remodeling have been observed in many disorders such as liver (10, 11), lung (12, 13), kidney (14) and heart (15, 16) fibrosis. Therefore, it seems that these cells have the ability to improve inflammatory diseases including asthma and ameliorate airway remodeling. Therefore, the effect of BMSCs therapy on lung pathology and inflammation in an ovalbumin-induced asthma model in mouse was examined in the present study.

## Materials and Methods

### Mice

BALB/c mice (6–8 weeks old) were obtained from Pasteur Institute of Iran, and bred in the animal laboratory of Tehran University of Medical Science. Mice were maintained in regular cages under the controlled environmental conditions ( $20 \pm 2$  °C and 12 hr light–dark cycle) and allowed free access to standard lab chow and water. Animal care and the general protocols for animal use were approved by the Animal Ethics Community of Tehran University of Medical Sciences.

### Experimental design

Fourteen male BALB/c mice were entered into this study. Four animals were not sensitized and served as the control group while others were sensitized by intraperitoneal injection of ovalbumin (OVA) (10 mg) (OVA, Sigma grade 5) and aluminum hydroxide (2 mg) on day 0 and 14. After one week, animals were exposed to aerosolized OVA (3%) in a closed chamber (dimensions 40×40×70 cm) using a compressor nebulizer (Omron CX3, Japan) for 30 min per day on three days a week for eight weeks (17). Then, animals were randomly divided into two groups:

1- Asthma group: animals were not treated (n=4).

2- Asthma+BMSC group: animals were treated with single intravenous injection of BMSCs ( $1 \times 10^6$ ) on the last week of challenge (n=6).

The sample size was chosen according several similar previous studies (18-20, 38).

### Preparation of BMSCs

The BMSCs were collected from the long bones of adult male Balb/c mice aged 6-8 weeks. Briefly, animals were killed, and the tibias and the femurs were dissected out. The proximal and distal ends were removed under aseptic conditions, and the bone marrow was aspirated with 1 ml culture medium using a 31 G needle. The cell pellet containing hematopoietic cells and bone marrow stromal cells among others was suspended in growth medium containing Dulbecco's modified Eagle's medium (DMEM; Invitrogen, Burlington, Ontario, Canada) supplemented with 15% fetal bovine serum (FBS; Invitrogen), penicillin (100 u/ml), streptomycin (100 µg/ml) and amphotericin B (25 ng/ml) (Sigma). The harvested cells were seeded on a 25 cm<sup>2</sup> flask (Nunc, Roskilde, Denmark) and maintained at 37 °C and 5% CO<sub>2</sub> in an incubator for 24 hr. The flasks were then washed with PBS to remove the hematopoietic cells. The cells were then incubated for 2–3 days, at which point the cells reached 70–80% confluence. Cultures were harvested with Trypsin–EDTA solution (0.25% Trypsin, 0.5 mM EDTA; Sigma) for 5–10 min at 37 °C to obtain a single-cell suspension. Nucleated marrow cells were counted using a cytometer to ensure adequate cell numbers for transplantation. This cycle was repeated four times (passage 1, 2, 3 and 4, respectively). At the 3rd passage, the cells were checked for BMSC purity using antibody staining as described later (21).

### Characterization and purification

Mouse BMSCs within 3-5 passages after the initial plating of the primary culture were harvested by trypsinization, and then the cells were fixed in neutralized 2% paraformaldehyde solution (Sigma, USA) for 30 min. The fixed cells were washed twice with phosphate buffered saline (PBS) (Sigma, USA) and incubated with antibodies to the following antigens: CD31, CD45, CD90 and CD44 (all from Chemicon, CA) for 30 min. Flow cytometry was performed with a FACScan flowcytometer (Becton Dickinson, CA) (22).

### BMSCs multilineage differentiation potential

Cultured stem cells of passage 2 were disseminated at a density of 5000 cells/cm<sup>2</sup> and maintained in growth medium for 3 days. Then medium was replaced by differentiation medium

with slight modifications. Differentiation medium contained minimum essential medium- $\alpha$  (MEM), 10% FBS, 2 mM L-glutamine, 100 U/ml penicillin and 100 mg/ml streptomycin and additionally either 10 nM dexamethasone, 50 mg/ml L-ascorbic acid and 10 mM  $\beta$ -glycerophosphate (osteogenic differentiation) or 10 nM dexamethasone, 200 mg/ml indomethacin, 5 mg/ml insulin and 0.5 mM 3-isobutyl-1-methylxanthine (IBMX) (adipogenic differentiation). Media change was performed every 3–4 days. After 21 days, osteogenic deposits and adipocytes were visualized by alizarin red and oil red O staining respectively (23).

#### **Alizarin red S staining**

Confirmation of osteogenesis was confirmed by means of Alizarin Red S staining (highlights extracellular matrix calcification). Cells in flasks (25 cm<sup>2</sup>) were washed with PBS and fixed in 10% (v/v) formaldehyde (Sigma-Aldrich). After 15 min alizarin red s (ARS) 2% (pH = 4.1) was added to each flask. The flasks were incubated at room temperature for 20 min. Then the flasks were washed four times with dH<sub>2</sub>O while being shaken for 5 min (24).

#### **Oil red O staining**

At day 10 after the induction of adipogenesis, the 24-well plates containing cultured BMSCs were washed with PBS three times, fixed with 10% formalin, sealed to prevent dehydration, and stored at 4 °C. Subsequently, the fixative was aspirated and the individual wells were stained with 600  $\mu$ l of freshly prepared 0.3% Oil Red O staining solution for 20 min and then washed five times with water (25).

#### **BMSCs Labeling with Bromodeoxyuridine (BrdU)**

To determine the fate of the transplanted BMSCs, BrdU were used. BMSCs reached the 3rd passage and transferred to a 250 ml flask. After about 40 percent of flask was occupied by the cells, BrdU was added to the culture at a concentration of 5 mM and then every time that culture is changed, BrdU was added. Until the cells reach a stage 70 to 80% confluence (26).

#### **Bronchoalveolar lavage (BAL) fluid**

One day after the last challenge, mice were anesthetized and BAL fluid was collected in by cannulating the trachea and lavaging with three 0.3 ml sterile PBS. Total cell number for each animal was determined and differential cell analysis was performed on slides stained with Wright and Giemsa solutions (27).

#### **Histopathological analysis**

Left lungs were fixed in formalin, embedded in paraffin, sectioned at 4 mm thickness, and stained

with hematoxylin-eosin (H&E) solution, periodic acid schiff (PAS) and Masson's trichrome to estimate inflammation, goblet cell hyperplasia and subepithelial fibrosis, respectively. Then five airway sections randomly distributed throughout the left lung were analyzed for each animal and their average scores were calculated as follows: to determine the goblet cell hyperplasia the ratio of PAS-positive cells/total cells were calculated, the adopted grading system was: 0, no goblet cells; 1, < 15%; 2, 15–30%; 3, 30–45%; 4, 45–60%; 5, >60% (27), the severity of lung inflammation was performed based on the degree of inflammatory cell infiltration to the peribronchiolar area. It was evaluated by a subjective scale: 0, no cells; 1, a few cells; 2, a ring of cells 1 cell layer deep; 3, a ring of cells 2–4 cells deep; 4, a ring of cells 4–6 cells deep; 5, a ring of cells > 6 cells deep (28). subepithelial fibrosis was asses using the Digimizer software. The area of collagen deposition (AC) and the perimeter of basement membrane of bronchioles (Pbm) were measured. Results are expressed as the AC per Pbm (AC/Pbm  $\mu$ m<sup>2</sup>/ $\mu$ m). The adopted grading system was:

- 0, <5 AC/Pbm ( $\mu$ m<sup>2</sup>/ $\mu$ m);
- 1, 5–10 AC/Pbm ( $\mu$ m<sup>2</sup>/ $\mu$ m);
- 2, 10–15 AC/Pbm ( $\mu$ m<sup>2</sup>/ $\mu$ m);
- 3, 15–20 AC/Pbm ( $\mu$ m<sup>2</sup>/ $\mu$ m);
- 4, 20–25 AC/Pbm ( $\mu$ m<sup>2</sup>/ $\mu$ m);
- 5, >25 AC/Pbm ( $\mu$ m<sup>2</sup>/ $\mu$ m) (28).

In order to analyze the migration of BMSCs to the lung tissue, light microscopic evaluation was made by a blinded investigator.

#### **Statistical analysis**

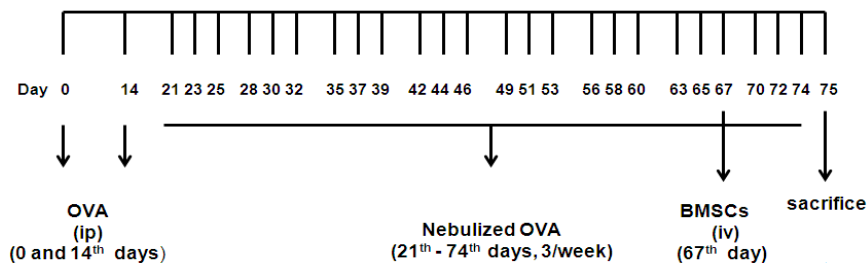
Data are presented as the mean $\pm$ SEM. Comparison between groups (control, asthma and asthma+BMSC) were performed using analyze with analysis of variance (ANOVA) followed by the Tukey test. A probability value of <0.05 was considered statistically significant.

## **Results**

### **Characterization of BMSCs**

The BMSCs appeared as a monolayer of large, fibroblast-like flattened cells which were able to adopt an osteogenic or adipogenic phenotype under appropriate conditions (Figure 2).

Flowcytometry analysis of BMSCs within 3-5 passages showed that BMSCs significantly expressed CD44 and CD90, but were negative for CD31 and CD45 (Figure 3).



**Figure 1.** Time table for mouse model of asthma and treatment with bone marrow-derived mesenchymal stem cells (BMSCs)

**The migration of BMSCs into the lung tissue**

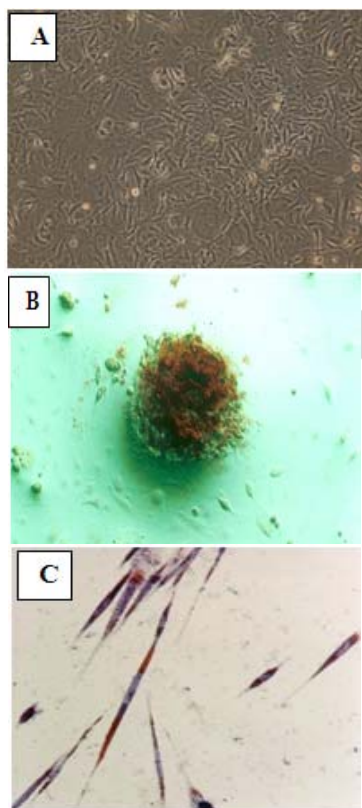
A large number of BrdU-BMSCs were found in the lungs of mice treated with BMSCs ( $67.33 \pm 9.21$ /visual field), indicating that BMSCs migrated into the inflamed lung (Figure 4).

**The BAL total WBC counts**

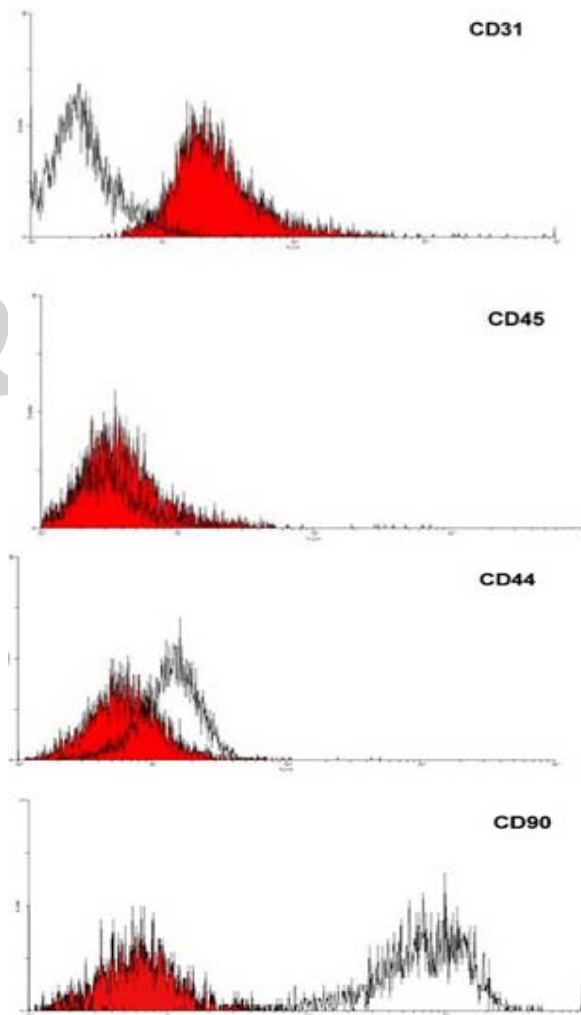
In asthmatic animals induced by ovalbumin, there was a significant increase in BAL total WBC counts ( $2495 \pm 339.76$ ,  $P < 0.01$ ). Treatment with BMSCs significantly decreased the accumulation of WBC ( $1485 \pm 214.64$ ,  $P < 0.05$ ). (Figure 5).

**Differential count of WBC in the BAL fluid**

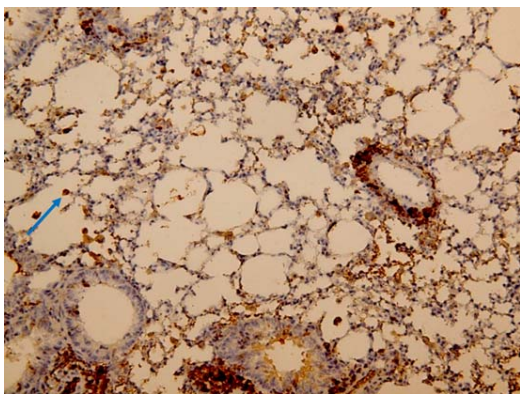
There was a significant increase in the percentage of neutrophils ( $23.68 \pm 0.94$ ,  $P < 0.001$ ) and eosinophils ( $24 \pm 1.41$ ,  $P < 0.01$ ) and a decrease in percentage of lymphocytes ( $30.14 \pm 4.1$ ,  $P < 0.01$ ) in BAL fluid of asthmatic animals compared with those



**Figure 2.** Initially adherent undifferentiated bone marrow-derived mesenchymal stem cells (BMSCs) grew as spindle-shaped cells (A). Alizarin red staining of mineralized bone tissue after osteogenic differentiation (B) and oil red O positive intracellular lipid droplets (C) indicates that BMSCs can differentiate to osteoblasts and adipocytes respectively



**Figure 3.** Flowcytometric analysis indicating that the cells were mesenchymal stem cells since CD44 and CD90 were positive and CD31 and CD45 were negative



**Figure 4.** BMSC migration into the lung tissue in ovalbumin-induced animal model of asthma in BALB-c mice treated with BMSCs (Asth+BMSC). Thin blue arrow shows BrdU-positive cell (magnification 20 ×)

of controls ( $14.48 \pm 0.45$ ,  $10.59 \pm 2.26$  and  $51.88 \pm 4.76$ , respectively). Treatment with BMSCs resulted in significant reduction in neutrophils ( $17.17 \pm 0.64$ ,  $P < 0.001$ ) and eosinophils ( $13.8 \pm 2.12$ ,  $P < 0.05$ ) with a nonsignificantly increase in lymphocytes ( $41.64 \pm 1.31$ ) compared with non treated asthmatic animals (Figure 5).

#### The peribronchial inflammatory cell infiltration

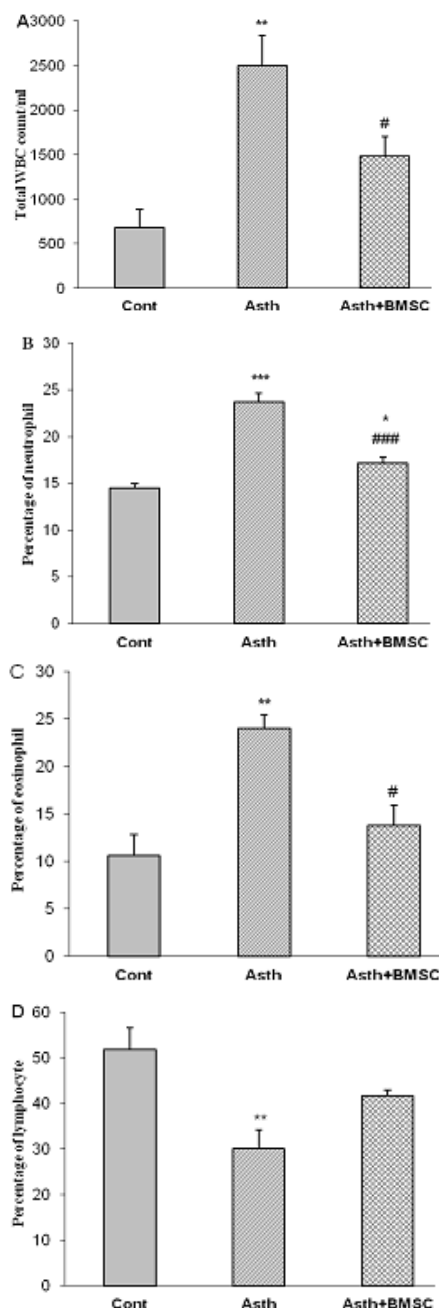
The mean peribronchial inflammatory cell infiltration score was significantly elevated in the asthma group versus the control group ( $4.75 \pm 0.25$  versus  $1 \pm 0.4$ ,  $P < 0.001$ ). Treatment with BMSCs markedly reduced the mean peribronchial inflammatory cell infiltration score versus the asthma group ( $2.16 \pm 0.4$ ,  $P < 0.01$ ) (Figure 6).

#### The airway goblet cell hyperplasia

The score of goblet cells evaluated by PAS staining showed that goblet cells in the asthmatic mice were significantly higher than those of the control mice ( $3.75 \pm 0.25$  versus  $0.75 \pm 0.25$ ,  $P < 0.001$ ). Asthmatic mice treated with BMSCs showed lower numbers of goblet cells compared with no treated asthmatic mice ( $1.6 \pm 0.33$ ,  $P < 0.01$ ). Furthermore, there was no significant difference between asthmatic mice treated with BMSCs and control mice (Figure 6).

#### The subepithelial fibrosis

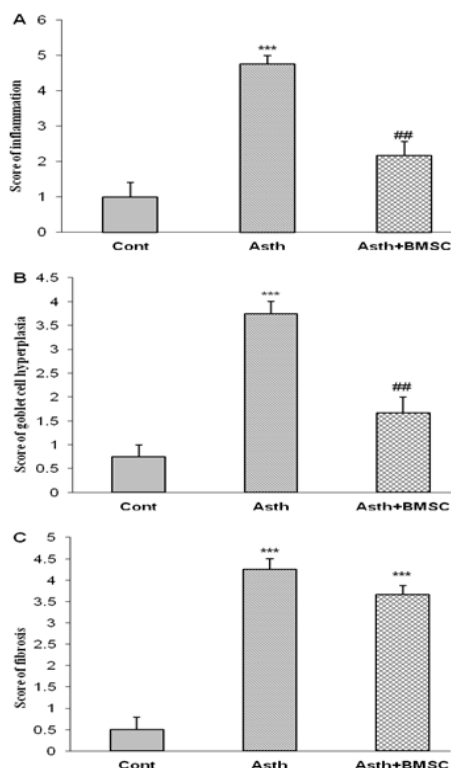
A significant increase in the extent of collagen deposition was observed in the asthma group as compared with control group ( $4.25 \pm 0.25$  versus  $0.5 \pm 0.25$ ,  $P < 0.001$ ). BMSCs therapy did not reduce the extent of collagen deposition ( $3.66 \pm 0.21$ ,  $P < 0.001$ ) (Figure 6). Photographs of lung histopathology of lung specimens in different groups were provided in Figure 7.



**Figure 5.** Total WBC count/ml (A) and the percentage of neutrophils (B), eosinophils (C) and lymphocytes (D) in the BAL fluid in control animals (Cont, n=4), OVA-induced asthma model (Asth, n=4) and asthmatic animals treated with BMSC (Asth+BMSC, n=6). Statistical comparison between groups was performed using analysis of variance followed by the Tukey test. \* $P < 0.05$ , \*\* $P < 0.01$ , \*\*\* $P < 0.001$  compared to control group, # $P < 0.05$ , ### $P < 0.001$  compared to asthma group

## Discussion

The results of the present study showed significant increase in inflammatory cell infiltration to the bronchoalveolar fluid and all scores of lung



**Figure 6.** The peribronchial inflammatory cell infiltration (A), the airway goblet cell hyperplasia (B) and the subepithelial fibrosis (C) in control animals (Cont, n=4), OVA -induced asthma model (Asth, n=4) and asthmatic animals treated with BMSC (Asth+BMSC, n=6). The degree of peribronchial inflammation was evaluated by a subjective scale. The scoring system was: 0, no cells; 1, a few cells; 2, a ring of cells 1 cell layer deep; 3, a ring of cells 2-4 cells deep; 4, a ring of cells 4-6 cells deep; 5, a ring of cells > 6 cells deep. The degree of goblet cell hyperplasia was reported as the ratio of PAS-positive cells/total cells. The adopted grading system was: 0, no goblet cells; 1, < 15%; 2, 15-30%; 3, 30-45%; 4, 45-60%; 5, > 60%. The degree of fibrosis was expressed as the area of collagen deposition per the perimeter of basement membrane (AC/Pbm  $\mu\text{m}^2/\mu\text{m}$ ) of bronchioles. The adopted grading system was: 0, <5 AC/Pbm ( $\mu\text{m}^2/\mu\text{m}$ ); 1, 5-10 AC/Pbm ( $\mu\text{m}^2/\mu\text{m}$ ); 2, 10-15 AC/Pbm ( $\mu\text{m}^2/\mu\text{m}$ ); 3, 15-20 AC/Pbm ( $\mu\text{m}^2/\mu\text{m}$ ); 4, 20-25 AC/Pbm ( $\mu\text{m}^2/\mu\text{m}$ ); 5, >25 AC/Pbm ( $\mu\text{m}^2/\mu\text{m}$ ). Statistical comparison between groups was performed using analysis of variance followed by the Tukey test. \*\*\* $P < 0.001$  compared to control group, ##  $P < 0.01$  compared to asthma group

pathological changes in asthma group compared to control group. In addition, it showed that BMSCs migrated to the lung tissue in Asthma+BMSC group and effectively inhibited airway inflammation, goblet cell hyperplasia and inflammatory cell infiltration to the bronchoalveolar fluid induced by OVA sensitization.

In this study BMSCs migrated to and localized in the lung tissue in Asthma+BMSC group. The ability of mesenchymal stem cells (MSCs) to migrate into the damaged and inflamed areas has been shown in several diseases such as cerebral ischemia (29), myocardial infarction (30) and pulmonary fibrosis (31). Despite much research, the mechanisms

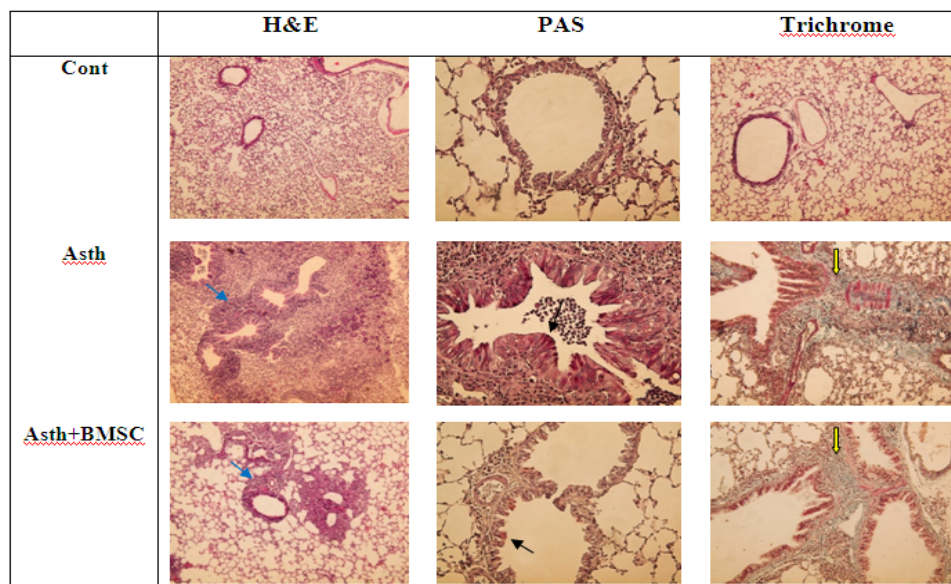
responsible for the migration and implantation of these cells are not well defined. However, the general result is that MSCs express multiple receptors for chemokine and cytokine that may play a role in their migration into the damaged tissue. It has been demonstrated that Stromal cell-derived factor-1 (SDF-1) and its cellular receptor, C-X-C chemokine receptor type 4 (CXCR4), are involved in MSCs migration to the brain (32), liver (33) and heart (34). Importantly, Exogenous MSCs migration to sites of inflammation in asthmatic mice, through a SDF-1/CXCR4-dependent mechanism, has been shown in Ou-Yang *et al* study (35). Therefore, it seems that BMSCs migrated to the lung tissue through such mechanism in current study.

Previously, it has been documented that chronic stimulation of T helper (Th) by allergens triggers their differentiation into T helper type 2 (Th2) cells. Th2 produce cytokines involved in immunoglobulin E (IgE) production, eosinophil activation, neutrophil and monocyte recruitment to tissues, fibrosis and excess mucus production. IgE antibodies bind to the IgE receptor on mast cells or basophils, causing the sensitization and activation of these cells in allergen re-exposure. Activation of mast cells triggers the release of inflammatory mediators which causes vasodilation, bronchoconstriction and tissue damage. Eosinophils cause airways inflammation by releasing their contents. Neutrophils and monocytes also release their inflammatory products, and increase these complications. Mentioned factors lead to structural changes of the airways including subepithelial fibrosis, goblet cell hyperplasia, airway smooth muscle hypertrophy and angiogenesis (36).

In fact, the increased inflammatory cell infiltration, especially neutrophil and eosinophil, to the bronchoalveolar fluid, lung inflammation, goblet cell hyperplasia and subepithelial fibrosis have been reported in OVA-sensitized animals (37, 38).

In the present study, significant increase in the infiltration of neutrophil and eosinophil to the bronchoalveolar fluid, lung inflammation, goblet cell hyperplasia and subepithelial fibrosis was observed in sensitized mice which confirmed sensitization (induction of an asthma animal model) of mice which is supported by previous studies (36-38).

In this study BMSCs decreased the infiltration of neutrophil and eosinophil to the bronchoalveolar fluid, lung inflammation and goblet cell hyperplasia in Asthma+BMSC group compared to asthma group. Over the last decade, MSCs have attracted significant interest to treat asthma and its complications because of their ability to regulate immune and inflammatory responses (8). Previous studies showed that intravenously introduce MSCs reduce airway inflammation, mucus hypersecretion and bronchoconstriction index as well as Th2 cytokines



**Figure 7.** Histopathological findings of bronchial wall in control animals (Cont), OVA -induced asthma model (Asth) and asthmatic animals treated with BMSC (Asth+BMSC). Blue thin arrows show inflammatory cell infiltration, black thin arrows show goblet cells, yellow thin arrows show collagen deposition; staining with hematoxin-eosin (H&E) solution, periodic acid schiff (PAS) and Masson's trichrome; magnification 10 ×, 40 × and 20 ×, respectively).

levels and inflammatory cells infiltration in murine model of asthma and chronic obstructive pulmonary disease (COPD) (13, 39-44). Bonfield *et al* showed that intravenous administration of human MSCs could significantly decrease airway inflammation, mucus hypersecretion and hyper responsiveness in animal model of asthma (38). Firinci *et al* used murine bone marrow MSCs in their experiments and demonstrated that intravenous administration of MSCs led to a significant decrease in basement membrane and smooth muscle layer thickness and reduced the number of mast cells and goblet cells (17). Ou-Yang *et al* reported that cell therapy could protect mice against a range of allergic airway inflammatory pathologies, including inflammatory cells infiltration, mast cell degranulation and airway hyperreactivity (35). All mentioned studies support the findings of the present study.

According to previous studies, induction of T-regulatory cells and Th2 to Th1 shift may attenuate inflammatory and allergic responses during asthma treatment. In fact the potential therapeutic effect of Th2 to Th1 in animal model of asthma was previously shown in several studies (45-47). Furthermore, Bonfield *et al* in their study showed that MSCs mediated their effect on the murine asthma model through decrease in Th2 cytokines (38). Therefore, by initiating such mechanisms BMSCs may exert therapeutic effects in our study.

However, BMSCs did not reduce subepithelial fibrosis, which is in contrast to findings of Bonfield *et al* study that revealed that MSCs decreased extracellular matrix deposition (38). It may be

explained by the differences in duration of OVA challenge which was longer, or amount of extracellular matrix deposition which was more in our study. Further studies are recommended to evaluate whether long-term cell therapy and the administration of repeated doses of BMSCs could reduce the subepithelial fibrosis in this model.

In contrast to other studies which have used cell therapy before induction of asthma, in this study we reported that cell therapy can be a therapeutic option for asthma treatment. Furthermore, since our protocol had 8 weeks OVA challenge for establishing asthma induced airway remodeling instead of 4 weeks (38), remodeling was well established in our study.

In our study, a limited investigation of circulating and lung inflammatory mediators failed to show any effects of cell therapy on inflammatory biomarkers including Th2 cytokines.

## Conclusion

In conclusion, the results of the present study demonstrated that cell therapy significantly suppressed lung pathology and inflammation in the ovalbumin induced asthma model in mice which deserve further studies including clinical investigations.

## Acknowledgment

This study was financially supported by Research Department of Tehran University of Medical Sciences, Tehran, Iran. The results described in this paper were a part of PhD student.

## References

1. Nakagome K, Nagata M. Pathogenesis of airway inflammation in bronchial asthma. *Auris Nasus Larynx* 2011; 38:555-563.
2. Bloemen K, Verstraalen S, Van Den Heuvel R, Witters H, Nelissen I, Schoeters G. The allergic cascade: review of the most important molecules in the asthmatic lung. *Immunol Lett* 2007; 113:6-18.
3. Al-Muhsen S, Johnson JR, Hamid Q. Remodeling in asthma. *J Allergy Clin Immunol* 2011; 128:451-462.
4. Bergeron C, Tulic MK, Hamid Q. Airway remodelling in asthma: from benchside to clinical practice. *Can Respir J* 2010; 17:85-93.
5. Girodet PO, Ozier A, Bara I, Tunon de Lara JM, Marthan R, Berger P. Airway remodeling in asthma : new mechanisms and potential for pharmacological intervention. *Pharmacol Ther* 2011; 130:325-337.
6. Cavkaytar O, Vurali D, Arik Yilmaz E, Buyuktiryaki B, Soyer O, Sahiner UM, *et al*. Evidence of hypothalamic-pituitary-adrenal axis suppression during moderate-to-high-dose inhaled corticosteroid use. *Eur J Pediatr* 2015; 174:1421-1431.
7. Baker N, Boyette LB, Tuan RS. Characterization of bone marrow-derived mesenchymal stem cells in aging. *Bone* 2015;70:37-47.
8. Bonfield TL, Caplan AI. Adult mesenchymal stem cells: an innovative therapeutic for lung diseases. *Discov Med* 2010; 9:337-345.
9. Tessier L, Bienzle D, Williams LB, Koch TG. Phenotypic and immunomodulatory properties of equine cord blood-derived mesenchymal stromal cells. *PLoS One* 2015;10:e0122954.
10. Mohammadian M, Abasi E, Akbarzadeh A. Mesenchymal stem cell-based gene therapy: A promising therapeutic strategy. *Artif Cells Nanomed Biotechnol*. 2015:1-6. [Epub ahead of print]
11. Rabani V, Shahsavani M, Gharavi M, Piryaei A, Azhdari Z, Baharvand H. Mesenchymal stem cell infusion therapy in a carbon tetrachloride-induced liver fibrosis model affects matrix metalloproteinase expression. *Cell Biol Int* 2010; 34:601-605.
12. Moodley Y, Atienza D, Manuelpillai U, Samuel CS, Tchongue J, Ilancheran S, *et al*. Human umbilical cord mesenchymal stem cells reduce fibrosis of bleomycin-induced lung injury. *Am J Pathol* 2009; 175:303-313.
13. Lee SH, Jang AS, Kim YE, Cha JY, Kim TH, Jung S, *et al*. Modulation of cytokine and nitric oxide by mesenchymal stem cell transfer in lung injury/fibrosis. *Respir Res* 2010; 11:16.
14. Semedo P, Correa-Costa M, Antonio Cenedeze M, Maria Avancini Costa Malheiros D, Antonia dos Reis M, Shimizu MH, *et al*. Mesenchymal stem cells attenuate renal fibrosis through immune modulation and remodeling properties in a rat remnant kidney model. *Stem cells* 2009; 27:3063-3073.
15. Deng W, Chen QW, Li XS, Liu H, Niu SQ, Zhou Y, *et al*. Bone marrow mesenchymal stromal cells with support of bispecific antibody and ultrasound-mediated microbubbles prevent myocardial fibrosis via the signal transducer and activators of transcription signaling pathway. *Cytotherapy* 2011; 13:431-440.
16. Molina EJ, Palma J, Gupta D, Torres D, Gaughan JP, Houser S, *et al*. Reverse remodeling is associated with changes in extracellular matrix proteases and tissue inhibitors after mesenchymal stem cell (MSC) treatment of pressure overload hypertrophy. *J Tissue Eng Regen Med* 2009; 3:85-91.
17. Firinci F, Karaman M, Baran Y, Bagriyanik A, Ayyildiz ZA, Kiray M, *et al*. Mesenchymal stem cells ameliorate the histopathological changes in a murine model of chronic asthma. *Int Immunopharmacol* 2011; 11:1120-1126.
18. Ogulur I, Gurhan G, Kombak FE, Filinte D, Barlan I, Akkoc T. Allogeneic pluripotent stem cells suppress airway inflammation in murine model of acute asthma. *Int Immunopharmacol* 2014; 22:31-40.
19. Cho KS, Park MK, Kang SA, Park HY, Hong SL, Park HK, *et al*. Adipose-derived stem cells ameliorate allergic airway inflammation by inducing regulatory T cells in a mouse model of asthma. *Mediators Inflamm* 2014; 2014:436-476.
20. Ogulur I, Gurhan G, Aksoy A, Duruksu G, Inci C, Filinte D, *et al*. Suppressive effect of compact bone-derived mesenchymal stem cells on chronic airway remodeling in murine model of asthma. *Int Immunopharmacol* 2014; 20:101-109.
21. Pirzad Jahromi G, Seidi S, Sadr SS, Shabanzadeh AP, Keshavarz M, Kaka GR, *et al*. Therapeutic effects of a combinatorial treatment of simvastatin and bone marrow stromal cells on experimental embolic stroke. *Basic Clin Pharmacol Toxicol* 2012; 110:487-493.
22. Kashani IR, Golipoor Z, Akbari M, Mahmoudi R, Azari S, Shirazi R, *et al*. Schwann-like cell differentiation from rat bone marrow stem cells. *Arch Med Sci* 2011; 7:45-52.
23. Song X, Xie S, Lu K, Wang C. Mesenchymal stem cells alleviate experimental asthma by inducing polarization of alveolar macrophages. *Inflammation* 2015; 38:485-492.
24. Zaminy A, Kashani IR, Barbarestani M, Hedayatpour A, Mahmoudi R, Farzaneh Nejad AR. Osteogenic Differentiation of Rat Mesenchymal Stem Cells from Adipose Tissue in Comparison with Bone Marrow Mesenchymal Stem Cells: Melatonin As a Differentiation Factor. *Iran Biomed J* 2008; 12:133-141.
25. Pachón-Peña G, Yu G, Tucker A, Wu X, Vendrell J, Bunnell BA, *et al*. Stromal stem cells from adipose tissue and bone marrow of age-matched female donors display distinct immunophenotypic profiles. *J Cell Physiol* 2011; 226:843-851.
26. Qian C, Tio RA, Roks AJ, Boddeus KM, Harmsen MC, van Gilst WH, *et al*. A promising technique for transplantation of bone marrow-derived endothelial progenitor cells into rat heart. *Cardiovasc Pathol* 2007; 16:127-135.
27. Khakzad MR, Mirsadraee M, Mohammadpour A, Ghafarzadegan K, Hadi R, Saghari M, *et al*. Effect of verapamil on bronchial goblet cells of asthma: an experimental study on sensitized animals. *Pulm Pharmacol Ther* 2012; 25:163-168.
28. Cao R, Dong XW, Jiang JX, Yan XF, He JS, Deng YM, *et al*. M(3) muscarinic receptor antagonist



- bencycloquidum bromide attenuates allergic airway inflammation, hyperresponsiveness and remodeling in mice. *Eur J Pharmacol* 2011; 655:83-90.
29. Wang L, Li Y, Chen J, Gautam SC, Zhang Z, Lu M, et al. Ischemic cerebral tissue and MCP-1 enhance rat bone marrow stromal cell migration in interface culture. *Exp Hematol* 2002; 30:831-836.
30. Pittenger MF, Martin BJ. Mesenchymal stem cells and their potential as cardiac therapeutics. *Circ Res* 2004; 95:9-20.
31. Moodley Y, Atienza D, Manuelpillai U, Samuel CS, Tchongue J, Ilancheran S, et al. Human umbilical cord mesenchymal stem cells reduce fibrosis of bleomycin-induced lung injury. *Am J Pathol* 2009; 175:303-313.
32. Wang Y, Deng Y, Zhou GQ. SDF-1alpha/CXCR4-mediated migration of systemically transplanted bone marrow stromal cells towards ischemic brain lesion in a rat model. *Brain Res* 2008; 1195:104-112.
33. Hatch HM, Zheng D, Jorgensen ML, Petersen BE. SDF-1alpha/CXCR4: a mechanism for hepatic oval cell activation and bone marrow stem cell recruitment to the injured liver of rats. *Cloning Stem Cells* 2002; 4:339-351.
34. Yu J, Li M, Qu Z, Yan D, Li D, Ruan Q. SDF-1/CXCR4-mediated migration of transplanted bone marrow stromal cells toward areas of heart myocardial infarction through activation of PI3K/Akt. *J Cardiovasc Pharmacol* 2010; 55:496-505.
35. Ou-Yang HF, Huang Y, Hu XB, Wu CG. Suppression of allergic airway inflammation in a mouse model of asthma by exogenous mesenchymal stem cells. *Exp Biol Med (Maywood)* 2011; 236:1461-1467.
36. Bloemen K, Verstraelen S, Van Den Heuvel R, Witters H, Nelissen I, Schoeters G. The allergic cascade: review of the most important molecules in the asthmatic lung. *Immunol Lett* 2007; 113:6-18.
37. Neamati A, Boskabady MH, Mohaghegh Hazrati S, Khakzad MR, Moosavi SH. The effect of natural adjuvants (G2, G2F) on lung inflammation of sensitized guinea pigs. *Avicenna J Phytomed* 2013; 3:364-370.
38. Bonfield TL, Koloze M, Lennon DP, Zuchowski B, Yang SE, Caplan AI. Human mesenchymal stem cells suppress chronic airway inflammation in the murine ovalbumin asthma model. *Am J Physiol Lung Cell Mol Physiol* 2010; 299:760-770.
39. Kapoor S, Patel SA, Kartan S, Axelrod D, Capitle E, Rameshwar P. Tolerance-like mediated suppression by mesenchymal stem cells in patients with dust mite allergy-induced asthma. *J Allergy Clin Immunol* 2012; 129:1094-1101.
40. Atsma DE, Fibbe WE, Rabelink TJ. Opportunities and challenges for mesenchymal stem cell-mediated heart repair. *Curr Opin Lipidol* 2007; 18:645-649.
41. Le Blanc K, Ringden O. Immunomodulation by mesenchymal stem cells and clinical experience. *J Intern Med* 2007; 262:509-25.
42. Abreu SC, Antunes MA, de Castro JC, de Oliveira MV, Bandeira E, Ornellas DS, et al. Bone marrow-derived mononuclear cells vs. mesenchymal stromal cells in experimental allergic asthma. *Respir Physiol Neurobiol* 2013; 187:190-198.
43. Ghorbani A, Feizpour A, Hashemzahi M, Gholami L, Hosseini M, Soukhtanloo M, et al. The effect of adipose derived stromal cells on oxidative stress level, lung emphysema and white blood cells of guinea pigs model of chronic obstructive pulmonary disease. *Daru J Pharm Sci* 2014; 22:26.
44. Feizpour A, Ghorbani A, Boskabady MH. Adipose-derived stromal cell therapy affects lung inflammation and tracheal responsiveness in guinea pig model of COPD. *PLoS ONE* 2014; 9: e108974.
45. Boskabady MH, Keyhanmanesh R, Khamneh S, Doostar Y. Potential immunomodulation effect of *Nigella sativa* on ovalbumin sensitized guinea pigs. *J Zhejiang Univ Sci B* 2011; 12:201-209.
46. Boskabady MH, Shahmohammadi Mehrjardi S, Rezaee A, Rafatpanah H, Jalali S. The impact of *Zataria multiflora* Boiss extract on *in vitro* and *in vivo* Th1/Th2 cytokine (IFN- $\gamma$ /IL4) balance. *J Ethnopharmacol* 2013; 150:1024-1031.
47. Bayrami G, Boskabady MH, Jalali S, Farkhondeh T. The effect of the extract of *Crocus sativus* on tracheal responsiveness and plasma levels of IL-4, IFN- $\gamma$ , total NO and nitrite in ovalbumin sensitized Guinea-pigs. *J EthnoPharmacol* 2013; 147:530-535.