

Neuroprotective effects of atomoxetine against traumatic spinal cord injury in rats

Qing-Xian Hou ¹, Li Yu ², Shao-Qi Tian ¹, Cui-Jun Jiang ¹, Wen-Jiu Yang ¹, Zhi-Jie Wang ^{1*}

¹ Department of Orthopedics, Hospital of Qingdao University, Qingdao, Shandong, 266000, China

² Department of Pharmacy, Qilu Hospital of Shandong University (Qingdao Hospital District), Qingdao, Shandong, 266000, China

ARTICLE INFO

Article type:

Original article

Article history:

Received: May 31, 2015

Accepted: Nov 5, 2015

Keywords:

Antioxidant

Atomoxetine

Neurology

Spinal cord injury

ABSTRACT

Objective(s): Spinal cord injury (SCI) often causes serious and irreversible neurological deficit leading to disability or impairment of normal physical activity. Atomoxetine, a selective norepinephrine transporter (NET) inhibitor has gained much attention in the field of the neurodevelopmental disorder, but its effect on SCI has not been evaluated. The present study has been undertaken to investigate the neuroprotective effects of atomoxetine.

Materials and Methods: Administration of atomoxetine 20 mg/kg IP was compared with methylprednisolone (MP) 30 mg/kg IP in traumatic spinal cord injured Wistar rats. Tissue samples were evaluated for apoptosis, inflammation, and oxidative stress, along with histopathological examination and neurological evaluation.

Results: There was no significant difference in the caspase-3 activity between the control and the sham groups or between the MP and the atomoxetine groups ($P=0.811$). The administration of atomoxetine significantly reduced tissue tumour necrosis factor alpha (TNF- α), and nitric oxide (NO) levels compared to the trauma group ($P<0.001$). Treatment with atomoxetine also decreased the tissue myeloperoxidase (MPO) activity ($P=0.026$) and increased the tissue superoxide dismutase (SOD) activity compared to the trauma group ($P=0.001$ and $P=0.004$, respectively). Histopathological examination showed less degenerated neurons in the atomoxetine group compared to trauma group.

Conclusion: This is the first experimental evidence showing meaningful neuroprotective effects of atomoxetine over SCI through anti-apoptotic, anti-inflammatory, and antioxidant effects by reducing lipid peroxidation, which was confirmed by biochemical, histopathological and the functional evaluation.

► Please cite this article as:

Hou QX, Yu L, Tian ShQ, Jiang CJ, Yang WJ, Wang ZJ. Neuroprotective effects of atomoxetine against traumatic spinal cord injury in rats. Iran J Basic Med Sci 2016; 19:272-280.

Introduction

Spinal cord injury (SCI) causes debilitating consequences on the quality of life, due to irreversible neuronal defalcation. The initial physical impact constitute the primary injury, which is usually followed by excitotoxicity, edema, inflammation, demyelination and glial scar (1, 2). The exact pathophysiological mechanism causing the cascade of secondary effects is still not understood (3). In recent years, there have been a surge in number of studies exploring the role of oxidative stress, inflammatory pathways, lipid peroxidation and apoptosis in these cascades (4-6).

Atomoxetine is characterised as a selective norepinephrine transporter (NET), which has recently grabbed attention of neurosciences community for use in various neurological disorders (7). Atomoxetine has been approved by the US Food and Drugs Administration (FDA) for

the treatment of attention deficit/hyperactivity disorder and associated symptoms of depression and anxiety (8). The primary mechanism of action for atomoxetine is considered to be the inhibition of norepinephrine reuptake into the presynaptic terminal; therefore, atomoxetine shows high selectivity for the presynaptic NET, with a low affinity for other monoamine transporters (9). Previous studies have shown that drugs that modulate norepinephrine have been successful at enhancing neurological function in SCI (7). However, there has been no systematic study to evaluate the potential use of atomoxetine for the treatment of SCI. This study aims to investigate whether atomoxetine treatment protects the spinal cord from apoptosis, inflammation, and oxidative stress in rat model of SCI. The efficacy of atomoxetine was compared with methylprednisolone (MP), a drug widely used for the management of SCI.

*Corresponding author: Zhi-Jie Wang. Department of Orthopedics, Hospital of Qingdao University, No. 16 Jiangsu Road, Shinan District, Qingdao, Shandong 266000, China. Tel/Fax: +98-86-532-82911847; email: wangzj6922@gmail.com

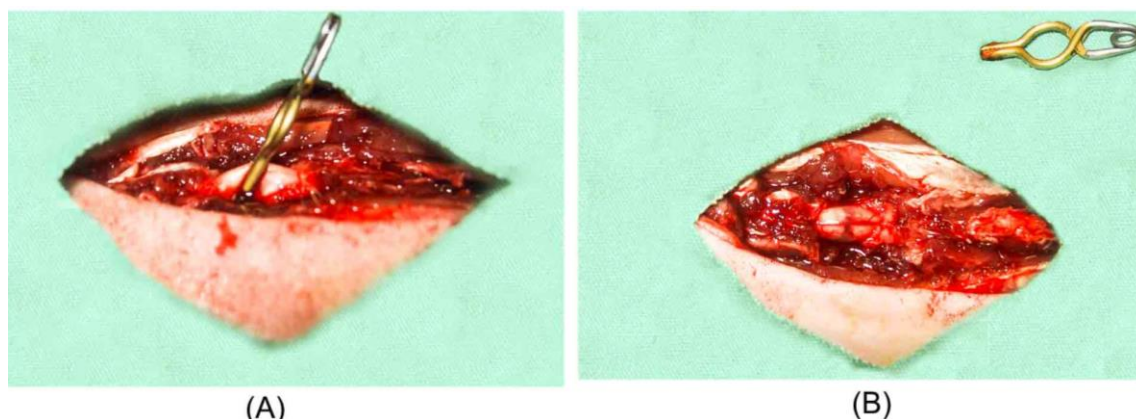


Figure 1. Experimental protocol: Rat spinal cord (a) extradural compression with a vascular clip and (b) Injured Spinal cord after extradural compression

Materials and Methods

Experimental groups

The study protocol involving the use of animals was reviewed and approved by the ethics committee of the Hospital of Qingdao University, Qingdao, China in accordance with the policies of the Guide to the Care and Use of Experimental Animals as per the Chinese Council of Animal Care. Adequate precautions were taken to minimize the number of animal use and to reduce their suffering. Forty adult male Wistar Albino rats weighing 200 to 300 g were purchased from the Shanghai Research Centre of Model Organisms (SRCMO). The rats were randomly assigned to five groups with eight rats per group. The groups were as follows: Group 1: control (n=9); no surgical procedure was performed. Spinal cord samples without trauma were obtained from the control group to compare the normal spinal cord morphology and baseline biochemical values. Group2: sham (n=9); rats underwent standard laminectomy procedure. Non-traumatized spinal cord samples were removed after 24 hr. Group 3: trauma (n=9); rats underwent SCI as described below. After laminectomy, spinal cord samples were obtained 24 hr after injury. Rats received a single intraperitoneal (IP) dose (1 cc) of physiological saline (0.9% NaCl) as vehicle. Group 4: atomoxetine (n=9); similar to group 3, but rats received a single intraperitoneal dose of 20 mg/kg atomoxetine (Astra-Zeneca, Cheshire, United Kingdom) immediately following SCI. Group 5: methylprednisolone (MP) (n=9); similar to group3, but rats received a single IP dose of 30 mg/kg (Hubei Gedian Humanwell Pharmaceutical, Hubei, China) immediately following SCI. Atomoxetine was dissolved in isotonic saline solution to achieve desired doses. All drug injections were administered intraperitoneally based on previous studies (10).

Anesthesia and spinal cord injury procedure

Adult male Wistar rats (200 to 300 g; Chinese Academy of Medical Sciences, Beijing, China) aged eight to ten weeks were used for injury. All rats were

kept under environmentally controlled conditions at room temperature (25 °C), with appropriate humidity and a 12-hr light cycle and granted free access to food and water. The animals were anesthetized with an IP injection of 10 mg/kg xylazine (Zhengzhou Sigma Chemical, He'nan, China) and 50 mg/kg ketamine (Ketalar, ParkeDavis, Turkey), and allowed to breathe spontaneously.

The rats were placed in a prone position. A T5 through T9 midline skin incision was made, and the paravertebral muscles were dissected. From T6 to T8, the spinous processes were removed, and laminectomy was performed. One minute extradural compression with a vascular clip (with 30 g force, Hangzhou Kangsheng Medical Equipments, Zhejiang, China) was performed around the exposed spinal cord, in order to cause an acute-compression injury [4,11]. At the end of the procedure, the clip was removed, and the surgical wound was closed in layers with silk sutures. Following closure of the wound, the drugs were administered intraperitoneally. The animals were euthanized after 3 week of surgery by injection of high dose (200 mg/kg) pentobarbital (Nembutal, Oak Pharmaceuticals, Lake Forest, IL, USA); then spinal cord samples (15 mm) were obtained from the operated area and divided into two equal parts. Cranial parts of the tissue samples were used for light microscopy evaluation and the caudal parts were cleared of blood with a scalpel and promptly stored at -80 °C for biochemical analysis.

Biochemical procedures

For the biochemical analysis, the tissues were homogenized in physiologic saline solution and centrifuged at 4000 g for 20 min. Thereafter, the upper clear supernatants forming the top layer was removed and used for the analysis.

Tissue caspase-3 analysis

Caspase-3 activity in the spinal tissue was evaluated using an ELISA kit (Uscn Life Science Inc.,

Wuhan, China). The ELISA procedures were performed according to the manufacturer's instructions. The microtiter plat contained caspase-3 antibody coating. Standards or samples were used in the designated microtiter wells with a biotin-conjugated antibody specific to caspase-3. Then, avidin conjugated to horseradish peroxidase (HRP) was added to each microplate well and incubated. Thereafter, 3, 3', 5, 5'-tetramethylbenzidine (TMB) substrate solution was added, and only the wells that contained caspase-3, biotin-conjugated antibody and enzyme-conjugated avidin exhibited a change in colour. The enzyme-substrate reaction was terminated by the addition of sulphuric acid solution, and the colour change was measured spectrophotometrically at a wavelength of 450 nm (BioTekELx800 Absorbance Microplate Reader). The results were expressed as ng/mg-protein.

Tissue tumour necrosis factor-alpha (TNF- α) analysis

The TNF- α level in the spinal tissue was measured using the ELISA kit (Uscn Life Science Inc., Wuhan, China). The sandwich ELISA kit contained TNF- α antibody precoated microtiter plates. Standards or samples were then added to the appropriate microtiter plate wells with a biotin-conjugated antibody specific to TNF- α . Next, avidin conjugated to HRP was added to each microplate well and incubated. After TMB substrate solution was added, only the wells that contained TNF- α , biotin-conjugated antibody and enzyme-conjugated avidin exhibited a change in colour. The enzyme-substrate reaction was terminated by the addition of sulphuric acid solution, and the colour change was measured spectrophotometrically at a wavelength of 450 nm. The results were expressed as pg/mg.

Tissue myeloperoxidase (MPO) analysis

The MPO enzyme activity in the spinal tissue was measured using commercially available ELISA kit (R&D systems, Minneapolis, USA). The sandwich ELISA procedure was performed according to the manufacturer's instructions. The microtiter plate provided with the kit was precoated with an antibody specific to MPO. Standards or samples were then added to the appropriate microtiter plate wells with abiotin-conjugated antibody specific to MPO. Next, avidin conjugated to HRP was added to each microplate well and incubated. After TMB substrate solution was added, only the wells that contained MPO, biotin-conjugated antibody and enzyme-conjugated avidin exhibited a change in colour. The enzyme-substrate reaction was terminated by the addition of sulphuric acid solution, and the colour change was measured spectrophotometrically at a wavelength of 450 nm. The results were expressed as pg/mg.

Tissue malondialdehyde (MDA) analysis

The MDA levels in the spinal tissue were evaluated using thiobarbituric acid (TBA) method as described by Ohkawa *et al* (12). Briefly, 100 ml of tissue homogenate was added to 50 ml of sodium dodecyl sulfate (SDS, 8.1%), and the resultant mixture was agitated and incubated for 10 min at room temperature. Then, 375 ml of acetic acid (pH 3.5, 20%) and 375 ml of TBA (0.6%) were added to this solution, and the samples were heated in boiling water for 60 min. After cooling at room temperature, 1.25 ml of butanol:pyridine (15:1) was added to each test tube and vortexed. The mixture was centrifuged at 4000 g for 5 min. The absorbance of the 750 ml of the organic layer in 1 ml of cells was read at 532 nm. MDA concentrations were expressed as nmol/mg-protein.

Tissue nitric oxide (NO) analysis

Tissue NO levels were evaluated using the method described by Miranda *et al* (13). Briefly, isolated tissues were homogenized in 10 ml of ice-cold saline solution and then absolute ethanol was added to precipitate the proteins. The material was allowed to separate over a 15 min period (at 25 °C), and then the supernatant was recovered. To 0.5 ml of supernatant, 0.5 ml vanadium (III) chloride (8 mgVCl₃/ml) was added, rapidly followed by the addition of 0.5 ml freshly prepared Griess reagent (1% sulfanilamide, 2% phosphoric acid, and 0.1% N-1 naphthyl-ethylenediamine dihydrochloride; 500 μ l). The mixture was then vortexed and incubated at 37 °C for 30 min before its absorbance was measured at 540 nm using the double-beam spectrophotometer. The results were expressed as nmol/mg protein.

Tissue superoxide dismutase (SOD) analysis

Total (Cu-Zn and Mn) SOD (EC1.15.1.1) activity was determined according to the method described by Sun *et al* (14). The principle of the method is based on the inhibition of nitro blue tetrazolium reduction by the xanthine-xanthine oxidase system as a superoxide generator. Activity was assessed in the ethanol phase of the supernatant after 1.0 ml ethanol/chloroform mixture (5/3, v/v) was added to the same volume of sample and centrifuged. One unit of SOD was defined as the enzyme amount causing 50% inhibition of nitro blue tetrazolium reduction. SOD activity was expressed as U/mg-protein.

Histopathological procedures

The spinal cord tissue obtained from animals from each group was fixed with 10% buffered paraformaldehyde for 24 hr and then embedded in paraffin. Using a microtome, 5 μ m-thick serial sections were cut from the paraffin blocks and stained with Mayer's Hematoxylin and counter stained with Eosin Stain (H&E) for histopathological

evaluation. The stained sections were observed under light microscope, by a pathologist who was blinded to the study. Histopathological changes such as edema, vascular congestion, neuronal degeneration and inflammation were scored between zero and three. Four different histopathologically assessed parameters were scored as follows; 0: absent; 1: mild; 2: moderate; and 3: common. The pathological score for each spinal cord was calculated based on the sum of the scores of the four different parameters (15).

To assess the degree of neuronal injury in more detail, the number of normal motor neurons in the anterior horn of the spinal cord (anterior to a line drawn through the central canal perpendicular to the vertebral axis) was counted in three sections for each animal and then averaged.

Neurological evaluation

The BBB (Basso, Beattie, and Bresnahan) locomotor rating scale was performed to evaluate functional recovery of the hindlimbs (16). Briefly, the rats were placed in an open field with a pasteboard-covered non-slip floor (n=6 in each group). In each testing session, each animal was observed for 4 min by two examiners who were blinded to the treatment. The assay was performed once per week and continued for 3 weeks after SCI. To evaluate the sensorimotor function, the grid-walking test assay was performed (17). Briefly, the positioning of the hindlimb paw was evaluated when the animal walked on an elevated plastic-coated wire mesh (40-45 cm with 2 cm² grid spaces). For three minutes, the animals were allowed to freely move on the wire mesh platform. If the foot fell through the grid, then the incidence was considered misstep. The grid-walking test was also performed once per week.

Statistical analysis

Data analysis was performed using SPSS for Windows, version 11.5 (SPSS Inc., Chicago, IL, USA). Shapiro Wilk test was performed to determine the normal distribution of the continuous variables. Kruskal Wallis test was performed to evaluate the difference in the median values. Spearman's Rank Correlation analysis was performed to calculate the degree of association between the continuous variables. A *P* value less than 0.05 was considered statistically significant.

Results

Tissue caspase-3 activity

There were significant differences among the tissue caspase-3 activity in the trauma group, the control and the sham groups ($P<0.001$). Thus, the data shows that SCI clearly caused an elevation of caspase-3 activity in the damaged tissue. When the atomoxetine group was compared with the trauma group, there was a statistically significant decrease in

caspase-3 activity ($P=0.001$). As in the atomoxetine group, the MP group also showed a statistically significant decrease in caspase-3 activity ($P=0.019$). There was no significant difference in the caspase-3 activity between the control and the sham groups ($P=0.929$) or between the MP and the atomoxetine groups ($P=0.811$).

Tissue TNF- α levels

There was a significant reduction in the tissue TNF- α levels in the animals administered atomoxetine ($P<0.001$). Additionally, the administration of MP also showed significant reduction in the tissue TNF- α levels as compared with the trauma group ($P<0.001$). The difference in the TNF- α were not significant between the control group and the sham group ($P=0.058$) or between the MP and the atomoxetine groups ($P=0.612$).

Tissue MPO activity

There was a significant difference between the tissue MPO activities between the control (spinal cord trauma) group and the sham control group ($P<0.001$); the results affirm that MPO activity is increased following SCI. Treatment with atomoxetine significantly decreased the tissue MPO activity ($P=0.026$). MP treatment also showed significant decrease in the MPO activity in spinal cord ($P=0.04$). There was no significant difference in the MPO activities between the control and the sham groups ($P=0.905$) or between the MP and the atomoxetine groups ($P=0.858$).

Tissue MDA levels

When mean tissue MDA levels of the control and the sham groups were compared with the trauma group, statistically significant differences were observed ($P<0.001$ for both). So these data showed that after SCI, tissue MDA levels were increased. When we compared the trauma and the atomoxetine groups, a statistically significant difference was observed ($P<0.001$). As in the atomoxetine group, the comparison between the trauma and the MP groups revealed a statistically significant difference ($P=0.004$). There was no significant difference in the MDA levels between the control and the sham groups ($P=0.698$) or between the MP and the atomoxetine groups ($P=0.357$).

Tissue NO levels

Tissue NO levels were found to be significantly increased in the trauma group when compared with both the control and the sham groups ($P<0.001$ for both). In the atomoxetine group, tissue NO levels were significantly decreased compared to the trauma group ($P<0.001$). Similar to the atomoxetine group, in the MP group, the NO levels were significantly decreased compared with the trauma group ($P=0.002$). There was no significant difference in the

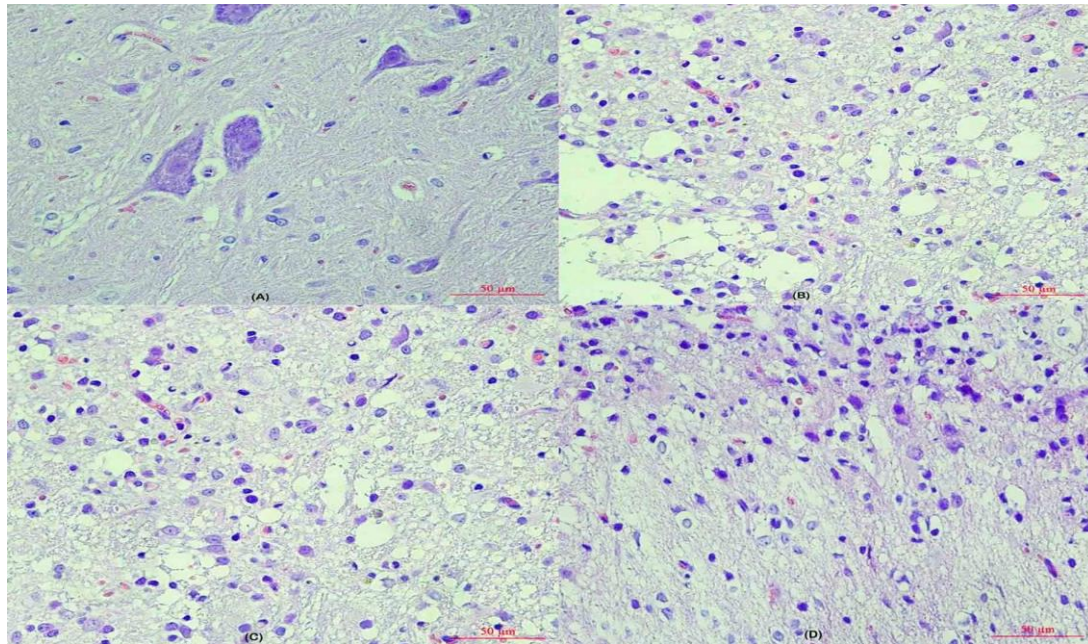


Figure 2. Evaluation of biochemical parameters. MP: methylprednisolone, TNF- α : tumour necrosis factor-alpha, MPO: myeloperoxidase, MDA: malondialdehyde, NO: nitricoxide, SOD: superoxide dismutase ($P<0.001$)

NO levels between the control and the sham groups ($P=0.12$) or between the MP and the atomoxetine groups ($P=0.512$).

Tissue superoxide dismutase (SOD) activity

Following SCI, tissue SOD activity decreased significantly when both the control and the sham groups were compared with the trauma group

($P<0.001$ for both). Both treatment with atomoxetine and MP, significantly increased the tissue SOD activity compared to the trauma group ($P=0.001$ and $P=0.004$, respectively). There was no significant difference in the tissue SOD activity between the control and the sham groups ($P=0.335$) or between the MP and the atomoxetine groups ($P=0.623$). The biochemical results of the study are shown in Figure 2.

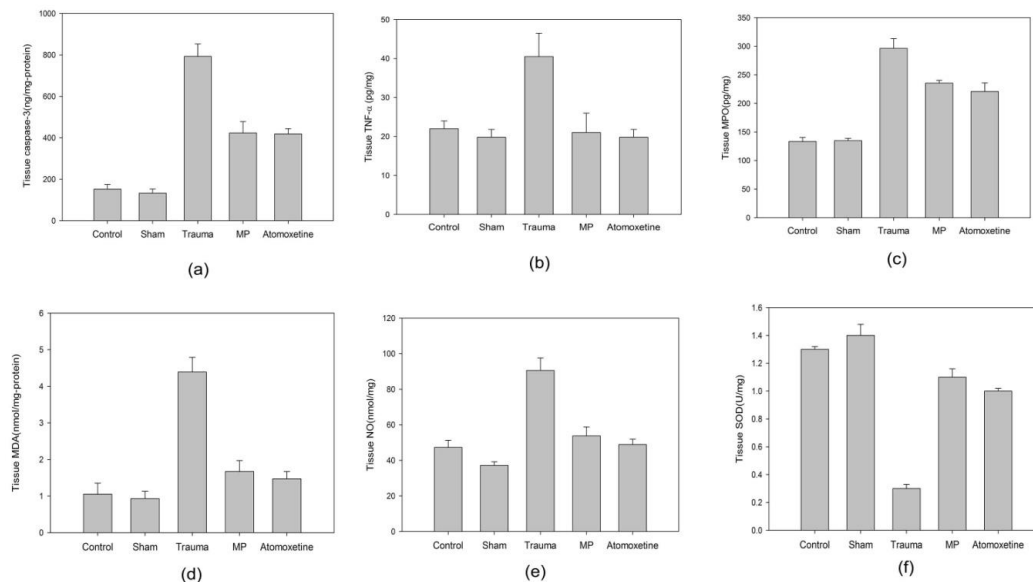


Figure 3. Photomicrographs of 5 μ m-thick spinal cord tissue sections from the different treatment groups (H&E). (A) Sham group, showing normal appearing spinal cord parenchyma only with mild edema and mild hemorrhagic congestion. (B). Trauma group, showing highly degenerated neurons. (C) Methylprednisolone group, showing less degenerated neurons, decreased edema and mild hemorrhagic. (D) Atomoxetine group, showing less degenerated neurons, and more normal appearing neurons. The cord tissues were well protected from injury, revealing less edema and mild hemorrhagic congestion

Table 1. Histopathological results relevant to the study groups

Myelinated Axon	Control	Sham	Trauma	Methylprednisolone	Atomoxetine	P-value
Pathology score	2.0	0.0	9.2	5.2	2.8	<0.001
Number of normal neurons	43.0	44.2	19.1	31.4	33.0	<0.001
Small-sized myelinated axons	0.0	0.0	85.1	72.8	1.0	<0.001
Medium-sized myelinated axons	11.2	0.0	120.0	87.2	64.8	<0.001
Large-sized myelinated axons	15.2	4.0	136.8	98.0	76.5	<0.001

Histopathological procedures

Light microscopy examinations of the spinal cord samples from the control and the sham groups were normal (Figure 3, A and B). In the trauma group, diffuse haemorrhage and congestion in the gray matter were observed at 24 hr after SCI. There was marked necatomoxetineis and edema. Additionally, in the damaged portions, polymorphonuclear leukocyte, lymphocyte and plasma cell infiltration were observed. Neural pyknosis, a loss of cytoplasmic features, and cytoplasmic eosinophilia were observed in the trauma group (Figure 3, C). In the atomoxetine group, as well as in the MP group, the spinal cord samples were well protected from SCI (Figure 3, D and E).

The trauma group showed statistically higher pathological score as compared to the control and the sham groups ($P<0.001$ for both). The atomoxetine group showed significantly lower pathological score than the pathological score of the trauma group ($P<0.001$). The MP group also showed lower pathologic score as compared to the trauma group ($P=0.042$). There was no significant difference between the control (spinal cord injury) and the sham groups ($P=0.08$) or between the MP and the atomoxetine groups regarding pathological score ($P=0.067$).

In the trauma group, the number of normal motor neurons in the anterior spinal cord was significantly decreased compared with both the control and the sham groups ($P<0.001$ for both). In the atomoxetine group, higher number of normal motor neurons was observed in the anterior region of the spinal cord

as compared with the trauma group ($P=0.003$). Similar to the atomoxetine group, the MP group also showed significantly higher numbers of normal motor neurons ($P=0.01$). The comparison between the atomoxetine and the MP groups did not show any significant differences ($P=0.688$). The histopathological results are shown in Table 1.

Neurologic evaluation

The initial BBB locomotive scale score was 21 for all groups. Following induction of injury to spinal cord, the mean BBB locomotor rating scale score was decreased significantly in the trauma group compared with the control and the sham groups ($P<0.001$ for both). Both the atomoxetine and the MP groups showed better BBB scores compared to the control (trauma only) group ($P=0.002$ and $P=0.003$, respectively). There was no significant difference in BBB locomotive scale score between the control and the sham groups ($P=0.8$) or between the MP and the atomoxetine groups ($P=0.141$). Following SCI, the mean angle recorded in the inclined-plane test was significantly lower in the trauma group than in the control and the sham groups ($P<0.001$ for both). Both atomoxetine and MP treatments revealed better angles in the inclined-plane test compared to the trauma group ($P=0.002$ and $P=0.001$, respectively). There was no significant difference in the inclined-plane test between the control and the sham groups ($P=0.058$) or between the MP and the atomoxetine groups ($P=0.493$). The results of the neurological examinations relevant to the study groups are shown in Figure 4.

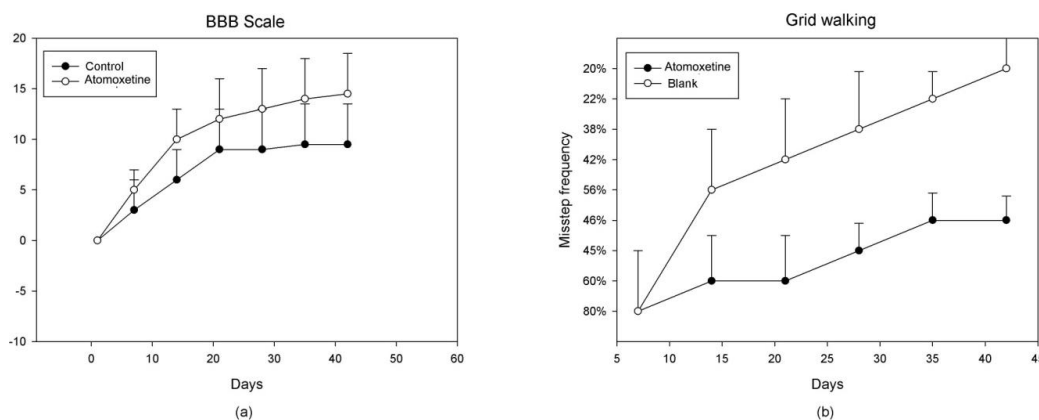


Figure 4. Behavioural performance at different times after spinal cord injury. Atomoxetine treated rats (n=6) had better BBB (Basso, Beattie, and Bresnahan) scores (A) and lower grid-walking misstep frequency (B) than methylprednisolone treated rats (n=6) 21 days after injury. Data are mean ± SD

Discussion

Trauma to spinal cord is the primary cause of neuronal tissue damage that is further worsened by secondary damage due to apoptosis, (18) generation of reactive oxygen species, (7, 9) inflammation, (5) and lipid peroxidation (19, 20). Previous experimental studies have shown valuable effects of statins in improving SCI (5). Taking clue from the beneficial effect of statins on SCI, we investigated the effects of atomoxetine on SCI, which had not been studied previously.

Furthermore, there are two rationales to study atomoxetine in SCI. First, atomoxetine has a very rapid bioavailability because its activation does not require hepatic metabolism (21). This brisk bioavailability may show a quick response to SCI. Secondly, atomoxetine was thought to have superior neuroprotective effects compared to other statins (22). The dosage of atomoxetine used in this study was based on pharmacological data from other studies where an oral dose of 20 mg/kg was used in rat model of prepulse inhibition (PPI) of acoustic startle (23). Additionally, other previous neuroprotection studies relevant to atomoxetine suggested the dose used in the present study (24).

The most popular treatment for SCI involves the administration of high-doses of MP, which makes it the widely used neuroprotective drug, although the efficiency and safety of MP has been vehemently questioned, resulting in discontinuation of its use in some settings (25). As MP is widely used in the experimental models of SCI, we compared the results of atomoxetine with MP (26). Neuronal death following SCI may be due to necrotomyelolysis (27, 28). Or apoptosis (29). Apoptosis causes death of neurons and oligodendrocytes in the spine; moreover, it agitates and damages the axon-myelin unit and diminishes impulse conduction resulting in neuronal loss (30). Caspase-3 is an interleukin converting enzyme and has been shown as the main effector of apoptosis in mammalian cells (31). Therefore, caspase-3 is a validated marker for indicating apoptotic activity (32). Our study shows an increase in the caspase-3, an indicator of trauma, activity after SCI. Both atomoxetine and MP treatments prevented apoptosis in the spinal cord by inhibition of caspase-3 activity.

Inflammatory reactions play key role in the development of traumatic secondary injury after SCI (5). Within a few hours after experimental SCI, pro-inflammatory cytokines, such as TNF- α , are upregulated (33). Upregulated TNF- α levels were shown to mediate inflammation, which results in secondary tissue damage and apoptosis after SCI (34). Furthermore, TNF- α was suggested to be central to neurodegeneration due to its early production after SCI (33). Our data confirms that there is a significant increase in the TNF- α levels in

injured spinal cord tissue. Both atomoxetine and MP treatments showed anti-inflammatory effects by inhibiting TNF- α levels. After injury to the spinal cord tissue, the neutrophils and other phagocytes reach the injured spinal cord tissue thereby produce hypochlorite, a strong oxidant synthesized by the enzyme MPO (35). Myeloperoxidase activity is strongly corresponds with the number of neutrophils and their inflammatory activity in the injured area (36). In the present study, the mean MPO activity was found to be increased in the traumatic spinal cord tissue. Both atomoxetine and MP administration caused a significant decrease in MPO activity, showing their anti-inflammatory effect. SCI produces free radicals due to oxidative stress resulting in initiation of lipid peroxidation activity in the damaged neural tissue (37). Our study shows significant increase in the levels of MDA, a stable products of lipid peroxidation, in the spinal cord tissue following traumatic SCI. Both atomoxetine and MP administration decreased the levels of MDA through inhibition of lipid peroxidation. Similarly, Somkuwar *et al* (38) reported that atomoxetine decreased the MDA levels in rats with spinal cord ischemia-reperfusion injury, suggesting that MDA can be used as a marker.

Oxidative stress is followed by antioxidant depletion and excess production of oxygen free radicals and NO at the site of injury.⁷ Oxygen free radicals can cause cytotoxicity by damaging lipids, proteins and nucleic acids (39). Furthermore, oxidative stress has a major implication in the progress of spinal cord lesions after the primary injury (40). Owing to high lipid content, the neuronal tissues such as spinal cord are prone to oxidative injury.

Histopathological examination of the spinal cord samples revealed that trauma to the spinal cord caused diffuse haemorrhage, marked edema, and necrotomyelolysis. However, in the injured portions of the spinal cord, there were infiltrating polymorphonuclear leukocytes, lymphocytes and plasma cells, which suggest an inflammatory response. Additionally, there was a decrease in the number of normal motor neuron in the anterior region of spinal cord. Both the atomoxetine and the MP groups showed better morphological results and a high number of normal motor neurons as compared with the trauma group. Furthermore, atomoxetine produced better histomorphological results than MP. It is known that the evaluation of the neuroprotection using histological evaluation does not always provide adequate conclusions. All small-, medium- and large-sized myelinated axons were significantly disturbed after traumatic SCI. Atomoxetine protected the spinal cord from traumatic injury by preserving the myelination of the axon. However, the same protective effect was also observed with MP.

Despite the lack of a significant difference between atomoxetine and MP for each of the biochemical parameters, atomoxetine produced better histopathological effect than MP. We hypothesized that this conflict occurred because there were only a few biochemical parameters studied in this study, so atomoxetine had further neuroprotective activity through other biochemical pathways than those were investigated in this study. The functional efficiency of the treatment was evaluated by locomotor performance with BBB scores (16). All rats had a BBB score of 21/21 before the trauma, and the traumatic SCI caused a significant decrease in BBB scores within 24 hr. Atomoxetine and MP treatments both revealed better BBB scores compared to the trauma group. There was also a decrease in the angle of the inclined-plane test following the traumatic SCI.

As expected, both atomoxetine and MP increased the mean angle in the inclined-plane test. As a result of these functional tests, both atomoxetine and MP treatments following SCI protected the spinal cord and improved neurological functions. All the results of this study suggest that atomoxetine have beneficial effects on preserving the normal spinal cord morphology, and cellular function by inhibiting apoptosis, and ameliorates inflammation and oxidative stress. However, the limitations of this study can be addressed by increasing the number of rats in each group to produce stronger conclusions. The dose dependent results may also be investigated.

Conclusion

The study shows meaningful neuroprotective effects in SCI. The anti-apoptotic, anti-oxidant and anti-inflammatory effects of atomoxetine are confirmed by biochemical, histopathological and the functional evaluation. This is the first experimental evidence suggesting therapeutic effect of atomoxetine in traumatic SCI. In light of these evidences, atomoxetine may be potential treatment for patients with SCI, but this needs to be further evaluated in human studies.

Acknowledgment

The study was financially supported by the Qingdao University, Qingdao, China.

Conflict of interest

No conflict of interest is associated with this work.

References

1. Dumont RJ, Okonkwo DO, Verma S, Hurlbert RJ, Boulos PT, Ellegala DB, *et al.* Acute spinal cord injury, part I: pathophysiologic mechanisms. *Clin Neuropharmacol* 2001; 24:254-264.
2. Mautes AE, Weinzierl MR, Donovan F, Noble LJ. Vascular events after spinal cord injury: contribution to secondary pathogenesis. *Phys Ther* 2000; 80:673-687.

3. Blight AR. Macrophages and inflammatory damage in spinal cord injury. *J Neurotrauma* 1992; 9:S83-S91.
4. Cemil B, Topuz K, Demircan MN, Kurt G, Tun K, Kutlay M, *et al.* Curcumin improves early functional results after experimental spinal cord injury. *Acta Neurochir (Wien)* 2010; 152:1583-1590.
5. Esposito E, Rinaldi B, Mazzon E, Donniacuo M, Impellizzeri D, Paterniti I, *et al.* Anti-inflammatory effect of simvastatin in an experimental model of spinal cord trauma: involvement of PPAR-alpha. *J Neuroinflamm* 2012; 9:81.
6. Pannu R, Barbosa E, Singh AK, Singh I. Attenuation of acute inflammatory response by atorvastatin after spinal cord injury in rats. *J Neurosci Res* 2005; 79:340-350.
7. Kratochvil CJ, Vaughan BS, Harrington MJ, Burke WJ. Atomoxetine: a selective noradrenaline reuptake inhibitor for the treatment of attention-deficit/hyperactivity disorder. *Expert Opin Pharmacother* 2003; 4:1165-1174.
8. Pataki CS, Feinberg DT, McGough JJ. New drugs for the treatment of attention-deficit/hyperactivity disorder. *Expert Opin Emerg Drugs* 2004; 9:293-302.
9. Gehlert DR, Gackenheim SL, Robertson DW. Localization of rat brain binding sites for [3H]atomoxetine, an enantiomerically pure ligand for norepinephrine reuptake sites. *Neurosci Lett* 1993; 157:203-206.
10. Swanson CJ, Perry KW, Koch-Krueger S, Katner J, Svensson KA, Bymaster FP. Effect of the attention deficit/hyperactivity disorder drug atomoxetine on extracellular concentrations of norepinephrine and dopamine in several brain regions of the rat. *Neuropharmacology* 2006; 50:755-760.
11. Kurt G, Ergun E, Cemil B, Borcek AO, Borcek P, Gulbahar O, *et al.* Neuroprotective effects of infliximab in experimental spinal cord injury. *Surg Neurol* 2009; 71:332-336.
12. Ohkawa H, Ohishi N, Yagi K. Assay for lipid peroxides in animal tissues by thiobarbituric acid reaction. *Anal Biochem* 1979; 95:351-358.
13. Miranda KM, Espey MG, Wink DA. A rapid, simple spectrophotometric method for simultaneous detection of nitrate and nitrite. *Nitric Oxide* 2001; 5:62-71.
14. Sun Y, Oberley LW, Li Y. A simple method for clinical assay of superoxide dismutase. *Clin Chem* 1988; 34:497-500.
15. Kertmen H, Gurer B, Yilmaz ER, Sanli AM, Sorar M, Arikok AT, *et al.* The protective effect of low-dose methotrexate on ischemia-reperfusion injury of the rabbit spinal cord. *Eur J Pharmacol* 2013; 714:148-156.
16. Basso DM, Beattie MS, Bresnahan JC. A sensitive and reliable locomotor rating scale for open field testing in rats. *J Neurotrauma* 1995; 12:1-21.
17. Z'Graggen WJ, Metz GA, Kartje GL, Thallmair M, Schwab ME. Functional recovery and enhanced corticofugal plasticity after unilateral pyramidal tract lesion and blockade of myelin-associated neurite growth inhibitors in adult rats. *J Neurosci* 1998; 18:4744-4757.

18. Beattie MS, Hermann GE, Rogers RC, Bresnahan JC. Cell death in models of spinal cord injury. *Prog Brain Res* 2002; 137:37-47.
19. Hulsebosch CE. Recent advances in pathophysiology and treatment of spinal cord injury. *Adv Physiol Educ* 2002; 26:238-255.
20. Dinc C, Iplikcioglu AC, Atabey C, Eroglu A, Topuz K, Ipcioglu O, *et al.* Comparison of deferoxamine and methylprednisolone: protective effect of pharmacological agents on lipid peroxidation in spinal cord injury in rats. *Spine* 2013; 38:E1649-E1655.
21. Sauer JM, Ring BJ, Witcher JW. Clinical pharmacokinetics of atomoxetine. *Clin Pharmacokinet* 2005; 44:571-590.
22. Ripley DL. Atomoxetine for individuals with traumatic brain injury. *J Head Trauma Rehabil* 2006; 21:85-88.
23. Gould TJ, Rukstalis M, Lewis MC. Atomoxetine and nicotine enhance prepulse inhibition of acoustic startle in C57BL/6 mice. *Neurosci Lett* 2005; 377:85-90.
24. Bymaster FP, Katner JS, Nelson DL, Hemrick-Luecke SK, Threlkeld PG, *et al.* Atomoxetine increases extracellular levels of norepinephrine and dopamine in prefrontal cortex of rat: a potential mechanism for efficacy in attention deficit/hyperactivity disorder. *Neuropsychopharmacology* 2002; 27:699-711.
25. Hurlbert RJ, Hamilton MG. Methylprednisolone for acute spinal cord injury: 5-year practice reversal. *Can J Neurol Sci* 2008; 35:41-45.
26. Schroter A, Lustenberger RM, Obermair FJ, Thallmair M. High-dose corticosteroids after spinal cord injury reduce neural progenitor cell proliferation. *Neuroscience* 2009; 161:753-763.
27. Balentine JD. Pathology of experimental spinal cord trauma. I. The necrotic lesion as a function of vascular injury. *Lab Invest* 1978; 39:236-253.
28. Borgens RB, Blight AR, Murphy DJ. Axonal regeneration in spinal cord injury: a perspective and new technique. *J Comp Neurol* 1986; 250:157-167.
29. Liu XZ, Xu XM, Hu R, Du C, Zhang SX, McDonald JW, *et al.* Neuronal and glial apoptosis after traumatic spinal cord injury. *J Neurosci* 1997; 17:5395-5406.
30. Pannu R, Christie DK, Barbosa E, Singh I, Singh AK. Post-trauma Lipitor treatment prevents endothelial dysfunction, facilitates neuroprotection, and promotes locomotor recovery following spinal cord injury. *J Neurochem* 2007; 101:182-200.
31. Keane RW, Kraydieh S, Lotocki G, Bethea JR, Krajewski S, Reed JC, *et al.* Apoptotic and anti-apoptotic mechanisms following spinal cord injury. *J Neuropathol Exp Neurol* 2001; 60:422-429.
32. Sakurai M, Nagata T, Abe K, Horinouchi T, Itoyama Y, Tabayashi K. Survival and death-promoting events after transient spinal cord ischemia in rabbits: induction of Akt and caspase3 in motor neurons. *J Thorac Cardiovasc Surg* 2003; 125:370-377.
33. Hayashi M, Ueyama T, Nemoto K, Tamaki T, Senba E. Sequential mRNA expression for immediate early genes, cytokines, and neurotrophins in spinal cord injury. *J Neurotrauma* 2000; 17:203-218.
34. Pan W, Zhang L, Liao J, Csernus B, Kastin AJ. Selective increase in TNF alpha permeation across the blood-spinal cord barrier after SCI. *J Neuroimmunol* 2003; 134:111-117.
35. Bao F, Chen Y, Dekaban GA, Weaver LC. Early anti-inflammatory treatment reduces lipid peroxidation and protein nitration after spinal cord injury in rats. *J Neurochem* 2004; 88:1335-1344.
36. Christie SD, Comeau B, Myers T, Sadi D, Purdy M, Mendez I. Duration of lipid peroxidation after acute spinal cord injury in rats and the effect of methylprednisolone. *Neurosurg Focus* 2008; 25:E5.
37. Torres S, Salgado-Ceballos H, Torres JL, Orozco-Suarez S, Diaz-Ruiz A, Martinez A, *et al.* Early metabolic reactivation versus antioxidant therapy after a traumatic spinal cord injury in adult rats. *Neuropathology* 2010; 30:36-43.
38. Somkuwar SS, Jordan CJ, Kantak KM, Dwoskin LP. Adolescent Atomoxetine Treatment in a Rodent Model of ADHD: Effects on Cocaine Self-Administration and Dopamine Transporters in Frontostriatal Regions. *Neuropsychopharmacology* 2013; 38:2588-2597.
39. Dawson TM, Dawson VL, Snyder SH. Molecular mechanisms of nitric oxide actions in the brain. *Ann N Y Acad Sci* 1994; 738:76-85.
40. Hulsebosch CE, DeWitt DS, Jenkins LW, Prough DS. Traumatic brain injury in rats results in increased expression of Gap-43 that correlates with behavioral recovery. *Neurosci Lett* 1998; 255:83-86.