

## The effect of oral and intraurethral trimetazidine use on urethral healing

Ali Ayyildiz <sup>1\*</sup>, Sema Nur Ayyildiz <sup>2</sup>, Erdal Benli <sup>1</sup>, Havva Erdem <sup>3</sup>, Selma Cirrik <sup>3</sup>, Tevfik Noyan <sup>2</sup>, R. Cankon Germiyanoglu <sup>4</sup>, Abdullah Çirakoglu <sup>1</sup>

<sup>1</sup> Ordu University Medical Faculty, Urology Department, Ordu, Turkey

<sup>2</sup> Ordu University Medical Faculty, Clinical Biochemistry Department, Ordu, Turkey

<sup>3</sup> Ordu University Medical Faculty, Pathology Department, Ordu, Turkey

<sup>4</sup> Ondokuz Mayıs University Medical Faculty, Urology Department, Samsun, Turkey

### ARTICLE INFO

#### Article type:

Original article

#### Article history:

Received: Dec 15, 2015

Accepted: Apr 28, 2016

#### Keywords:

Oxidative stress

Trimetazidine

Urethral healing

Urethral injury

### ABSTRACT

**Objective(s):** We aimed to study the effect of trimetazidine (TMZ) on urethral wound repair.

**Materials and Methods:** A total of 52 male rats were used; 8 groups were formed: 1-week and 3-week control (C1,C3), sham (S1, S3), oral (OT1, OT3), and intraurethral TMZ (IUT1, IUT3) groups. Serum and urine total antioxidant capacity (TAC), total oxidant capacity (TOC), and 8-hydroxy-deoxy-guanosine (8-OHdG) were studied. Hematoxyline-Eosin was used for the histopathological study. In addition, tumor necrosis factor alpha (TNF-  $\alpha$ ), interleukin 1 $\alpha$ , and  $\beta$  levels were compared across groups by an immunohistochemical method.

**Results:** There were significant differences between C3 and IUT3, OT3 and IUT3 with respect to serum TAC in 3-week groups ( $P=0.013$ ;  $P=0.001$ ). Serum TOC levels were significantly different between C3 and IUT3; S3 and OT3; and OT3 and IUT3 groups ( $P=0.024$ ;  $P=0.019$ ;  $P=0.000$ , respectively). Serum 8-OHdG levels were significantly different between C3 and OT3 groups ( $P=0.033$ ). In the immunohistochemical examination, C1 and OT1; C1 and IUT1; and S1, S3, OT1, OT3, IUT1 groups were significantly different with respect to IL-1 $\beta$  staining ( $P=0.007$ ;  $P=0.000$ ;  $P=0.009$ ), while there was a significant difference between C3 and S3 with respect to IL-1 $\beta$  ( $P=0.000$ ).

**Conclusion:** TMZ increased urinary total oxidant level; while increasing serum TAC levels in the long-term. It also reduced serum TAC levels in urethral use and caused an increase in serum TOC levels with minimal effects on DNA injury and repair. No effect was detected on IL1  $\alpha$  and TNF, but partially reduced the effect on IL-1  $\beta$  levels.

### ► Please cite this article as:

Ayyildiz A, Nur Ayyildiz S, Benli E, Erdem H, Cirrik S, Noyan T, Germiyanoglu RC, Çirakoglu A. The effect of oral and intraurethral trimetazidine use on urethral healing. Iran J Basic Med Sci 2016; 19:932-939.

### Introduction

Urethral injuries occur as a result of blunt or penetrating injuries, obstetric injuries, endoscopic urinary interventions, urethral catheterization, etc. They result in inflammation, ischemia, regeneration, and fibrosis. Depending on the severity of reactions, alterations in tissue characteristics may occur, and it cannot be predicted whether these injuries would end up with complete healing or obstruction. Fibrosis is a typical terminal sequela, and patients often need interventions for recurrent urethral strictures. Simple urethral dilatation, internal urethrotomy, and plasmakinetics are used as the initial treatment options for urethral strictures. Open urethroplasty can be used in difficult-to-treat patients (1, 2).

Wound repair is a multifactorial process that starts immediately after tissue injury and contains successive stages. Reactive oxygen species (ROS) are

some of the factors that affect wound repair. ROS is normally an essential component of body's defense system against pathogens at the wound site. In response to oxidation, neutrophils and macrophages produce great quantities of ROS, which plays a role both in eliminating foreign microorganisms and injuring surrounding tissues. A marked inflammation and elevated ROS levels point to oxidative stress, especially in chronic wounds. Higher ROS levels delay wound repair.

In the pathogenesis of many disorders, the severity of tissue injury can be established by ROS measurement. Although they take part in all stages of wound repair, they are at the highest level during the inflammatory stage (3). Many studies have reported various ROS that play an important roles in wound repair. However, the balance of this system is vital. ROS are essential both for battling against foreign pathogens and initiating the essential angiogenesis. Antioxidants have achieved successful results in the

\*Corresponding author: Ali Ayyildiz. Akyazi Mah, 828. Sk. No: 6, Altınordu, Ordu, Turkey. Tel: 90-505-5029931; email: urology52@gmail.com; semana52@gmail.com

management of a variety of disorders. They are currently used for wound care (4).

Trimetazidine (TMZ), also known as 1-(2,3,4-trimethoxybenzyl)-piperazine, has antioxidant and anti-ischemic properties. It preserves cellular membrane and integrity (5-7). The protective effects of TMZ have been attributed to both preservation of ATP synthesis and reduction of free radicals (5). It reportedly prevents neutrophil infiltration and inhibits systemic inflammatory mediators (5, 8).

Some previous experimental and clinical studies have been conducted to prevent urethral strictures from occurring following urethral injuries (1, 2). However, the results of those studies could not be routinely introduced into clinical practice. This study investigated the levels of factors functioning in wound repair, including total antioxidant capacity (TAC), total oxidant capacity (TOC), 8-hydroxydeoxyguanosine (8-OHdG), tumor necrosis factor (TNF), and interleukin-1 (IL-1 $\alpha$  and  $\beta$ ). We aimed to examine TMZ's effects on urethral injuries both biochemically and histopathologically.

## Materials and Methods

### Formation of the groups and experimental design

This study was conducted at the experimental animal laboratory of 19 Mayıs University after being approved by the local ethics committee. A total of 52 male rats were used. The experiments were conducted on control, sham, 1-week- and 3-week oral, and intraurethral TMZ groups. Therefore, a total of 8 study groups were formed (Table 1).

Urethral injury was created as previously described by A. Ayyıldız (1). The urethral damage was created with a 29 G needle which was given the shape of a hook by scratching the ventral surface of the urethral epithelium starting from approximately 0.5 cm proximal to external meatus (anterior urethra). The control group only received urethral injury. The sham group was administered 1.5 ml intraurethral isotonic saline on alternate days after urethral injury. Oral TMZ group was administered 5 mg/kg/day/1.5 ml TMZ via gavage for 1 week and 3 weeks. Intraurethral TMZ group was administered 5 mg/kg/alternate day/1.5 ml TMZ via an angiocath begun immediately after urethral injury and administered for 1 week and 3 weeks.

### Biochemistry

Rats were placed in metabolic cages and their urines were collected. The urine samples were stored at -80°C until the analysis of 8-OHdG, TAC, and TOC levels. Blood samples taken into gel biochemistry tubes were kept at room temperature for 30 min and then centrifuged at 3000 g for 15 min. Serum samples were stored as aliquots at -80 °C.

### 8-OHdG measurement

8-OHdG in rat urine was measured with Urinary 8-OHdG ELISA kit (Northwest LSS Urinary 8-OHdG ELISA Lot:U80H-2121) in Urinary ELISA reader (Biotek, ELX 800) at a wavelength of 450 nm. Urine samples were studied with 1:3 dilution. 8-OHdG measurement in rat serum was done with High Sensitive 8-OHdG ELISA kit (Northwest LSS8-OHdG ELISA Lot:HS80H-2121) in ELISA reader (Biotek, ELX 800) at a wavelength of 450 nm. The sera were not diluted before the study.

### Measurement of total antioxidant capacity (TAC)

TAC measurements in urine and serum samples were done in the Abbott C8000 Architect device with the ABTS-based colorimetric method described by Erel (9) [Rel Assay Diagnostics TAC (Total Antioxidant Status) Lot No: JY14043A].

### Measurement of total oxidant capacity (TOC)

TOC measurements in urine and serum samples were done in the Abbott C8000 Architect device using the direct automatized measurement method described by Erel (10) (Rel Assay Diagnostics TOC/Total Oxidant Status LotNo: JY140490). This analysis is based on the principle of the oxidation of ferrous ions to ferric ions in the presence of a variety of oxidant species in acidic medium and the subsequent measurement of ferric ions with xylenol orange.

### Pathology

#### Histopathological examination

Approximately 0.5 mm thick sections were taken from the penectomy materials from normal urethra and injured urethral sites. Following alcohol fixation for 24 hr, the sections were stained with Hematoxyline Eosin (H&E). All specimens were examined by the same pathologist under a light microscope. Urethral epithelial connective tissue, spongy tissue regularity, urethral and papillary structures, inflammation, hyperemia, and bleeding parameters were studied. Oral and intraurethral TMZ groups were compared with both control and sham groups.

#### Immunohistochemistry

##### IL-1 $\alpha$ analysis

IL-1 $\alpha$  (H-159): Paraffin blocks were sliced in 4  $\mu$ m thickness. The tissues were separated from paraffin and hydrated with xylene and alcohol. The sliced sections were primarily stained with IL-1 alpha [(H-159) (Santa Cruz Biotechnologies, Santa Cruz, CA, USA)]. This antibody was diluted at a ratio of 1:10. PBS was used as the negative control.

**Table 1.** Groups of study

1. group : Control group - 1 week	(C1)
2. group : Control group - 3 weeks	(C3)
3. group : Sham group - 1 week	(S1)
4. group : Sham group - 3 weeks	(S3)
5. group : Oral TMZ group - 1 week	(OT1)
6. group : Oral TMZ group - 3 weeks	(OT3)
7. group : Intraurethral TMZ - 1 week	(IUT1)
8. group : Intraurethral TMZ - 3 weeks	(IUT3)

**IL-1β analysis**

IL-1β (H-153): IL-1β was immunohistochemically detected by using lot no: sc-7884 (Santa Cruz Biotechnologies, Santa Cruz, CA, USA). This antibody was diluted at a ratio of 1:10. Immunostaining was applied according to the streptavidin-biotin-peroxidase protocol for IL-1β receptors.

**TNF-α analysis**

Anti-TNFα antibody (100 µg/vial, Lyophilized, Wuhan Boster Bio-engineering Co, Ltd) was added 0.2 ml distilled water and a concentration of 500 µg/ml was obtained. This antibody was diluted at a ratio of 1:100.

The presence of cells with no evidence of staining or the presence of rare positively stained cells, staining was accepted to be less than 3% and reported as negative. Immunohistochemical findings were evaluated on the basis of the frequency and intensity of staining. Staining intensity was graded as 0 (negative), 1 (weak), 2 (moderate), and 3 (strong). Staining frequency was graded between 0 and 4. Grade 0 indicated a staining of < 3%; grade 1: 3-15%; grade 2: 25-50%; grade 3: 50-75%; and grade 4: >75%. The index score was calculated by multiplying the intensity and frequency scores. The results were shown on 4 scales as follows: index score 0=0; index score 1=1 and 2; index score 2=3 and 4; and index score 3=6-12.

**Statistical analysis**

Statistical analyses were performed with SPSS 16 software package. For histopathological and immunohistochemical parameters Nonparametric Mann-Whitney U test was used. One-way ANOVA for

multiple comparisons and *post hoc* Tukey HSD test were used on STAC, STOC, S8-OHdG, UTAC, UTOC, and U8-OHdG. A *P*-value of less than 0.05 was considered statistically significant.

**Results**

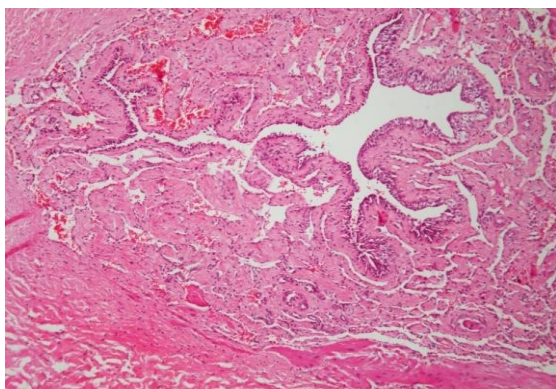
All parameters were compared for one and three weeks among control (C), sham (S), oral (OT), and intraurethral TMZ (IUT) groups.

**Urine and serum TAC, TOC, and 8-OHdG**

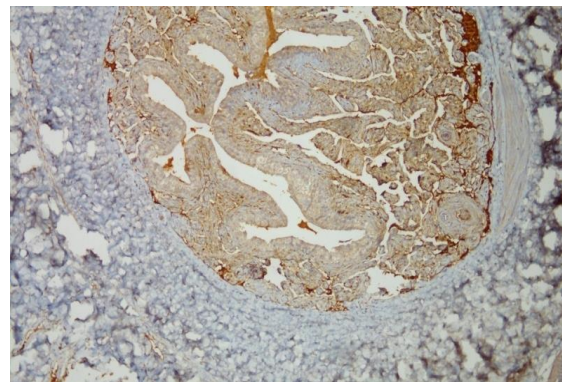
The results of all groups were shown in Table 2. There were no significant differences between the 1-week groups with respect to serum and urine TAC, TOC, and 8-OHdG levels (*P*>0.05), except U8-OHdG between OT1 and IUT1 groups (*P*=0,005) (Table 3). The comparison of 3-week groups revealed significant differences between C3 and IUT3, OT3 and IUT3 groups with respect to serum TAC level (*P*=0.013; *P*=0.001). Serum TOC levels were significantly different between C3 and IUT3, OT3 and IUT3 groups (*P*=0.024; *P*=0.019; *P*=0.000). Serum 8-OHdG levels also significantly differed between C3 and OT3 groups (*P*=0.033). In 3-week groups, on the other hand, urine TAC, TOC, and 8-OHdG levels showed no significant differences between the groups (*P*>0.05) (Table 4).

**Histopathological examination**

Histopathological examinations with H&E (Figure 1) evaluated urethral epithelial thickness (CUE), urethral lumen thickness (ULN), spongy tissue healing (HST), total urethral healing (TH), inflammation (INF), and hyperemia-bleeding (HB). The healing rates determined by the histopathological examination were presented in Table 5. The comparison of 1-week groups revealed that urethral thicknesses were significantly different between C1 and S1, C1 and OT1, C1 and IUT1 (*P*=0.032; *P*=0.006; *P*=0.030). Hyperemia-bleeding parameters were significantly different between C1 and OT1, C1, and IUT1 groups (*P*=0.002; *P*=0.006) (Table 3). In the comparisons



**Figure 1.** Light microscopy of urethra tissue from rats (HE stained urethra section, 100 x)

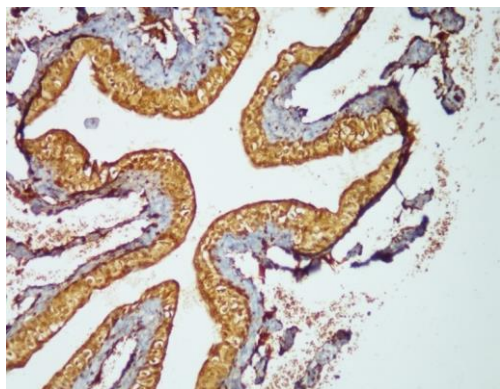


**Figure 2.** Immunohistochemical stained by tumour necrosis factor α of urethra tissue, 100 x

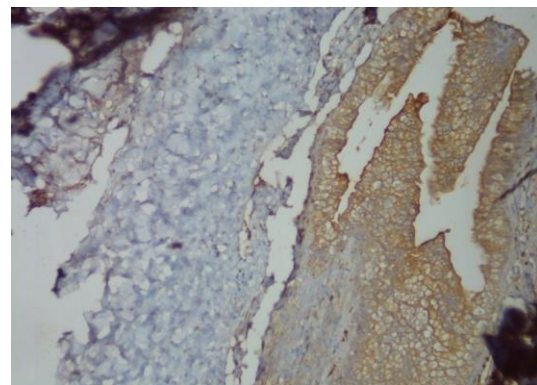


**Table 2.** Urine and serum TAS, TOS, and 8-OHdG: mean and SD

	C1 (n=5)	C3 (n=5)	S1(n=5)	S3 (n=5)	OT1 (n=8)	OT3(n=8)	IUT1 (n=8)	IUT3 (n=8)
Urine TAS	3,632±0,002	3,602±0,030	3,634±0,002	3,594±0,043	3,623±0,002	3,633±0,003	3,542±0,086	3,475±0,138
Urine TOS	38,63±3,627	2,294±0,462	6,412±2,393	9,673±8,771	54,47±17,05	33,99±22,54	4,797±3,184	22,13±13,78
Serum TAS	1,251±0,048	1,438±0,123	0,988±0,084	1,213±0,082	1,149±0,039	1,478±0,036	0,950±0,103	0,966±0,113
Serum TOS	9,894±0,817	43,08±14,68	12,32±2,513	28,75±9,846	12,15±1,472	62,05±6,626	23,21±6,167	10,48±1,782
Urine 8-OHdG	26,39±4,894	14,91±2,304	33,61±2,420	17,64±5,626	37,24±5,558	26,70±4,206	12,48±1,843	27,08±6,148
Serum 8-OHdG	0,542±0,030	0,494±0,053	0,621±0,095	0,531±0,080	0,618±0,030	0,720±0,030	0,725±0,027	0,965±0,026



**Figure 3.** Immunohistochemical stained by interleukin-1  $\alpha$  of urethra tissue, 200 x



**Figure 4.** Immunohistochemical stained by interleukin-1  $\beta$  of urethra tissue, 200 x

between the 3-week groups, the only significant differences were observed between C3 and S3, S3, and OT3, S3 and IUT3 with respect to spongy tissue healing ( $P=0.032$ ;  $P=0.045$ ;  $P=0.032$ ); and between C3 and S3, S3 and OT3 with respect to total urethral healing ( $P=0.019$ ;  $P=0.045$ ) (Table 4).

Immunohistochemical Examination: TNF, IL-1 $\alpha$ , and IL-1 $\beta$ : (Figures 2, 3, and 4): All immunohistochemical examination results were presented in

Table 6. The comparison of 1-week groups revealed significant differences between IL-1 $\beta$  staining of the groups C1 and OT1, C1 and IUT1, S1 and IUT1 ( $P=0.030$ ;  $P=0.003$ ;  $P=0.006$ ) while there were significant differences between the 3-week C3 and S3, C3 and OT3, C3 and IUT3 with respect to IL-1 $\beta$  level ( $P=0.008$ ;  $P=0.006$ ;  $P=0.011$ ) (Tables 3 and 4). The only significant 3-week difference was between IL-1 $\alpha$  staining of the groups S3 and OT3 ( $P=0.045$ ).

**Table 3.** Comparison of all parameters among 1 week-groups: <sup>a</sup>Nonparametric Mann Whitney U-Test, <sup>b</sup>One Way ANOVA Multiple comparison and post hoc Tukey HSD test, \* $P<0.05$ ; significant, NA:  $P>0.05$ ; insignificant

1 Week	STAC <sup>b</sup>	STOC <sup>b</sup>	S8-OHdG <sup>b</sup>	UTAC <sup>b</sup>	UTOC <sup>b</sup>	U8-OHdG <sup>b</sup>	CUE <sup>a</sup>	ULN <sup>a</sup>	HST <sup>a</sup>	TH <sup>a</sup>	INF <sup>a</sup>	HB <sup>a</sup>	IL-1 $\alpha$ <sup>a</sup>	IL-1 $\beta$ <sup>a</sup>	INF <sup>a</sup>
C1 - S1	NA	NA	NA	NA	NA	NA	NA	0,032*	NA	NA	NA	NA	NA	Na	NA
C1 - OT1	NA	NA	NA	NA	NA	NA	NA	0,006*	NA	NA	NA	0,002*	NA	0,030*	NA
C1 - IUT1	NA	NA	NA	NA	NA	NA	NA	0,030*	NA	NA	NA	0,006*	NA	0,003*	NA
S1 - OT1	NA	NA	NA	NA	NA	NA	NA	NA	NA	NA	NA	NA	NA	NA	NA
S1 - IUT1	NA	NA	NA	NA	NA	NA	NA	NA	NA	NA	NA	NA	NA	0,006*	NA
OT1 - IUT1	NA	NA	NA	NA	NA	0,005*	NA	NA	NA	NA	NA	NA	NA	NA	NA

TAC: total antioxidant capacity; TOC: total oxidant capacity; S8-HdG: 8-hydroxy-deoxy-guanosine; ULN: urethral lumen thickness; HST: spongy tissue healing; TH: total urethral healing; INF: inflammation

**Table 4.** Comparison to all parameters among 3 week-groups: <sup>a</sup>Nonparametric Mann Whitney U-Test, <sup>b</sup>One Way ANOVA Multiple comparison and post hoc Tukey HSD Test, \* $P<0.05$ ; significant, NA:  $P>0.05$ ; insignificant

3 Weeks	STAC <sup>b</sup>	STOC <sup>b</sup>	S8-OHdG <sup>b</sup>	UTAC <sup>b</sup>	UTOC <sup>b</sup>	U8-OHdG <sup>b</sup>	CUE <sup>a</sup>	ULN <sup>a</sup>	HST <sup>a</sup>	TH <sup>a</sup>	INF <sup>a</sup>	HB <sup>a</sup>	IL-1 $\alpha$ <sup>a</sup>	IL-1 $\beta$ <sup>a</sup>	TNF <sup>a</sup>
C3 - S3	NA	NA	NA	NA	NA	NA	NA	NA	0,032*	0,019*	NA	NA	NA	0,008*	NA
C3 - OT3	NA	NA	0,033*	NA	NA	NA	NA	NA	NA	NA	NA	NA	NA	0,006*	NA
C3 - IUT3	0,013*	0,024*	NA	NA	NA	NA	NA	NA	NA	NA	NA	NA	NA	0,011*	NA
S3 - OT3	NA	0,019*	NA	NA	NA	NA	NA	NA	0,045*	0,045*	NA	NA	0,045*	NA	NA
S3 - IUT3	NA	NA	NA	NA	NA	NA	NA	NA	0,032*	NA	NA	NA	NA	NA	NA
OT3 - IUT3	0,001*	0,000*	NA	NA	NA	NA	NA	NA	NA	NA	NA	NA	NA	NA	NA

TOC: total oxidant capacity; S8-HdG: 8-hydroxy-deoxy-guanosine; ULN: urethral lumen thickness; HST: spongy tissue healing; TH: total urethral healing; INF: inflammation

**Table 5.** Histopathological feature (Hematoxyline & Eosin)

Histopathological Feature	C1 (n=5)	C3 (n=5)	S1 (n=5)	S3 (n=5)	OT1 (n=8)	OT3 (n=8)	IUT1 (n=8)	IUT3 (n=8)
Coverage of urethral epithelium								
Complete	5	5	2	2	6 (%75)	7 (%87,5)	3 (%37,5)	6 (%75)
Incomplete	0	0	3	3	2	1	5	2
Urethral lumen narrowing								
Presence	5	2	1	1	1	4 (%50)	2 (%25)	2
Absence	0	3 (%60)	4 (%80)	4 (%80)	7 (%87,5)	4 (%50)	6 (%75)	6 (%75)
Healing of spongioz tissue								
Complete	5	5	3	1	7 (%87,5)	7 (%87,5)	3 (%37,5)	5(%62,5)
Incomplete	0	0	2	4	1	1	5	3
Inflammation								
Present	2	0	3	1	3	0	4	4
Absent	3	5	2	4	5	8 (%100)	4	4
Total healing								
Present	5	5	2	1	7 (%87,5)	7 (%87,5)	3 (%37,5)	4 (%50)
Absent	0	0	3	4	3	3	7	4
Hyperemia-Bleeding								
Present	0	5	2	3	7 (%87,5)	6 (%75)	7 (%87,5)	3(%37,5)
Absent	5	0	3	2	3	2	3	7

IUT1: intraurethral TMZ

**Table 6.** Results of evaluation immunohistochemistry

Immunohistochemistry	C1 (n=5)	C3 (n=5)	S1 (n=5)	S3 (n=5)	OT1 (n=5)	OT3 (n=8)	IUT1 (n=8)	IUT3 (n=8)
IL-1 $\alpha$								
0	%20	3	2	%80	%62,5	%17,5	%37,5	%37,5
1	%40	2	3	%20	%37,5	%87,5	%62,5	%62,5
2	%40	0	0	0	0	0	0	1
3	0	0	0	0	0	0	0	0
IL-1 $\beta$								
0	0	0	0	2	2	1	6 (%75)	1
1	1	0	2	3	4 (%50)	5 (%62,5)	2	4 (%50)
2	1	2	3	0	2	2	0	3
3	3 (%60)	3 (%60)	0	0	0	0	0	0
TNF								
0	0	0	0	2	2	4 (%50)	1	1
1	5 (%100)	3 (%60)	2	3	4 (%50)	2	7 (%87,5)	7 (%87,5)
2	0	2	2	0	2	2	0	0
3	0	0	1	0	0	0	0	0

IUT1: intraurethral TMZ

Urethral injury leads to formation of scar tissue, resulting in narrowing of urethral lumen and formation of strictures, causing a decrease in urinary flow. Current treatment regimens aim at treating urethral narrowing rather than preventing it.

However, in fact, treatment should primarily focus on preventing scar tissue formation. Urethral healing takes place in four phases namely inflammation, proliferation, maturation, and remodeling, similar to dermal healing (11). The simplest way to achieve this goal would be with oral and intraurethral agents. There are ongoing research efforts aiming to reduce scar tissue formation and hasten urethral healing (2). There is a constant

search for locally administered, simpler treatments for urethral strictures.

Many chemicals and medications have been studied for the treatment of urethral injuries so far. Substances such as transurethral triamcinolone, honey, Uttarbasti, and hydrocortisone-furacin combination have been used clinically while TGF-Beta oligodeoxynucleotide, halofuginone, recombinant viral solutions carrying reporter genes, and mitomycin C have been used in experimental studies (1, 2, 12, 13).

TMZ is a medication with anti-ischemic and antioxidant properties which prevents intracellular acidosis. It is used as a cardioprotective agent against

cardiac ischemia (5). However, no study to date has specifically examined the role of TMZ in wound healing and urethral injuries. Herein, we explored both short- and long-term efficacy of TMZ in urethral wound repair, both locally and generally. All chemical mediators contributing to healing during wound repair were studied in tissue, serum, and urine.

During the healing period after injury, ischemia should be alleviated, blood flow augmented, and neoangiogenesis maintained. At the healing period, cellular reactions and level of substances released by cells should be maintained in a fine balance, which plays an important role in the healing process. Promoting blood flow to wound site promotes early healing. In addition, a well maintained balance of ROS formed after injury is also important for wound healing, as well as adjacent tissue and distant organ injury. During ischemia-reperfusion injury in an organ, ROS such as superoxide anions, hydroxyl radicals, and hydrogen peroxidases are formed, which may enhance leukocyte activation, cause the release of endothelial adhesion molecules, and lead to a systemic increase in inflammatory mediators with a resultant endothelial injury in distant organs (5, 14). Increased ROS levels may also lead to pulmonary, hepatic, myocardial, or renal injury (5). TMZ provides protection against I-R injury in various tissues. It protects against ionic imbalance and also spares ATP levels (15), cellular membrane, and endothelial integrity (7). Sucu *et al* evaluated the effect of TMZ after experimentally designed renal I-R injury (5). They observed a reduction in MPO and MDA levels in the I-R group. In histopathological examination, they observed loss of Bowman area, increased glomerular congestion, and periglomerular and peritubular bleeding. They also found reduced periglomerular and perivascular leukocyte infiltration compared to the control group (5). Our study also demonstrated persistent hyperemia and bleeding in groups that were administered oral and intraurethral TMZ for 1 week although that effect vanished in the third week. In our study, TMZ, an antiischemic agent, contributed to vascularization at the end of one week.

It is already known that neutrophils emerging after trauma and I-R injury produce ROS and MPO as a result of oxidative stress. Leukocytes spreading in ischemic tissue re-enter systemic circulation after the establishment of reperfusion. These activated neutrophils act as mediators of I-R induced distant organ injury (16). In I-R injury, erythrocytes are affected by increased oxidative stress due to a reduction in their Na-K ATPase activity. These data suggest that a distant I-R injury augments circulatory oxidative state. Leukocytes have an important role in the emergence of distant organ injury. Such a prominent oxidative state results in an imbalance in

the distribution of endothelial cells, leading to increased vascular permeability and kidney hemorrhage. It is unknown whether such events predominantly studied in ischemia-reperfusion injury also occur after urethral injury. However, it has been theorized that reactions similar to those in I-R injury may also occur due to increased oxidative stress after traumatic injury. Future studies should address under which circumstances oxidative stress would emerge after urethral injuries. TMZ may influence urethral healing by its antioxidant and anti-ischemic properties. Our study investigated serum and urine total antioxidant and oxidant levels at the first and third week of wound repair after urethral injury. These are the proliferative and maturation stages, respectively, of wound repair. DNA injury was also studied. Histopathological and immune staining techniques were used to study IL-1 $\alpha$  and  $\beta$ , and TNF, which take part in wound repair. Oxidative stress and wound repair factors after urethral injury were studied for the first time, and thus this study is the first of its kind in the literature.

Urethra's histopathological evaluation indicated that oral and urethral TMZ use prevents narrowing of the urethral lumen. That efficacy continued in the third week despite having been slightly reduced. While significant healing didn't occur in spongy tissue in oral and intraurethral TMZ groups at the end of the first, TMZ's effect was higher than desired at the end of three weeks. This may have been due to higher blood supply to spongy tissue than epithelial tissue. TMZ has not effect on inflammation. Hyperemia-bleeding was at maximum in the 1-week oral and intraurethral TMZ. Normally expected to favorably affect wound repair, oxidative stress may sometimes lead to serious injury at local and systemic levels as a result of its excessive functions (4). In the present study, we investigated the impact of oxidative stress and the outcomes of treatment after urethral injury. No study to date has studied urine TAC and TOC levels. In our study, urine TAC and TOC levels were studied after urethral injury because the urethra is a urinary tract organ that is naturally in contacts with urine. No change was found in TAC and TOC levels between the groups. While serum TAC and TOC levels did not change in the 1-week group, the 3-week intraurethral TMZ group exhibited a significant reduction compared to the control group. Serum TOC level was significantly higher in 3-week oral TMZ group than in the control groups. Although urine TOC level was normal in the 1-week intraurethral TMZ group, it was higher in 3-week intraurethral TMZ group, which was an interesting finding.

Antioxidants are known to have an ability to prevent harmful reactions: they contribute to wound repair. As TMZ is also an antioxidant agent, it appears theoretically inevitable that it would also

contribute to urethral healing. Studies addressing the effects of oral and intraurethral TMZ on TAC, TOC, histopathological urethral healing, and inflammatory substances would be invaluable for the treatment of urethral injuries, as would those reproducing the favorable results obtained at experimental setting in human studies. Urine TAC levels were higher than serum TAC levels. In the control and 3-week oral groups, serum TAC levels were higher than in the other groups. When oral TMZ was used, TAC level increased by 3 weeks, although it may, in fact, be increasing spontaneously after injuries since it also increased in control studies not using any drugs. Serum TAC levels were higher for C3 and OT3. Serum TOC levels were higher in the 3-week control group, in the sham group although to a lesser degree than the control group, in the 3-week oral TMZ group, and in the 1-week intraurethral TMZ group although to a lesser degree than the former groups. In the 1-week and 3-week intraurethral TMZ groups, serum TAC levels were significantly lower. Intraurethrally administration of TMZ does not augment total antioxidant level. It may act through EPCs (17). Serum TAC levels increase during long-term spontaneous wound repair. This suggests that rats spontaneously increase their TAC against their own ROS products. With oral TMZ use, on the other hand, no difference from the control group was observed. We did not find any previous study that specifically investigated the effects of TMZ on wound repair. All studies so far have been conducted on ischemia and/or reperfusion. This stems from the classical knowledge that TMZ has anti-ischemic and antioxidant properties. We, on the other hand, suggest that it exerted its actions over EPCs released into circulation as a result of inflammation during injury and wound repair (17).

Oxidative stress causes lipid oxidation, protein oxidation, and DNA injury (17). 8-OHdG, a marker of DNA injury, was high in all groups despite inter-group differences in urine samples. In serum, on the other hand, the levels were normal. Since urethra is an organ directly in contact with urine, a marker of DNA injury being increased only in urine samples appears normal. The U8-OHdG level in OT3 was higher than in the other groups. We could not understand why it is limited to just this group. It requires further investigation.

Interleukin-1 is an acute phase protein synthesized by antigen presenting cells. It activates cyclooxygenase, phospholipase A2, and iNOS. It has an important role in wound healing (4). In the present study, the immunohistochemical analysis demonstrated an unchanged tissue IL- $\alpha$  and TNF scoring with both routes of administration of TMZ. When TMZ is orally administered, ILs released by monocytes, macrophages, endothelial cells, and T lymphocytes were detected in high quantities (17,

18). However, the low level of staining in the 1-week urethral group is noteworthy. In the 3-week urethral group, on the other hand, 50% staining was present. We know that cells exposed to IL produce PGE2 and NO in high quantities (18). It has been observed that TMZ caused NO increase over EPCs, and it also increased EPCs' migration and adhesion (17). The effect of TMZ in urethral injuries may also occur by the same mechanism. However, while IL-1  $\beta$  being +++ in the majority of cases in the control group suggests such increases at wound site after injury, these scores were + and - in the TMZ group. A lowering impact of TMZ on IL-1 beta levels was observed in wound repair.

In TNF staining, on the other hand, there was + staining in nearly all subjects in both the 1-week and 3-week intraurethral groups. As expected, there was TNF positivity after urethral trauma in the control group. TNF is a strong chemotactic mediator. It has strong local effects; fibroblasts and endothelial cells have important biological functions in TNF-mediated wound repair (4). In contrast, our study suggested that the effect of TMZ on wound repair does not occur through TNF. Researchers evaluated urethra healing after urethroplasty in rats. They investigated neutrophils, macrophages, VEGF, TNF- $\alpha$ , TNF- $\beta$ , PDGF, and IL-10 on the urethral tissue. Increases in all parameters and remodeling on the rat urethra on the twelfth day were observed (19).

## Conclusion

It was observed that TMZ did not increase total antioxidant levels in urine but conversely increased urinary total oxidant level; while increasing serum TAC levels long-term. It also reduced serum TAC levels in urethral use and increased serum TOC levels. No effect was detected on IL-1 $\alpha$  and TNF, but a partially reducing effect on IL-1 $\beta$  levels. Further experimental and human studies are needed to clarify this issue.

## Acknowledgment

This study was funded by Ordu University (project no: AR-1367).

## Conflict of interest

The authors declare no conflict of interest.

## References

1. Ayyıldız A, Akgül K.T, Cebeci Ö, Nuhoglu B, Caydere M, Ustün H, *et al.* Intraurethral honey application for urethral injury: an experimental study. *Int Urol Nephrol* 2007; 39: 815-821.
2. Ayyıldız A, Nuhoglu B, Gülerkaya B, Caydere M, Ustün H, Germiyanoglu C, *et al.* Effect of intraurethral Mitomycin-C on healing and fibrosis in rats with experimentally induced urethral stricture. *Int J Urol* 2004; 11: 1122-1126.

3. Parihar A, Parihar MS, Milner S, Bhat S. Oxidative stress and anti-oxidative mobilization in burn injury. *Burns* 2008; 34: 6-17.
4. Aksoy H, Özakpınar ÖB. Yara iyileşmesi ve oksidatif stres. *Marmara Pharm J* 2014; 18: 153-158.
5. Sucu S, Unlu A, Tamer L, Aytacoğlu B, Coskun B, Bilgin R, *et al.* Effects of trimetazidine on tissue damage in kidney after hindlimb ischemia-reperfusion. *Pharmacol Res* 2002; 46:345-349.
6. Harpey C, Clauser P, Labrid C, Freyria JL, Poirier JP. Trimetazidine, a cellular anti-ischemic agent. *Cardiovasc Drug Rev* 1988; 6:292-312.
7. Hauet Th, Bauza G, Goujon M, Caritez JC, Carretier M, Eugene M, *et al.* Effects of trimetazidine on lipid peroxidation and phosphorous metabolites during cold storage and reperfusion of isolated perfused rat kidney. *Pharmacol Exp Ther* 1998; 285:1061-1067.
8. Williams FM, Tanda K, Kus M, Williams TJ. Trimetazidine inhibits neutrophil accumulation after myocardial ischemia and reperfusion in rabbits. *J Cardiovasc Pharmacol* 1993; 22:828-833.
9. Erel O. A novel automated method to measure total antioxidant response against potent free radical reactions. *Clin Biochem* 2004; 37:112-119.
10. Erel O. A new automated colorimetric method for measuring total oxidant status. *Clin Biochem* 2005; 38:1103-1111.
11. Ninan N, Thomas S, Grohens Y. Wound healing in urology. *Adv Drug Deliv Rev* 2015; 82-83:93-105.
12. Kumar S, Wong PF, Leaper DJ. What is new wound healing? *Turk J Med Sci* 2004; 34:147-160.
13. Yalcinkaya FR, Davarci M, Gokce A, Güven EO, İnci M, Kerem M, *et al.* Intraurethral uterbasti application for urethral injury in rats. *J Anim Vet Adv* 2002; 11:1494-1497.
14. Carden DL, Granger DN. Pathophysiology of ischemia-reperfusion injury. *J Pathol* 2000; 190:255-266.
15. Cross HR. Trimetazidine: a novel protective role via maintenance of Na<sup>+</sup>-K<sup>+</sup> ATPase activity? *Cardiovasc Res* 2000; 47:637-639.
16. Granger DN. Role of xanthine oxidase and granulocytes in ischemia-reperfusion injury. *Am J Physiol* 1988; 255:1269-1275.
17. Wu Q, Qi B, Liu Y. Mechanisms underlying protective effects of trimetazidine on endothelial progenitor cells biological functions against H<sub>2</sub>O<sub>2</sub>-induced injury: involvement of antioxidation and Akt/eNOS signaling pathways. *Eur J Pharmacol* 2013; 707:87-94.
18. Kuralay F, Çavdar Z. İnflamatuvar medyatörlere toplu bakış. *Genel Tıp Derg* 2006; 16:143-152.
19. Hofer MD, Cheng EY, Bury MI, Park E, Xu W, Hong SJ, *et al.* Analysis of primary urethral wound healing in the rat. *Urology* 2014; 84:246. e241-e247