

The effect of *Quercus brantii* gall extract on burn wound healing in rat

Faraidoon Haghdoost^{1, 2}, Mohammad Mehdi Baradaran Mahdavi¹, Behzad Zolfaghari³, Mohammad Hossein Sanei⁴, Somaye Najafi², Alireza Zandifar^{1, 2}, Navid Manouchehri¹, Shaghayegh Haghjooy Javanmard^{2*}

¹ Medical Students' Research Center, Isfahan University of Medical Sciences, Isfahan, Iran

² Physiology Research Center, Department of Physiology, Isfahan University of Medical Sciences, Isfahan, Iran

³ Department of Pharmacognosy and Isfahan Pharmaceutical Sciences Research Center, School of Pharmacy, Isfahan University of Medical Sciences, HezarJarib Ave, Isfahan, Iran

⁴ Department of Pathology, Isfahan University of Medical Sciences, Isfahan, Iran

ARTICLE INFO

Article type:

Short communication

Article history:

Received: Aug 28, 2015

Accepted: Jun 30, 2016

Keywords:

Burn wound healing

Gall extract

Quercus Brantii

ABSTRACT

Objective(s): The aim of the present study was to evaluate the effect of *Quercus brantii* galls extract on the rat skin burn wound healing.

Materials and Methods: Ethanol extract of the galls of *Q. brantii* was used to treat the induced burn wounds on the back of 32 Wistar rats divided into 4 groups. The groups were treated by placebo, 1%, 2% and 4% concentration gall extract gels for 14 days and the efficacy of treatment was assessed based on reduction of burn wound area, as well as histological and molecular characteristics.

Results: The mean wound surface in the 14th day, in all groups treated by *Q. brantii* gall extracts were larger than control group and the differences were statistically significant ($P=0.043$). The mean histological wound healing scores were not statistically different. Analysis of nitric oxide and platelet derived growth factor concentration in wound fluids in the 5th day of study showed that there was not any significant difference between groups ($P=0.468$ and 0.312 respectively). Fibroblast growth factor (bFGF) concentration in the wound fluids, was significantly higher in group treated with 1% gall extract gel in comparison to the control group ($P=0.026$).

Conclusion: Our results could not prove the significant positive effect of *Q. brantii* galls extract on the burning wound healing. More studies with more groups treated with different doses of the *Q. brantii* extract are recommended.

► Please cite this article as:

Haghdoost F, Baradaran Mahdavi MM, Zolfaghari B, Sanei MH, Najafi S, Zandifar AR, Manouchehri N, Haghjooy Javanmard Sh. The effect of *Quercus brantii* Gall extract on burn wound healing in rat. Iran J Basic Med Sci 2016; 19:1144-1150.

Introduction

Burn wounds remain a major health problem affecting communities worldwide (1). The ultimate aim of burn management and treatment is rapid wound healing and epithelialization in order to prevent infection and minimize functional and aesthetic complications (2).

Wound healing is a complex dynamic process. It starts with inflammation that dominates early phase giving way to granulation tissue formation and scar remodeling (3). These events of wound healing are classically divided to several phases: inflammation, proliferation and remodeling (4, 5). The inflammation phase starts immediately after injury and is characterized by release of cytokines and growth factors, influx of neutrophils and macrophages in the wound area and creation of a preliminary matrix (6). The proliferation phase is characterized by re-

epithelialization and granulation tissue formation. Re-epithelialization begins shortly after injury. Epidermal cells at the margin of the wound begin to proliferate within 1 to 2 days after injury. On the 4th day after injury, granulation tissue invades the wound gap and numerous new capillaries grow through new stroma (7, 8). The final phase is skin remodeling. During this phase, collagen is deposited by fibroblasts and forms an organized network to increase wound tensile strength (9).

The complex process of wound healing is regulated by a complex network of chemokines and growth factors such as fibroblast growth factor (FGF) family and platelet derived growth factor (PDGF) (10). Fibroblast growth factor (FGF) is one of the largest families of growth and differentiation factor for mesenchymal and neuroectodermal cells. FGF2 (bFGF) is a member of this family that induces DNA synthesis,

*Corresponding author: Shaghayegh Haghjooy Javanmard. Physiology Research Center, Department of Physiology, Isfahan University of Medical Sciences, Isfahan, Iran. Tel: +98-311-7922414; Fax: +98-311-7922295; email: sh_haghjooy@med.mui.ac.ir

angiogenesis, ECM synthesis and down-regulation of type one collagen synthesis (11, 12). PDGF is released from platelets, endothelium and macrophages. PDGF acts as a potent mitogen for all mesenchymal cells and a chemoattractant for inflammatory cells and fibroblasts. It also stimulates synthesis of fibronectin, glycosaminoglycan and collagenase (12-15).

Another key role player in wound healing process is Nitric oxide (NO) which is an important intercellular signaling molecule. (16, 17) During phagocytosis, in inflammatory phase, there is a dramatic increase in leukocyte oxygen consumption. Some of this oxygen is converted to reactive oxygen species (ROS) such as superoxide ions. ROS is essential for oxidative killing, but excessive production of ROS can result in tissue injury via cellular protein and DNA damage (18, 19). NO has scavenging activity for superoxide as the main component of oxidative stress (20). On the other hand NO has beneficial effects on angiogenesis, inflammation, cell proliferation, matrix deposition and remodeling (17).

Findings from many studies indicate that appropriate treatment and wound care accelerates healing process and prevents infection. Different synthetic drugs are available for enhancing wound healing in modern medicine. Moreover, herbal medicines are crucial in wound healing since they initiate disinfection, debridement and provide a moist area for natural healing process (21).

The oaks (genus *Quercus*) are one of the most important groups of flowering plants that dominate large regions of northern hemisphere. There are more than 200 species of oak in western hemisphere, and probably larger number in Asia and relatively few in Europe (22). The oak plant is a major genus in northern and central parts of Iran (23). The main importance of oak tree is the presence of tannins in their different parts. According to the references and local information, *Quercus* species can be used in wound treatment due to different properties of tannins available in them (24). *Quercus brantii* widely grows in Iran and decocted extract from its fruits is traditionally used to treat inflammation, diarrhea, cut and burns (23). The gall extracts of this plant is traditionally used on inflamed skin and skin burn in Kurdistan but there is few information about the underlying mechanism. The aim of this study was to examine wound healing potential of *Q. brantii* gall extracts using various wound healing parameters in burned rats.

Materials and Methods

Plant collection and *Q. brantii* gall extract preparation

The galls of *Q. brantii* were collected from Zagross Mountains in Kurdistan province in October 2010. These plants were authenticated in Herbarium Department of Biology, Faculty of Sciences, University of Isfahan, Isfahan, Iran. The powder of the galls of *Q.*

brantii were extracted with absolute 75% hydroalcoholic solution and extract was evaporated to dryness on a rotary evaporator and freeze dryer respectively. Total phenolic contents of *Q. brantii* gall extract were estimated according to the method described by Singleton *et al*, Twenty microliters of the 0.85% extract was added to 1.58 mL water, and then 100 µl of the Folin-Ciocalteu reagent was added, and mixed. After 30 sec, 300 µl of 20% Na₂CO₃ was added and thoroughly mixed and reminded in 20 °C for 2 hr. Absorbance was measured at 765 nm. Standard curve of absorbance was created versus concentration of gallic acid (50-500 µg) and total phenolic contents were reported as percentage equivalents to gallic acid (25). Xantan gum 1% was used to prepare aqueous gel as vehicle. Xantan gum was added to warm water under stirring slowly and the gall extract was added consequently to obtain homogenized gel. This gel was cooled and packed in the tubes and stored in the refrigerator till use (4 °C).

Animals and experimental protocol

Female Wistar rats weighing 250±20 g at the time burns were inflicted, from Razi Institute of Iran, were housed in the animal unit (12-hr light/dark cycle, temperature approximately 23 °C) at least two week prior to the experiments. The rats were housed in individual cages with free access to water and food pellets. 32 rats were randomly divided into four groups of 8. Each rat got a number to perform the blindness of analyzers. After creating burn wounds, each group was dressed by a different extract dose of *Quercus* galls for 14 days. At the day 14th the animals were sacrificed and the wounds were separated to determine the healing grade by microscopic evaluation.

Skin burn injury induction

The rats were anesthetized with intra peritoneal injection of ketamine (50 mg/kg) and xylazine (5 mg/kg). Animals` back were shaved and burn injury was induced by applying an aluminum plaque (1.5 * 1.5 cm) which was heated to 100 degree centigrade in a dry oven, on the skin of the rats for 10 sec to create a deep dermal burn wound. All the procedures were performed by the same person to minimize the bias of differences in the force of application. The reliability of this method in the production of full thickness burns has previously been validated by Koizumi *et al* (26).

Treatment

The animals were divided into four groups. From the first day, wounds were dressed daily by 20 mg of the *Quercus* prepared gel for each group. Group one (G1) was the control group in which the burn wounds were treated by Xantan gum 1% water gel without any extract. Group 2 (G2), Group 3 (G3) and Group 4 (G4) had daily application of 1%, 2% and 4% prepared water gels of the *Quercus* gall extract, respectively.

Wound area and closure assessment

To assess the wound surface, burn wounds were photographed after creating wound (first day) and at the day 14, by the same instrument (Canon IXUS 200 IS Digital Camera) and settings, fixed distance of camera from the wound and the same position of rats. Then the photos were analyzed by MATLAB R2009 a software. Data from MATLAB software were pixels of wound image per pixels of one cm². Differences between the wound size at the first day and also 14th between groups were compared between groups. Also wound closure ($=100 - [(wound\ size\ on\ 14^{th}\ day / wound\ size\ on\ 1^{st}\ day) * 100]$) was assessed (27).

Histological evaluation

After the 14th day all the rats were scarified and the wounds were separated. All wound tissue specimens were fixed in 10% neutral-buffered formalin for at least 24 hr at room temperature. After fixation, vertical sections to the anterior-posterior axis of the wound were dehydrated in graded ethanol, cleared in xylene, and embedded in paraffin. Four-micron-thick sections were mounted on glass slides, dewaxed, rehydrated to distilled water, and stained with hematoxylin and eosin. For histological evaluation, all slides were examined by two pathologists, without knowledge of the prior treatment, under a microscope from × 20 to × 100 magnifications. The histological score adopted in this study was performed according to the previous study concerning wound healing in experimental models. The criteria used as histological scores of wound healing are summarized in Table 1 (28).

Determination of bFGF, PDGF and NO concentration in wounds fluids

Three samples of wound fluid were collected using sterile nitrate-free absorbent paper strips placed on the edges of the wound for 10 min, in order to measure bFGF, PDGF and NO on the 5th day of the study.

Table 1. Criteria to evaluate histological scores of wound healing

Score	Criteria
1-3	None to minimal cell accumulation. No granulation tissue or epithelial travel.
4-6	Thin, immature granulation that is dominated by inflammatory cells but has few fibroblasts, capillaries or collagen deposition. Minimal epithelial migration.
7-9	Moderately thick granulation tissue, can range from being dominated by inflammatory cells to more fibroblasts and collagen deposition. Extensive neovascularization. Epithelium can range from minimal to moderate migration.
9-12	Thick, vascular granulation tissue dominated by fibroblasts and extensive collagen deposition. Epithelium partially to completely covering the wound.

This method for the measurement has been validated for other sample types (29-31). For bFGF

and PDGF measurement, protein elution from the Shirmer strips was performed by stirring the strips in 0.5 ml of buffer (50 mMTris, 50 mMNaCl, 0.05% Brij 35, pH 7.6) for at least 2h at+4 °C. For wound fluid NO determinations, filter paper was placed in 0.5 ml of distilled water (32). The amount of bFGF and PDGF in wounds fluid was measured using enzyme-linked immunosorbent assay using available reagents and recombinant standards (R&D Systems, Minneapolis, MN) according to manufacturer’s instruction on 5th day samples. The total NO level of wound fluid was measured using the Griess assay after conversion of NO₃ to NO₂ with the NO₃ reductase enzyme as described previously (33, 34).

Statistical analysis

All data are expressed as the mean ± the standard deviation (mean± SD). A statistical software package, SPSS (version 16), was used to perform statistical analysis. The data was tested for normality and homogeneity of variance. Data was analyzed by analysis of variance (ANOVA), followed by a *post hoc* multiple comparison. For the histological results, statistical analysis was performed using Kruskal-Wallis test. Statistical significance was accepted at *P*<0.05.

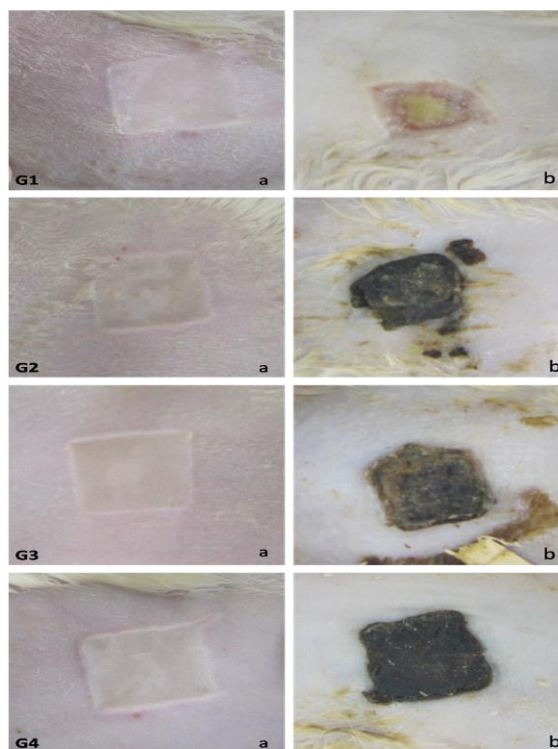


Figure 1. Macroscopic morphology of skin burn wound in the first day of the study created by 10-sec application of 1.5 * 1.5 aluminum plaque which was heated to 100 degree centigrade (a). Macroscopic morphology of the wounds after 14-day treatment by Quercus Brantii gall extract (b). G1: control group/ G2: Group treated with 1% concentration extract/ G3: Group treated with 2% concentration extract/ G4: Group treated with 4% concentration extract

Table 2. Burning wound surface at the first and 14th day and wound closure

Group	Wound surface		†Wound closure
	First day	14 th day	
	Mean±SD (n)	Mean±SD (n)	Mean±SD (n)
G1	2.36± 0.18 (8)	1.37± 0.41 (8)	41.98±5.63 (8)
G2	2.50± 0.22 (8)	1.97± 0.46 (8)	21.23±6.05 (8)
G3	2.47± 0.18 (8)	2.03± 0.61 (7)	16.81±10.14 (7)
G4	2.35± 0.23 (8)	*2.09± 0.38 (5)	*8.68±8.40 (5)
^P-value	0.383	0.043	0.031

G1: Control group/ **G2:** Group treated with 1% concentration gall extract/ **G3:** Group treated with 2% concentration gall extract/ **G4:** Group treated with 4% concentration gall extract/Each value is mean±standard deviation/ n: number of animals/ † Data are given as percentages/ ^By comparison of all groups (ANOVA test)/ *Shows P-value<0.05 for comparison with the control group/ Because of sample missing (animal death and unsatisfactory biopsies) the number of samples are different in groups in 14th day

Results

The total phenolic content of the gall extract was estimated as 87% gallic acid equivalent. Burn wounds were induced in the first day and all animal’s wounds were photographed in both first and 14th day of study (Figure 1). As seen in Table 2, the mean of wound surface didn’t have any significant difference in first day in control group in comparison with other groups (treated with 1, 2 and 4% concentration gall extract gel). Wound area was significantly different between treatment groups and control groups on the day 14 of the study (P<0.05). Analysis of wound closure is also reported in the table 2. Difference between groups was statistically significant (P=0.031 by ANOVA test).

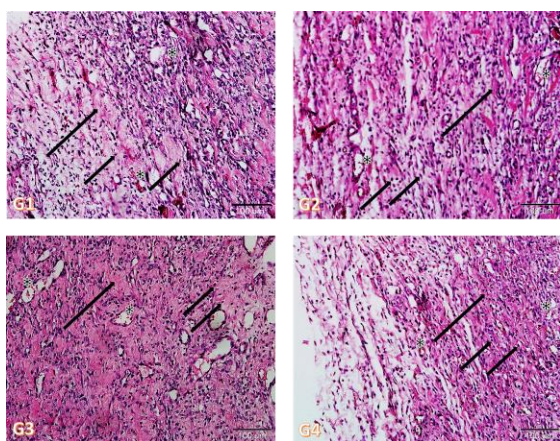


Figure 2. Histopathology of burn wounds at 14th day of the study. Stained with H&E (200x). G1: control group/ G2: Group treated with 1% concentration gall extract/ G3: Group treated with 2% concentration gall extract/ G4: Group treated with 4% concentration gall extract/ Asterisks show capillaries. Small arrows show fibroblasts. Long arrows show granulation

Comparison of G1 with the other three groups (G2, G3 and G4) showed P= 0.190, 0.098 and 0.035 respectively. As described before, at 14th day, the wounds were removed for microscopic analysis. Figure 2 is Photomicrographs of wound histology in different groups after 14th day of the study. In the Figure the capillary sections, fibroblasts and granulation formation are marked. Each wound was given a score from 0 to 12 and a mean score was calculated for each group. Then the average wound healing scores of groups were compared.

As Table 3 Shows there was no significant difference between groups regarding the wound healing score determined by microscopic analysis of wounds (P= 0.256 by ANOVA test). Figure 2 is showing the histopathology of the wounds in different groups of the study after 14 days.

As shown in Table 4, at the 5th day, the average of NO concentration in the wound fluids in G1, G2, G3 and G4 was 3.20±0.97, 5.28±1.40, 4.98±0.90 and 4.33±0.62 respectively (P-value=0.468 by ANOVA test). The mean concentration of PDGF in wound fluids were 50.60± 0.16, 53.44±0.68, 51.84±0.39 and 52.69±0.90 for G1, G2, G3 and G4 respectively.

There was no significant difference between groups regarding this factor (P=0.312 by ANOVA test). The mean concentrations of bFGF in wound fluids in G1, G2, G3 and G4 were 50.60±0.16, 53.44±0.68, 51.84±0.39 and 52.69±0.90 respectively (P-value=0.026). In comparison of control group (G1) to other groups (G2, G3 and G4 respectively) the p-values were 0.020, 0.527 and 0.120 respectively.

Table 3. Wound healing at the 14th day

Group	Wound healing score	
	Mean±SE	†P-value
G1	3.28±0.28	
G2	3.0±0.4	0.988
G3	4.8± 1.2	0.299
G4	3.0± 0.3	0.988
^P-value	0.256	

G1: Control group/ **G2:** Group treated with 1% concentration gall extract/ **G3:** Group treated with 2% concentration gall extract/ **G4:** Group treated with 4% concentration gall extract/ Each value is mean±standard error (n = 8)/ ^By comparison of all groups (kruskal-Wallis test)/ †Post hoc analysis for comparison of control group with other groups

Table 4. Wound fluid concentration of different factors in 5th day of the study

Group	Factors		
	NO concentration (µmol/ml)	PDGF concentration (pg/ml)	bFGF concentration (pg/ml)
	Mean±SE (n)	Mean±SE (n)	Mean±SE (n)
G1	3.20± 0.97 (8)	18.64± 0.69 (6)	50.60± 0.16 (7)
G2	5.28± 1.40 (7)	22.29± 2.70 (8)	*53.44± 0.68 (8)
G3	4.98± 0.90 (8)	18.88± 2.07 (8)	51.84± 0.39 (8)
G4	4.33± 0.62 (8)	16.70± 2.01 (8)	52.69± 0.90 (8)
P-value	0.468	0.312	0.026

G1: Control group/ **G2:** Group treated with 1% concentration gall extract/ **G3:** Group treated with 2% concentration gall extract/ **G4:** Group treated with 4% concentration gall extract/ Each value is mean± standard error/*Shows P-value<0.05 for comparison with the control group/ Because of sample missing (unsatisfactory wound fluid samples) the number of samples are different in groups in 14th day

Discussion

Quercus species can be used in wound treatment due to different properties of tannins available in them (24). Tannins promote wound healing through scavenging of free radicals, promoting wound contraction, angiogenesis and fibroblast formation (35). Studies have shown that tannin molecules and polyphenols are able to decrease the mutagenic activity of some mutagens. Mutagens produce free radicals to interact with cellular functions. Antimutagenic effect of tannins might be due to their antioxidative properties (36). In Kurdistan of Iran the galls of *Q. brantii* is widely used for treatment of burn injuries in traditional medicine and is used as wound dressing. The aim of this study was to investigate the effect of *Q. brantii* gall extract on burning wound healing.

In our study, the wound surface analysis results showed that the mean wound surface in the 14th day, in

all groups which were treated by *Q. brantii* gall extracts were larger than control group. Different from our results, previous studies have reported that seed of *Q. Brantii* is associated with higher wound closure ratio (36). In our study gall were used and shorter period of treatment time was considered. According to the different studies, *Quercus* species have antibacterial effects and Infection can prevent the wound healing process (37, 38). But in our study groups treated with *Q. brantii* had larger wound surface after 14th day. We observed that groups treated by *Q. brantii* gall extract had a crust like formation on their wounds that made the wound surface assessment complicated. *Q. brantii* has anti-bacterial effects. But control group had a smaller wound surface and groups treated by *Q. brantii* had larger wound surface (lower rate of mound closure). There was no crust in the control group. Higher concentration of *Q. brantii* gall extract was associated with more crust formation. So analysis of the wound surface in *Q. brantii* treated groups was influenced by the crust formation and this can be a limitation of our study. More studies with larger sample sizes are necessary to make it possible to select some samples and remove the crust formation before wound surface analysis (wound area assessment without crust like formation). In study of Hemmati *et al* seeds were used and there was no similar crust like formation. We think this can be the reason for larger wound surface after 14th day and also making the real wound size assessments complicated. The crust could be used as a natural dressing to prevent dehydration and infection in the wound area. Pathology report of wound healing scores showed that the average scores of treatment groups were not significantly different and all groups almost got a score lower than 50% on our scoring system. A study is conducted by Hemmati *et al* on the wound healing effect of *Q. brantii* in rats. They have reported that the *Q. brantii* ointment is effective on wound healing in animal models and is associated with higher wound closure ratio. They have used the seed of *Q. brantii* and made ointment. The injuries in that study was full-thickness skin ulcers and were treated until complete healing (36). They didn't measured any molecular biomarkers. In our study treatment time was 14 days. In this period, no healing score more than 50% was found. We think it's better to repeat the same study over a longer period of treatment time and on larger samples.

Analysis of NO and PDGF concentration in wound fluids in the 5th day of study revealed no significant difference between groups; however in the case of the bFGF concentration, all groups had a higher bFGF concentration than the control group (group treated by 1% was significantly higher). In our study, *Q. brantii* extract increased the bFGF level in wound fluid but it was only significantly higher in lower dose. Different studies have shown that foods rich in tannins are toxicogenic and able to prevent cell growth. Especially

antibacterial and larvicidal effects of *Quercus* species galls are reported and proved by different studies (36, 39). So the result of our study can be due to the toxic effect of the plant. This can be the reason that in lower dose the bFGF level was significantly higher than control group but in higher doses the bFGF level is diminished. It can be due to a dose dependent effect. More studies with more groups treated with different doses of the QB extract is recommend. Wound healing potentials of *Quercus infectoria* and *Quercus persica* had been previously discussed in the literature. Umachigi *et al* have suggested that the ethanol extracts of *Quercus infectoria* leaves have positive effect on wound healing with a significant increase in the levels of antioxidant enzymes, superoxide dismutase and catalase, in the granulation tissue. The *Quercus infectoria*-treated animals in this study showed a significant increase in dry granuloma weight, granuloma breaking strength and the level of hydroxyproline content (40). Studies have shown that *Quercus* species have antibacterial activity on both Gram-positive and Gram-negative bacteria, with higher activity against Gram-positive bacteria (41, 42). As we know the burn wound is an ideal substrate for bacterial growth (43). *Staphylococcus aureus*, *Pseudomonas aeruginosa*, *Streptococcus pyogenes* and *Klebsiella pneumoniae* are the most important pathogenic bacteria in burns infections (37). Bacterial wound infection have detrimental effect on wound healing since it causes decreased chemotaxis, increased production of cytotoxic enzymes and decreased growth factor production (38). Voravuthikunchai and Kitpipit showed that *Q. infectoria* has significant activity against methicillin-resistant *S. aureus* (44). Singh *et al* has mentioned antibacterial activity for *Q. infectoria* dye against *Klebsiella pneumoniae* and *Pseudomonas aeruginosa* (45). According to the Ebrahimi *et al* study, *Q. persica* promote wound healing through increasing reepithelialization and wound contraction (24).

Conclusion

Despite the mentioned wound healing effects of *Q. infectoria* and *Q. persica*, our results didn't approve the significant positive effect of *Q. brantii* galls extract on healing of burn wounds. So more studies with more sample size and more groups treated with different doses of the *Q. brantii* extract is recommend.

Acknowledgment

This study was supported by Isfahan University of Medical Sciences, Isfahan, Iran (Grant no. 289064). The results described in this paper were part of a student thesis. The authors thank the staffs of the Applied Physiology Research Centre. We also are grateful to Mrs Khadije Fathi and Mr Fayegh Nazari because of their kind and detailed explanation of the method of treating burning wounds in the village (Toraq tape) they are living.

References

1. Stander M, Wallis LA. The emergency management and treatment of severe burns. *Emerg Med Int* 2011; 2011:161375.
2. Atiyeh BS, Costagliola M, Hayek SN, Dibo SA. Effect of silver on burn wound infection control and healing: review of the literature. *Burns* 2007; 33:139-148.
3. Bastos ML, Houly RL, Conserva LM, Andrade VS, Rocha EM, Lyra Lemos RP. Antimicrobial and wound healing activities of Piper hayneanum. *J Chem Pharm Res* 2011; 3:213-222.
4. Singer AJ, Clark R. Cutaneous wound healing. *N Engl J Med* 1999; 341:738-746.
5. Cohen JL, Jorizzo JL, Kircik LH. Use of a topical emulsion for wound healing. *J Support Oncol* 2007; 5:1-9.
6. Neub A, Houdek P, Ohnemus U, Moll I, Brandner JM. Biphasic regulation of AP-1 subunits during human epidermal wound healing. *J Invest Dermatol* 2007; 127:2453-2462.
7. Al-Waili N, Salom K, Al-Ghamdi AA. Honey for wound healing, ulcers, and burns; data supporting its use in clinical practice. *ScientificWorldJournal* 2011; 11:766-787.
8. Laplante AF, Moulin V, Auger FA, Landry J, Li H, Morrow G, *et al*. Expression of heat shock proteins in mouse skin during wound healing. *J Histochem Cytochem* 1998; 46:1291-1301.
9. Rawat S, Gupta A. Development and Study of Wound Healing Activity of an Ayurvedic Formulation. *Asian J Res Pharm Sci* 2011; 1:26-28.
10. Barrientos S, Stojadinovic O, Golinko MS, Brem H, Tomic-Canic M. Growth factors and cytokines in wound healing. *Wound Repair Regen* 2008; 16:585-601.
11. Friesel RE, Maciag T. Molecular mechanisms of angiogenesis: fibroblast growth factor signal transduction. *FASEB J* 1995; 9:919-925.
12. Ashcroft GS, Horan MA, Ferguson MW. The effects of ageing on wound healing: immunolocalisation of growth factors and their receptors in a murine incisional model. *J Anat* 1997; 190:351-365.
13. Pierce GF, Mustoe TA, Lingelbach J, Masakowski VR, Gramates P, Deuel TF. Transforming growth factor beta reverses the glucocorticoid-induced wound-healing deficit in rats: possible regulation in macrophages by platelet-derived growth factor. *Proc Natl Acad Sci U S A* 1989; 86:2229-2233.
14. Ansel JC, Tiesman JP, Olerud JE, Krueger JG, Krane JF, Tara DC, *et al*. Human keratinocytes are a major source of cutaneous platelet-derived growth factor. *J Clin Invest* 1993; 92:671-678.
15. Lynch SE, Colvin RB, Antoniades HN. Growth factors in wound healing. Single and synergistic effects on partial thickness porcine skin wounds. *J Clin Invest* 1989; 84:640-646.
16. Wink DA, Hanbauer I, Krishna MC, DeGraff W, Gamson J, Mitchell JB. Nitric oxide protects against cellular damage and cytotoxicity from reactive oxygen species. *Proc Natl Acad Sci U S A* 1993; 90:9813-9817.
17. Luo JD, Chen AF. Nitric oxide: a newly discovered function on wound healing. *Acta Pharmacol Sin* 2005; 26:259-264.
18. Bishop A. Role of oxygen in wound healing. *J Wound Care* 2008; 17:399-402.

19. Song HS, Park TW, Sohn UD, Shin YK, Choi BC, Kim CJ, *et al*. The effect of caffeic acid on wound healing in skin-incised mice. *Korean J Physiol Pharmacol* 2008; 12:343-347.
20. Soneja A, Drews M, Malinski T. Role of nitric oxide, nitrooxidative and oxidative stress in wound healing. *Pharmacol Rep* 2005; 57:108-119.
21. Djerrou Z, Maameri Z, Hamdi-Pacha Y, Serakta M, Riachi F, Djaalab H, *et al*. Effect of virgin fatty oil of *Pistacia lentiscus* on experimental burn wound's healing in rabbits. *Afr J Tradit Complement Altern Med* 2010; 7:258-263.
22. Nixon KC, editor An overview of *Quercus*: Classification and phylogenetics with comments on differences in wood anatomy 2007.
23. Safary A, Motamedi H, Maleki S, Seyyednejad S. A preliminary study on the antibacterial activity of *Quercus brantii* against bacterial pathogens, particularly enteric pathogens. *Int J Botany* 2009; 5:176-180.
24. Ebrahimi A, Khayam M, Nejati V. Evaluation of the antibacterial and wound healing activity of *quercus persica*. *J Basic Appl Sci* 2012; 8:118-123.
25. Singleton VL, Orthofer R, Lamuela-Raventos RM. Analysis of total phenols and other oxidation substrates and antioxidants by means of Folin-Ciocalteu reagent. *Methods Enzymol* 1999; 299:152-178.
26. Koizumi T, Goto H, Tanaka H, Yamaguchi Y, Shimazaki S. Lecithinized superoxide dismutase suppresses free radical substrates during the early phase of burn care in rats. *J Burn Care Res* 2009; 30:321-328.
27. Thakur R, Jain N, Pathak R, Sandhu SS. Practices in wound healing studies of plants. *Evid Based Complement Alternat Med* 2011; 2011: 438056.
28. Greenhalgh DG, Sprugel KH, Murray MJ, Ross R. PDGF and FGF stimulate wound healing in the genetically diabetic mouse. *Am J Pathol* 1990; 136:1235-1246.
29. Barro CD, Romanet JP, Fdili A, Guillot M, Morel F. Gelatinase concentration in tears of corneal-grafted patients. *Curr Eye Res* 1998; 17:174-182.
30. Muller M, Trocme C, Lardy B, Morel F, Halimi S, Benhamou PY. Matrix metalloproteinases and diabetic foot ulcers: the ratio of MMP-1 to TIMP-1 is a predictor of wound healing. *Diabet Med* 2008; 25:419-426.
31. Zandifar E, Sohrabi Beheshti S, Zandifar A, Haghjooy Javanmard S. The effect of captopril on impaired wound healing in experimental diabetes. *Int J Endocrinol* 2012; 2012:785247.
32. Boykin JV Jr, Baylis C. Hyperbaric oxygen therapy mediates increased nitric oxide production associated with wound healing: a preliminary study. *Adv Skin Wound Care* 2007; 20:382-388.
33. Haghjooyjavanmard S, Nematbakhsh M, Monajemi A, Soleimani M. von Willebrand factor, C-reactive protein, nitric oxide, and vascular endothelial growth factor in a dietary reversal model of hypercholesterolemia in rabbit. *Biomed Pap Med Fac Univ Palacky Olomouc Czech Repub* 2008; 152:91-95.
34. Haghdooost F, Baradaran Mahdavi MM, Zandifar A, Sanei MH, Zolfaghari B, Javanmard SH. *Pistacia atlantica* resin has a dose-dependent effect on angiogenesis and skin burn wound healing in rat. *Evid Based Complement Alternat Med* 2013; 2013:8.
35. Lai HY, Lim YY, Kim KH. Potential dermal wound healing agent in *Blechnum orientale* Linn. *BMC Complement Altern Med* 2011; 11:62.
36. Hemmati AA, Houshmand G, Nemati M, Bahadoram M, Dorestan N, Rashidi-Nooshabadi MR, *et al*. Wound healing effects of persian Oak (*Quercus brantii*) ointment in rats. *Jundishapur J Nat Pharm Prod* 2015; 10:e25508.
37. Jenkins AT, Young A. Smart dressings for the prevention of infection in pediatric burns patients. *Expert Rev Anti Infect Ther* 2010; 8:1063-1065.
38. Edwards R, Harding KG. Bacteria and wound healing. *Curr Opin Infect Dis* 2004; 17:91-96.
39. Redwane A, Lazrek HB, Bouallam S, Markouk M, Amarouch H, Jana M. Larvicidal activity of extracts from *Quercus lusitania* var. *infectoria* galls (Oliv.). *J Ethnopharmacol* 2002; 79:261-263.
40. Umachigi S, Jayaveera K, Ashok Kumar C, Kumar G, Kishore Kumar D. Studies on wound healing properties of *Quercus infectoria*. *Trop J Pharm Res* 2008; 7:913-9.
41. Basri D, Fan S. The potential of aqueous and acetone extracts of galls of *Quercus infectoria* as antibacterial agents. *Indian J Pharmacol* 2005; 37:26.
42. Sakar MK, Sohretoglu D, Ozalp M, Ekizoglu M, Piacente S, Pizza C. Polyphenolic compounds and antimicrobial activity of *Quercus aucheri* leaves. *Turk J Chem* 2005; 29:555.
43. Abd-El Aal AM, El-Hadidy MR, El-Mashad NB, El-Sebaie AH. Antimicrobial effect of bee honey in comparison to antibiotics on organisms isolated from infected burns. *Ann Burns Fire Disasters* 2007; 20:83-88.
44. Voravuthikunchai SP, Kitpipit L. Activity of medicinal plant extracts against hospital isolates of methicillin-resistant *Staphylococcus aureus*. *Clin Microbiol Infect* 2005; 11:510-512.
45. Singh R, Jain A, Panwar S, Gupta D, Khare S. Antimicrobial activity of some natural dyes. *Dyes Pigm* 2005; 66:99-102.