

## Favorable effects of progesterone on skin random flap survival in rats

Lin Dingsheng<sup>1,2</sup>, Liu Zengbing<sup>1,3</sup>, Huang Dong<sup>1\*</sup>

<sup>1</sup>Department of Orthopaedics, Southern Medical University, Guangdong No.2 Province people's Hospital, Guangdong, China

<sup>2</sup>Department of Hand Surgeries, The Second Affiliated Hospital of Wenzhou Medical University, Wenzhou, China

<sup>3</sup>Department of Hand Surgeries, The No.4 People's Hospital of Hengshui, Hengshui, China

### ARTICLE INFO

#### Article type:

Original article

#### Article history:

Received: Apr 1, 2016

Accepted: Jun 30, 2016

#### Keywords:

Angiogenesis  
Malondialdehyde  
Progesterone  
Random skin flap  
Superoxide dismutase  
Vascular endothelial -  
growth factor

### ABSTRACT

**Objective(s):** The aim of this study is to determine the effects of progesterone treatment on the survival of random skin flaps.

**Materials and Methods:** McFarlane flaps were established and 40 male rats were randomly assigned to the progesterone-treated as the test group or normal saline-treated as the control group. Progesterone or normal saline (10 mg/kg) was administered intraperitoneally once daily. On postoperative day 2, malondialdehyde (MDA) and superoxide dismutase (SOD) were detected using test kits. Flap survival rates were evaluated with transparent graph paper under direct visualization, the levels of inflammation were examined by haematoxylin and eosin (H&E) staining, and the expression of vascular endothelial growth factor (VEGF) was immunohistochemically evaluated on day 7.

**Results:** Compared to that in the control group, the mean survival area was significantly larger in the progesterone group. SOD activity was increased significantly, but the MDA levels in the test group were decreased. H&E-stained slices revealed that inflammation was inhibited in the test group. VEGF expression markedly increased in the progesterone group.

**Conclusion:** This study showed that progesterone administered intraperitoneally significantly improved random skin flap survival in rats.

#### ► Please cite this article as:

Dingsheng L, Zengbing L, Dong H. Favorable effects of progesterone on skin random flap survival in rats. Iran J Basic Med Sci 2016; 19:1166-1170.

### Introduction

In plastic surgery, randomly patterned skin flaps are commonly used as a reconstructive option, because such transfer is technically simple, and the flap colour and texture largely match those of recipient site tissues (1-3). Unfortunately, flap necrosis is a major reason for failure in plastic and reconstructive surgery (4). Various studies have focused on enhancing flap viability through pharmacological manipulations, such as the use of nitroglycerine (5), and antioxidants (6), which have been shown to be beneficial in improving random flap survival. Nevertheless, their safety and validity are still controversial.

Progesterone is widely known as a female sex hormone, and exogenous progesterone is used to treat women who experience repeat abortions and irregular menstruation. Progesterone has also been reported to act as a neurohormone, and has neuroprotective effects (7). It is known that progesterone promotes neurogenesis after ischemic stroke by increasing vascular endothelial growth factor (VEGF) expression (8) and reducing inflammatory cytokine levels (9, 10). In recent years, progesterone has

been reported to exhibit potent antioxidant and anti-inflammatory activities (11, 12). Dang *et al* (13) showed that progesterone increased VEGF expression in an animal model of ischemia-reperfusion injury.

Ischemia-reperfusion, a complex inflammatory process, is considered to be the principal pathogenic factor compromising random flap survival (14).

Superoxide dismutase (SOD) is a natural intracellular scavenger of oxygen free radicals, a sensitive indicator of antioxidant status, and an important endogenous antioxidant (15). However, malondialdehyde (MDA) is a product of intracellular lipid peroxidation caused by the toxic effects of oxygen free radicals. Some studies have shown that progesterone alleviated acute brain injury by elevating SOD activities and reducing MDA levels after subarachnoid haemorrhage (16). Thus, we hypothesized that progesterone might improve random skin flap survival via such physiological and pharmacological effects. However, the potential effects of progesterone on survival of random skin flaps have not been explored.

The purpose of the present research was to determine the effects of progesterone on random skin flap survival.

\*Corresponding author: Huang Dong. Department of Orthopaedics, Southern Medical University, Guangdong No.2 Province people's Hospital, Guangdong, China. Tel/Fax: 0086-2089168888; email: huangdong\_177@126.com

## Materials and Methods

### Ethics statement

All experiments in this study were performed in strict accordance with the recommendations in the Guide to the Care and Use of Laboratory Animals of the National Institutes of Health.

### Animals and groups

Forty male Sprague-Dawley rats, weighing 200–250 g, were used in this study. They have been divided into two main groups randomly: the test group, progesterone-treated group (n= 20) and the control: normal saline-treated group (n = 20). Each main group was divided into three subgroups for research. The first subgroup: on postoperative day 2, flap tissue samples of 7 rats in each group were used to determine oxidative stress marker levels. The second subgroup: on postoperative day 7, 7 rats in each group were used for macroscopic evaluation. The third subgroup: the remaining 6 rats in each group were used for histopathological assessment and VEGF immunostaining. The study also followed the Guide for the Care and Use of Laboratory Animals of Wenzhou Medical University.

### Reagents

Progesterone (H33020828) was purchased from Zhejiang Xian Ju Pharmaceutical Co, Ltd (Zhejiang, China). SOD and MDA test kits were purchased from Nanjing Jiancheng Biology Institution (Nanjing City, Jiangsu Province, China). Anti-VEGF antibody was purchased from Santa Cruz Biotechnology (Dallas, TX, USA), and Cedar Bridge Company (Beijing, China) was the source of goat anti-rat immunoglobulin G-R (IgG-R).

### Surgical procedure

Animals were anesthetized with an intraperitoneal injection of 2% (w/v) pentobarbital sodium (40 mg/kg, Solarbio Science & Technology, Beijing, China). The skin of the dorsal trunk was shaved with electric clippers and the remaining hair was soaked with water and daubed with depilatory cream uniformly before the surgical operation. Then, 3 min later, the cream was removed and the procedure was repeated until the hair was removed completely. A McFarlane flap (17) measuring 9 × 3 cm was marked on the back: with reference to the iliac crests and the spine, a caudally-based flap was raised and completely separated from the deep fascia; then, both sacral arteries were sheared off completely. Finally, the flap was sutured back onto the original position using 4-0 running nylon sutures. Prior to analysis, each flap was divided into 3 distinct equal zones: the distal zone (area III), the intermediate zone (area II), and the proximal zone (area I). Progesterone (10 mg/kg) was injected into the test group subjects (intraperitoneal injection [IP]) and the control group subjects received the same volume of saline solution (IP). Injections were given once daily for

7 consecutive days. The rats were housed individually after the operation and were given a neck collar to prevent skin flap cannibalism (18). Standard laboratory food for rats and water were provided *ad libitum*. All surgeries were performed by the same staff and no rat died during the procedures. Then, 2 and 7 days later, the rats were sacrificed with 50 g/l chloral hydrate (8 ml/kg, IP).

### Testing Indicators

#### Macroscopic Evaluation

On postoperative day 7, survival of the flaps was assessed by measuring the size of viable and necrotic areas with transparent graph paper (in mm<sup>2</sup>) under direct visualization, which is an easy method used by many researchers (19). A dark colour and eschar formation indicated flap necrosis. Outcomes are shown as percentage of viable areas, calculated using the formula: extent of viable area × 100 / total area (viable and ischemic).

#### Histopathological Assessment

On postoperative day 7, 3 flap tissue samples (1 cm × 1 cm) from the centre of the flaps were collected from 3 areas and fixed in 10% (v/v) formaldehyde for 24 h, embedded in paraffin wax, sliced longitudinally into 5-μm thick segments, and stained with haematoxylin and eosin (H&E). The numbers of neutrophils were counted under a light microscope (×100). We randomly chose 5 scope fields (×100), counted the numbers of the neutrophils, and then used the formula: total neutrophil counts/5 scope fields.

#### Determination of Oxidative Stress Markers

On postoperative day 2, 10 flap tissue samples (0.5 cm × 0.5 cm) were rapidly collected from the transition areas (Areas II and III) of the 2 groups. The specimens were homogenized, weighed, and then diluted to 10% (v/v) in an ice bath. SOD activity was assessed using a commercial test kit via an oxidase enzymatic method. The MDA levels in the flap tissue were assessed using a commercial test kit via the thiobarbituric acid method (TBA) at 90–100°C (20).

#### VEGF immunostaining

VEGF expression levels were evaluated immunohistochemically using a streptavidin/peroxidase-based protocol. The tissue sections were dewaxed using xylene and ethanol; then, normal goat serum (a blocking solution) was added, followed by incubation for 20 min at room temperature. Next, 50-μl amounts of primary antibody solution (diluted 1:200) were added and the slices were held at 4 °C for 18 hr. All slices were warmed to 37 °C for 45 min and washed with phosphate-buffered saline (PBS) solution. Next, 50-μl amounts of goat anti-rat antibody (diluted 1:50) were added to the slices, which were then incubated at 37 °C for 1 hr, and washed with PBS solution. A 3, 3'-

diaminobenzidine tetrahydrochloride (DAB) solution was applied for 3 min for colour development.

First, we used a BX51 optical microscope (Olympus Corporation, Tokyo, Japan) to identify VEGF-intensive regions under low magnification, and then vessels in each slice were viewed in 5 fields under high ( $\times 400$ ) magnification. Observation parameters (white balance, aperture, shutter speed, and time) did not vary. Images were saved using Image-Pro Plus software (ver. 6.0; Media Cybernetics, Rockville, MD, USA) and the integral absorbance (IA) values were used as indicators of VEGF expression levels.

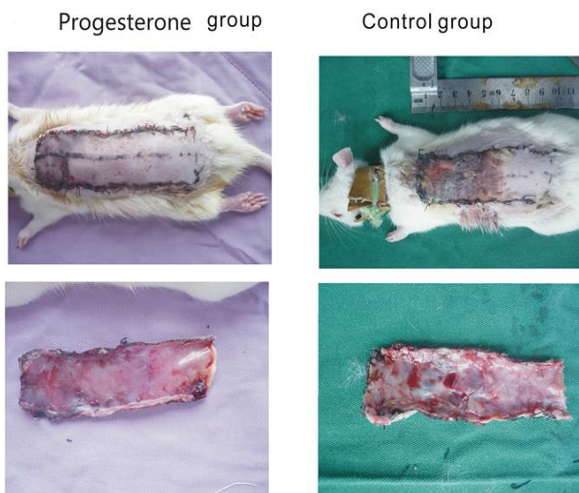
**Statistical analysis**

Data are expressed as means  $\pm$  standard errors (SE). Percent survival and histology were compared using the Mann-Whitney U-test. Student's *t*-test was used for between-group comparisons. Graphs were rendered using the GraphPad prism software package (Ver. 5.0 GraphPad Software, Inc., La Jolla, CA, USA). All data were analysed with SPSS software (ver. 19.0; SPSS Inc., Chicago, IL, USA). A *P*-value $<0.05$  was considered to reflect statistical significance.

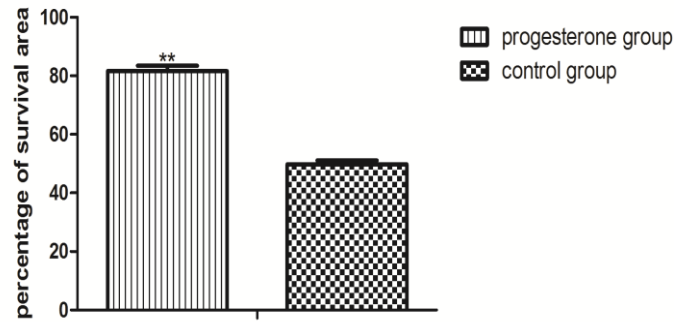
**Results**

**Macroscopic evaluation**

On postoperative day 7, the boundary between the surviving and necrotic area was clear on each flap: the necrotic areas of the flaps were dark in colour with a rough texture, while the surviving flap area had a normal colour and normal texture. Area I in all flaps survived but Area III in all flaps was necrotic. Area II in all flaps partially survived (Figure 1). The percentages of surviving areas were  $81.62\pm 1.86\%$  and  $49.78\pm 1.36\%$  in the experimental and control groups, respectively ( $P<0.01$ ; Figure 2).



**Figure 1.** Digital photographs showing flaps from the 2 groups. On postoperative day 7, the boundary between the surviving and necrotic area was clear in each flap. The distal area (area III) in the progesterone group exhibited less oedema, inflammatory response and fibre hyperplasia under the skin than the control



**Figure 2.** Percentage of surviving area in the 2 groups. The percentage surviving areas were  $81.62\pm 1.86\%$  and  $49.78\pm 1.36\%$  in the progesterone and control groups, respectively ( $P<0.01$ )

**Histopathological evaluation**

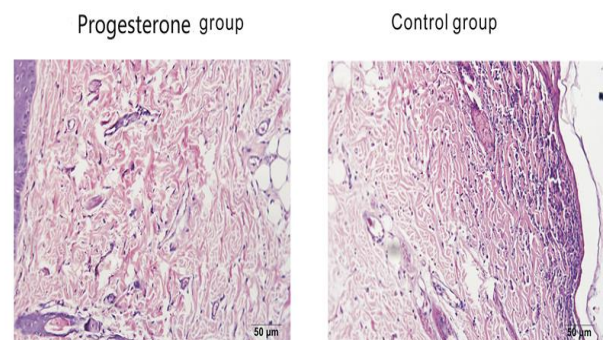
H&E-stained slices from area II of the 2 groups showed that the infiltration of inflammatory cells in the control group was obviously more extensive than that in the test group. Neutrophil density was obvious in the control group ( $44.80\pm 3.54$ ), whereas it decreased significantly in the experimental group ( $30.10\pm 2.67$ ), indicating that the inflammatory reaction was more severe in the control group ( $P<0.05$ ; Figure 3).

**Content of oxidative stress markers**

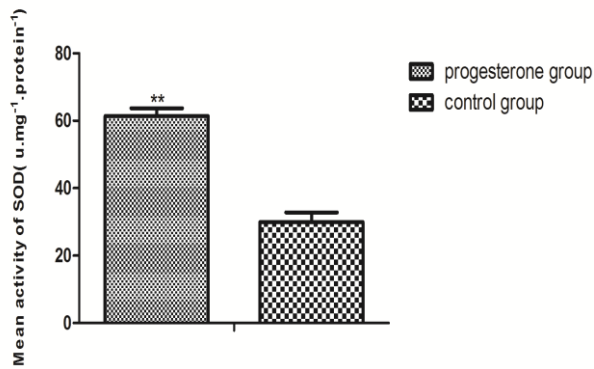
The SOD level in the experimental flaps group was  $61.40\pm 2.29$  u-mg<sup>-1</sup>·protein<sup>-1</sup>, which was significantly higher than that in the control group ( $29.95\pm 2.91$  u-mg<sup>-1</sup>·protein<sup>-1</sup>,  $P<0.01$ ; Figure 4). The mean level of MDA in the experimental group ( $16.25\pm 3.08$  nmol-mg<sup>-1</sup>·protein<sup>-1</sup>) was significantly lower than that in the control group ( $62.32\pm 5.38$  nmol-mg<sup>-1</sup>·protein<sup>-1</sup>,  $P<0.01$ ; Figure 5).

**VEGF expression**

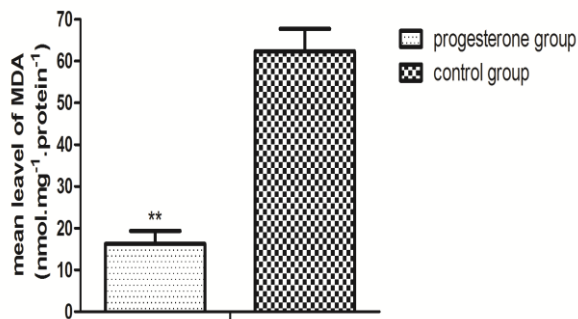
Immunohistochemical results showed that the average VEGF expression increased significantly in the experimental group ( $3,479\pm 68$ ) compared to the control group ( $1,923\pm 43$ ,  $P<0.01$ ; Figure 6).



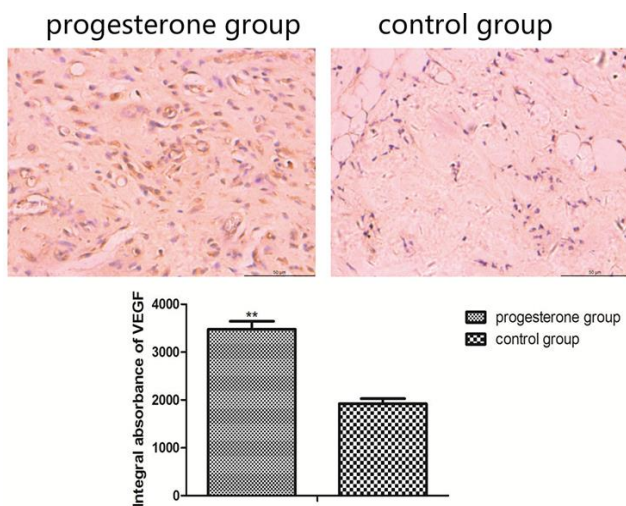
**Figure 3.** Histological changes in the flaps in the 2 groups ( $\times 100$ ). Neutrophil density was obvious in the control group ( $44.80\pm 3.54$ ), whereas it decreased significantly in the experimental group ( $30.10\pm 2.67$ ) ( $P<0.05$ )



**Figure 4.** Mean activity of superoxide dismutase (SOD) in the 2 groups. The SOD level in the experimental flaps group was 61.40±2.29 u.mg<sup>-1</sup>.protein<sup>-1</sup>, which was significantly higher than that in the control group (29.95±2.91 u.mg<sup>-1</sup>.protein<sup>-1</sup>, P<0.01)



**Figure 5.** Mean level of malondialdehyde (MDA) in the 2 groups. The mean level of MDA in the experimental group (16.25±3.08 nmol.mg<sup>-1</sup>.protein<sup>-1</sup>) was significantly lower than that in the control group (62.32±5.38 nmol.mg<sup>-1</sup>.protein<sup>-1</sup>, P<0.01)



**Figure 6.** Comparison of vascular endothelial growth factor (VEGF) expression in the intermediate area II of the 2 groups. Immunohistochemical results showed that the average VEGF expression increased significantly in the experimental group (3,479±68) compared to the control group (1,923±43, P<0.01)

**Discussion**

In the present study, we showed that intraperitoneal progesterone was beneficial for the survival of random skin flaps. Progesterone significantly increased SOD levels and decreased MDA levels in flap tissue specimens from the progesterone-treated group. Histopathological and immunohistochemical examinations revealed increased VEGF expression.

Reactive oxygen species (ROS) play an important role in the pathogenesis of ischemia-reperfusion injury, and their generation starts when oxygen is reintroduced to a tissue after ischemia (21). The fresh supply of oxygen in ischemic tissue is a double-edged sword. On the one hand, it reduces the accumulation of lactic acid and increases the generation of ATP. These changes are conducive to cell homeostasis. On the other hand, the oxygen results in generation of ROS, which are damaging to proteins, nucleic acids, and fatty acids. It is well known that ROS and their products, such as lipid peroxides, can damage the cell membrane. Thus, scavenging ROS is important after tissue reperfusion (22).

SOD is a vital endogenous antioxidant and a sensitive indicator of antioxidant status (23). MDA, a major product of lipid peroxidation, is generated as a result of the toxic effects of oxygen free radicals. Thus, MDA levels are an objective indicator of tissue oxidative damage. Although progesterone significantly suppressed MDA levels and increased SOD levels in the flap tissues in this study, its mechanism is unclear. It is likely associated with a stimulatory effect on SOD.

Blood supply is a critical factor in flap survival. It is well known that VEGF induces the migration and proliferation of endothelial cells and enhances neovascularization (24). Many reports have shown that progesterone can increase VEGF expression (25, 26). In this study, the levels of VEGF expression in the flaps of the test group were significantly higher than the levels in the flaps of the control group. This indicates that progesterone may improve flap survival via a VEGF-mediated angiogenesis effect. Nevertheless, the mechanism by which progesterone regulates VEGF needs to be studied further.

In conclusion, progesterone increased SOD activity and VEGF expression, eliminated ROS, and suppressed inflammatory reactions. In light of our results, we conclude that progesterone improved random flap survival by acting as an anti-inflammatory, antioxidant, and angiogenic agent, and that it may be useful in clinical practice to improve random flap survival.

**Conclusion**

This study showed that progesterone, administered intraperitoneally, significantly improved random skin flap survival in rats.

## Acknowledgment

This study was supported by the National Natural Science Foundation of China (No.81503397), Zhejiang Province Chinese medicine scientific research fund (No. 2014ZB074), Zhejiang provincial medical and health science and technology program (2016KYB195).

## Conflict of interest

The authors declare that there are no conflicts of interest.

## References

- Brown DL, Penington AJ. Murine skin flap survival may not be affected by underlying fat viability. *J Plast Reconstr Aesthet Surg* 2007; 60:294-299.
- Zhang T, Gong W, Li Z, Yang S, Zhang K, Yin D, *et al.* Efficacy of hyperbaric oxygen on survival of random pattern skin flap in diabetic rats. *Undersea Hyperb Med* 2007; 34:335-339.
- Dolen UC, Sungur N, Koca G, Ertunc O, Bagci Bosi AT, Kocer U, *et al.* The Vasodilator Effect of a Cream Containing 10% Menthol and 15% Methyl Salicylate on Random-Pattern Skin Flaps in Rats. *Arch Plast Surg* 2015; 42:695-703.
- Bagdas D, Cam Etoz B, Inan Ozturkoglu S, Cinkilic N, Ozyigit MO, Gul Z, *et al.* Effects of systemic chlorogenic acid on random-pattern dorsal skin flap survival in diabetic rats. *Biol Pharm Bull* 2014; 37:361-370.
- Sa JZ, Aguiar JL, Cruz AF, Schuler AR, Lima JR, Marques OM. The effects of local nitroglycerin on the surgical delay procedure in prefabricated flaps by vascular implant in rats. *Acta Cir Bras* 2012; 27:905-911.
- Ciloglu NS, Zeytin K, Aker F. The effects of resveratrol on flap survival in diabetic rats. *J Plast Surg Hand Surg* 2014; 48:234-237.
- De Nicola AF, Coronel F, Garay LI, Gargiulo-Monachelli G, Gonzalez Deniselle MC, Gonzalez SL, *et al.* Therapeutic effects of progesterone in animal models of neurological disorders. *CNS Neurol Disord Drug Targets* 2013; 12:1205-1218.
- Jiang C, Zuo F, Wang Y, Lu H, Yang Q, Wang J. Progesterone changes VEGF and BDNF expression and promotes neurogenesis after ischemic stroke. *Mol Neurobiol* 2016; 1-11.
- He J, Evans CO, Hoffman SW, Oyesiku NM, Stein DG. Progesterone and allopregnanolone reduce inflammatory cytokines after traumatic brain injury. *Exp Neurol* 2004; 189:404-412.
- Wright DW, Kellermann AL, Hertzberg VS, Clark PL, Frankel M, Goldstein FC, *et al.* ProTECT: a randomized clinical trial of progesterone for acute traumatic brain injury. *Ann Emerg Med* 2007; 49:391-402, 402 e391-392.
- Evsen MS, Ozler A, Gocmez C, Varol S, Tunc SY, Akil E, *et al.* Effects of estrogen, estrogen/progesterone combination and genistein treatments on oxidant/antioxidant status in the brain of ovariectomized rats. *Eur Rev Med Pharmacol Sci* 2013; 17:1869-1873.
- Si D, Wang H, Wang Q, Zhang C, Sun J, Wang Z, *et al.* Progesterone treatment improves cognitive outcome following experimental traumatic brain injury in rats. *Neurosci Lett* 2013; 553:18-23.
- Dang J, Mitkari B, Kipp M, Beyer C. Gonadal steroids prevent cell damage and stimulate behavioral recovery after transient middle cerebral artery occlusion in male and female rats. *Brain Behav Immun* 2011; 25:715-726.
- Cao B, Wang L, Lin D, Cai L, Gao W. Effects of lidocaine on random skin flap survival in rats. *Dermatol Surg* 2015; 41:53-58.
- Zhu WH, Leng XS, Zhu JY. Effect of Shenfu injection on ischemia-reperfusion injury of rat liver graft. *Hepatobiliary Pancreat Dis Int* 2006; 5:205-209.
- Cai J, Cao S, Chen J, Yan F, Chen G, Dai Y. Progesterone alleviates acute brain injury via reducing apoptosis and oxidative stress in a rat experimental subarachnoid hemorrhage model. *Neurosci Lett* 2015; 600:238-243.
- Kelly CP, Gupta A, Keskin M, Jackson IT. A new design of a dorsal flap in the rat to study skin necrosis and its prevention. *J Plast Reconstr Aesthet Surg* 2010; 63:1553-1556.
- Ozkan O, Ozgentas HE. Combination of rat vest, teeth shortening, and nail cutting to prevent aut cannibalization and protect surgical flaps. *Plast Reconstr Surg* 2006; 117:1671.
- Reichenberger MA, Keil H, Mueller W, Herold-Mende C, Gebhard MM, Germann G, *et al.* Comparison of extracorporeal shock wave pretreatment to classic surgical delay in a random pattern skin flap model. *Plast Reconstr Surg* 2011; 127:1830-1837.
- Ozkan F, Senayli Y, Ozyurt H, Erkorkmaz U, Bostan B. Antioxidant effects of propofol on tourniquet-induced ischemia-reperfusion injury: an experimental study. *J Surg Res* 2012; 176:601-607.
- Gurlek A, Aydogan H, Parlakpinar H, Bay-Karabulut A, Celik M, Sezgin N, *et al.* Protective effect of melatonin on random pattern skin flap necrosis in pinealectomized rat. *J Pineal Res* 2004; 36:58-63.
- Lin Y, Lin B, Lin D, Huang G, Cao B. Effect of thymosin beta4 on the survival of random skin flaps in rats. *J Reconstr Microsurg* 2015; 31:464-470.
- Sirota TV, Zakharchenko MV, Kondrashova MN. [Cytoplasmic superoxide dismutase activity is a sensitive indicator of the antioxidant status of the rat liver and brain]. *Biomed Khim* 2014; 60:63-71.
- Fang T, Lineaweaver WC, Chen MB, Kisner C, Zhang F. Effects of vascular endothelial growth factor on survival of surgical flaps: a review of experimental studies. *J Reconstr Microsurg* 2014; 30:1-13.
- Uysal N, Baykara B, Kiray M, Cetin F, Aksu I, Dayi A, *et al.* Combined treatment with progesterone and magnesium sulfate positively affects traumatic brain injury in immature rats. *Turk Neurosurg* 2013; 23:129-137.
- Hyder SM, Stancel GM. Regulation of angiogenic growth factors in the female reproductive tract by estrogens and progestins. *Mol Endocrinol* 1999; 13:806-811.