

Exploring the effect of intravenous lipid emulsion in acute methamphetamine toxicity

Ameneh Ghadiri ¹, Leila Etemad ^{2*}, Mohammad Moshiri ³, Seyed Adel Moallem ⁴, Amir Hossein Jafarian ⁵, Farzin Hadizadeh ⁶, Mahmoud Seifi ⁷

¹ Department of Toxicology, Faculty of Pharmacy, Islamic Azad University, Shahreza Branch, Shahreza, Iran

² Pharmaceutical Research Center, Mashhad University of Medical Sciences, Mashhad, Iran

³ Legal Medicine Research Center, Legal Medicine Organization, Tehran, Iran

⁴ Department of Pharmacodynamics and Toxicology, School of Pharmacy, Mashhad University of Medical Sciences, Mashhad, Iran

⁵ Department of Pathology, Ghaem Hospital, Mashhad University of Medical Sciences, Mashhad, Iran

⁶ Biotechnology Research Center, Mashhad University of Medical Sciences, Mashhad, Iran

⁷ Biotechnology Research Center, School of Pharmacy, Mashhad University of Medical Sciences, Mashhad, Iran

ARTICLE INFO

Article type:

Original article

Article history:

Received: Jul 31, 2016

Accepted: Oct 20, 2016

Keywords:

Acute toxicity

Antidote

Intravenous lipid emulsion

Methamphetamine

ABSTRACT

Objective(s): The increasing use of methamphetamine (METH) in the last decades has made it the second most abused drug. Advances in the area of intravenous lipid emulsion (ILE) have led to its potential application in the treatment of poisoning. The present study aims to investigate the potential role of ILE as an antidote for acute METH poisoning.

Materials and Methods: Two groups of six male rats were treated by METH (45 mg/kg), intraperitoneally. Five to seven min later, they received an infusion of 18.6 ml/kg ILE 20% through the tail vein or normal saline (NS). Locomotor and behavioral activity was assessed at different time after METH administration. Body temperature and survival rates were also evaluated. Brain and internal organs were then removed for histological examination and TUNEL assay.

Results: ILE therapy for METH poisoning in rats could prevent rats mortalities and returned the METH-induced hyperthermia to normal rates ($P<0.05$). ILE reduced freezing and stereotyped behaviors and increased rearing responses ($P<0.05$). Locomotor activity also returned to control levels especially during the last hours of the experiment. ILE administration decreased the prevalence of pulmonary emphysema in the lungs ($P<0.05$ and $P<0.01$) and percentages of TUNEL positive cells in the brain ($P<0.05$), in comparison with the control group.

Conclusion: ILE could reduce the severity of METH-induced toxicity as well as mortality rate in the animals. Intravenous infusion of lipid emulsion may save the life of patients with acute METH intoxication who do not respond to standard initial therapy.

► Please cite this article as:

Ghadiri A, Etemad L, Moshiri M, Moallem SA, Jafarian AH, Hadizadeh F, Seifi M. Exploring the effect of intravenous lipid emulsion in acute methamphetamine toxicity. Iran J Basic Med Sci 2017; 20:138-144; <http://dx.doi.org/10.22038/ijbms.2017.8236>

Introduction

The increasing use of methamphetamine (METH) in the last decades has made it the second-most abused drug in the world. It has been reported that nearly 0.7% of the global population (33.8 million people) aged 15 to 64 years-old, used amphetamine-type stimulants in 2010 (1). Relative ease of availability and low cost of synthesis are among the reasons for rise in METH abuse (2). METH abusers utilize various routes of administration including smoking, injection, ingestion, nasal insufflation or snorting, sublingually or even rectally (1). METH abuse can adversely affect health, causing acute mental and behavioral disorders and long-term health complications following chronic use (3). Every year, approximately 94000 cases of METH intoxication are admitted to the emergency wards of United States hospitals (4). The incidence of METH

intoxication in all autopsies in San Diego County has been 4.9% (5). Patients with acute METH intoxication may present with a variety of clinical manifestations including: hypertension, tachycardia, dysrhythmias, myocardial ischemia, hyperthermia, agitation, seizures, intra-cerebral hemorrhage, headache, euphoria, choreo-athetoid movements, hyperreflexia, paranoid psychosis, rhabdomyolysis, muscle rigidity and acute lung injury. Benzodiazepines are the recommended treatment for METH toxicity and can reduce agitation, seizures, delirium or hallucinations (6). However, at the present time, there is no available antidote for acute METH toxicity. Severe METH overdose or poisoning can even be fatal.

Intravenous lipid emulsion (ILE) is a lipid rich emulsion that has been used to provide calories and essential free fatty acid to patients in peripheral

*Corresponding author: Leila Etemad. Pharmaceutical Research Center, Mashhad University of Medical Sciences, Mashhad, Iran. Tel: +98-51-37112611; email: Etemadl@mums.ac.ir

parenteral nutrition (7). Recently, ILE has been utilized for delivering lipid-soluble drugs, such as fentanyl, decotaxl and etopsides, intravenously, because of the biocompatible nature of the lipid-based delivery systems (8-10). Advances in the area of ILE have resulted in potential application of ILE for treating poisoning. There is considerable evidence from animal studies and case reports to support the effectiveness of ILE in alleviating drug or xenobiotic toxicity and reversing the hemodynamic or neurological toxicity (11-13). The present study aims to investigate the potential role of ILE as an antidote in acute METH poisoning.

Materials and Methods

Animals and drugs

Two groups of six male Wistar rats weighing 250-300 g; were obtained from the Animal Center, School of Pharmacy, Mashhad University of Medical Sciences. Animals were kept on a 12 hr light/dark cycle and temperature of 23 ± 1 °C (room temperature) with free access to standard laboratory food and tap water.

All experimental procedures were carried out in accordance with the guidelines of the Animal Care Committee of Mashhad University of Medical Sciences.

ILE was obtained from Fresenius Kabi AB, Spain and METH was donated by the Department of Medicinal Chemistry, School of Pharmacy, Mashhad University of Medical Sciences (Mashhad, Iran).

Groups and treatments

All animals were treated by METH at a dose of 45 mg/kg, intraperitoneally. Five to seven min after METH injection, they received an infusion of 18.6 ml/kg ILE 20% in the experimental group or normal saline (NS) in the control group in the same volume through the tail vein. ILE or NS were infused at a rate of 4 ml/min. Dose and infusion rate were based on a previous study (14).

Evaluation of locomotor activity and stereotyped behavior

The locomotors activity and stereotypical behavior of all animals were assessed in an open field at 0 (before METH injection), 0.5, 1, 2, 4, 8 and 24 hr after METH administration. Briefly each rat was placed in the center of an open-field apparatus and its activity was recorded by digital video for 10 min. Motor activity was measured by the number of peripheral, central and total square crossings; freezing length and number of rearing.

Stereo-typed behavior was rated using the scoring system of Sanberg *et al* (15): asleep or stationary (0), active (1), predominantly active but with bursts (2), stereotyped activity such as sniffing along a fixed path in the cage (3), stereotyped sniffing or rearing maintained in one location (4), stereotyped behavior in one location with bursts of gnawing or licking (5).

Body temperature and survivals

The body temperatures of the rats in both control and experimental groups were assessed by rectal thermometer during the same intervals. The mortality rate was calculated for each group after 24 hrs of drug administration.

Histopathological examination and TUNEL assay

On the third day after drug administration, the brain and internal organs including the lung, kidney and pancreas of animals were removed after euthanasia and fixed by immersion in 10% buffered formalin. The tissues were then embedded into paraffin blocks and were cut at a thickness of 5 μ m tissue sections. For the histopathological examination, sections were stained with hematoxylin and eosin. Paraffin embedded sections were also scored for apoptosis by terminal deoxynucleotidyl transferase-mediated dUTP nick end labeling (TUNEL). The assay was performed according to the manufacturer's instructions (Roche/ Germany). The total number of positive cells on ten fields in each section was counted. Cells with condensed dark nuclei and morphological apoptotic changes were scored as TUNEL positive (16).

Statistical analysis

All numerical results are reported as mean \pm SEM. Unpaired T test was used to evaluate differences in the body temperature in two groups and two-way repeated-measures ANOVA for evaluating the differences among various times of intra-groups. Tukey *post-hoc* test was performed as posttest. Kruskal-Wallis ANOVA and Mann-Whitney testing were used for evaluating open-filed variables, stereotyping motions, histopathological findings and TUNEL results. Fisher exact tests were used to evaluate differences in mortality rate. The alpha level was set at 0.05. Data analysis was performed using SPSS Version 21.

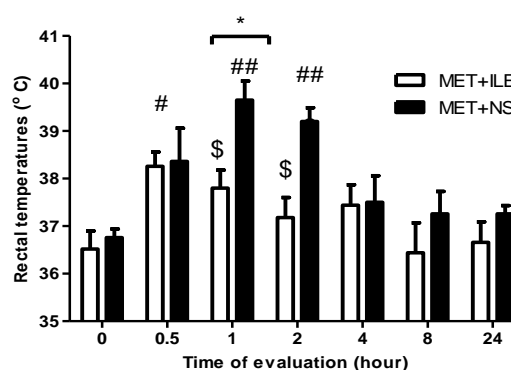


Figure 1. Rectal temperature of rats received methamphetamine (45mg/kg) plus intravenous lipid emulsion 20% (18.6 ml/kg). All data are expressed as mean \pm SEM, N=6. Comparison of data by values of zero time were analyzed by ANOVA, posttest=Tukey, N=6. # $P<0.05$, ## $P<0.01$ and\$ (Not significant) compared to control group. Comparison means between groups were analyzed by non-paired T test,* $P<0.05$ within-group comparisons

Results

Body temperature and survivals

ILE therapy for poisoning by METH in rats could protect them from death and all of them were alive at the time of the last evaluation. Nevertheless, only 50% of rats treated by METH+NS were survived (Mean survival time of METH+NS = 13 ± 3.7 hrs and METH+ILE = 24 ± 0 hr, $P < 0.05$). All METH-treated rats became hyperthermic after 30 min; however the mean rectal temperatures of ILE treated group returned to normal condition more quickly than the other group ($P < 0.05$) (Figure 1).

Evaluation of locomotor activity and stereotyped behavior

The mean time spends for freezing for each group is presented in Figure 2. METH in both groups significantly enhanced the freezing response until 2 hr after injection in comparison with zero time. In subsequent times, METH-induced freezing was significantly lessened by ILE compared with NS ($P < 0.01$ and $P < 0.05$) and could reverse the effect to normal.

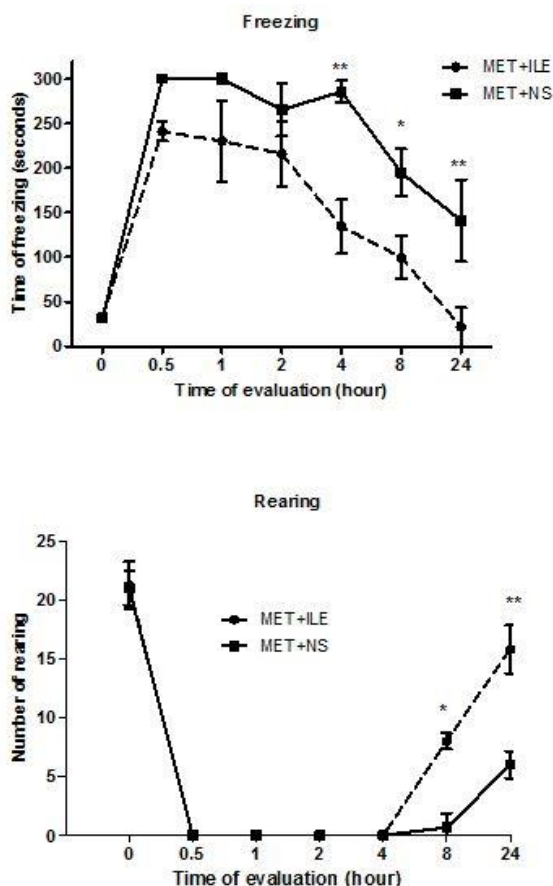


Figure 2. Effect of methamphetamine (45 mg/kg) administration plus intravenous lipid emulsion 20% (18.6 ml/kg) or normal saline on freezing and rearing in rats during different time intervals (hr). All data were expressed as mean \pm SEM, N=6. Comparison of values of two groups with each other at each episode of time was analyzed by non-paired T test, * $P < 0.05$, ** $P < 0.01$

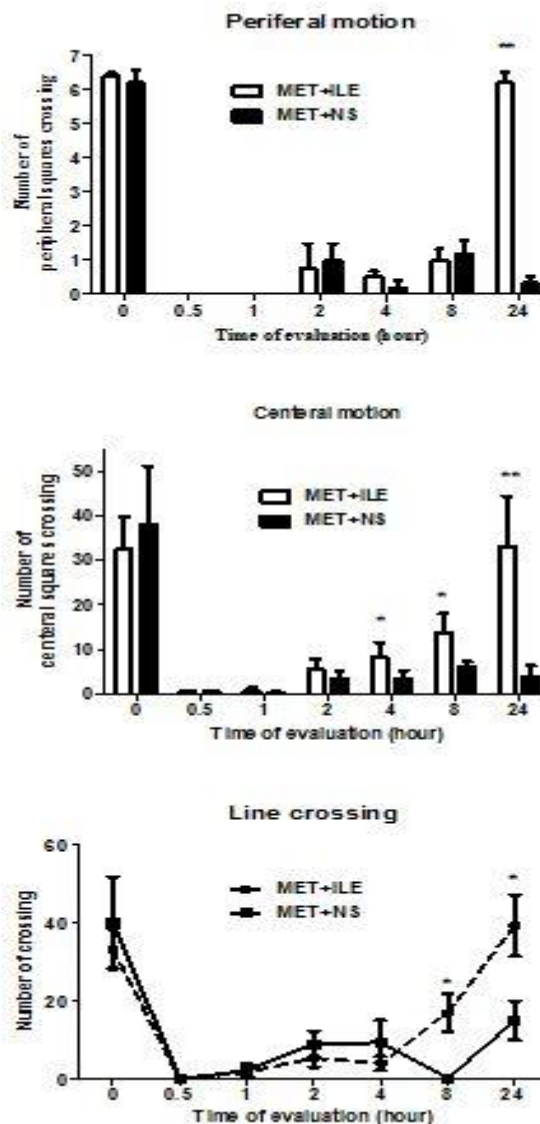


Figure 3. Effect of methamphetamine (45 mg/kg) administration plus intravenous lipid emulsion 20% (18.6 ml/kg) or normal saline on locomotor activity in rats at different time intervals (hr). Values are expressed as mean \pm SEM, N=6. Comparison of values of two groups with each other's on each time was analyzed by non-paired T test, * $P < 0.05$, ** $P < 0.01$

METH administration also decreased the rearing responses during the first two hrs that was significantly increased in the next time interval in the ILE receiving group ($P < 0.01$ and $P < 0.05$) (Figure 2).

The METH intoxicated rats lost the ability to cross the lines of open filed (Figure 3). However, rats that were exposed to the METH+ILE, especially during the last hrs of the experiment, crossed the central and periferal squares significantly more than the other group ($P < 0.01$) and returned to original condition (Figure 3). Indeed, the animals receiving METH engaged in vigorous stereotyped movements and ILE could reduce stereotyped behavior eight hrs after METH administration ($P < 0.05$) (Figure 4).

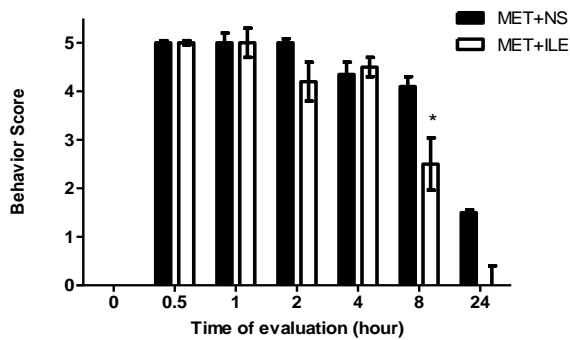


Figure 4. Stereotyped behavioral response to methamphetamine (45 mg/kg) administration plus intravenous lipid emulsion 20% (18.6 ml/kg) or normal saline every 10-min interval during 24 hr. Data were reported by mean±SE, N=6. Comparison of values of two groups with each other's on each time was analyzed by non-paired T test, * P<0.05

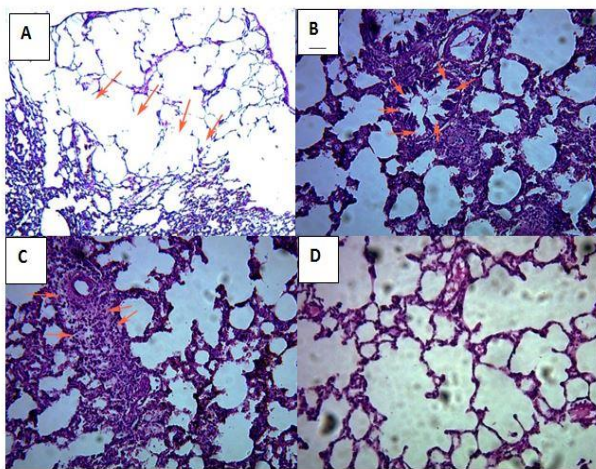


Figure 5. Light photomicrograph of hematoxylin and eosin-stained sections in the lung tissue of rats that were exposed to methamphetamine (45 mg/kg) plus intravenous lipid emulsion 20% (18.6 ml/kg) or normal saline. A) emphysema B) Bronchiolitis C) Interstitial Inflammation D) normal lung

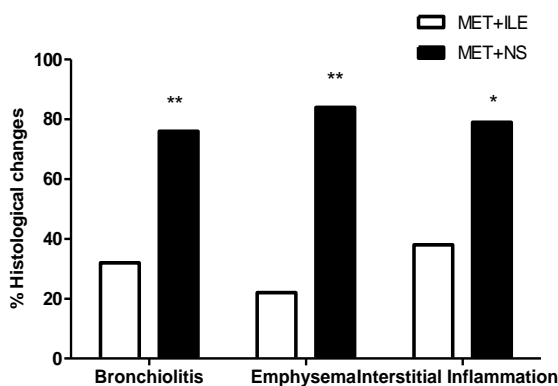


Figure 6. Effect of methamphetamine (45 mg/kg) plus intravenous lipid emulsion 20% (18.6 ml/kg) or normal saline on histopathological changes in the lung tissue of rats after 3 days. Results are shown as the mean±SEM. *P<0.05 and **P<0.01 vs control group. Data were analyzed by χ^2 tests. N=6

Histopathological examination and TUNEL assay

H&E staining of rat lungs following METH exposure showed the presence of emphysematous changes in the lungs, bronchiolitis and interstitial inflammation sections (Figure 5).

The frequency of these findings was significantly lower in the ILE-treated group in comparison with the control group (Figure 6). No pathologic findings were observed in other tissues.

The TUNEL assays revealed an induction of apoptosis in lung and brain tissues in groups receiving METH (Figure 7). However the percentages of TUNEL positive cells in the brain was significantly decreased only in groups that received METH+ ILE, in comparison with the control group (P<0.05) (Figure 8).

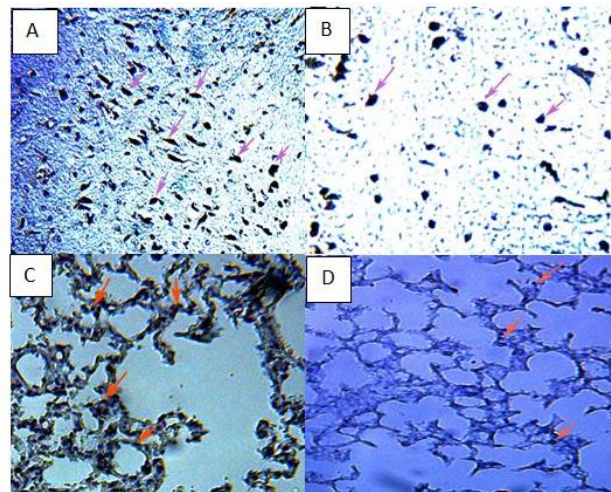


Figure 7. Immunohistochemical staining for TUNEL in the lung and brains tissue of rats that were exposed to methamphetamine (45 mg/kg) plus intravenous lipid emulsion 20% (18.6 ml/kg) or normal saline. The brain tissue from group received METH +NS (A), METH+ILE (B), and lung tissue from rats received METH +NS (C) and METH+ILE (D)

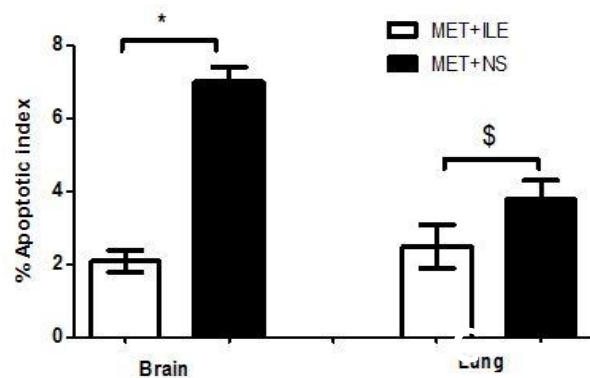


Figure 8. Effect of methamphetamine (METH) (45 mg/kg) plus intravenous lipid emulsion 20% (ILE) (18.6 ml/kg) or normal saline on cells apoptosis in the lung and brain tissues as revealed by TUNEL assay. Values are presented as mean±SEM. P<0.05* compared to control group. \$= Not significant

Discussion

The first ILE use for overdose/poisoning was reported in 2006 in the management of acute local anesthetic toxicity (17), especially restoring cardiac and hemodynamic stability. Nowadays the resuscitative effects of ILE has been evaluated against several classes of drugs and xenobiotic such as beta blockers (18), calcium channel blockers (19), organophosphates (20), tricyclic antidepressants (21), antipsychotics (22), cocaine(23), and others.

Although numerous mechanisms for ILE antidote activity have been suggested, the lipid sink (partitioning) theory is predominant. Based on this theory, the intravenous administration of lipid emulsion at high doses creates a new lipid compartment in the blood which causes fat-soluble drugs to move away from the target receptors. Subsequently, the concentration of drug is reduced at the target site and reverse the intoxication (24). There is a positive relationship between the fat solubility of drug; based on octanol/water partition coefficient and the volume of distribution; and decreasing serum drug concentration treated by ILE (25).

On the other hand, METH is a highly lipophilic drug with a volume distribution of 3.2-4.2 l/Kg and Log P (octanol/water) of 2.1 (26, 27). Thus it can cross the blood brain barrier more easily than other drugs (3). Therefore, ILE could redistribute METH from the action site, nervous system, and reverse intoxication in rats.

The common manifestations of METH overdose are as follows: agitation, shivering, dyspnea, hyperactivity, hyperpyrexia and tremor (4).

Amphetamine administration to the rats can produce behavioral excitation including forward locomotion, exploratory behavior, and different kinds of stereotyped behavior (28). In this study, METH-induced acute intoxication was associated with high frequency of stereotypical movements. The severity of intoxication and high frequency of stereotypical movements make animals unable to move normally. However, after one or two half-lives and diminishing of the severity of toxicity, the rats showed normal activity. The rats treated by ILE could return to normal behavior and body temperature faster than the control group.

ILE could also reduce the mortality rate of METH significantly in comparison with the control group. A similar effect has been reported for many other drugs such as haloperidol, tramadol, propranolol, bupivacaine and cocaine (13, 22, 29, 30). In most reports, ILE has been shown to reverse cardiac and hemodynamic instability.

Several studies confirm that ILE has also been able to reduce the complications or mortality induced by neurotoxic agents (13, 22, 31, 32). Unfortunately, we could not evaluate the cardiovascular manifestation of METH intoxication.

There are some human case reports regarding the successful treatment by ILE of poisoning when multiple

drugs are used simultaneously, such as cocaine and amphetamine. A 28-year-old man was admitted to the hospital complaining of convulsion, hemodynamic instability, tachycardia, supraventricular and ventricular arrhythmias, hyperthermia and loss of consciousness after overdosing on cocaine (33). When the standard treatment failed, he received an ILE infusion. After 15 min, the patient's cardiovascular condition was stabilized. Arora *et al* (23), in a similar case, successfully treated cocaine poisoning with ILE in a patient who did not respond to standard treatment for seizure and cardiac outcomes. Pre-treatment on cocaine toxicity with ILE could significantly reduce cocaine-induced mortality rate, cardiovascular collapse and blunted hypotension in rats. Cocaine is a similar drug, in terms of mechanism and toxicity, to amphetamines. Both of cocaine and amphetamine are CNS stimulant and have similar action mechanisms; however cocaine is more cardio-toxic than METH and METH is more neurotoxic than cocaine. These reports confirm our results.

The use of ILE 70 min after an unsuccessful standard cardiopulmonary resuscitation in a 17-year-old girl, who developed seizures and cardiovascular collapse after an intentional ingesting of an overdose of bupropion, lamotrigine and amphetamine, improved her cardiovascular status and her neurologic function (34). Recently a middle-aged man was admitted to the hospital because of swallowing an egg-sized portion of METH (35). The patient's condition deteriorated shortly after admission with sympathomimetic poisoning and autonomic instability. He remained refractory to standard treatment, ILE at an amount of 100 ml could reverse the symptoms of toxicity, 20 min after infusion. These reports corroborate our results.

Our pathological finding showed that METH administration can cause bronchiolitis, emphysema and interstitial inflammation. Clinical studies have also revealed that METH intoxication induces acute lung injury, pulmonary edema and pulmonary congestion (36, 37). However, these pathological changes are more common in chronic abuse than acute. ILE infusion in this study could reduce METH-induced lung injuries. It should be mentioned that the administration of ILE at high doses can induce dose dependent pulmonary fat emboli (22). Acute respiratory distress syndrome (ARDS) has been reported as the most common pulmonary complication in resuscitated patients with ILE (38). Pulmonary complications associated with ILE infusion are related to lipid load and underlying pulmonary disease (22). ILE infusion released a high concentration of free-fatty acids into the blood stream (39, 40) that can induce impaired endothelium-dependent vasorelaxation and vasoconstriction (41). Pulmonary vasoconstriction and shunt have increased in patients with ARDS that received ILE infusion (42, 43). However, these effects have not been reported in patients with normal lung function (43, 44). METH is also a known potent vasoconstrictor and co-

administration of these two compounds, METH and ILE, in theory, may have synergic effect on lung complications. But in our research, ILE reduced the METH pulmonary inflammation and percentage of pulmonary cell apoptosis. A possible explanation for these results is the lipid sink theory.

The percentage of brain cell apoptosis was reduced in the ILE-treated group in comparison with the control group. METH is a potent neurotoxin and induces neuronal apoptosis especially at high doses (45). ILE could also reduce this METH complication as well as hyperthermia.

Conclusion

ILE could reduce the severity of METH- induced toxicity and mortality rate of animals by lipid sink theory or direct effect. Although the possible adverse effects of ILE and interferences with other rescue treatments should be considered, intravenous infusion of lipid emulsion may save the life of patients with acute METH intoxication who do not respond to initial treatment. Further human and animal studies are needed to determine the exact indications and their possible mechanisms.

Conflict of interest

The authors declare that they have no conflict of interest.

Acknowledgment

The authors are thankful to the Vice Chancellor for Research, Mashhad University of Medical Sciences and Iran National Science Foundation for their financial support. The results described in this paper were part of student thesis.

References

- Courtney KE, Ray LA. Methamphetamine: an update on epidemiology, pharmacology, clinical phenomenology, and treatment literature. *Drug Alcohol Depend* 2014; 143: 11-21.
- Cadet JL, Krasnova IN, Jayanthi S, Lyles J. Neurotoxicity of substituted amphetamines: molecular and cellular mechanisms. *Neurotox Res* 2007; 11: 183-202.
- Kiyatkin EA, Sharma HS. Acute methamphetamine intoxication: brain hyperthermia, blood-brain barrier, brain edema, and morphological cell abnormalities. *Int Rev Neurobiol* 2009; 88: 65-100.
- Cruickshank CC, Dyer KR. A review of the clinical pharmacology of methamphetamine. *Addiction* 2009; 104: 1085-99.
- Davis GG, Swalwell CI. The incidence of acute cocaine or methamphetamine intoxication in deaths due to ruptured cerebral (berry) aneurysms. *J Forensic Sci* 1996; 41: 626-8.
- Jang DH, Amphetamine. In: Hoffman RS, *et al*, Editors. *Goldfrank's Toxicologic Emergencies*. McGraw-Hill Professional: New York 2015 p. 1029-1037.
- Hallberg D, Holm I, Obel AL, Schuberth O, Wretling A. Fat emulsions for complete intravenous nutrition. *Postgrad Med J* 1967; 43: 307-16.
- Zhao M, Su M, Lin X, Luo Y, He H, Cai C, *et al*. Evaluation of docetaxel-loaded intravenous lipid emulsion: pharmacokinetics, tissue distribution, antitumor activity, safety and toxicity. *Pharm Res* 2010; 27:1687-702.
- Hippalgaonkar K, Majumdar S, Kansara V. Injectable lipid emulsions-advancements, opportunities and challenges. *AAPS PharmSciTech* 2010; 11:1526-40.
- Patlolla RR, Vobalaboina V. Pharmacokinetics and tissue distribution of etoposide delivered in parenteral emulsion. *J Pharm Sci* 2005; 94: 437-45.
- Bania TC, Antidotes in Depth, intravenous fat emulsion. In: Hoffman R S, *et al*, Editors. *Goldfrank's Toxicologic Emergencies*. McGraw-Hill Professional: New York. 2015 p. 976-710.
- Moshiri M, Vahabzadeh M, Mohammadpour A H, Hosseinzadeh H. Evaluation of intravenous lipid emulsion on haloperidol-induced hypotension in rabbits. *Toxicol Ind Health* 2016; 945-952.
- Vahabzadeh M, Moshiri M, Mohammadpour A H, Hosseinzadeh H. Promising effects of intravenous lipid emulsion as an antidote in acute tramadol poisoning. *Reg Anesth Pain Med* 2013; 38:425-430.
- Perez E, Bania T C, Medlej K, Chu J. Determining the optimal dose of intravenous fat emulsion for the treatment of severe verapamil toxicity in a rodent model. *Academic emergency medicine* 2008; 15: 1284-1289.
- Sanberg PR, Zoloty SA, Willis R, Ticarich CD, Rhoads K, Nagy RP, *et al*. Digiscan activity: automated measurement of thigmotactic and stereotypic behavior in rats. *Pharmacol Biochem Behav* 1987; 27:569-72.
- Etemad L, Jafarian AH, Moallem SA. Pathogenesis of Pregabalin-Induced Limb Defects in Mouse Embryos. *J Pharm Pharm Sci* 2015; 18:882-889.
- Ciechanowicz S, Patil V. Lipid emulsion for local anesthetic systemic toxicity. *Anesthesiol Res Pract* 2012; 2012:1-11.
- Rothschild L, Bern S, Oswald S, Weinberg G. Intravenous lipid emulsion in clinical toxicology. *Scand J Trauma Resusc Emerg Med* 2010; 18: 51.
- Tebbutt S, Harvey M, Nicholson T, Cave G. Intralipid prolongs survival in a rat model of verapamil toxicity. *Acad Emerg Med* 2006; 13: 134-139.
- Moshiri M, Vahabzadeh M, Etemad L, Hosseinzadeh H. Failure of Intravenous Lipid Emulsion to Reduce Diazinon-induced Acute Toxicity: a Pilot Study in Rats. *Iran J Pharm Res* 2013; 12:897-902.
- Yoav G, Odelia G, Shaltiel C. A lipid emulsion reduces mortality from clomipramine overdose in rats. *Vet Hum Toxicol* 2002; 44:30.
- Moshiri M, Mohammadpour AH, Vahabzadeh M, Etemad L, Memar B, Hosseinzadeh H. Evaluating the effects and safety of intravenous lipid emulsion on haloperidol-induced neurotoxicity in rabbit. *BioMed Res Inter* 2014; 2014:1-9.
- Arora NP, Berk WA, Aaron CK, Williams KA. Usefulness of intravenous lipid emulsion for cardiac toxicity from cocaine overdose. *Am J Cardiol* 2013; 111: 445-447.
- Weinberg G, Lin B, Zheng S, Di Gregorio G, Hiller D, Ripper R, *et al*. Partitioning effect in lipid resuscitation:

- further evidence for the lipid sink. *Crit Care Med* 2010; 38: 2268-2269.
25. French D, Smollin C, Ruan W, Wong A, Drasner K, Wu AH. Partition constant and volume of distribution as predictors of clinical efficacy of lipid rescue for toxicological emergencies. *Clin Toxicol (Phila)* 2011; 49: 801-809.
26. Harris DS, Boxenbaum H, Everhart ET, Sequeira G, Mendelson JE, Jones RT. The bioavailability of intranasal and smoked methamphetamine. *Clin Pharmacol Ther* 2003; 74:475-486.
27. Cook CE, Jeffcoat AR, Hill JM, Pugh DE, Patetta PK, Sadler BM, *et al*. Pharmacokinetics of methamphetamine self-administered to human subjects by smoking S-(+)-methamphetamine hydrochloride. *Drug Metab Dispos* 1993; 21:717-723.
28. Randrup A, Munkvad I, Udsen P. Adrenergic Mechanisms and Amphetamine Induced Abnormal Behaviour. *Acta Pharmacol Toxicol (Copenh)* 1963; 20: 145-157.
29. Harvey MG, Cave GR. Intralipid infusion ameliorates propranolol-induced hypotension in rabbits. *J Med Toxicol* 2008; 4:71-76.
30. Weinberg GL, VadeBoncouer T, Ramaraju GA, Garcia-Amaro MF, Cwik MJ. Pretreatment or resuscitation with a lipid infusion shifts the dose-response to bupivacaine-induced asystole in rats. *Anesthesiology* 1998; 88:1071-1075.
31. Calenda E, Dinescu SA. Failure of lipid emulsion to reverse neurotoxicity after an ultrasound-guided axillary block with ropivacaine and mepivacaine. *J Anesth* 2009; 23:472-3.
32. Zimmer C, Piepenbrink K, Riest G, Peters J. Cardiotoxic and neurotoxic effects after accidental intravascular bupivacaine administration. Therapy with lidocaine propofol and lipid emulsion. *Anaesthesist* 2007; 56:449-453.
33. Jakkala-Saibaba R, Morgan PG, Morton GL. Treatment of cocaine overdose with lipid emulsion. *Anaesthesia* 2011; 66: 168-1170.
34. Sirianni AJ, Osterhoudt KC, Calello DP, Muller AA, Waterhouse MR, Goodkin MB, *et al*. Use of lipid emulsion in the resuscitation of a patient with prolonged cardiovascular collapse after overdose of bupropion and lamotrigine. *Ann Emerg Med* 2008; 51:412-415.
35. Tse J, Ferguson K, Whitlow KS, Erickson K. The use of intravenous lipid emulsion therapy in acute methamphetamine toxicity. *Am J Emerg Med* 2015; 1732.e3-1732.e4.
36. Derlet RW, Rice P, Horowitz BZ, Lord RV. Amphetamine toxicity: experience with 127 cases. *J Emerg Med* 1989; 7:157-161.
37. Inoue H, Ikeda N, Kudo K, Ishida T, Terada M, Matoba R. Methamphetamine-related sudden death with a concentration which was of a 'toxic level'. *Leg Med (Tokyo)* 2006; 8:150-155.
38. Levine M, Sholnik AB, Ruha AM, Bosak A, Menke N, Pizon AF. Complication following antidotal use of intravenous lipid emulsion therapy. *J Med Toxicol* 2014; 10:10-14.
39. Karpe F, Olivecrona T, Olivecrona G, Samra JS, Summers LK, Humphreys SM, *et al*. Lipoprotein lipase transport in plasma: role of muscle and adipose tissues in regulation of plasma lipoprotein lipase concentrations. *J Lipid Res* 1998; 39:2387-93.
40. Peterson J, Bihain BE, Bengtsson-Olivecrona G, Deckelbaum RJ, Carpentier YA, Olivecrona T. Fatty acid control of lipoprotein lipase: a link between energy metabolism and lipid transport. *Proc Natl Acad Sci USA* 1990; 87:909-913.
41. Sloboda N, Feve B, Thornton SN, Nzietchueng R, Regnault V, Simon G, *et al*. Fatty acids impair endothelium-dependent vasorelaxation: a link between obesity and arterial stiffness in very old Zucker rats. *J Gerontol A Biol Sci Med Sci* 2012; 67:927-38.
42. Venus B, Prager R, Patel CB, Sandoval E, Sloan P, Smith RA. Cardiopulmonary effects of Intralipid infusion in critically ill patients. *Crit Care Med* 1988; 16:587-590.
43. Hwang TL, Huang SL, Chen MF. Effects of intravenous fat emulsion on respiratory failure. *Chest* 1990; 97:934-938.
44. Lekka ME, Liokatis S, Nathanail C, Galani V, Nakos G. The impact of intravenous fat emulsion administration in acute lung injury. *Am J Respir Crit Care Med* 2004; 169: 638-644.
45. Qiao D, Xu J, Le C, Huang E, Liu C, Qiu P, *et al*. Insulin-like growth factor binding protein 5 (IGFBP5) mediates methamphetamine-induced dopaminergic neuron apoptosis. *Toxicol Lett* 2014; 230: 444-453.