

Reno-protective effect of *Rheum turkestanicum* against gentamicin-induced nephrotoxicity

Mohammad Taher Boroushaki¹, Sahar Fanoudi¹, Hamid Mollazadeh², Samaneh Boroumand-Noughabi^{3,4}, Azar Hosseini^{5*}

¹ Department of Pharmacology, Faculty of Medicine, Mashhad University of Medical Sciences, Mashhad, Iran

² Department of Physiology and Pharmacology, School of Medicine, North Khorasan University of Medical Sciences, Bojnurd, Iran

³ Department of Pathology, Faculty of Medicine, Mashhad University of Medical Sciences, Mashhad, Iran

⁴ Department of Hematology and Blood Banking, Faculty of Medicine, Mashhad University of Medical Sciences, Mashhad, Iran

⁵ Pharmacological Research Center of Medicinal Plants, Mashhad University of Medical Sciences, Mashhad, Iran

ARTICLE INFO

Article type:

Short communication

Article history:

Received: Apr 30, 2018

Accepted: Sep 17, 2018

Keywords:

Rheum turkestanicum

Gentamicin

Reactive oxygen species

Malondialdehyde

Oxidative stress

ABSTRACT

Objective(s): Gentamicin belongs to the family of aminoglycoside antibiotics and is a preferred drug in developing countries because of its low cost, availability, and potent effects against bacterial. However, gentamicin can induce nephrotoxicity. In this research, hydroalcoholic extract of *Rheum turkestanicum* was used against gentamicin-induced nephrotoxicity and its effect against gentamicin-induced nephrotoxicity in rats has been investigated.

Materials and Methods: The rats were placed into one of these groups: saline group, gentamicin group that received gentamicin 80 mg/kg/day for six days, and two treatment groups that received *R. turkestanicum* intraperitoneally at doses of 100 and 200 mg/kg body weight, respectively, 1 hr before gentamicin injections. Urine samples were collected at 24 hr to measure glucose and protein concentration. Blood samples were collected to determine serum urea and creatinine. One kidney was homogenized to measure malondialdehyde and thiol, and the other kidney was kept for pathological studies.

Results: Gentamicin increased the level of urinary glucose and protein, and increased malondialdehyde while it decreased thiol in kidney tissue, and increased the concentration of urea and creatinine in the serum. Histopathological pathology revealed renal damage following gentamicin usage; however, the extract was able to improve gentamicin toxicity.

Conclusion: *R. turkestanicum* has positive effects in the attenuation of gentamicin-induced nephrotoxicity.

► Please cite this article as:

Boroushaki MT, Fanoudi S, Mollazadeh H, Boroumand-Noughabi S, Hosseini A. Reno-protective effect of *Rheum turkestanicum* against gentamicin-induced nephrotoxicity. Iran J Basic Med Sci 2019; 22:328-333. doi: 10.22038/ijbms.2019.31552.7597

Introduction

Gentamicin as an antibiotic is used in the treatment of Gram-negative infections although its usage is limited because of serious adverse effects such as nephrotoxicity. About 30% of individuals who have consumed gentamicin have developed symptoms of renal dysfunction (1). The accurate mechanism of renal toxicity is not clear and studies have shown that the generation of reactive oxygen species (ROS), reactive nitrogen species (RNS), decreasing of antioxidant enzymes, induction of inflammatory pathways, reduction of renal blood flow due to the contraction of mesangial cells that lead to tubular necrosis, damage to cells, infiltration of leukocytes, and reduction of glomerular filtration rate (GFR) can play roles in gentamicin toxicity (1-3).

According to the roles of oxidative stress and inflammation in gentamicin toxicity, antioxidant and anti-inflammatory agents may reduce renal toxicity. Herbal medicines are composed of different compounds that have pharmacological properties such as antioxidant and anti-inflammatory, as a result these compounds may play a role in decreasing gentamicin-induced nephrotoxicity. Recent studies have shown

Pistacia vera (4), *Bauhinia purpurea* (5), *Ferulago angulate* (6), grape seed (7), *Zingiber officinales* (8), *Crocus sativus* (9), crocin (10), green tea (11), saffranal (12), pomegranate seed oil (13), and other herbs can reduce gentamicin nephrotoxicity by their antioxidant action.

In Chinese medicines, the *Rheum* species (polygonaceae) have a long history in the treatment of diseases. The main active ingredients of the *Rheum* species (with varying degrees of antioxidant properties) are a series of anthraquinones, dianthrone, glycosides, and tannins. The anthraquinone derivatives are emodin, rhein, chrysophanol, physcion, alizarin, citreosein, and aloe-emodin (14). *Rheum turkestanicum* (*R. turkestanicum*) belongs to the polygonaceae family and is found in central Asia and the northeast of Iran. In traditional Iranian medicine, this herb is used to treat hypertension and diabetes. Recent studies have shown antidiabetic (15) and protective effects against doxorubicin (16).

R. turkestanicum contains high amount of polyphenolic and flavonoid compounds that act as potent antioxidants (15). Recent studies have shown some of the *Rheum* species and its active ingredients

*Corresponding author: Azar Hosseini. Pharmacological Research Center of Medicinal Plants, Mashhad University of Medical Sciences, Mashhad, Iran. Tel: +98-51-38002283; Fax: +98-51-38828567; Email: Hoseini@ijbms.mums.ac.ir

have nephro-protective effects against metals (17). Considering the antioxidant activity of *R. turkestanicum*, in this study we investigated the effect of this herbal plant against gentamicin-induced nephrotoxicity in rats.

Materials and Methods

2,2'-dinitro-5,5'-dithiodibenzoic acid (DTNB), 2-thiobarbituric acid (TBA), n-butanol, sodium hydroxide (NaOH), sodium chloride (NaCl), ethylenediaminetetraacetic acid disodium salt (Na₂EDTA), Tris, phosphoric acid, HCl, potassium chloride (KCl), and ether were obtained from Merck (Darmstadt, Germany). Gentamicin was purchased from DarouPakhsh Co (Tehran, Iran).

Preparation of the extract

The roots of *R. turkestanicum* Janisch. were obtained from Chenar, a village in Zavain Rural District, Kalat County, Razavi Khorasan Province, Iran. Identification and authentication was done by M R Joharchi, Ferdowsi University of Mashhad Herbarium (voucher specimen No 21377). The dried and fine roots (50 g) were extracted with 70% ethanol in a Soxhlet apparatus for 48 hr. The hydro-alcoholic extract obtained in the previous step was dried on a water bath, and then stored at -18 °C in a freezer. The extraction yield was 19% (w/w).

Experimental

Twenty-four adult male Wistar rats (250-300 g) were purchased from the animal house of the Mashhad University of Medical Sciences (MUMS) and kept in cages at 20±4 °C temperature in a 12 hr light/12 hr dark cycle with *ad libitum* access to food and water. All experimental protocols were in accordance with the guidelines and standards of animal care approved by the Ethics Committee of MUMS. All the rats were randomly divided into four groups of six and were treated according to the following protocol: the control group that received normal saline (1 ml/kg, IP), the gentamicin group that received gentamicin 80 mg/kg/day for six days, two treatment groups that received *R. turkestanicum* hydro-alcoholic extract IP at doses of 100 and 200 mg/kg, respectively, 1 hr before gentamicin injections [doses of extract based on a previous study, (15)]. On the seventh day, 24-hr urine samples were collected using metabolic cages to measure glucose and protein excretion. Twenty-four hours after the last injection of gentamicin (with 12 hr fasting consideration), the animals in all groups were anaesthetized with an injection of ketamine (95 mg/kg) and xylasin (5 mg/kg). Then they were euthanized and blood samples were obtained by cardiac puncture to evaluate the serum urea and creatinine. Both kidneys were removed, and the left kidney was homogenized in cold KCl solution (1.5%, pH 7) to give a 10% homogenate, and used for suspension to measure malondialdehyde (MDA) and thiol content. Next, the right kidney was processed for histopathological studies.

Biochemical analysis

Urea concentration was estimated colorimetrically using an auto-analyzer (Technicon RA-1000, England) and urea kit (Man Lab Company, Tehran, I R Iran). Creatinine concentration was determined by the Jaffe's

method (18). Urine glucose levels were measured by the enzymatic assay (glucose oxidase) and protein concentration was estimated according to the turbidimetric method (19, 20).

Malondialdehyde (MDA) assay

Thiobarbituric acid reactive substances (TBARS), products of LPO, were determined as the malondialdehyde (MDA) equivalent, which reacts with TBA and produces a red complex with a peak absorbance at 532 nm (21). A mixture of 3 ml phosphoric acid (1 %) and 1 ml TBA (0.6 %) was added to 0.5 ml of homogenate, and the mixture was heated for 45 min in a boiling water bath. After cooling, 4 ml of n-butanol was added to the mixture, vortexed for 1 min, and then centrifuged for 20 min at 20,000 rpm. Then, the absorbance of the organic layer was measured at 532 nm. The standard curve of the MDA was plotted over the concentration range of 0–40 μM (22).

Total thiol content assay

Total thiol content was estimated using DTNB as the reagent. This reagent reacts with the SH groups and produces a yellow complex that has a peak absorbance at 412 nm. The 1 ml Tris-ethylenediaminetetraacetic acid (EDTA) buffer was added to 50 μl of kidney homogenate, and absorbance was read at 412 nm against the Tris-EDTA buffer alone (A₁). Then, 20 μl DTNB reagent (10 mM in methanol) was added to the mixture, and after 10 min, the sample absorbance was read again (A₂). The absorbance of the DTNB reagent was also read and considered as a blank (B). Total thiol concentration (mM) was calculated from the following equation (20):

$$\text{Total thiol concentration (mM)} = (A_2 - A_1 - B) \times 1.07 / 0.05 \times 13.6$$

Histological study

The right kidney was prepared for histopathological examination. The kidney tissues were fixed in 10% formalin, dehydrated, cleared and embedded in paraffin wax. Sections of 5 μm thick were cut and stained with haematoxylin and eosin (H&E) for light microscope (LM) studies (23).

Statistical analysis

The results are shown as mean±standard error of the mean (SEM). Statistical analysis was performed using the one-way analysis of variance (ANOVA) followed by the Tukey–Kramer *post hoc* test for multiple comparisons. The *P*-values less than 0.05 were considered to be statistically significant. The experiment was carried out in triplicate.

Results

Effects of *R. turkestanicum* on serum urea and creatinine

In comparison with the control group, gentamicin increased the level of creatinine and urea (*P*<0.0001). On the other hand, the *R. turkestanicum* extract significantly reduced serum creatinine (100 mg/kg, *P*<0.01; 200 mg/kg, *P*<0.001) and serum urea (100 mg/kg, *P*<0.05; 200 mg/kg, *P*<0.01) in comparison with gentamicin (Figure 1).

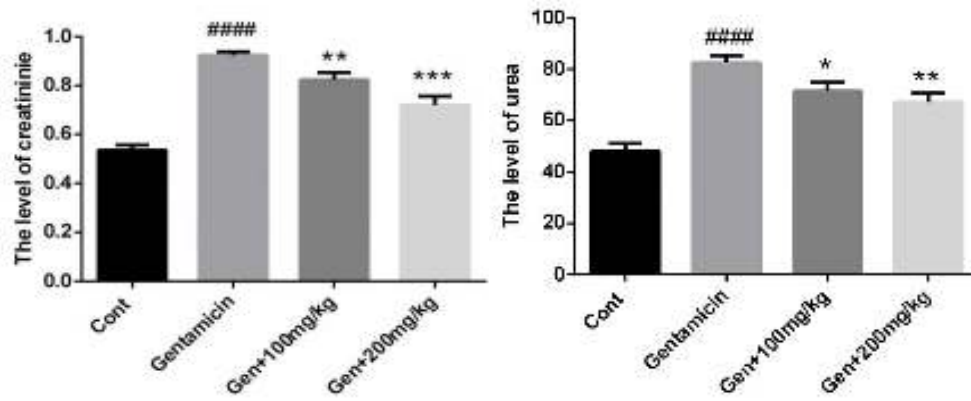


Figure 1. Effect of *Rheum turkestanicum* on serum creatinin and urea after gentamicin administration. The creatinine and urae were determined in the serum. Data were expressed as mean±SEM. #### $P<0.001$ in cmparison with control group. * $P<0.05$, ** $P<0.01$ and *** $P<0.001$ in comparison with gentamicin treated group

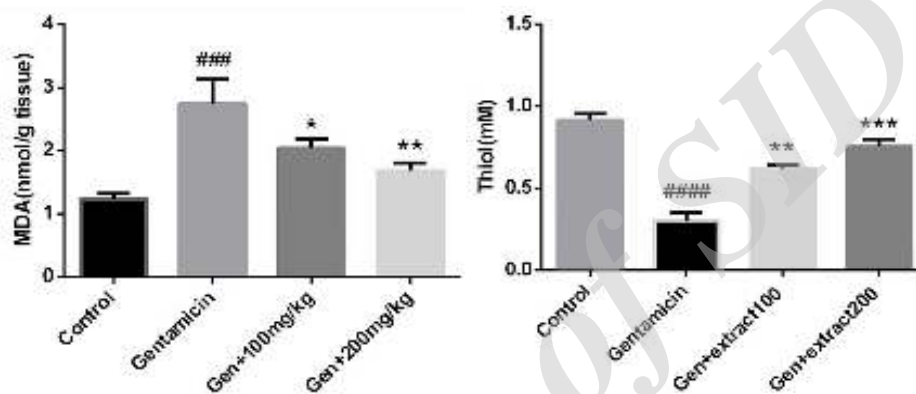


Figure 2. Effect of *Rheum turkestanicum* on MDA and thiol in kidney tissue after gentamicin administration. The level of MDA and thiol were measured in kidney tissue. Data were expressed as mean±SEM. ### $P<0.001$ in cmparison with control group. * $P<0.05$, ** $P<0.01$ and *** $P<0.001$ in comparison with gentamicin

Effects of *R. turkestanicum* on MDA and thiol in kidney tissue

Lipid peroxidation was evaluated by the determination of MDA in the kidney. Also, the content of thiol was measured. As shown in Figure 2, gentamicin increased MDA ($P<0.001$) and decreased thiol content in the kidney ($P<0.0001$) compared to the control group. The extract prevented the toxicity of gentamicin via decreasing of MDA and increasing of thiol in the kidney. The extract reduced MDA at a dose of 100 mg/kg

($P<0.05$) and 200 mg/kg ($P<0.01$), while it increased the content of thiol at applied doses (100 mg/kg, $P<0.01$; 200 mg/kg, $P<0.001$) (Figure 2).

Effects of *R. turkestanicum* on urine glucose and protein concentration

As shown in Figure 3, gentamicin increased the urinary protein ($P<0.0001$) and glucose ($P<0.0001$) in comparison with the control group. The extract decreased the urinary glucose at doses of 100 mg/kg

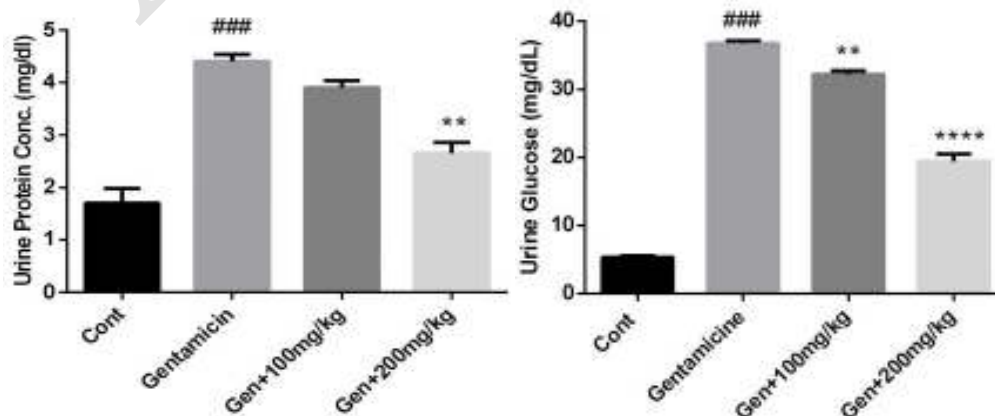


Figure 3. The measurement of glucose and protein in urine. Data were expressed mean±SEM. ### $P<0.001$ in cmparison with control group. ** $P<0.01$ and **** $P<0.0001$ in comparison with gentamicin

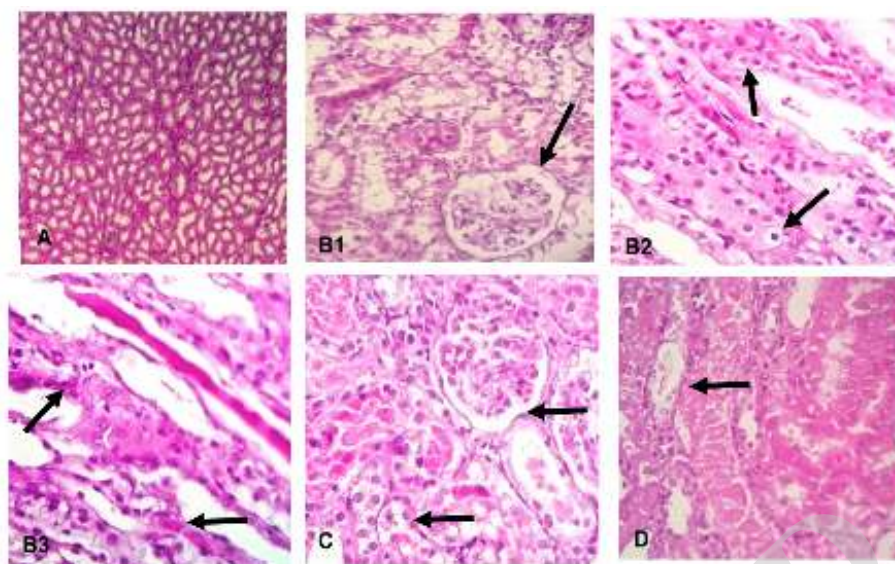


Figure 4. The pathological changes of kidney tissue after gentamicin exposure and *R. turkestanicum* pretreatment. A) normal kidney tissue (100, B1) gentamicin with hydropic degeneration (3+), B2) gentamicin with RBC cast (2+), B3) gentamicin with hyalin cast (1+), C) 100 mg/kg +gentamicin showed necrosis (2+) and D) 100 mg/kg +gentamicin showed necrosis (1+). The + sign shows the severity of injury. 1+ (mild), 2+ (moderate) and 3+ (sever). (Magnification: A: 100× and B1 to D: 400×)

($P < 0.01$) and 200 mg/kg ($P < 0.0001$), while the urinary protein was reduced at a dose of 200 mg/kg ($P < 0.01$) by the extract (Figure 3).

Effects of *R. turkestanicum* on histopathological changes in the kidney

The histopathological studies showed that gentamicin caused hydropic degeneration and red blood cell (RBC) and hyalin casts with different severity. Pretreatment of rats with *R. turkestanicum* reduced damages, especially at a dose of 200 mg/kg (Figure 4).

Discussion

Our findings showed the protective effects of *R. turkestanicum* against nephrotoxicity, induced by gentamicin. In this research, gentamicin increased the level of MDA, urinary protein, urinary glucose, serum creatinine, and urea, while it decreased the level of thiol in the kidney tissue. Recent studies have confirmed our observations (24). The extract of *R. turkestanicum* prevented nephrotoxicity of gentamicin by increasing thiol, and decreasing MDA, serum urea, creatinine, urinary glucose, and protein. Also, the extract reduced histopathological changes relatively.

Aminoglycosides are used as common antibiotics in diseases induced by Gram-negative pathogens (25). The consumption of these antibiotics has been limited in recent years due to side effects such as nephrotoxicity and ototoxicity. In developing countries, the use of gentamicin is common because of its availability, effectiveness, and cost (26). Different mechanisms play a role in gentamicin toxicity, but the most important is the production of ROS such as hydroxide and hydrogen peroxide that damage renal cells (27). Gentamicin also causes a reduction of antioxidant enzyme activity, leading to lipid peroxidation production, and alerts morphological and functional cells (28, 29).

According to the role of ROS in gentamicin toxicity, using antioxidant compounds can be effective in reducing

the level of toxicity. Medicinal herbs are composed of many ingredients with different pharmacological effects such as antioxidant activity, which could decrease gentamicin toxicity. Recent studies have reported several medicinal herbs have a nephroprotective effect against gentamicin. These herbs include pomegranate seed oil (13), *Rheum emodi* (17), green tea (10), crocin (11), *Zingiber officinale* (8), grape seed (7) and *Punica granatum* (30). One of the herbal medicines that is used in traditional medicine is *R. turkestanicum*. The polyphenol ingredients such as anthocyanins, anthraquinones, flavanols, and stilbenes are found in various species of the genus *Rheum* (14). The medicinal use of this species is mainly related to the presence of several secondary metabolites such as anthracenes (emodin, fission, chrysophanol, aloe-emodin, and rhein derivatives), stilbenes (resveratrol, rhapontigenin, piceatannol, and its derivatives), naphthalenes, and chromones in the underground parts of the plants. Most of the components have antioxidant activities and lead to protective effects against toxicological agents. Hosseini *et al.* showed the protective effects of *R. turkestanicum* against doxorubicin in H9c2 cells (16). Also, the protective effects of *R. turkestanicum* were shown in STZ-diabetic rats by increasing thiol (15). The antioxidant activity of *R. turkestanicum* ethyl acetate extract (of the root) is related to the content of rhododendron. Dehghan *et al.* has shown that rhododendrin is active against DPPH (1,1-diphenyl-2-picrylhydrazyl radical scavenging activity, 64.3%), similar to BHT (butylated hydroxytoluene acts as a standard antioxidant, 67.3%), ($IC_{50} = 95.7 \mu\text{M}$) (31). *R. emodi* as another plant in this genus and similar to *R. turkestanicum*, has shown potent antioxidant activity and reno-protective effects against metals such as cadmium, mercuric chloride and gentamicin (17, 32, 33).

The studies have shown which presence of antioxidant compounds such as anthraquinones (anthracenosides) and tannins in *R. emodi* and *R. officinale* can reduce

nephrotoxicity by the scavenging of free radicals (34, 35). According to the presence of tannins in *R. turkestanicum*, probably the protective effect of *R. turkestanicum* is related to its components and other ingredients that have antioxidant activities.

In the present study, a significant reduction in lipid peroxidation (MDA is a stable metabolite of lipid peroxidation caused by oxidative stress) and increase in the level of thiol contents (an important part of the structural proteins and nonprotein compounds plays a vital role in cellular processes such as enzyme activity and restoration of cellular pathways and mechanisms in cell detoxification) of the cells were observed after using the extract (36). Due to the main role of oxidative stress in the induction and progression of nephrotoxicity that was shown in many studies, it can be concluded that the use of antioxidant compounds could reverse this toxicity.

Conclusion

The results of this study showed that *R. turkestanicum* hydroalcoholic extract attenuated gentamicin-induced nephrotoxicity. This is supported by the improvement of serum and urinary markers of renal function and the decrease of protein and lipid damage, but the explanation and mechanism of this defense need further explorations.

Acknowledgment

This work was supported by a grant (No 940178) from the Vice-Chancellor for Research and Technology, Mashhad University of Medical Sciences, Iran. This research did not receive any specific grant from funding agencies in the public, commercial, or not-for-profit sectors.

Conflict of Interest

The authors declare that they have no conflict of interest.

References

- Martinez-Salgado C, López-Hernández FJ, López-Novoa JM. Glomerular nephrotoxicity of aminoglycosides. *Toxicol Appl Pharmacol* 2007;223:86-98.
- Balakumar P, Rohilla A, Thangathirupathi A. Gentamicin-induced nephrotoxicity: do we have a promising therapeutic approach to blunt it? *Pharmacol Res* 2010; 62:179-186.
- Lopez-Novoa JM, Quiros Y, Vicente L, Morales AI, Lopez-Hernandez FJ. New insights into the mechanism of aminoglycoside nephrotoxicity: an integrative point of view. *Kidney Int* 2011; 79:33-45.
- Ehsani V, Amirteimoury M, Taghipour Z, Shamsizadeh A, Bazmandegan G, Rahnema A, et al. Protective effect of hydroalcoholic extract of *Pistacia vera* against gentamicin-induced nephrotoxicity in rats. *Ren Fail* 2017; 39:519-525.
- Lakshmi B, Neelima N, Kasthuri N, Umarani V, Sudhakar M. Protective effect of *Bauhinia purpurea* on gentamicin-induced nephrotoxicity in rats. *Indian J Pharm Sci* 2009; 71:551-554.
- Valipour P, Heidarian E, Khoshdel A, Gholami-Arjenaki M. Protective effects of hydroalcoholic extract of *Ferulago angulata* against gentamicin-induced nephrotoxicity in rats. *Iran J Kidney Dis* 2016;10:189-196.
- Safa J, Argani H, Bastani B, Nezami N, Ardebili BR, Ghorbanihaghjo A, et al. Protective effect of grape seed extract on gentamicin-induced acute kidney injury. *Iran J Kidney Dis* 2010; 4:285-291.
- Lakshmi B, Sudhakar M. Protective effect of *Zingiber officinale* on gentamicin-induced nephrotoxicity in rats. *Int J Pharmacol* 2010; 6:58-62.
- Ajami M, Eghtesadi S, Pazoki-Toroudi H, Habibey R, Ebrahimi SA. Effect of *Crocus sativus* on gentamicin induced nephrotoxicity. *Biol Res* 2010; 43:83-90.
- Khan SA, Priyamvada S, Farooq N, Khan S, Khan MW, Yusufi AN. Protective effect of green tea extract on gentamicin-induced nephrotoxicity and oxidative damage in rat kidney. *Pharmacol Res* 2009; 59:254-262.
- Yarijani ZM, Najafi H, Madani SH. Protective effect of crocin on gentamicin-induced nephrotoxicity in rats. *Iran J Basic Med Sci* 2016; 19:337-343.
- Boroushaki MT, Sadeghnia HR. Protective effect of safranal against gentamicin-induced nephrotoxicity in rat. *Iran J Basic Med Sci* 2015; 34:285-288.
- Boroushaki MT, Asadpour E, Sadeghnia HR, Dolati K. Effect of pomegranate seed oil against gentamicin-induced nephrotoxicity in rat. *J Food Sci Technol* 2014; 51:3510-3514.
- Dorsey JF, Kao GD. Aloe (-emodin) for cancer? More than just a comforting salve. *Cancer Biol Ther* 2007; 6:89-90.
- Hosseini A, Mollazadeh H, Amiri MS, Sadeghnia HR, Ghorbani A. Effects of a standardized extract of *Rheum turkestanicum* Janischew root on diabetic changes in the kidney, liver and heart of streptozotocin-induced diabetic rats. *Biomed Pharmacother* 2017; 86:605-611.
- Hosseini A, Rajabian A. Protective effect of *Rheum turkestanicum* root against doxorubicin-induced toxicity in H9c2 cells. *Revista Brasileira de Farmacognosia* 2016; 26:347-351.
- Alam MA, Javed K, Jafri M. Effect of *Rheum emodi* (Revand Hindi) on renal functions in rats. *J Ethnopharmacol* 2005; 96:121-125.
- Masson P, Ohlsson P, Björkhem I. Combined enzymic-Jaffé method for determination of creatinine in serum. *Clin Chem* 1981; 27:18-21.
- Lott JA, Turner K. Evaluation of Trinder's glucose oxidase method for measuring glucose in serum and urine. *Clin Chem* 1975; 21:1754-60.
- McElderry L, Tarbit I, Cassells-Smith A. Six methods for urinary protein compared. *Clin Chem* 1982; 28:356-60.
- Fernández J, Pérez-Álvarez JA, Fernández-López JA. Thiobarbituric acid test for monitoring lipid oxidation in meat. *Food Chem* 1997; 59:345-53.
- Hosseinzadeh H, Sadeghnia HR, Ziaee T, Danaee A. Protective effect of aqueous saffron extract (*Crocus sativus* L.) and crocin, its active constituent, on renal ischemia-reperfusion-induced oxidative damage in rats. *J Pharm Pharm Sci* 2005; 8:387-393.
- Oda SS, El-Ashmawy IM. Protective effect of silymarin on mercury-induced acute nephro-hepatotoxicity in rats. *Global Veterinaria* 2012; 9:376-383.
- Banday AA, Farooq N, Priyamvada S, Yusufi AN, Khan F. Time dependent effects of gentamicin on the enzymes of carbohydrate metabolism, brush border membrane and oxidative stress in rat kidney tissues. *Life Sci* 2008; 82:450-459.
- Xie J, Talaska AE, Schacht J. New developments in aminoglycoside therapy and ototoxicity. *Hear Res* 2011; 281:28-37.
- Riff LJ, Jackson GG. Pharmacology of gentamicin in man. *J Infect Dis* 1971; 124:S98-S105.
- Sahu BD, Tatireddy S, Koneru M, Borkar RM, Kumar JM, Kuncha M, et al. Naringin ameliorates gentamicin-induced nephrotoxicity and associated mitochondrial dysfunction, apoptosis and inflammation in rats: possible mechanism of nephroprotection. *Toxicol Appl Pharmacol* 2014; 277:8-20.
- Alarifi S, Al-Doaiss A, Alkahtani S, Al-Farraj S, Al-Eissa MS, Al-Dahmash B, et al. Blood chemical changes and renal

- histological alterations induced by gentamicin in rats. Saudi J Biol Sci 2012; 19:103-110.
29. Sahu BD, Kuncha M, Putcha UK, Sistla R. Effect of metformin against cisplatin induced acute renal injury in rats: a biochemical and histoarchitectural evaluation. Exp Toxicol Pathol 2013; 65:933-940.
30. Biswas D, Rathod NS, Halagali K, Nidavani R, Shalavadi M, Biradar B, et al. Protective effect of *Punica granatum* l. on gentamicin-induced acute renal failure in adult rats. Res J Pharmacol Pharmacodyn 2016; 8:161-167.
31. Dehghan H, Salehi P, Amiri MS. Bioassay-guided purification of α -amylase, α -glucosidase inhibitors and DPPH radical scavengers from roots of *Rheum turkestanicum*. Ind Crops Prod 2018; 117: 303-309.
32. Mishra SK, Tiwari S, Shrivastava A, Srivastava S, Boudh GK, Chourasia SK, et al. Antidyslipidemic effect and antioxidant activity of anthraquinone derivatives from *Rheum emodi* rhizomes in dyslipidemic rats. J Nat Med 2014; 68:363-371.
33. Chai YY, Wang F, Li YL, Liu K, Xu H. Antioxidant activities of stilbenoids from *Rheum emodi* Wall. Evid Based Complement Alternat Med 2012; 2012:603678.
34. Yokozawa T, Fujioka K, Oura H, Nonaka G-i, Nishioka I. Effects of rhubarb tannins on uremic toxins. Nephron 1991; 58:155-160.
35. Yokozawa T, Nakagawa T, Lee Ki, Cho Ej, Terasawa K, Takeuchi S. Effects of green tea tannin on cisplatin-induced nephropathy in LLC-PK1 cells and rats. J Pharm Pharmacol 1999; 51:1325-1331.
36. Boroushaki MT, Mollazadeh H, Rajabian A, Dolati K, Hosseini A, Paseban M, et al. Protective effect of pomegranate seed oil against mercuric chloride-induced nephrotoxicity in rat. Ren Fail 2014; 36: 1581-1586

Archive of SID