

Pioglitazone abrogates testicular damage induced by testicular torsion/detorsion in rats

Nevertyty Mohamed Mahmoud ^{1*}, Soad Lotfy Kabil ¹

¹ Department of Pharmacology, Faculty of Medicine, Zagazig University, Egypt

ARTICLE INFO	ABSTRACT
<p>Article type: Original article</p> <p>Article history: Received: Jul 5, 2018 Accepted: Feb 19, 2019</p> <p>Keywords: Apoptosis Inflammation Ischemia Pioglitazone Reperfusion Testis</p>	<p>Objective(s): Testicular torsion/detorsion (T/D) is a well-known cause for infertility. Pioglitazone is an agonist of peroxisome proliferator activated receptor-gamma (PPAR-γ). Previous studies have shown that pioglitazone has anti-inflammatory, antioxidant and antiapoptotic properties. The present study hypothesized that pioglitazone may be protective against the testicular T/D tissue insults, and the possible pathophysiological mechanisms involved in this effect were also investigated.</p> <p>Materials and Methods: Rats were randomly divided into four groups: sham group, T/D group where testicular torsion was performed for 4 hr followed by 4 hr of detorsion and two pioglitazone-treated groups (1 mg/kg and 3 mg/kg, by single intraperitoneal injection 30 min prior to detorsion). At the end of reperfusion period, blood, ipsilateral and contralateral testicular tissue samples were obtained for biochemical and histopathological examination.</p> <p>Results: Pioglitazone reduced oxidative tissue damages, inflammatory mediators, and apoptotic markers and enhanced the total antioxidant status, and AMP-activated protein kinase level. Moreover, pioglitazone improved spermatogenesis evidenced by increased Johnsen's score and reversed the histopathological damages induced by testicular T/D. The effects of pioglitazone were higher with the dose of 3 mg/kg.</p> <p>Conclusion: Pioglitazone exhibited a protective effect against the deleterious actions of testicular T/D. This beneficial potential of pioglitazone may be attributed to its antioxidant, anti-inflammatory and antiapoptotic properties, which was more obvious with the dose of 3 mg/kg. Pioglitazone may be a promising therapy for testicular T/D.</p>

► Please cite this article as:

Mahmoud NM, Kabil SL. Pioglitazone abrogates testicular damage induced by testicular torsion/detorsion in rats. Iran J Basic Med Sci 2019; 22:884-892. doi: 10.22038/ijbms.2019.33199.7929

Introduction

Torsion of spermatic cord is one of the most serious urological emergencies (1). Torsion - associated ischemia can lead to germ cell death. Although reperfusion is essential for survival of testicular cells, it is assumed to be responsible for bad prognosis, a phenomenon called ischemia - reperfusion (I/R) injury (2). Reperfusion is associated with over release of reactive oxygen species (ROS) (3), in addition to pro-inflammatory cytokines release including interleukin-6 (IL-6) and tumor necrosis factor- α (TNF- α), chemokines (monocyte chemoattractant protein-1 (MCP-1)) and cell adhesion molecules which results in recruitment of neutrophils and macrophages. ROS stimulate oxidative stress by oxidizing mitochondrial membranes, cell membrane lipids, proteins, and DNA, leading to cellular dysfunction, which is followed by germ cell apoptosis (4, 5). Sequel of spermatic cord torsion dose not only affect ipsilateral testis but also extends to contralateral testis. Pioglitazone is an agonist of peroxisome proliferator activated receptor-gamma (PPAR- γ), which is a member of nuclear hormone receptor superfamily. PPAR- γ regulates expression of genes involved in several physiological and pathological processes, such as glucose homeostasis, cellular differentiation, regulation of lipid metabolism, atherosclerosis, infertility, and inflammation (6). In a recent study, it was

demonstrated that therapeutic effects of pioglitazone reach far beyond its use as an insulin sensitizer; several evidences revealed that pioglitazone attenuates I/R tissue insults in heart, brain and kidney (7). To the best of our knowledge, this study is the first to evaluate the possible protective potential of pioglitazone in testicular torsion-detorsion (T/D) injury. So, the current study hypothesized that pioglitazone may possess a protective effect against testicular T/D tissue damages, and the possible underlying mechanisms were investigated.

Materials and Methods

Drugs and chemicals

Pioglitazone and carboxy methylcellulose (1%, vehicle of pioglitazone) were purchased from Sigma- Aldrich. (St Louis, MO, USA). Ketamine (5%) was purchased from Sigma-Tec Pharmaceutical Industries (6th of October City, Giza, Egypt). Xylazine (2%) was purchased from ADWIA Co. (10th of Ramadan City, Egypt).

Animals

Twenty-four adult male Wistar rats weighing 230–250 g were purchased from Faculty of Veterinary Medicine, Zagazig University. Rats were housed at the animal house, Faculty of Medicine, Zagazig University under standard laboratory conditions at a temperature of 22±2 °C, relative humidity of 60%, 12-hr light-dark

*Corresponding author: Nevertyty Mohamed Mahmoud. Department of Pharmacology, Faculty of Medicine, Zagazig University, Egypt. Tel: 00201061329496; Email: Nevertytymohamed@yahoo.com

cycle and supplemented with commercial rodent chow and water *ad libitum*. Rats were acclimatized for 1 week before the experiment. The study was performed in Department of Pharmacology, Faculty of Medicine, Zagazig University. All experimental procedures were approved by the local Ethics Committee of Zagazig University, Egypt (IRB: 4183) and in accordance with National Institutes of Health guide for care and use of Laboratory animals (NIH Publications No. 8023, revised 1978).

Study design

24 male Wistar rats were randomly allocated into 4 groups (6 rats each): sham group where rats subjected to surgical stress without testicular T/D and received carboxymethyl cellulose (1%) intraperitoneally (IP); testicular T/D group: rats were subjected to testicular torsion for 4 hr then testicular detorsion for another 4 hr and received carboxymethyl cellulose (1%) IP; pioglitazone group (Pio 1): rats treated with a single IP injection of pioglitazone 1 mg/kg (8) 30 min prior to detorsion; pioglitazone group (Pio 3): rats treated with a single IP injection of pioglitazone 3 mg/kg (8) 30 min prior to detorsion.

Surgical procedure and tissue preparation

Rats were anesthetized with IP injection of 50 mg/kg ketamine and 10 mg/kg Xylazine. Skin of scrotal area was shaved and prepared with 10 % povidone-iodine solution. A scrotal vertical midline incision was performed; torsion was induced by rotating right testis 720° in a clockwise direction and maintained by fixing the testis in the scrotum with a 4-0 silk suture. Sham rats were subjected to the same surgical procedure without testicular rotation. After 4 hr torsion period, right testis was detorted and returned into the scrotum for 4 hr for reperfusion (9). At the end of the experiment, bilateral orchietomies were performed. Blood samples were collected via cardiac puncture, centrifuged at 3000 g for 15 min to obtain a clear serum and was then stored at -20 °C until use for biochemical assays.

The excised testicular tissue (ipsilateral and contralateral) was washed with ice-cold saline and then longitudinally divided into two equal parts; one was fixed in 10% formalin for histopathological and immunohistochemical evaluation and the other was immersed immediately in liquid nitrogen and stored at -80 °C. Testicular tissue samples were homogenized in cold potassium buffer phosphate solution. Homogenates were centrifuged for 15 min at 3000 g, and supernatants were used for biochemical assessment.

Assay of testicular MDA

Malondialdehyde (MDA) level in the testicular homogenate was quantified colorimetrically by using MDA assay kit purchased from MyBiosource Inc, San Deigo, USA and performed according to manufacturer's instructions.

Assay of testicular GSH

Reduced glutathione (GSH) content in the testicular homogenate was quantitatively assayed by the use of Sandwich ELISA kit (Catalog No. MBS046356, MyBiosource. Inc, San Deigo, USA) according to

manufacturer's guidelines.

Assay of testicular SOD activity

Testicular superoxide dismutase (SOD) activity evaluation was carried out according to a method (10) depending on ability of xanthine-xanthine oxidase system to inhibit nitro blue tetrazolium (NBT) reduction.

Assay of pro-inflammatory markers in testicular homogenate

Quantitative ELISA kits were used for determination of testicular TNF- α (ab100785) and MCP-1 (ab100778) purchased from Abcam, Cambridge, UK, according to manufacturer's instructions.

Assay for caspase -3 activity in testicular homogenate

Caspase-3 activity was determined in testicular homogenate using apoptotic marker CASP3/Caspase 3 (Cat.no.LS-F11016, Life span Biosciences, USA) ELISA assay kit, according to manufacturer's instructions.

Assay of AMPK activity in testicular homogenate

AMP- activated protein kinase (AMPK) activity was estimated in testicular homogenates using anti-AMPK antibody (ab80039) ELISA assay kit (Abcam, Cambridge, UK), according to manufacturer's instructions.

Assay of TOS in serum

Serum total oxidant status (TOS) level was assayed using the method described by Erel (11) and were calculated in $\mu\text{mol H}_2\text{O}_2$ equivalent/l.

Assay of TAS in serum

Serum total antioxidant status (TAS) level was assayed according to the method described by Erel (12) and expressed as mmol Trolox equivalent/l.

Histopathology

The obtained testicular tissues were fixed in 10% formalin and embedded in paraffin blocks. 4- μm sections were obtained and stained with hematoxylin and eosin (H&E). Histopathological assessment of spermatogenesis was performed using Johnsen's mean testicular biopsy score (MTBS) (13). MTBS was calculated by dividing sum of all scores by the total number of seminiferous tubules examined (Table 1).

Immunohistochemical detection of testicular IL-6 and Bcl-2

4 μm thick testicular sections were deparaffinized, rehydrated in alcohol with serial rinsing in phosphate - buffered saline (PBS), and its endogenous peroxidase activity was quenched with 3 % H_2O_2 in methanol. For antigen retrieval, sections were pretreated in citrate buffer (pH 6.0) in a microwave. After that, the sections were incubated with rabbit polyclonal antibodies; anti Bcl-2 Ab (ab 194583) and anti-IL-6 Ab (ab 208113) specific for rat (Abcam, Cambridge, UK) at 4 °C overnight. After washing the slides with PBS, sections were incubated at 37 °C for 30 min with biotinylated polyvalent anti-rabbit antibody as a secondary antibody for primarily antibody detection, followed by incubation with streptavidin peroxidase, then stained with 3'3'-diaminobenzidine plus chromogen for detection

of peroxidase activity (D7679, Sigma, Aldrich) at room temperature for 10 min. Slides were counterstained with hematoxylin and examined under light microscope. Expression of IL-6 and Bcl-2 in testicular tissue was graded on scale depending on extent of brown stained cells (Scale 0 = no observed staining; scale 1= <10% of cells were stained weakly; scale 2= multifocal aggregates of uniformly stained cells, 10–75%; scale 3= diffuse positive staining). Histopathological analysis was performed blindly by an expert pathologist.

Statistical analysis

Analysis of data was performed using Graph Pad Prism software (v 6.0). Data were presented as mean ± standard error of mean (SEM). Multiple group comparisons were performed using one-way analysis of variance (ANOVA) followed by *post hoc* Tukey multiple comparisons test. Probability values, *P*<0.05 were considered as statistically significant.

Results

Effect of pioglitazone on testicular oxidant and antioxidant status

Tissue MDA levels were significantly (*P*<0.05) increased in both ipsilateral and contralateral testes of T/D group by 100.25% and 92%, respectively, compared to those of sham group. Pioglitazone (1 mg/kg) treatment (Pio 1 group) significantly (*P*<0.05) reduced tissue MDA levels in ipsilateral testes by 29.1 % and in contralateral testes by 31.2 % compared to T/D group. Further significant (*P*<0.05) reductions in MDA levels by 46.2% in ipsilateral and 46% in contralateral testes were detected in pioglitazone 3 mg/kg (Pio 3)-treated group (Figure 1A). On contrary, testicular GSH levels and SOD activity in T/D ipsilateral testes were decreased significantly (*P*<0.05) by 58% and 47.2%, respectively. Also, pioglitazone 3 mg/kg in contralateral testes attenuated GSH levels and SOD activity by 48.6% and 45.7%, respectively compared to sham rats. Pio 1 group showed significant (*P*<0.05) elevation in GSH levels by 58.3% and 47.2% and SOD activity by 29% and 38.3% in ipsilateral and contralateral testes, respectively in relation to T/D group. Additionally, the testicular GSH levels showed significant (*P*<0.05) increase by 88%

and 81% and SOD activity by 51% and 72.1%, in pio 3 group in ipsilateral and contralateral testes, respectively compared to T/D group (Figure 1B,C).

Effect of pioglitazone on serum TOS and TAS

Serum TOS level in T/D group was significantly (*P*<0.05) increased by 174% compared to sham group. Pioglitazone at both doses of 1 mg/kg and 3 mg/kg showed significant (*P*<0.05) reduction in serum TOS level by 25.2% and 41.1%, respectively in respect to T/D group (Figure 1D). Compared to sham group, serum TAS level was significantly (*P*<0.05) decreased by 43.2% in T/D group. Pioglitazone treated groups at doses of 1 mg/kg and 3 mg/kg showed significant (*P*<0.05) increase in the serum TAS level by 19.5 % and 43%, respectively compared to T/D group (Figure 1E).

Effect of pioglitazone on testicular pro-inflammatory mediators

T/D group showed significant (*P*<0.05) increase in TNF- α by 235% and 197% and MCP-1 levels by 143.5% and 132 % in ipsilateral and contralateral testes, respectively compared to sham rats. Pio 1 group showed significant (*P*<0.05) decrease in the levels of TNF- α by 35.3% and 34% and MCP-1 by 31 % and 28.6 % in ipsilateral and contralateral testis, respectively compared to T/D group. More reductions in these inflammatory mediators levels were encountered in Pio 3 rats as evidenced by significant (*P*<0.05) decrease in TNF- α by 48.6%, and 47% and MCP-1 by 45% and 46.3% in ipsilateral and contralateral testes, respectively (Table 2).

Effect of pioglitazone on testicular level of AMPK

Testicular T/D produced significant (*P*<0.05) increase in AMPK level by 41% in ipsilateral and 42.5% in contralateral testes compared to sham group. AMPK levels were significantly (*P*<0.05) decreased in Pio 1 and Pio 3 groups by 19.4% and 43% in ipsilateral testis and by 24% and 46% in contralateral testes, respectively, compared to testicular T/D group (Table 2).

Effect of pioglitazone on testicular caspase -3 activity

T/D group showed significant (*P*<0.05) increase in

Table1. Histological criteria and Johnsen’s score for spermatogenesis assessment

Score	Characters
Score-10	Complete spermatogenesis with many spermatozoa present
Score-9	Slightly impaired spermatogenesis with many late spermatids, disorganized epithelium
Score-8	Less than five spermatozoa per tubule, few late spermatids
Score-7	No spermatozoa, no late spermatids, many early spermatids
Score-6	No spermatozoa, no late spermatids, few early spermatids
Score-5	No spermatozoa or spermatids, many spermatocytes
Score-4	No spermatozoa or spermatids, few spermatocytes
Score-3	Spermatogonia only
Score-2	No germinal cells, Sertoli cells only
Score-1	No seminiferous epithelium

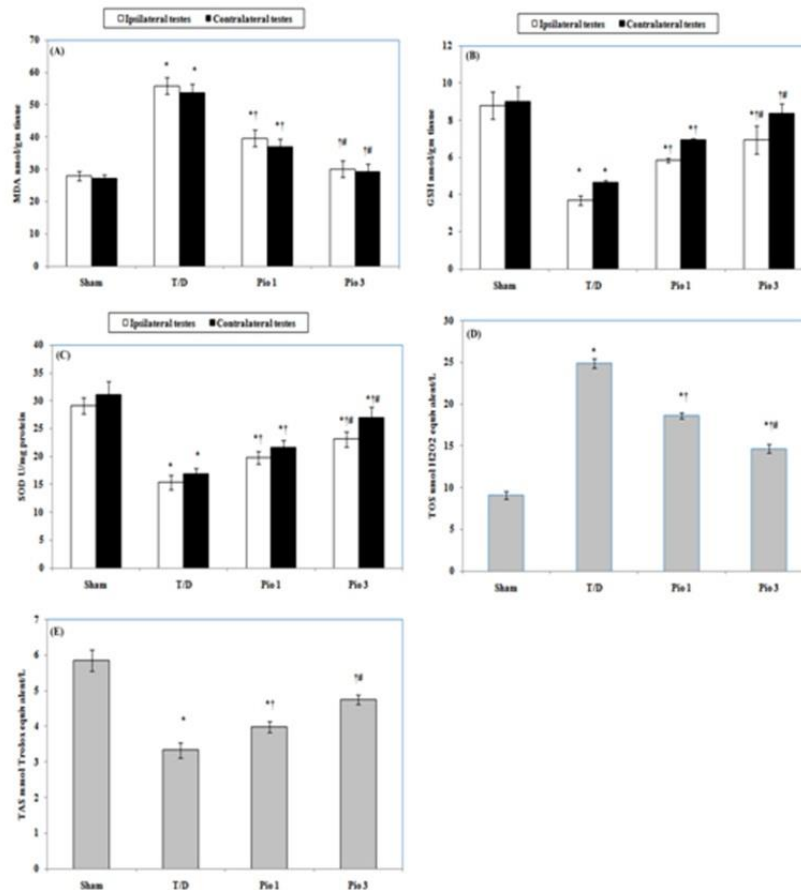


Figure 1. Effect of testicular torsion/detorsion(T/D) alone or with pioglitazone (Pio) (1 and 3 mg/kg) on (A) malondialdehyde (MDA), (B) reduced glutathione (GSH), and (C) superoxide dismutase (SOD) activity in ipsilateral and contralateral testes, (D) serum total oxidant status (TOS) and (E) serum total antioxidant status (TAS). Data are means±SEM. * compared to sham group, † compared to T/D group and # compared to Pio 1 group ($P<0.05$)

caspase -3 activity by 181.5% and 163% in ipsilateral and contralateral testis, respectively in relation to sham rats. Caspase -3 activity was significantly ($P<0.05$) decreased in Pio 1 and Pio 3 groups by 30.6%, and 58 % in ipsilateral testis and by 29.4% and 58.4% in contralateral testes, respectively in comparison with T/D group (Table 2).

Histopathological analysis for assessment of spermatogenesis

Rats in sham group displayed normal testicular architecture of normal seminiferous tubules, multiple normal layers of spermatogenic cells from spermatogonium up to mature sperms and surrounded by normal basement membrane, while testicular tissues

Table 2. Effect of pioglitazone 1 and 3 mg/kg on testicular inflammatory markers, caspase - 3 activity and Johnsen’s score in rats exposed to torsion/ detorsion

Parameters	Sham	T/D	Pio 1	Pio 3
TNF- α (pg/g tissue)				
I	11.43 ± 0.07	38.29 ± 2.11*	24.76 ± 1.93*†	19.67 ± 0.94*†#
C	11.15 ± 0.04	33.16 ± 2.03*	21.87 ± 1.56*†	17.57 ± 0.84*†#
MCP-1 (ng/ml)				
I	24.54 ± 1.08	59.77 ± 1.62*	41.19 ± 1.44 *†	32.94 ± 1.54*†#
C	23.94 ± 1.07	55.52 ± 1.43*	39.65 ± 1.38*†	29.79 ± 1.84*†#
AMPK (ng/mg tissue)				
I	23.71 ± 1.35	33.46 ± 1.75*	39.95 ± 2.3 *†	47.85 ± 3.47*†#
C	23.95 ± 1.21	34.12 ± 1.96*	42.23 ± 2.52*†	49.78 ± 3.1*†#
Caspase -3 (ng/g tissue)				
I	6.8 ± 0.41	19.14 ± 1.31*	13.29 ± 1.25*†	8.04 ± 0.91*†#
C	6.8 ± 0.34	17.89 ± 1.26*	12.63 ± 1.18*†	7.45 ± 0.73*†#
Johnsen's score				
I	9.56 ± 0.41	4.17 ± 0.25 *	6.94 ± 0.27* †	7.85 ± 0.32 *†#
C	9.57 ± 0.43	4.33 ± 0.28*	7.17 ± 0.30*†	8.13 ± 0.38*†#

Values are expressed as mean± SEM (n=6).I= ipsilateral, C= contralateral. Pio: pioglitazone; TNF-α: tumor necrosis factor alpha; MCP-1: monocyte chemoattractant-1; AMPK: AMP- activated protein kinase * significantly different from sham group ($P<0.05$), † significantly different from T/D group ($P<0.05$), # significantly different from Pio 1 group ($P<0.05$)

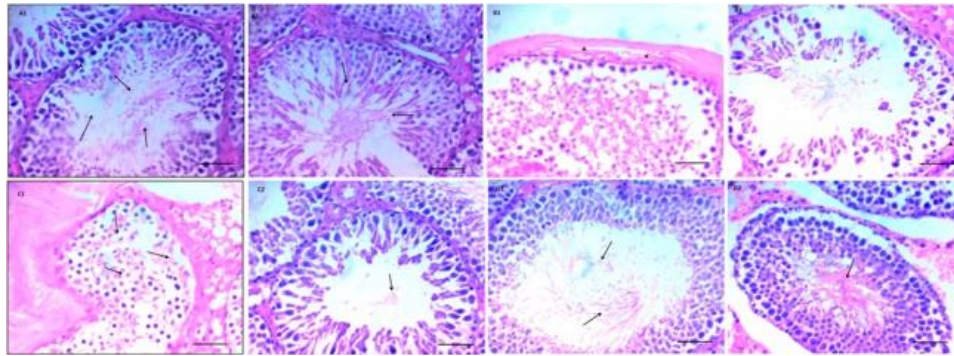


Figure 2. Photomicrographs of (H & E X 400, scale bar represent 50 μ m) testicular sections. (A1 and A2) Testicular tissue of ipsilateral and contralateral testes of sham rat represents normal seminiferous tubule containing normal layers of spermatogenic cells up to mature sperms (arrows) and surrounded by normal basement membrane (arrowheads). (B1 and B2) Ipsilateral and contralateral testes of rat exposed to torsion / detorsion show marked sloughing and disorganization of spermatogenic cells, thickening of basement membrane (arrowheads) and absence of mature sperms. (C1 and C2) Demonstrate mild reductions of spermatogenic cells layers with few sperms in lumen (arrows) of ipsilateral and contralateral testes of rat exposed to torsion / detorsion and treated with pioglitazone 1 mg/kg. (D1 and D2) represent normal layers of spermatogenic cells with mature sperms in lumen (arrows) and normal thicknesses of basement membrane (arrowheads) in ipsilateral and contralateral testes of rat exposed to torsion / detorsion and treated with pioglitazone 3 mg/kg

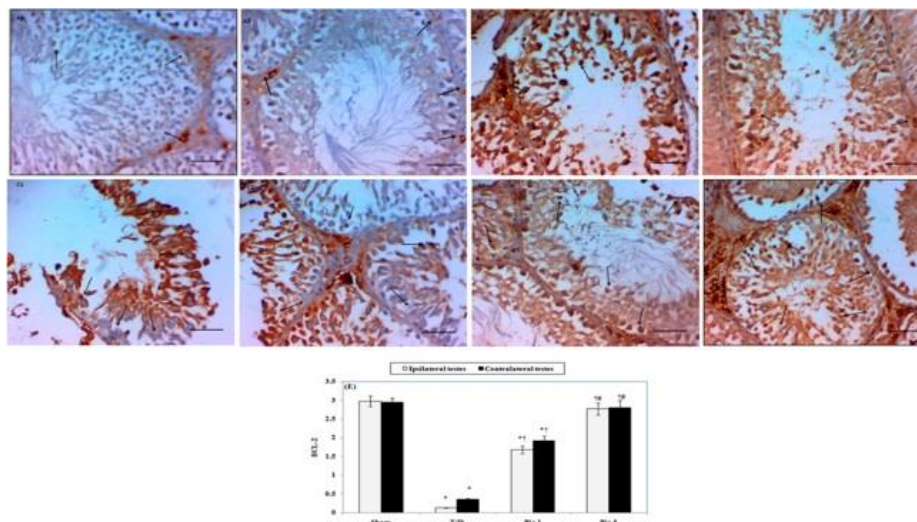


Figure 3. A-D Photomicrographs represent immunohistochemical staining of Bcl-2 in testicular tissues of different groups (magnification \times 400, scale bar represent 50 μ m). (A 1) ipsilateral testis and (A 2) contralateral testis sections of sham rat show diffuse cytoplasmic staining of Bcl- 2 (arrows). Representative section from ipsilateral (B 1) and contralateral (B 2) testes of rat exposed to torsion / detorsion (T/D) show less Bcl- 2 staining (arrows). (C 1 and 2) Representative sections of ipsilateral and contralateral testes of rat exposed to T/D and treated with pioglitazone 1 mg /kg (Pio 1) show moderate expression of Bcl- 2(arrows). Sections of ipsilateral (D 1) and contralateral (D2) testes of rats exposed to T/D and treated with 3 mg/kg pioglitazone (Pio 3) show increased Bcl- 2 cytoplasmic staining (arrows). (E) Bar histogram demonstrating scores of Bcl-2 expression. Results shown are means \pm SEM of six rats/ group. * compared to sham group, † compared to T/D group and # compared to Pio 1 group ($P < 0.05$)

of T/D group exhibited sloughing, disorganization of spermatogenic cells with absence of mature sperms and thickening of basement membrane of both ipsilateral and contralateral testes. Treatment with pioglitazone 1 and 3 mg/ kg showed significant dose-dependent increase in layers of spermatogenic cells with mature sperms in lumen of both ipsilateral and contralateral testes (Figure 2). While significant increase in Johnsen’s score was observed in Pio 1 group, further significant increments in the score were detected in Pio 3 group affecting both ipsilateral and contralateral testis (Table 2).

Immunohistochemical testicular Bcl-2 expression

Immunohistochemical staining of testicular tissue

revealed expression of Bcl-2 in sham rats (Figure 3(A)). Testicular T/D group showed significant ($P < 0.05$) decrease in Bcl-2 expression in both ipsilateral and contralateral testes compared to sham group (Figure 3(B)). Pio 1 and Pio 3 treated groups showed significant ($P < 0.05$) increase in Bcl-2 expression in respect to testicular T/D group (Figure 3(C), (D), (E)).

Immunohistochemical testicular IL-6 expression

Testicular T/D group showed positive staining for IL-6 in ipsilateral and contralateral testicular tissue (Figure 4(B)) compared to sham group (Figure 4(A)). Pio 1 and Pio 3 groups showed negative staining for IL-6 compared to testicular T/D group (Figure 4C, D, E).

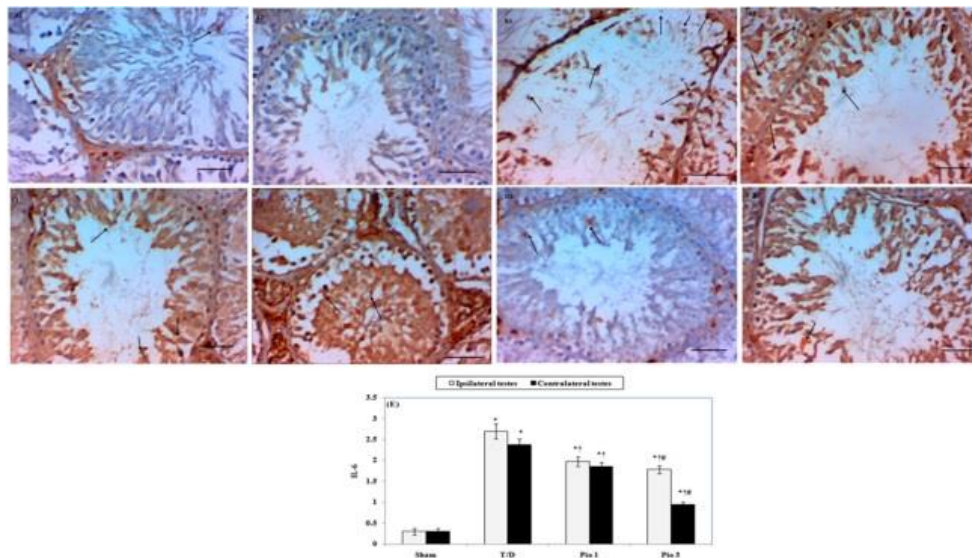


Figure 4. A-D Photomicrographs represent immunohistochemical staining of interleukin 6 (IL-6) in testicular tissues of different groups (magnification $\times 400$, scale bar represent $50 \mu\text{m}$). Ipsilateral (A1) and Contralateral (A2) testes of sham rat show weak cytoplasmic expression of IL-6 (arrows). Rat exposed to testicular torsion / detorsion (T/D) show marked cytoplasmic expression of IL-6 (arrows) in both ipsilateral (B1) and contralateral (B2) testes. Pioglitazone treatment (1 and 3 mg/kg) produced dose-dependent decrease in IL-6 expression (arrows) in ipsilateral (C1 and D1) and contralateral testes (C2 and D2). (E) Bar histogram represents scores of IL-6 expression. Data are means \pm SEM. * compared to sham group, † compared to T/D group and # compared to Pio 1 group ($P < 0.05$)

Discussion

The current study demonstrates for the first time a protective potential for pioglitazone in the testicular injury induced by unilateral T/D. Being end arteries, testicular arteries make the testes especially susceptible to ischemic injury. In agreement with previous studies (14,15), we reported that unilateral testicular rotation for four hours followed by four hours reperfusion caused significant testicular damage in both ipsilateral and contralateral testes, as evidenced by biochemical (increased levels of MDA, MCP- 1, TNF- α , caspase-3, AMPK, TOS and decreased levels of GSH, SOD, TAS), immunohistochemical (increased IL-6 and decreased Bcl -2) and histopathological analyses, which revealed decreased Johnsen’s score of spermatogenesis. To explain contralateral testicular injury, multiple theories were implicated including autoimmunization against the spermatogonia, decrease in testicular blood flow caused by a reflex sympathetic response and ROS generation after detorsion (15). In the present study, pretreatment with pioglitazone (1 and 3 mg/kg) significantly decreased the levels of MDA, MCP- 1, TNF- α , caspase-3, AMPK, TOS, and IL-6 and increased the levels of GSH, SOD, TAS and Bcl -2. These beneficial effects of pioglitazone are supported by increase in Johnsen’s score of spermatogenesis. Based on the literature argument, oxidative stress plays a central role in pathophysiology of testicular T/D-induced injury. Unfortunately, both phases of torsion and detorsion result in burst of mitochondrial ROS generation, which consumes natural antioxidants, leading to oxidative stress. The liberated ROS exert its deleterious effects by triggering oxidative damage to lipids, proteins and DNA (16). Consistent with earlier studies (15, 17), the current study demonstrated increased MDA in both ipsilateral and contralateral testicular tissues as indicator of lipid peroxidation. In the present work, pioglitazone decreased MDA level in both ipsilateral and contralateral

testes. In the same context, previously published studies confirmed inhibition of lipid peroxidation by pioglitazone supplementation (18, 19). To declare potential mechanisms by which pioglitazone abrogated T/D induced - oxidative stress, we assayed the effects of pioglitazone on antioxidant system in both ipsilateral and contralateral testes. Testicular level of GSH, an important scavenger of ROS, was decreased bilateral in rats exposed to T/D, while administration of pioglitazone elevated GSH levels in a dose-dependent manner. The current results are in line with a previous study (20) that reported enhancement of GSH levels in rats exposed to renal I/R and pretreated with pioglitazone. SOD is a vital antioxidant that catalyzes partitioning of superoxide radicals into hydrogen peroxide or molecular oxygen to be scavenged by GSH. Previous studies have shown that SOD activity is reduced due to testicular T/D (21). In the present study, we demonstrated decline in SOD activity in both testes of T/D rats, meanwhile pioglitazone maintained SOD activity that this effect can be attributed to its antioxidant property. In harmony with that, pioglitazone increased SOD activity and protected against paracetamol-induced hepatotoxicity (22). This eminent antioxidant potential of pioglitazone is additionally confirmed in this study by decreasing the serum TOS and increasing the TAS. Pioglitazone also increased the TAS in diabetic rabbits (23). These data attribute the rapid and direct inhibition of complex I (via the attenuation of NADPH oxidase activity) and complex III of mitochondrial respiration to antioxidant effect of pioglitazone, which leads to decrease in generation of ROS from mitochondria (24-26). Collectively, we concluded that the antioxidant potential of pioglitazone is due to inhibition of ROS generation and bolstering testicular antioxidant parameters including GSH and SOD.

In the current study, pioglitazone ameliorated the increased levels of TNF- α and IL-6 in both ipsilateral

and contralateral testes after unilateral T/D. A PPAR- γ dependent inhibition of TNF- α and IL-6 was reported in previous studies against carrageenan-induced inflammation (27), forebrain I/R injury (28) and myocardial I/R injury (29).

In this study, pioglitazone decreased MCP-1 level in testicular tissue. MCP-1 is a principle chemokine for recruitment of monocytes into testicular interstitium to be matured into resident - macrophages (30), which can further contribute to more release of inflammatory mediators and ROS. Therefore, pioglitazone-induced inhibition of MCP-1 provides indirect antioxidant mechanism for attenuating the release of ROS. Testicular T/D injury is associated with increased MCP-1 expression by Leydig cells, macrophages, peritubular cells and perivascular cells (31). ITO and co-workers (32) demonstrated tendency of pioglitazone to reduce myocardial infarct size resulted from myocardial I/R through attenuating expression of MCP-1. In the same line, pioglitazone was established to produce anti-inflammatory effect against cecal ligation and puncture-induced sepsis in mice through attenuating the expression of MCP-1 and IL-6 (33). Anti-inflammatory activity of pioglitazone is approved to be independent from its antidiabetic action (34).

Apoptosis is an essential physiologic process that takes place during normal spermatogenesis; however, overproduction of ROS initiates intrinsic apoptotic pathway through increasing the expression of pro-apoptotic Bax and decreasing anti-apoptotic Bcl-2 with subsequent destabilization of mitochondrial membrane (35). Membrane destabilization leads to release of mitochondrial cytochrome-C into the cytoplasm, and activation of cascade of caspases including caspase-3, which eventually activates caspase-activated DNase and degrades DNA (36). Additionally, TNF- α stimulates its receptors on mitochondrial membrane to activate extrinsic pathway of apoptosis (37); these pathways result in germ cell specific apoptosis. The present study detected that pioglitazone increased expression of anti-apoptotic Bcl-2 and decreased the level of caspase-3 in testicular tissue of rotated and non-rotated testicles that can be suggested as an anti-apoptotic mechanism of pioglitazone.

In agreement with our results, Hu *et al.* (38) illustrated renoprotective effect of pioglitazone against I/R injury and attributed this effect to enhancement of Bcl-2 expression, which antagonizes death-promoting activity of Bax, so mitochondrial activity and cell integrity are maintained.

The current results demonstrated an increase in AMPK activity in T/D rats, which indicates presence of innate mechanism to counteract testicular injury, and pioglitazone treatment was associated with more increase in AMPK level. Previous studies detected an increase in AMPK levels in myocardial (39), hepatic (40) and renal (41) I/R injury. AMPK is considered as energy sensor; it is phosphorylated and activated by increased AMP/ATP ratio during tissue ischemia. Oxidative stress can also activate AMPK. The protective effect of AMPK against many types of I/R injury is well-established. This protection might be due to improving metabolic stress by maintaining metabolic balance through activating catabolic (ATP generating) pathways and

attenuating anabolic (ATP consuming) steps (42). The anti-inflammatory role of AMPK was also investigated, and the results showed that AMPK activators suppress the release of TNF- α and IL-6 from macrophage in response to lipopolysaccharide; additionally, activation of AMPK decreased the expression of adhesion molecules, infiltration of leukocytes and decreased the level of pro-inflammatory cytokines in hepatic I/R injury (40). Moreover, the antiapoptotic effect of AMPK against hepatic I/R injury in rats was detected (43). The antioxidant character of AMPK was reported to be a result of increasing level of SOD, and catalase (44) and inhibiting the release of ROS through inhibition of NAD(P)H oxidase (45). Many researches proved the ability of pioglitazone to augment the level of AMPK, and this may participate in protection against atherosclerosis (46), cisplatin-induced nephrotoxicity (47) and myocardial injury caused by metabolic syndrome (48).

Additionally, pioglitazone reduced congestion, sloughing and disorganization of spermatogenic cells and increased the layers of spermatogenic cells with mature sperms in the lumen with subsequent increase in the Johnsen's score. The aforementioned histopathological results supported the biochemical and immunohistochemical results. Avlan *et al.* (9) reported similar histopathological derangements of testis exposed to testicular T/D.

Conclusion

The present study revealed that unilateral testicular torsion caused bilateral testicular damage with increased oxidative, inflammatory and apoptotic markers. Pioglitazone reversed testicular histopathological derangements, reduced inflammation, and enhanced antioxidative status and antiapoptotic markers. These effects of pioglitazone are dose-dependent. So, the present study demonstrated the protective effect of pioglitazone against testicular T/D, which was attributed to its antioxidant, anti-inflammatory and antiapoptotic properties.

Acknowledgment

The authors acknowledge Dr. Kamal Alqasheshey, Pathology Department, Faculty of Medicine, Zagazig University for histopathological and immunohistochemical examination of the testes.

Conflicts of Interest

The authors declare that they have no conflict of interest.

References

1. Arevalo M K, Sheth KR, Menon VS, Ostrov L, Hennis H, Singla N, *et al.* Straight to the Operating Room: An Emergent Surgery Track for Acute Testicular Torsion Transfers. *J Pediatr* 2018;192:178-183.
2. Ghasemnejad-Berenji M, Ghazi-Khansari M, Yazdani I, Saravi SSS, Nobakht M, Abdollahi A, *et al.* Rapamycin protects testes against germ cell apoptosis and oxidative stress induced by testicular ischemia-reperfusion. *Iran J Basic Med Sci* 2017; 8, 905-911.
3. Parlaktas BS, Atilgan D, Ozyurt H, Gencten Y, Akbas A, Erdemir F, *et al.* The biochemical effects of ischemia-

- reperfusion injury in the ipsilateral and contralateral testes of rats and the protective role of melatonin. *Asian J Androl* 2014; 2: 314-318.
4. Kanter M. Protective effects of melatonin on testicular torsion/detorsion-induced ischemia-reperfusion injury in rats. *Exp Mol Pathol* 2010; 3: 314-320.
 5. Taati M, Moghadasi M, Dezfoulian O, Asadian P, Zendehtdel M. Effects of Ghrelin on germ cell apoptosis and proinflammatory cytokines production in Ischemia-reperfusion of the rat testis. *Iran J Reprod Med* 2015; 2: 85-92.
 6. Bonato JM, Bassani TB, Milani H, Vital MABF, de Olivera RMW. Pioglitazone reduces mortality, prevents depressive-like behavior, and impacts hippocampal neurogenesis in the 6-OHDA model of Parkinson's disease in rats. *Exp Neurol* 2017; 300: 188-200.
 7. Sekulic-Jablanovic M, Petkovic V, Wright M B, Kucharaya k, Huerzeler N, Levano S ,*et al.* Effects of peroxisome proliferator activated receptors (PPAR)- γ and - α agonists on cochlear protection from oxidative stress. *PLoS One* 2017; 11: e0188596.
 8. Cao Z.1, Ye P, Long C, Chen K, Li X, Wang H. Effect of pioglitazone a peroxisome proliferator-activated receptor gamma agonist, on ischemia-reperfusion injury in rats. *Pharmacology* 2007; 3: 184-192.
 9. Avlan D, Erdouğan K, Cimen B, Dusmez Apa D, Cinel I, Aksoyek S. The protective effect of selenium on ipsilateral and contralateral testes in testicular reperfusion injury. *Pediatr Surg Int* 2005; 21: 274 - 278.
 10. Sun Y, Oberley LW, Li Y. A simple method for clinical assay of superoxide dismutase. *Clin Chem* 1988; 3:497-500.
 11. Erel O. A new automated colorimetric method for measuring total oxidant status. *Clin Biochem* 2005; 12: 1103-1111.
 12. Erel O. A novel automated direct measurement method for total antioxidant capacity using a new generation, more stable ABTS radical cation. *Clin Biochem* 2004; 4:277-285.
 13. Johnsen S G. Testicular biopsy score count - method for registration of spermatogenesis in human testes: normal values and results in 335 hypogonadal males. *Hormones* 1970; 1:2-25.
 14. Sukhotnik I, Miselevich I, Lurie M, Nativ O, Coran AG, MMogilner JG. The time relationship between ipsilateral testicular ischemia and germ cell apoptosis in the contralateral testis in rat. *Pediatr Surg Int* 2005; 217: 512-516.
 15. Tsounapi P, Saito M, Dimitriadis F, Shimizu S, Kinoshita Y, Shomori K, *et al.* Protective effect of sivelestat, a neutrophil elastase inhibitor, on ipsilateral and contralateral testes after unilateral testicular ischaemia- reperfusion injury in rats. *BJU Int* 2011; 107: 329-336.
 16. Filho DW, Torres MA, Bordin AL, Crezcynski-Pasa TB, Boveris A. Spermatic cord torsion, reactive oxygen and nitrogen species and ischemia-reperfusion injury. *Mol Aspects* 2004; 1-2:199-210.
 17. Oral A, Halici Z, Bayir Y, opcu A, Un H, Bilgin AO, *et al.* Effect of oral zinc administration on long – term ipsilateral and contralateral testes damage after experimental testis ischemia reperfusion. *Andrologia* 2017; 49. doi: 10.1111/and.12673.
 18. Somi M H, Hajipour B, Asl N A, Estakhri R, Azar AN, Zade MN, *et al.* Pioglitazone attenuates ischemia/reperfusion-induced liver injury in rats. *Transplant Proc* 2009; 41: 4105-4109.
 19. Surapaneni KM, Jainu M. Comparative effect of pioglitazone, quercetin and hydroxy citric acid on the status of lipid peroxidation and antioxidants in experimental non-alcoholic steatohepatitis. *J Physiol Pharmacol* 2014; 65: 67-74.
 20. Ragab D, Abdallah D M, El-Abhar H S. Cilostazol renoprotective effect: modulation of PPAR- γ , NGAL, KIM-1 and IL-18 underlies its novel effect in a model of ischemia-reperfusion. *PLoS One* 2014; 9, e 95313.
 21. Un H, Bayir, Y, Halici Z, Akpinar E, Karakus E, Oral A, *et al.* The Effects of RAAS inhibition in rate limiting step by aliskiren on testicular torsion injury in rats. *J Urol* 2015; 194:828-833
 22. Gupta G, Krishna G, Chellappan D K, Gubbiyappa KS, Candasamy M, Duma K. Protective effect of pioglitazone, a PPAR γ agonist against acetaminophen-induced hepatotoxicity in rats. *Mol Cell Biochem* 2014; 393: 223-228.
 23. Gumieniczek A, Hopkała H, Roliński J, Bojarska-Junak, A. Interleukin-6 and oxidative stress in plasma of alloxan-induced diabetic rabbits after pioglitazone treatment. *Immunopharmacol Immunotoxicol* 2006; 28: 81-91.
 24. Collino M, Aragno M, Mastrocola R, Gallicchio M, Rosa AC, Dianzani C, *et al.* Modulation of the oxidative stress and inflammatory response by PPAR-gamma agonists in the hippocampus of rats exposed to cerebral ischemia/reperfusion. *Eur J Pharmacol* 2006; 530:70-80.
 25. Garcia-Ruiz I, Solis-Munoz P, Fernandez-Moreira D, Muñoz-Yagüe T, Solís-Herruzo JA. Pioglitazone leads to an inactivation and disassembly of complex I of the mitochondrial respiratory chain. *BMC Biol* 2013; 11: 88-102.
 26. Takada S, Hirabayashi K, Kinugawa S, Yokota T, Matsushima S, Suga T, *et al.* Pioglitazone ameliorates the lowered exercise capacity and impaired mitochondrial function of the skeletal muscle in type 2 diabetic mice. *Eur J Pharmacol* 2014; 5; 740:690-696.
 27. Fröde TS, Buss Zda S, dos Reis, G O, Medeiros YS. Evidence of anti-inflammatory effects of pioglitazone in the murine pleurisy model induced by carrageenan. *Int Immunopharmacol* 2009; 9:1394-1400.
 28. El-Sahar A E , Safar M M, Zaki, H F, Attia AS, Ain-Shoka AA. Neuroprotective effects of pioglitazone against transient cerebral ischemic reperfusion injury in diabetic rats: Modulation of antioxidant, anti-inflammatory, and anti-apoptotic biomarkers. *Pharmacol Rep* 2015; 67: 901- 906.
 29. Han J, Wang D, Ye L, Li P, Hao W, Chen X, *et al.* Rosmarinic acid protects against inflammation and cardiomyocyte apoptosis during myocardial ischemia/reperfusion injury by activating peroxisome proliferator-activated receptor gamma. *Front Pharmacol* 2017; 8: 456-466.
 30. Gerdprasert O, O'Bryan MK, Nikolic-Paterson D J, Sebire K, de Kretser DM, Hedger MP. Expression of monocyte chemoattractant protein-1 and macrophage colony-stimulating factor in normal and inflamed rat testis. *Mol Hum Reprod* 2002; 8:518-524.
 31. Al-Maghrebi M, Renno W M, Al-Ajmi N. Epigallocatechin-3-gallate inhibits apoptosis and protects testicular seminiferous tubules from ischemia/reperfusion-induced inflammation. *Biochem Biophys Res Commun* 2012; 420: 434-439.
 32. Ito H, Nakano A, Kinoshita M, Matsumori A. Pioglitazone, a peroxisome proliferator-activated receptor-gamma agonist, attenuates myocardial ischemia/reperfusion injury in a rat model. *Lab Invest* 2003; 83: 1715-1721.
 33. Matsutani T, Tamura K, Kutsukake M, Matsuda A, Tachikawa E, Uchida E. Impact of pioglitazone on macrophage dynamics in adipose tissues of cecal ligation and puncture-treated mice. *Biol Pharm Bull* 2017; 5: 638- 644.
 34. Kuru karabas M, Ayhan M, Guney E, Sertter M, Meteoglu I. The effect of pioglitazone on antioxidant levels and renal histopathology in streptozotocin-induced diabetic rats. *ISRN Endocrinol* 2013; 9:858690.
 35. Shaha C, Tripathi R, Mishra D P. Male germ cell apoptosis: regulation and biology. *Philos Trans R Soc Lond B Biol Sci* 2010; 365: 1501-1515.
 36. Kitazumi I, Tsukahara M, Regulation of DNA

- fragmentation: the role of caspases and phosphorylation. *FEBS J* 2011; 278: 427-444.
37. Turner T T, Bang H J, Lysiak J L. The molecular pathology of experimental testicular torsion suggests adjunct therapy to surgical repair. *J Urol* 2004; 172: 2574-2578.
38. Hu H, Zou C, Xi X, Shi Z, Wang G, Huang X. Protective effects of pioglitazone on renal ischemia-reperfusion injury in mice. *J Surg Res* 2012; 178: 460 - 465.
39. Hao M, Zhu S, Hu L, Zhu H, Wu X, Li Q. Myocardial ischemic postconditioning promotes autophagy against ischemia reperfusion injury via the activation of the nNOS/AMPK/mTOR Pathway. *Int J Mole Sci* 2017; 18: pii: E614.
40. Zhang M, Yang D, Gong X, Ge P, Dai J, Lin L, et al. Protective benefits of AMP-activated protein kinase in hepatic ischemia-reperfusion injury. *Am J Transl Res* 2017; 9:823-829.
41. Chen BL, Wang LT, Huang KH, Wang CC, Chiang CK, Liu SH. Quercetin attenuates renal ischemia/reperfusion injury via an activation of AMP-activated protein kinase-regulated autophagy pathway. *J Nutr Biochem* 2014; 25:1226-1234.
42. Craig PM, Moyes C, LeMoine CM R. Sensing and responding to energetic stress: Evolution of the AMPK network. *Comp Biochem Physiol B Biochem Mol Biol* 2017; 17:30161-30166.
43. Peralta C, Bartrons R, Serafin A, Blázquez C, Guzmán M, Prats N, et al. Adenosine monophosphate-activated protein kinase mediates the protective effects of ischemic preconditioning on hepatic ischemia-reperfusion injury in the rat. *Hepatology* 2001; 34: 1164 -1173.
44. Yun H, Park S, Kim MJ, Yang WK, Im DU, Yang KR, et al. AMP-activated protein kinase mediates the antioxidant effects of resveratrol through regulation of the transcription factor FoxO1. *FEBS J* 2014; 281: 4421- 4438.
45. Song P, Zou M H. Regulation of NAD (P) H oxidases by AMPK in cardiovascular systems. *Free Radic Biol* 2012; 52: 1607-1619.
46. Tian Y, Chen T, Wu Y, Yang L, Wang L, Fan X, et al. Pioglitazone stabilizes atherosclerotic plaque by regulating the Th17/Treg balance in AMPK-dependent mechanisms. *Cardiovasc Diabetol* 2017; 16:140-148.
47. Zhang J, Zhang Y, Xiao F, Liu Y, Wang J, Gao H, et al. The peroxisome proliferator-activated receptor γ agonist pioglitazone prevents NF- κ B activation in cisplatin nephrotoxicity through the reduction of p65 acetylation via the AMPK-SIRT1/p300 pathway. *Biochem Pharmacol* 2016; 101: 100-111.
48. Matsuura N, Asano C, Nagasawa K, Ito S, Sano Y, Minagawa Y, et al. Effects of pioglitazone on cardiac and adipose tissue pathology in rats with metabolic syndrome. *Int J Cardiol* 2015; 179:360-369.