

## Cutaneous Manifestations of Primary Immunodeficiency Diseases in Children

Athar Moin<sup>1</sup>, Abolhassan Farhoudi<sup>2</sup>, Mostafa Moin<sup>2</sup>, Zahra Pourpak<sup>2</sup>, and Nasrin Bazargan<sup>3</sup>

<sup>1</sup> Department of Dermatology, Faculty of Medicine, Shahed University, Tehran, Iran

<sup>2</sup> Department of Allergy and Clinical immunology of Children's Medical center, Immunology, Asthma and Allergy Research Institute, Tehran University of Medical Sciences, Tehran, Iran

<sup>3</sup> Department of Pediatric, Faculty of Medicine, Kerman University, Kerman, Iran

Received: 29 November 2005; Received in revised form: 28 May 2006; Accepted: 26 June 2006

### ABSTRACT

Primary immunodeficiency diseases (PIDs) are rare but include severe conditions found predominantly in children, Most PIDs have cutaneous manifestations that may be important as early diagnostic features.

The purpose of this study was to determine the frequency and nature of cutaneous alterations associated with PIDs.

This article is a cross-sectional study at the department of allergy and clinical immunology of children's medical center conducted between December 5, 2001 and April 20, 2002. The subjects included pediatric patients with a diagnosis of PID and dermatological diagnoses were made by a dermatologist.

Two hundred and ten patients were studied They consisted of 68 cases of humoral deficiency, 22 cases of cellular and combined deficiencies, 57 cases of phagocytic defects and 63 cases of other PIDs. In 67 cases (31.8%) the cutaneous alterations preceded and were the basis for clinical immunological diagnosis. Overall cutaneous alterations were infections in 99 cases and eczematous dermatitis in 27 cases.

Our findings support the results of other studies that most PIDs have cutaneous features which being their typical aspects are highly suggestive for the diagnosis of PIDs.

**Key words:** Children; Cutaneous manifestations; Primary immunodeficiency

### INTRODUCTION

Primary immunodeficiency diseases (PIDs) comprise a number of serious and rare genetically determined disorders characteristically observed in infants and children. The diagnosis of a PID is important for several reasons: a high index of

suspicion and early diagnosis can lead to lifesaving treatment, prevention of complications, as well as significant improvement in the quality of life.<sup>1,2</sup>

One of the organs which is involved in PIDs is skin and its alterations such as infections, eczematous dermatitis or erythroderma may be the clue for the final diagnosis. Dermatology specialist may be the first to diagnose an immune defect in the patients and can help them the most, regarding prompt treatment.<sup>3</sup>

The purpose of this study was to determine the frequency and nature of cutaneous alterations

---

**Corresponding Author:** Athar Moin, MD;  
Department of Dermatology, Mostafa Khomeini Hospital, Italia St.  
Faculty of Medicine, Shahed University, Tehran, Iran. Tel: (+98  
21) 8896 9437, 38, Fax: (+98 21) 4401 0083, E-mail:  
sj812003@yahoo.com

associated with PIDs. No similar studies have hitherto been reported from Iran.

## PATIENTS AND METHODS

This was a cross-sectional study which was carried out between December 5, 2001 and April 20, 2002. The subjects included pediatric patients with a diagnosis of PID at the pediatric medical center of Tehran University. Dermatological diagnoses were made by a dermatologist sex, age, age at onset of disease, family history of disease and consanguinity of their parents were obtained from the clinical files of the patients or by interview. Diagnoses were grouped according to their primary immune defect, and dermatological involvements were grouped according to the etiology of their most prominent sign.

## RESULTS

Two hundred and ten patients were studied, 122 male and 88 females of whom 41.6% (n=86) had onset of their disease before the first year of life. 45.5% (n=96) of patients had positive family history resembling PIDs and 51.2% (n=108) of their parents were relatives. The characteristics of the patients are shown in table 1.

PIDs were classified as humoral in 68 (32.4%) cases, cellular and combined in 22 (10%) cases, phagocytic 57 (27.1%) cases and other PIDs in 63 (30%) cases (Table 2).

In 67 cases (31.8%) the cutaneous alterations preceded and were the basis for the clinical immunologic diagnosis, 49 cases (23.2%) had cutaneous infections and 13 cases (6.2%) had dermatitis.

**Table 1. Patients' characteristics.**

Characteristics	No. (%)
<b>Sex</b>	
Males	122 (58.1)
Females	88 (41.9)
<b>Age distribution (year)</b>	
<1	7 (3.3)
1-5	32 (15.1)
>5	168 (79.6)
<b>Onset of disease (year)</b>	
<1	88 (41.6)
1-5	73 (34.6)
>5	28 (13.3)
Family history of disease	95 (45.5)
Consanguinity of parents	108 (51.2)

Overall the most prominent cutaneous alterations were infectious in 99 (47.1%) of cases and eczematous dermatitis in 27 (12.8%) of cases. The most common cause of cutaneous infections were bacteria in 71 (33.8%) and mycoses in 37 (17.6%) of cases (table 2). Cutaneous alterations associated with different immunodeficiencies are shown in tables 2-5. The highest cutaneous infections were seen in cellular and combined immunodeficient patients (95.5%) and phagocytic defect (84.2%) cases (Figure 1). The highest bacterial infections were seen in phagocytic defect and the highest viral and mycotic infections were seen with cellular and combined immunodeficiency (Table 2). Most eczematous lesions were associated with humoral and cellular and combined immunodeficiencies (Table 2, Figures 2, 3).

**Table 2. Groups of primary immunodeficiencies: Associated infections and eczema.**

Immunodeficiencies	Case No. (%)	Skin infections No. (%)	Bacterial No. (%)	Viral No. (%)	Mycotic No. (%)	Eczema-dermatitis No. (%)
Humoral	68(32.4)	32(30.9)	9(13.2)	5(7.3)	12(17.6)	19(27.9)
Cellular & Combined	22(10.5)	21(95.5)	12(54.5)	4(18.2)	14(63.6)	5(22.7)
Phagocytic	57(27.1)	48(84.2)	48(84.2)	1(1.7)	9(15.7)	2(3.5)
Other PIDs	63(30)	9(14.3)	2(3.2)	4(6.3)	2(3.2)	1(1.6)
Total	210	99(47.1)	71(33.8)	14(6.6)	37(17.6)	27(12.8)

## Cutaneous Manifestations of PIDs

**Table 3. Humoral immunodeficiencies with some cutaneous manifestations.**

Disease	Number of cases	Cutaneous infections	(No.)	Dermatitis (No.)	Other manifestations (No.)
X-linked agammaglobulinemia (Bruton's)	23	Abscesses	(3)	4	Maculopapular rash (3)
		Furunculosis	(2)		Urticaria (2)
		Impetigo	(2)		
		Candida	(3)		
Selective IgA deficiency	17	Folliculitis	(1)	5	ITP (1)
Common variable immunodeficiency (CVID)	28	Candida	(2)	6	Maculopapular rash (1)
		Candida	(4)		Urticaria (1)
					Alopecia areata (1)

**Table 4. Cellular and combined immunodeficiency with some cutaneous manifestations.**

Disease	Number of cases	Cutaneous infections	(No.)	Dermatitis (No.)	Other manifestations (No.)
Severe combined immunodeficiency	1	1	(1)	-	-
Hyper IgM syndromes	4	Cellulitis	(1)	4	Idiopathic Thrombocytopenic Purpura (1)
		Abscesses	(2)		Maculopapular rash (1)
Chronic mucocutaneous candidiasis	7	Trush	(7)	-	-
		Perleth	(3)		
CD4+T-cell deficiency	4	Multiple wart	(3)	1	-
Hyper IgE	6	Herpes	(1)	5	Coarse face (3)
		Abscesses candida	(6)		Maculopapular rash (1)
			(4)		

**Table 5. Phagocytic immunodeficiency with some cutaneous manifestations.**

Disease	Number of cases	Cutaneous infections	(No.)	Dermatitis (No.)	Other manifestations (No.)
Primary neutropenia	4	Abscesses	(2)	-	Maculopapular rash (1)
Chronic granulomatosis disease (CGD)	34	Abscesses	(23)	-	Nose ulcer (5)
		Folliculitis	(5)		Paronychia (2)
		Impetigo	(3)		
Chediak-Higashi syndrome	4	-		-	Silvery hair (2)
Leukocyte adhesion defect	6	cellulitis	(2)	-	-
		folliculitis	(2)		
		Periodontitis	(2)		
Shwachman syndrome	4	Abscesses	(3)	-	-
		Cellulitis	(3)		
Other PIDs and cutaneous manifestations :					
Ataxia telangiectasia	62	(8)		1	Skin telangiectasia (6)
					Hyperpigmentation (1)
					Hypopigmentation (3)
					Family malignancy (17)
Wiskott Aldrich syndrome		(1)		1	-

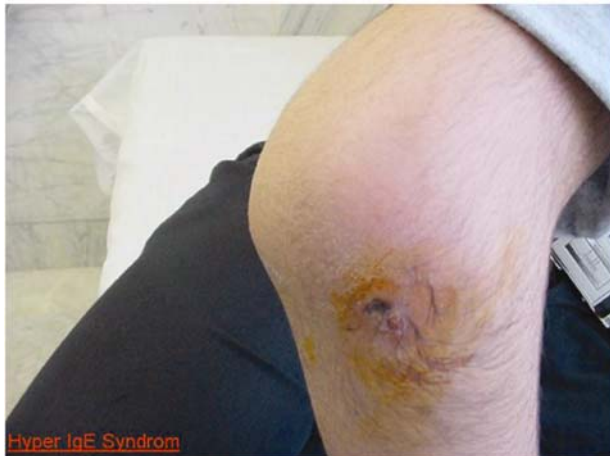## DISCUSSION

In this study most of the patients (57.3%) were males. In Japanese studies 72%, in the British studies 62% and in the Swiss studies 63% of cases consisted of males.<sup>4</sup>

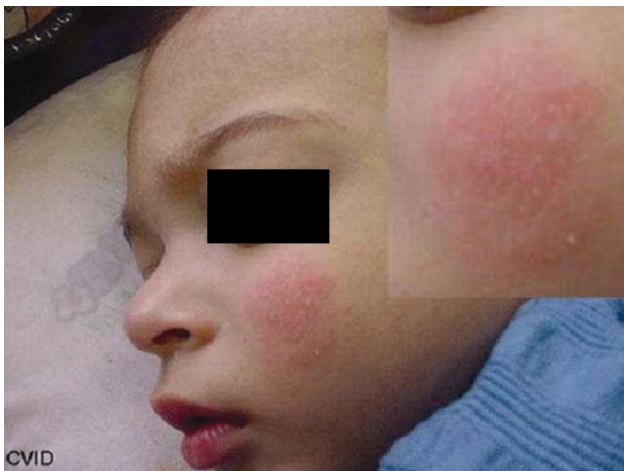There was a family history of PID in 45.5% of patients and 51.2% of their parents were relatives. In some other studies family history was reported in 25% of the cases.<sup>4</sup> Shortly after the patient is diagnosed as having a particular PID the pattern of inheritance should be described to the family and the potential for carrier detection and prenatal diagnosis can be discussed. The patients' siblings should be screened to ensure that they do not have the same disorder. In families with X-linked or autosomal dominant disorders, it is wise to discuss genetic risks again when the patient or the siblings reach the reproductive age.<sup>4</sup>

The onset of disease in 41.8% was before the first year and in 34.6% between 1-5 years. The onset of disease varied from one illness to another. In some studies about 40% of the cases were diagnosed in the first year and the other 40% by the age of 5 years.<sup>4</sup>

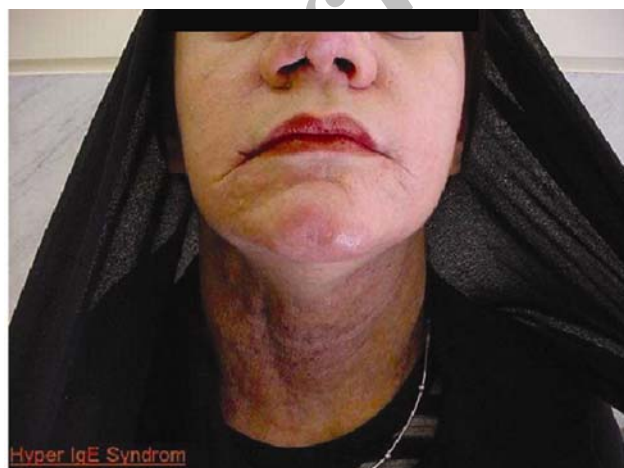
In our study those PIDs affecting antibody production were more frequent (Table 2) Similar to some other studies.<sup>5-8</sup> The skin is one of the organs in which manifestations of an immunodeficiency is reflected rather early in life.<sup>3,9</sup> 31.8% of our patients had skin manifestations at the onset of their disease. In one study by Hermazewski and Webster in 21% of cases, skin lesions were the first presenting symptoms in patients with primary antibody deficiencies.<sup>10</sup> The high frequency of cutaneous alteration in PIDs and their easy access for observation and biopsy have been generally overlooked. The fact that a high proportion of patients with PIDs, have cutaneous alterations makes a complete dermatologic examination mandatory.<sup>2</sup> In pediatric patients with failure to thrive, chronic refractory systemic manifestations often present in other family members, recurrent cutaneous infections unresponsive to adequate therapy, atypical forms of eczematous dermatitis or unusual features such as extensive telangiectasia, erythroderma or silvery hair should arouse the suspicion of PID and prompt specialized immunologic consultation should be made. 40.5% of our patients had dermatologic alterations and many of them had more than one skin lesion. In study of



**Figure 1.** Recurrent furunculosis in a patient with hyper IgE syndrome.



**Figure 2.** Dermatitis on the face of a child with CVID.



**Figure 3.** Neck dermatitis and coarse face of a woman with IgE syndrome.

## Cutaneous Manifestations of PIDs

Berron- Ruiz, et al.<sup>2</sup> 69% of PIDs had dermatologic abnormalities.

Few of PIDs have specific dermatological features but non specific manifestations are not uncommon.<sup>1,11</sup> One of the nonspecific cutaneous manifestations are infections and in many of PIDs, cutaneous infections are prominent clinical features.<sup>12</sup> In our patients cutaneous infections were the predominant cutaneous alterations, present in 47.1% of the cases. It is compatible with Berron-Ruiz study<sup>2</sup> in which cutaneous infections were found in 46% of PIDs. The majority of infections were bacterial (Table 2). Recurrent frunculosis, abscesses, folliculitis and impetigo are some manifestations of bacterial infections in PIDs (Table 3, 4, 5). In this study recurrent abscesses were seen frequently and they predominated in phagocytic defects and hyper IgE syndrome and it tended to be multiple, recurrent and difficult to control. Bacteriologic cultures should be performed, since growth of unusual organisms is not infrequent.<sup>2,13</sup> CGD were the most phagocytic disorder (Table 5). CGD is a genetically heterogenous group of disorders of phagocytic cell oxidative metabolism characterized by recurrent life-threatening infections with bacteria and fungi and dysregulated granuloma formation with onset of symptoms usually before the first year of life.<sup>14,15</sup> The earliest lesions are usually staphylococcal infections of the skin around the ears and nose, skin abscesses are common, especially in the perianal region.<sup>13</sup> The next cutaneous infection was mycosis primarily candidiasis (Tables 2-4) and it was seen more in cellular and associated ID. The extent of candidiasis involvement is variable, and ranges from recurrent, recalcitrant thrush to mild erythematous scaling plaques with a few dystrophic nails to severe generalized, crusted granulomatous plaques.<sup>13</sup> The syndrome of chronic localized candidiasis is unique because the lesions develop marked hyperkeratosis and may produce cutaneous horn formation.<sup>6,13</sup> Mucocutaneous lesions due to candida were more frequently oral, whitish, adherent plaques and paronychia.

The third type of skin infection consisted of viral infections (Table 2). The lower frequency of viral lesions such as molluscum contagiosum, condylomata and viral wart in PIDs, contrasts with their high frequency in patients with acquired immunodeficiencies, AIDS in particular.<sup>2</sup> Infants and

children with PID are rarely exposed to common viral infections. In this study multiple warts were seen in patients with CD4+ T-cell deficiency (Table 4).

Another nonspecific cutaneous alteration was eczematous dermatitis in 12.8% of patients (table 2). The lesions were mild and non characteristic and were seen mostly in hyper-IgM and hyper IgE syndrome, selective IgA deficiency, CVID, Wiskott-Aldrich syndrome and ataxia telangiectasia (Table 3, 4). Many primary immunodeficiencies are associated with dermatitis which usually begins in infancy or early childhood. In most cases, it is indistinguishable from eczema in normal individuals, however it may show a tendency to become secondarily infected, to flare up with systemic infections, and to be refractory to treatment. The types of dermatitis encountered include atopic, seborrheic, perioral, ichthyosiform and non specific.<sup>16</sup>

The other nonspecific cutaneous manifestation was maculopapular rash or morbilliform eruptions (Table 3, 4, 5). Its pathogenesis is unclear, it is sometimes caused by viral infections or it is one of the manifestations of acute graft-versus host reactions due either to maternal-fetal engraftment or to the transfusion of nonirradiated blood products after birth.<sup>1</sup>

One of the specific cutaneous manifestations of PIDs is telangiectasia, a mucocutaneous marker of ataxia telangiectasia. In this study all patients with ataxia telangiectasia had telangiectasia of eye and 6 patients had skin telangiectasia (Table 5). Another specific cutaneous manifestation of PIDs is silvery hair that in our study was present in 2 patients (Table 5). It has been a classic feature for diagnosis of Chediak-Higashi syndrome, more recently Griscelli syndrome another severe immunodeficiency and Elejalde syndrome (neuroectodermal melanolyosomal disease) with silvery hair were described.<sup>11</sup> However the differential diagnosis of Chediak-Higashi syndrome can be easily made through direct microscopic examination of the hair which shows small and large clumps of melanin irregularly arranged along the hair shafts.<sup>1</sup>

Our findings support the results of other studies and provide concepts that most PIDs have cutaneous features and because of their typical aspects, evolution and response to treatment are highly suggestive of the diagnosis. The dermatologist is particularly well suited to detect PIDs through their cutaneous features.

## REFERENCES

1. Atherton DJ, Gennery AR, Cant AJ. The neonate. In: Burns T, Breathnach S, Cox N, Griffiths C, editors. Rook's text book of dermatology. Massachusetts: Blackwell, 2004: 14.53-14.86.
2. Berron-Ruiz A, Berron-Perez R, Ruiz-Maldonaolo R. Cutaneous markers of primary immunodeficiency diseases in children. *Pediatr Dermatol* 2000; 17(2):91-6.
3. Sillevius Smitt JH, Wulfraat NM, Kuijpers TW. The skin in primary immunodeficiency disorders. *Eur J Dermatol* 2005; 15(6):425-32.
4. Richard SE, Ochs HD, Winkelstein JA. Immunodeficiency disorders: General consideration. In: Stiehm EE, Ochs HD, Winkelstein JA, editors. Immunologic disorders in infants & children. Philadelphia: Saunders, 2004: 289-356.
5. Buckley RH. The T-B and NK-cell system. In: Behrman RE, Kliegman RM, Jenson HB. Nelson text book of pediatrics. USA: Saunders, 2004: 683-701.
6. Hong R, Clement LT, Gatti RA, Kirkpatrick CH. Disorders of the T cell system. In: Stiehm RE, editor. Immunologic disorders in infants and children, Philadelphia: Sunders, 1996: 339-409.
7. Abuzakouk M, Feighery C. Primary immunodeficiency disorders in the Republic of Ireland: first report of the national registry in children and adults. *J Clin Immunol* 2005; 25(1):73-7.
8. Lim DH, Thong By, Ho Sy, Shek LP, Lou J, Leong KP, et al. Primary immunodeficiency disease in Singapore- the last 11 years. *Singapore Med J* 2003; 44(11):579-86.
9. Danl MV. Clinical immunodermatology. Philadelphia: Mosby, 1996: 147-66.
10. Chapel H, Haney M, Mishab S, Snowden N. Essentials of clinical immunology. Oxford, Blackwell, 1999: 51-76.
11. Paller AS. Primary immunodeficiencies. In: Bologna J, Jorizzo J, Rapini R, editors. Dermatology. Spain: Mosby, 2003; 832-52.
12. Tausk FA, Winkelstein JA. Cutaneous manifestations of primary immunodeficiency disease. In: Provost TT, Flynn JA, editors. Cutaneous Medicine. London: Hamilton, 2001: 263-72.
13. Paller AS. Immunodeficiency syndromes. In: Harper J, Oranje A, Prose N, editors. Text book of pediatric dermatology. Oxford: Blackwell, 2000: 1678-709.
14. Holland S, Gallin JI. Evaluation of the patient with suspected immunodeficiency. In: Mandell GI, Bennett J, Dolin R, editors. Principles and practice of infectious disease. USA: Churchill Livingstone, 2005: 149-58.
15. Buckley RH. Immunodeficiency disease. *JAMA* 1992; 268(20):2797-805.
16. Paller AS. Cutaneous manifestations of immunological disorders in children. *Adv Dermatol* 1991; 6:199-216.