

CASE REPORT

Iran J Allergy Asthma Immunol
September 2006; 5(3):143-145

Crohn's Disease and Idiopathic Thrombocytopenic Purpura in a Patient with Ectodermal Dysplasia and Immunodeficiency

Farzaneh Motamed¹, Fariborz Zandieh², and Mostafa Sedighi²

¹ Department of Gastroenterology, Tehran University of Medical Sciences, Tehran, Iran

² Department of Asthma, Allergy and Immunology, Tehran University of Medical Sciences, Tehran, Iran

Received: 23 October 2005; Received in revised form: 4 March 2006; Accepted: 4 April 2006

ABSTRACT

In this case report we will describe a rare association between anhyrotic ectodermal dysplasia (AED) and immunodeficiency and autoimmunity [in our case: Idiopathic Thrombocytopenic Purpura (ITP) and Crohn disease]. AED is a rare congenital disorder characterized by sparse hair, abnormal teeth and anhidrosis due to lack of eccrine glands. The survey of 87 cases with (AED) revealed only one Irritable Bowel Disease (IBD). AED has only two relevancies with immunodeficiency: (EDA-ID: Ectodermal Dysplasia Anhyrotic with Immunodeficiency) and APE-CED (Autoimmune polyendocrinopathy, Candidiasis and Ectodermal Dysplasia) that in our case EDA-ID is strongly suspected.

Key words: Crohn's disease; Ectodermal Dysplasia; ITP; Immunodeficiency

INTRODUCTION

Anhidrotic ectodermal dysplasia (AED) is a rare congenital disorder characterized by sparse hair, abnormal teeth and anhidrosis due to lack of eccrine glands. AED patients often complain of GI problems. The major GI problems are constipation and swallowing difficulty.^{1,2} The survey of 87 cases with (AED) revealed only one IBD.² Mucous glands of AED are hypoplastic in the bronchi, esophagus and colon, but not known in small bowel.³ These explain the frequent respiratory infections, feeding problems and constipation. Hypoplastic mucous glands might also hinder the healing process.

CASE REPORT

The patient is a 5-year old boy who because of chronic diarrhea and failure to thrive (FTT) was referred to the Department of gastroenterology of the children's medical center.

The patient had fever, moderate dehydration, FTT (all of growth indices were below 5 percentile), anhidrosis and chronic bloody diarrhea. His problem had begun from 4 months of age with recurrent dysentery and occasional vomiting, petechia, purpura and inability to sweat and episodes of high fever in warm environments.

He had also recurrent hospital admissions because of recurrent respiratory tract infections, petechia and purpura and bloody diarrhea. He is the only child of closed- related parents.

There was history of one abortion and G6PD deficiency in his mother.

Corresponding Author: Fariborz Zandieh, MD;
Department of Asthma, Allergy and Immunology, Tehran University of Medical Sciences, Tehran, Iran. Tel: (+98 21) 4408 9588, Fax: (+98 21) 4440 86997, E-mail: f_zandieh2000@yahoo.com

Physical Examination

He had several rudimentary primary teeth with gingival infections. He would not shed tears when crying. His growth and developmental milestones were all below 5 percentile.

He was dehydrated with fever and had cachexia, anodontia, anhidrosis, and frontal bossing, low set ears, pectus excavatum, dry skin, purpuric lesions on skin and mucous membranes, and no organomegaly. He had rectal prolapse, anal fissure, a large anal tag, and inguinal lymphadenopathy.

Para clinic Studies

Stool examination revealed many RBCs and WBCs, but no fat droplets, no parasites and trypsin activity was normal.

Stool culture was negative. Metabolic evaluations were normal. He had thrombocytopenia, hematuria, anemia of chronic disease, CRP (+), normal PT and PTT biochemistry and ABG. G6PD activity was low, biopsy of inguinal adenopathy was normal. Bone marrow aspiration was compatible with ITP. Bone marrow flowcytometry was normal, and echocardiographic study did not show any abnormality. EEG revealed slight abnormalities. Sweat test could not be done because of his anhidrosis, hyperthermia and flushing.

He was treated with prednisone and IVIG with improvement in his thrombocytopenia. In the last admission he was 5 years old and presented with cachexia, fever, bloody diarrhea, clubbing and anal tag. Prednisone had been stopped 5 months ago without flare up of his ITP. He had anemia and raised ESR. Barium study revealed a suspicious fistula in ileum and thickening of the mucosa. Upper endoscopy was normal, except for hiatal hernia. Abdominal sonography was normal. Colonoscopy revealed erythema and fragile mucosa with discrete different size ulcers (Figure 1).

Colonic histology revealed pus collection, granulation tissue, mild crypt branching, goblet destruction, infiltration of neutrophils, lymphocytes and plasma cells in lamina propria, cryptitis and chronic crypt destructive colitis compatible with Crohn's disease.

IgG antiIgA and endomysial antibodies were negative. CBC and Immunoelectrophoresis were normal. Palmar skin biopsy was compatible with ectodermal dysplasia (Figure 2).

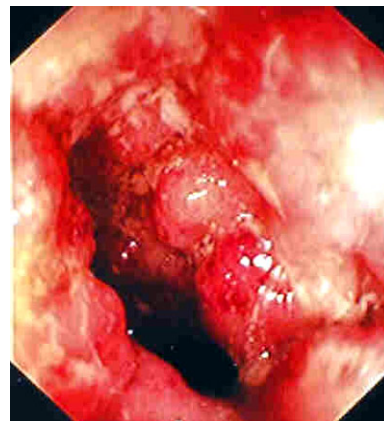


Figure 1. Erythema and fragile mucosa with discrete different size ulcers in colonoscopy.

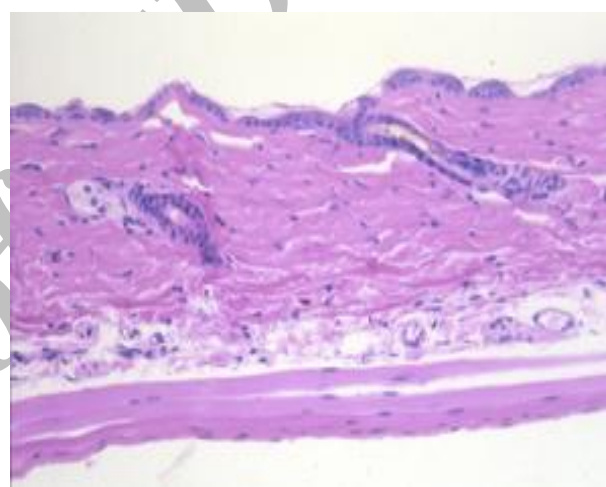


Figure 2. Diagnosis of ectodermal dysplasia with palmar skin biopsy.

Further immunological evaluations:

CD₃= 70% (Normal) CD₄ = 36% (Normal)

CD8=5% (Normal: 20 – 25%)

CD4/CD8= 6.5 (Normal: 2-2.5)

CD19= 17% (Normal)

IgG =725 and 728 (Normal)

IgM = 48 and 46 (Normal)

IgA = 140 and 100 (Normal)

Isohemagglutinin titers= 0 (It was checked four times)

NBT= 100% (Normal)

DISCUSSION

This case portrays a rare association between ED, Crohn's disease, ITP and immunodeficiency. ED is a heterogeneous group of disorders characterized by two or more of the followings findings: partial or complete

absence of sweat glands, anomalous dentition and hypotrichosis, defects of nails and eccrine and sebaceous glands. Affected children may experience episodes of high fever in warm environments. In infancy the typical facieses such as frontal bossing, malar hypoplasia, flattened nasal bridge, recessed columella, wrinkled hyperpigmented periorbital skin and prominent low set ears can not be diagnosed. Some have stenosis of lacrimal puncta, corneal opacity and cataracts.⁴ Poor development of mucous glands in the respiratory and GI tract may result in increased susceptibility to respiratory infection, purulent rhinitis, dysphonia, dysphagia and diarrhea, but IBD is very rare.⁵ 30% of affected boys die during the first 2 years of life due to hyperpyrexia or respiratory infection.

Crohn's disease (CD) is a chronic inflammatory disorder of the GI tract that manifests during childhood or adolescence in up to 25% of cases. The mucosal immune system must tightly control the balance between responsiveness and no responsiveness (tolerance) to the millions of antigens passing along the mucosal surface. CD may be a disorder of mucosal immune interpretation of the microbial environment. Genetic variants increasing susceptibility to CD, may have persisted and expanded in human owing to a beneficial effect in mediating host– microbial interactions in an unsanitary world.⁶ CD is a panenteric inflammatory process. The classic presentations of this deficiency are abdominal pain, diarrhea, poor appetite and weight loss.⁶ Probably defect in mucosal barrier in ED patients can predispose them to multiple infections and IBD.

The association of E.D and immunodeficiency (EDA-ID) has been reported in several families with X Linked inheritance.⁷ Immunologic investigations most often document normal or increased IgM and variable serum IgA, usually reduced serum IgG but sometimes normal levels, delayed or absent production of isohemagglutinin and inability to form specific

antibodies to polysaccharide antigens are common features.

Immunologic findings suggest that these patients also suffer from an immunodeficiency syndrome (EDA – ID) with some autoimmunity presentation such as: ITP, Crohn's Disease. The molecular basis of X Linked recessive anhidrotic ED with immunodeficiency has remained elusive but mutations in the IKK– gamma (NEMO) gene have been identified in patient with EDA– ID. Mutation analysis of this gene in this patient can confirm the diagnosis.⁷

In our case with recurrent diarrhea and pneumonia, FTT and absence of isohemagglutinin titer that normally reaches to at least 1/8 by the age of 2 to 4 years, an immunodeficiency has been suspected for him. Presence of ITP and Crohn's disease in our case as an autoimmune process will substantially potentiate our suspicion to this syndrome.

REFERENCES

1. Clarke A, Phillips DI, Brown R, Harper PS. Clinical aspects of X-linked hypohidrotic ectodermal dysplasia. *Arch Dis Child* 1987; 62(10):989-96
2. National Foundations for ED. GI complaints in individuals with hypohidrotic ED (christ– siemen– touraine syndrome). *Pediatr Dermatol* 1995; 12: 288-9.
3. Reed WB, Lopez DA, Landing B. Clinical spectrum of anhidrotic ectodermal dysplasia. *Arch Dermatol* 1970; 102(2):134-43.
4. Freise – Maia N, Pinheiro M: Ectodermal dysplasias--some recollections and a classification. *Birth Defects Orig Artic Ser* 1988; 24(2):3-14
5. Shouichi O, Ayako R, Taro N. IBD – like complication in anhidrotic ED. *AJG Des* 2000:3651–2.
6. Shanahan F. Crohn's disease. *Lancet* 2002; 359(9300):62-9
7. Doffinger R, Smahi A, Bessia C, Geissmann F, Feinberg J, Durandy A, ET AL. X-linked anhidrotic ectodermal dysplasia with immunodeficiency is caused by impaired NF-kappaB signaling. *Nat Genet* 2001; 27(3):277-85.