

CASE REPORT

Iran J Allergy Asthma Immunol
March 2012; 11(1): 79-81.

Pneumomediastinum is a Possible Acute Complication of Severe Occupational Asthma

Gianni Pala, Patrizia Pignatti, and Gianna Moscato

Allergy and Immunology Unit, Fondazione 'Salvatore Maugeri', Institute of Care and Research, Scientific Institute of Pavia, Italy

Received: 2 August 2011 ; Accepted: 17 September 2011

ABSTRACT

Occupational asthma has been reported to be the most common chronic respiratory occupational disease in many developed countries, and as with other occupational lung diseases, occupational asthma is potentially preventable.

We report the case of a 24-year-old baker who experienced pneumomediastinum as a consequence of workplace exposure.

This is the first report of pneumomediastinum as an acute complication of occupational asthma, and it exemplarily shows that the lack of medical surveillance at the workplace may lead to an acute, although unusual, complication.

Keywords: Baker; Occupational asthma; Occupational rhinitis; Pneumomediastinum; Wheat flour.

INTRODUCTION

Occupational asthma (OA) is the most common chronic respiratory occupational disease in many developed countries¹ and is the cause of long-term clinical and socio-economic consequences. As with other occupational lung diseases, OA is potentially preventable and medical surveillance plays a key role in prevention.

Benefits for the individual worker relate to the early diagnosis of occupational sensitization or disease at a time when intervention is most likely to minimize subsequent morbidity.²

Corresponding Author: Gianni Pala, MD;
Allergy and Immunology Unit, Fondazione 'Salvatore Maugeri',
Institute of Care and Research, Scientific Institute of Pavia, Via
Maugeri 10, Pavia, Italy. Tel: (+39 0382) 592 941, Fax: (+39 3082)
592 086, E-mail: giannipalass@libero.it

CASE DESCRIPTION

In July, 2010, a 24-year-old man, presented to us with a 2-year-history of rhinoconjunctivitis, cough, shortness of breath and wheezing. Symptoms had developed after he had worked as a baker for 4 years, occurred only when he was exposed to wheat flour at the workplace and improved during weekends and holidays. For two years symptoms were treated, but did not control, by daily use of short-acting beta-agonists, prescribed by the GP as relief medication. He was never submitted to medical surveillance at the workplace, and never consulted a specialist. While working in 2009 Christmas Eve's night, when bread production was increased, he started to complain of progressively worsening shortness of breath and cough inducing vomiting. Few hours later, at the end of work-shift, he also experienced chest pain. He was admitted to the Emergency Department, where chest radiograph

and subsequent CT scan showed the presence of spontaneous pneumomediastinum (SPM). The patient was discharged without any advice of avoiding flour exposure, and he returned to work two weeks later. During working time he reported frequent use of relief medication.

He came to our observation nine months after the acute event. Firstly we prescribed peak expiratory flow (PEF) monitoring during a two-week period at-work and a two-week period off-work.^{1,3} A significant variability depending on workplace exposure was registered (Figure 1). On successive admission to our Department, no clinical history or signs of atopy were detected; baseline spirometry was normal; fraction of exhaled nitric oxide was elevated (52 ppb). Methacholine challenge test revealed marked bronchial hyperresponsiveness (PD₂₀FEV₁: 206 µg). Skin prick test with wheat flour extract (Lofarma Allergeni; Milan, Italy) was positive (wheal size 15x8 mm)⁴ and serum specific IgE to wheat flour (IMMULITE, Siemens Healthcare Diagnostics, Tarrytown, New York) were 5.79 kU/l (negative <0.1 kU/l). The specific inhalation challenge, which is considered the “gold standard” for OA diagnosis, was not performed due to the previous history of PM. On the basis of the clinical history, the significant PEF rate variability, bronchial hyperresponsiveness and sensitization to flour, a diagnosis of occupational rhinitis and asthma due to wheat flour complicated by SPM was made^{1,3,5} and the patient was advised to avoid any further exposure to the offending agent.

DISCUSSION

SPM, defined by the appearance of free air in the mediastinum that is not preceded by trauma, surgery, or other medical procedures, was initially introduced into the medical literature in 1939 by Hamman,⁶ from

which “Hamman sign” (air crepitus heard on auscultation with each heart beat) is derived. SPM has been described predominantly in young adult men exposed to a sudden pressure change within the intrathoracic cavity. The incidence appears to be increasing in more recent reports, but this may reflect greater physician awareness and better access to quality investigation.⁷ The pathogenesis of this condition involves a sudden increase in intrathoracic pressure resulting in an increased intraalveolar pressure. The pressure differential created within the pulmonary parenchyma leads to alveolar rupture with further leakage of air throughout the interstitium and bronchovascular tissue sheath following a centripetal pattern toward the mediastinum.⁸ Bronchial constriction and cough during severe asthma exacerbation^{9,10} are included among the various precipitating events triggering a strong Valsalva manoeuvre, creating the pressure differential needed for its genesis. Nevertheless, this is the first report of SPM as an acute complication of OA. Despite baking is a well known occupation at high risk for OA,¹¹⁻¹³ our patient was not submitted to medical surveillance at the workplace, nor received education on the effects that the workplace may have in causing or exacerbating asthma. This lead not only to delay in diagnosis, but also to an acute, although unusual, complication. Only when severe event eventually convinced the patient, two years after the onset of work-related symptoms, he referred to a specialist. The present case also underlines the need that physicians, including those working in the emergency departments, be aware of the possible role of the workplace in the genesis of respiratory disorders, especially in adult-onset asthma, and of its possible acute complications, in order to prescribe in-depth investigations.

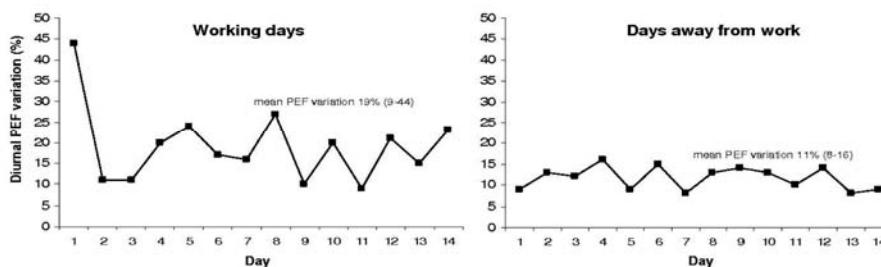


Figure 1. Serial measurements of peak expiratory flow (PEF), performed during a period at-work and again after a period off-work, showed significant diurnal variation (i.e. 20% fall in peak flow from maximum to minimum) on 7 working days, with minimum values recorded after the work shift, whereas no significant changes were observed on days outside from the workplace.

Severe Occupational Asthma

Statement of Conflicts of Interest

All the authors have no conflict of interest to declare.

ACKNOWLEDGMENTS

Pala G and Moscato G performed diagnostic tests. Pignatti P performed the laboratory tests. All authors participated to the writing of the paper. All authors read and approved the final manuscript

REFERENCES

1. Tarlo SM, Balmes J, Balkissoon R, Beach J, Beckett W, Bernstein D, et al. Diagnosis and management of work-related asthma: American College Of Chest Physicians Consensus Statement. *Chest* 2008; 134(3 Suppl):1-41.
2. Tarlo SM, Liss GM. Prevention of occupational asthma. *Curr Allergy Asthma Rep* 2010; 10(4):278-86.
3. Moscato G, Godnic-Cvar J, Maestrelli P. Statement on self-monitoring of peak expiratory flows in the investigation of occupational asthma. Subcommittee on Occupational Allergy of European Academy of Allergy and Clinical Immunology. *J Allergy Clin Immunol* 1995; 96(3):295-301.
4. Bernstein IL, Li JT, Bernstein DI, Hamilton R, Spector SL, Tan R, et al. Allergy diagnostic testing: an updated practice parameter. *Ann Allergy Asthma Immunol* 2008; 100(3 Suppl 3):1-148.
5. Moscato G, Vandenplas O, Gerth Van Wijk R, Malo JL, Quirce S, Walusiak J, et al. EAACI Task Force on Occupational Rhinitis. Occupational rhinitis. *Allergy* 2008; 63(8):969-80.
6. Hamman L. Spontaneous mediastinal emphysema. *Bull Johns Hopkins Hosp* 1939; 64:1-21.
7. McMahon DJ. Spontaneous pneumomediastinum. *Am J Surg* 1976; 131(5):550-51.
8. Caceres M, Ali SZ, Braud R, Weiman D, Garrett HE Jr. Spontaneous pneumomediastinum: a comparative study and review of the literature. *Ann Thorac Surg* 2008; 86(3):962-66.
9. Abolnik I, Lossos IS, Breuer R. Spontaneous pneumomediastinum. A report of 25 cases. *Chest* 1991; 100(1):93-95.
10. Newcomb AE, Clarke CP. Spontaneous pneumomediastinum: a benign curiosity or a significant problem? *Chest* 2005; 128(5):3298-302.
11. Kogevinas M, Zock JP, Jarvis D, Kromhout H, Lillienberg L, Plana E, et al. Exposure to substances in the workplace and new-onset asthma: an international prospective population-based study (ECRHS-II). *Lancet* 2007; 370(9584):336-41.
12. Bittner C, Grassau B, Frenzel K, Baur X. Identification of wheat gliadins as an allergen family related to baker's asthma. *J Allergy Clin Immunol* 2008; 121(3):744-49.
13. Moscato G, Pala G, Boillat MA, Folletti I, Gerth van Wijk R, Olgiati-Des Gouttes D, et al. EAACI Position Paper: Prevention of work-related respiratory allergies among pre-apprentices or apprentices and young workers. *Allergy* 2011; 66(9):1164-73.