

ORIGINAL ARTICLE

Iran J Allergy Asthma Immunol
April 2015; 14(2):126-132.

The Diagnosis of Hyper Immunoglobulin E Syndrome Based on Project Management

Shiva Saghafi¹, Zahra Pourpak^{1,2}, Cristina Glocker³, Franziska Nussbaumer³,
Abdolreza Babamahmoodi⁴, Bodo Grimbacher³, and Mostafa Moin^{1,2}

¹ Immunology, Asthma and Allergy Research Institute, Tehran University of Medical Sciences, Tehran, Iran

² Department of Immunology and Allergy, Children Medical Center,
Tehran University of Medical Sciences, Tehran, Iran

³ Center for Chronic Immunodeficiency (CCI), University Medical Center
and University of Freiburg, Freiburg, Germany

⁴ Health Management Research Center, Baqiyatallah University of Medical Sciences, Tehran, Iran

Received: 24 May 2014; Received in revised form: 16 July 2014; Accepted: 28 July 2014

ABSTRACT

Hyperimmunoglobulin E Syndrome (HIES) is a complex primary immunodeficiency characterized by both immunologic and non-immunologic manifestations. High serum IgE level, eosinophilia, eczema, recurrent skin and lung infections constitute the immunologic profile of HIES, whereas characteristic facial appearance, scoliosis, retained primary teeth, joint hyperextensibility, bone fractures following minimal trauma and craniosynostosis are the main non-immunologic manifestations. The diagnosis of HIES cannot be made by routine immunologic tests.

As the main characteristic laboratory abnormalities of this syndrome are highly elevated serum IgE levels and eosinophilia; both features have a broad spectrum of differential diagnosis. The purpose of this essay was presenting the best way for diagnosis management of HIES. Based on the genetic reports of patients of the Center for Chronic Immunodeficiency (CCI) as a single center experience, and applying project management (PM) in health care research projects, we sought the best way for a rapid diagnosis of HIES.

The combination of project management principles with immunologic and genetic knowledge to better define the laboratory and clinical diagnosis lead to an improvement of the management of patients with HIES. These results are shown in one "Decision Tree" which is based on 342 genetic reports of the CCI during the past ten years.

It is necessary to facilitate the diagnostic analysis of suspected HIES patients; applying project management in health care research projects provides a better and more accurate diagnosis eventually leading to a better patients' care. This Abstract was presented at 16th Biennial Meeting of the European Society for Immunodeficiencies (ESID 2014), Prague, Czech Republic.

Keywords: Diagnosis; Hyperimmunoglobulin E Syndrome; Management; Project

Corresponding Authors: Mostafa Moin, MD;
Immunology Asthma and Allergy Research Institute, Tehran
University of Medical Sciences, Tehran, Iran. Tel: (+98 21) 6691
9587, Fax: (+98 21) 6642 8995, E-mail: mmoin@tums.ac.ir

Bodo Grimbacher, MD;
Center for Chronic Immunodeficiency, University Medical Center
and University of Freiburg, Freiburg, Germany. Tel: (+49 761) 2707
7731, E-mail: bodo.grimbacher@uniklinik-freiburg.de

INTRODUCTION

Hyperimmunoglobulin E Syndrome (HIES) is a rare primary immunodeficiency characterized by extremely high serum IgE level, eosinophilia, eczema-like dermatitis, skin and pulmonary abscesses and recurrent pneumonia which can result in formation of pneumatoceles.¹ The abscesses are frequently caused by *Staphylococcus aureus* and are typically 'cold' as they lack classic signs of inflammation such as redness, warmth, or pain.^{2,3} Additionally, chronic candidiasis of the mucous membranes and/or the nail bed has been observed in most HIES patients.¹

Most cases of HIES are sporadic, but both autosomal dominant (AD-HIES) and autosomal recessive traits of inheritance (AR-HIES) have been described.

The AD form of HIES and most sporadic cases have extra-immune manifestations, defining AD-HIES as a multisystem disease. Skeletal abnormalities such as hyperextensibility of the joints, scoliosis, and multiple bone fractures can variably be seen in patients with AD-HIES.¹ Moreover, many patients show a typical facial appearance and have retained primary teeth.⁴ In addition, this form is associated with an increased risk of malignancy, and particularly non-Hodgkin lymphomas.⁵ Nevertheless, the clinical phenotype of individual patients is highly variable.

AD-HIES is predominantly caused by dominant negative mutations in the Signal Transducer and Activator of Transcription (STAT)3. STAT3 is part of multiple Jak-STAT signaling pathways, which plays a key role in the signal transduction of a broad range of cytokines and is crucial for the IL-6- and IL-21-mediated regulation of Th17 cells.⁶⁻⁸

In contrast to the syndromic character of AD-HIES, the AR variant is characterized by recurrent viral infections, extreme eosinophilia, and neurological complications, whereas skeletal and dental abnormalities seen in AD-HIES are absent.⁹ Homozygous mutations of the dedicator of cytokinesis 8 (*DOCK8*) gene have been shown to be responsible for many, although not all, cases of AR-HIES.^{10,11} Since the discovery that loss-of-function mutations in *DOCK8* underlie AR-HIES, an estimated more than 100 patients worldwide have been identified. *DOCK8* deficiency appears to impair CD4+ and CD8+ T-cell proliferative responses, as well as B- and T-cell memory.¹²

In addition to *STAT3* and *DOCK8* mutations, recently, homozygous mutations in the phosphoglucomutase 3 (*PGM3*) have been described in nine patients from four consanguineous families with recurrent infections and elevated serum IgE levels, but normal *STAT3* and *DOCK8*.¹³ The human phosphoglucomutases (PGMs) belong to the family of phosphohexose mutases which are involved in the reversible conversion of glucose-1-phosphate (Glc-1-P) to glucose-6-phosphate (Glc-6-P).

Although defective Th17 cell differentiation occurs through different mechanisms in patients with AR-HIES versus patients with AD-HIES, reduced numbers of Th17 cells are seen in both the dominant and the recessive form of HIES.¹⁴⁻¹⁶ In contrast, normal counts of Th17 cells have been reported in patients with atopic dermatitis who reveal some clinical and laboratory similarities with HIES patients, therefore Th17 cell counts could be a key finding for the differential diagnosis of HIES cases.¹⁷

The purpose of this essay was to combine project management principles with immunology and genetics to organize a better diagnosis and management of HIES. Although genetic testing is essential in diagnosis and the new classification is based upon genetic developments,¹⁸ genetic diagnosis should be done targeted to save time and costs. In the absence of a definitive known genetic test, the diagnosis might be easier by incorporation of clinical and laboratory findings with project management principles.

Methodology

A methodology is required as each project needs to go through a process. An important input to the design of the methodology is a project management maturity survey done across all of its sections and levels.¹⁹ Project management (PM) is the application of knowledge, skills and techniques to execute projects effectively and efficiently. It is the discipline of organizing a project to achieve the goals and to work as an essential key professional skill for a successful research development.²⁰ PM is the process by which a project achieves its stated objectives and requires some elaboration such as this Health Care Project. The team collaboration and connection must be conducted by the principal investigator.²¹

The tools and techniques applied in this PM could help us to process the cases' clinical and laboratory findings as an input to the output of diagnosis and

finding the HIES cases (Figure 1). An improved diagnosis and treatment management will result in a better outcome for these patients and their families and finally for social health management.²²

The outcome by the recognition of these cases may cause a better supervision by a clinical immunologist interdisciplinary of the other specialists care that overall are defined “Science Team” in this project management.

Patients will be evaluated for immunological tests by clinical and laboratory technologists under agreement of Ethics Committee and followed longitudinally by specialists in immunology, dermatology, neurology, radiology, dental health, bone metabolism and finally genetics.²³

The impact of these efforts is to increase awareness, facilitate recognition, and promote optimal treatment for patients with this kind of primary immunodeficiency disorder worldwide.

Clinical and Laboratory Findings

Recurrent pulmonary infections along with ‘cold’ skin and lung abscesses are the most prominent symptoms of HIES that can lead to diagnosis. Positive immunological tests such as blood eosinophilia at least 2SD above the normal range (higher than 700cells/ μ L) and high serum IgE level associated with a cut-off point of more than 2000 IU/mL are the hallmark of the syndrome.¹⁵ However, serum IgE levels vary widely over time and do not correlate with the clinical presentation of the patients²⁴ occasionally reaching normal values despite the persistence of symptoms.²⁵

In 1999, the National Institutes of Health (NIH) clinical HIES scoring system based on 20 clinical and

laboratory findings was introduced as a diagnostic tool. A point scale was developed: more specific and objective findings were assigned more points. Scores of at least 40 points suggested HIES, whereas a score below 20 made the diagnosis unlikely. For intermediate values, no firm conclusion could be reached.

This clinically validated scoring system which combines the immunologic and non-immunologic features, has facilitated the clinical diagnosis of AD-HIES and should therefore preferably be used.²⁶

Further to this, an alternative scoring system to distinguish AD-HIES patients with and without *STAT3* mutations has been suggested by our group.²⁷

In the patients described here, the medical history in the diagnosis of HIES is obviously the starting-point due to the patient’s immunologic background. The clinical and laboratory aspects of *STAT3*, *DOCK8* and *PGM3* deficiencies have overlapping but distinct features which makes the management of these patients important.²⁸

The diagnostic experience of 342 HIES patients of one single center (CCI), is summarized in figure 2.

Out of the 342 HIES patients referred to our center, 207 were either sporadic showing an AD-HIES phenotype or had an AD trait of inheritance and hence were sequenced on *STAT3*. 102 of the 207 patients whose PCR products were sequenced, were found to carry a heterozygous *STAT3* mutation, 105 were *STAT3* wild type.

These 105 *STAT3* wild type patients, additional to the 135 patients diagnosed with AR inheritance were subjected to homozygosity mapping. Seventeen patients showed homozygosity on chromosome 6 the locus of *PGM3*, whereas 74 showed homozygosity on

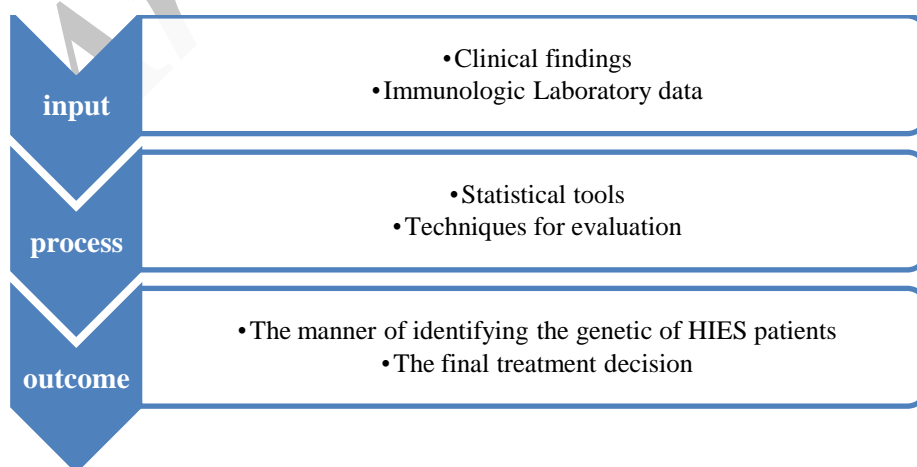


Figure 1. Diagnostic Process Framework of Hyper IgE Syndrome project

Hyper IgE Syndrome Diagnosis

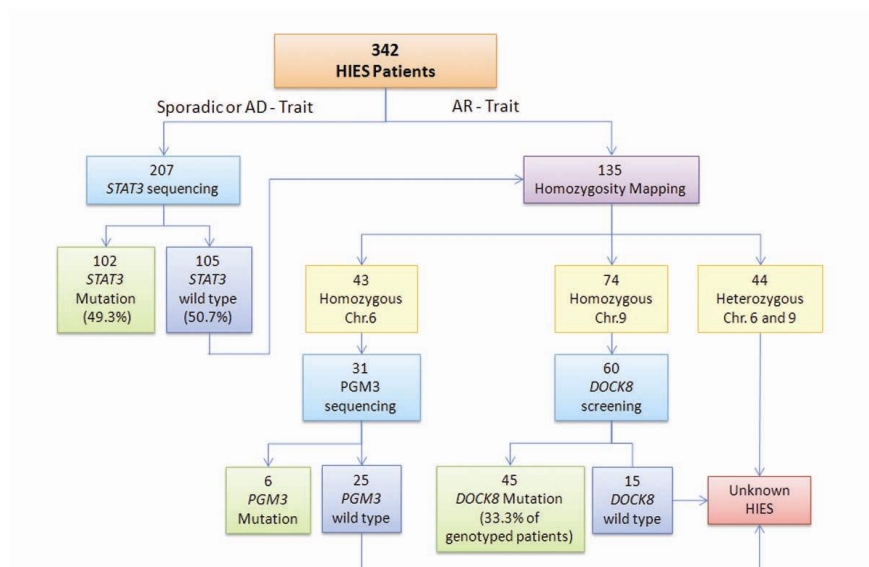


Figure 2. Genetic report of 342 HIES patients as a single center experience in Center of Chronic Immunodeficiency (CCI) (during last ten years)

chromosome 9 the locus *DOCK8*. Subsequent sequencing of these patients on *PGM3* or *DOCK8* revealed homozygous *PGM3* mutations in six patients and 45 homozygous *DOCK8* mutations. Overall of the 342 patients referred to our center 153 were found to carry mutations in one of the three genes analyzed,

the remaining 189 patients have either not yet been sequenced or carry a, to date, unknown mutation.

Based on this single center experience, we propose the following management of patients with the clinical diagnosis of HIES (Figure 3).

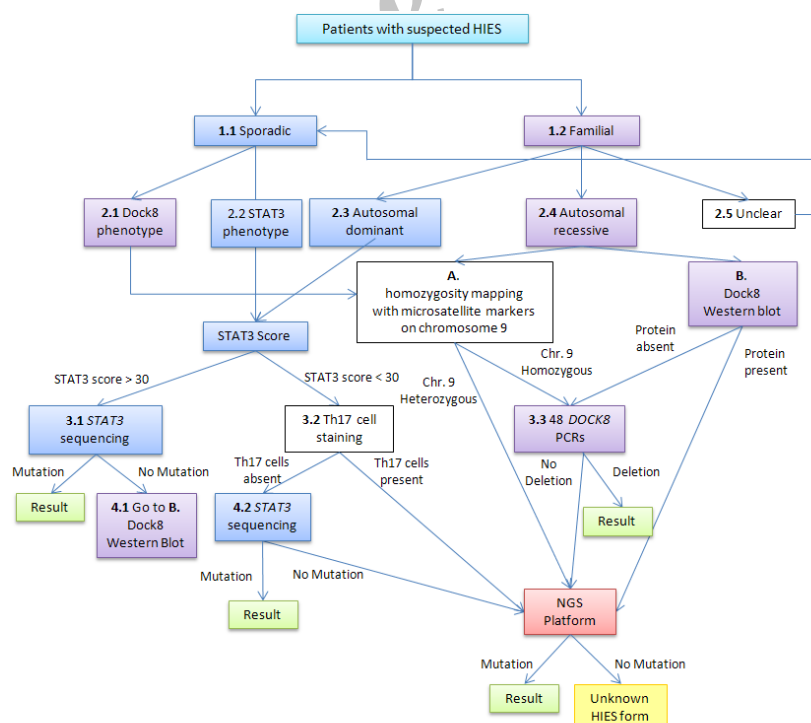


Figure 3. Decision tree for diagnosis management of Hyper IgE Syndrome Patients

Following a decision tree (figure 3 – boxes 1.1 to 4.2), the first thing to assess is whether the patient is a sporadic patient or has positive family history (1.1 and 1.2). Sporadic HIES patients, without family history, are further subdivided in two groups based on their phenotype (2.1 and 2.2). A patient presenting with *DOCK8* or AR-HIES phenotype (2.1) will be subjected to homozygosity mapping on chromosome 9, the *DOCK8* locus (A). If, on the other hand, the patient presents with an AD-HIES phenotype (2.2) and has a *STAT3* score of more than 30 points he will undergo *STAT3* sequencing (3.1). The detection of a *STAT3* mutation leads to the result, whereas the absence of a mutation induces further investigation. In this case we propose to continue with western blotting for *DOCK8*, to assess the presence or absence of the *DOCK8* protein (B).

A sporadic patient with AD-HIES phenotype but negative *STAT3* score will be analyzed for the presence or absence of Th17 cells (3.2). The absence of Th17 cells suggests the presence of a *STAT3* mutation and leads therefore to *STAT3* sequencing (4.2). The detection of a *STAT3* mutation gives the result, whereas the absence of a mutation involves further investigation. In this event we propose to continue with Next Generation Sequencing (NGS).

Like sporadic patients, patients with positive family history are further subdivided in groups according to their phenotype in AD, AR or unclear (2.3, 2.4 and 2.5). Familial cases presenting an AD phenotype will follow the same route as the sporadic patients with dominant phenotype (2.2). On the other hand, if the patient has positive familial history and recessive phenotype (2.4), we propose to do either genotyping with microsatellite markers for homozygosity mapping on the *DOCK8* locus (A), or western blotting to assess *DOCK8* protein expression (B).

Both, homozygosity on chromosome 9 as well as the absence of detectable *DOCK8* protein will be followed by the assessment of deletions within the *DOCK8* gene. For this purpose all 48 exons of *DOCK8* are amplified by PCR (3.3). The absence of one or more exons confirms the existence of a deletion within the gene. If, in contrast, all 48 exons of *DOCK8* can be amplified by PCR or *DOCK8* protein is detectable by western blotting the patient will be sequenced on NGS platform. Sequencing on NGS platform will also be performed if the patient is heterozygous on

chromosome 9.

The analysis of a familial HIES patient with unclear phenotype and/or inheritance (2.5), will follow the same route as the analysis of sporadic cases.

Patients with confirmed *DOCK8* deficiency can undergo hematopoietic stem cell transplantation.²⁹⁻³² Potential management strategies of HIES include continuous supportive treatment with antifungal drugs and antibiotic treatments but this is not our focus in this attempt.

DISCUSSION

The purpose of this study was to combine management principles with immunological and genetic knowledge to improve the clinical diagnosis and management of HIES patients and to advance our health care knowledge in order to create better patients' care.

HIES is a complex, multisystem disorder that apart from eosinophilia and high level of serum IgE, remains a syndrome that lacks specific diagnostic criteria. As we do not have a unique specific immunologic or molecular marker for the diagnosis, clinicians must recognize clinical symptoms along with laboratory findings, which are monitored over the years, to make the diagnosis.³³

In HIES patients, the medical history of the patients represents the starting-point due to the patients' immunologic background. HIES is a complex and heterogeneous disease and the patients require interdisciplinary care by specialists in pediatrics/internal medicine, pneumonology, dermatology, surgery, stomatology, neurology, oncology, and psychology under the clinical immunologist's supervision.²³ The functional manager or principal investigator is concerned with resourcing specialists and the technical inputs to the project. Functional managers manage team members who deliver work to achieve project activities. The project team is responsible for actually executing the work (activities) needed to deliver the results required.¹⁹

To the best of our knowledge, a few articles have been published in diagnosis management of primary immunodeficiency syndromes and only two articles correlated to HIES diagnosis management were found and compared.^{22,34}

Bonilla et al provided six algorithms for the diagnosis and management of primary

immunodeficiency syndromes in 2005. HIES which was categorized as phagocyte defects, has a place in the related algorithm with an undefined phagocyte defect.²² According to the major clinical manifestations of HIES in the relevant article and considering the summary statements related to this syndrome, it is obvious that the AR type of this syndrome have recently been described when the management article was reported.⁹

Bousfiha et al categorized immunological anomalies in eight groups in 2013. They started by clinical features and combined routine immunological investigations to suggest a phenotypic classification that forms the basis for diagnostic trees.³⁴ HIES is placed in two of the diagnostic figures that corresponds to the 8 Primary Immunodeficiency Diseases (PID) groups in the International Union of Immunological Societies (IUIS) classification; in the algorithm of well-defined syndromes with immunodeficiencies and as a distinctive clinical features of combined T- and B- cell immunodeficiencies. In this effort the tree-based decision making process was based on the observed clinical and/or biological phenotype whilst in our present decision tree, *STAT3* scoring and some immunologic specific results (homozygosity mapping, western blotting and Th17) were conductor.

The aim of this article is to illuminate and to inform the health care systems for uniform evaluation toward the diagnosis management and control of the problems of these patients.

Ultimately the impact of this effort is to increase awareness, facilitate recognition and promote health care knowledge for diagnosis of patients with this kind of primary immunodeficiency disorder worldwide and plan to apply management techniques in health care projects.

Although the HIES is a rare disease, but a wide range of diseases by different genetic causes are in its differential diagnosis (as Omenn syndrome, Netherton syndrome, Wiskott-Aldrich syndrome)³⁵.

So, it is necessary to provide facilities for molecular and genetic diagnostic tests for all suspected HIES patients and the decision tree will conduct in this extensive manner and make easy the way to diagnosis and management.

We recommend a multi-center study for involving patients from all ethnic groups for testing and to qualify this proposed decision tree.

ACKNOWLEDGEMENTS

This Project was supported by collaboration of Tehran University of Medical Sciences, the German Federal Ministry of Education and Research (BMBF 01 EO 0803) and Deputy of Research and Technology, Ministry of Health and Medical Education, Islamic Republic of Iran.

REFERENCES

1. Grimbacher B, Holland SM, Gallin JI, Greenberg F, Hill SC, Malech HL, et al. Hyper-IgE syndrome with recurrent infections--an autosomal dominant multisystem disorder. *N Engl J Med* 1999; 340(9):692-702.
2. Chamlin SL, McCalmont TH, Cunningham BB, Esterly NB, Lai CH, Mallory SB, et al. Cutaneous manifestations of hyper-IgE syndrome in infants and children. *J Pediatr* 2002; 141(4):572-5.
3. Minegishi Y, Saito M. Cutaneous manifestations of Hyper IgE syndrome. *Allergol Int* 2012; 61(2):191-6.
4. O'Connell AC, Puck JM, Grimbacher B, Facchetti F, Majorana A, Gallin JI, et al. Delayed eruption of permanent teeth in hyperimmunoglobulinemia E recurrent infection syndrome. *Oral Surg Oral Med Oral Pathol Oral Radiol Endod* 2000; 89(2):177-85.
5. Leonard GD, Posadas E, Herrmann PC, Anderson VL, Jaffe ES, Holland SM, et al. Non-Hodgkin's lymphoma in Job's syndrome: a case report and literature review. *Leuk Lymphoma* 2004; 45(12):2521-5.
6. Buckley RH. The hyper-IgE syndrome. *Clin Rev Allergy Immunol* 2001; 20(1):139-54.
7. Holland SM, DeLeo FR, Elloumi HZ, Hsu AP, Uzel G, Brodsky N, et al. *STAT3* mutations in the hyper-IgE syndrome. *N Engl J Med* 2007; 357(16):1608-19.
8. Minegishi Y, Saito M, Tsuchiya S, Tsuge I, Takada H, Hara T, et al. Dominant-negative mutations in the DNA-binding domain of *STAT3* cause hyper-IgE syndrome. *Nature* 2007; 448(7157):1058-62.
9. Renner ED, Puck JM, Holland SM, Schmitt M, Weiss M, Frosch M, et al. Autosomal recessive hyperimmunoglobulin E syndrome: a distinct disease entity. *J Pediatr* 2004; 144(1):93-9.
10. Engelhardt KR, McGhee S, Winkler S, Sassi A, Woellner C, Lopez-Herrera G, et al. Large deletions and point mutations involving the dedicator of cytokinesis 8 (*DOCK8*) in the autosomal-recessive form of hyper-IgE syndrome. *J Allergy Clin Immunol* 2009; 124(6):1289-302.
11. Zhang Q, Davis JC, Lamborn IT, Freeman AF, Jing H,

- Favreau AJ, et al. Combined immunodeficiency associated with DOCK8 mutations. *N Engl J Med* 2009; 361(21):2046-55.
12. Zhang Q, Davis JC, Dove CG, Su HC. Genetic, clinical, and laboratory markers for DOCK8 immunodeficiency syndrome. *Dis Markers* 2010; 29(3-4):131-9.
13. Sassi A, Lazaroski S, Wu G, Haslam SM, Fliegauf M, Mellouli F, et al. Hypomorphic homozygous mutations in phosphoglucomutase 3 (PGM3) impair immunity and increase serum IgE levels. *J Allergy Clin Immunol* 2014; 133(5):1410-9.
14. Al Khatib S, Keles S, Garcia-Lloret M, Karakoc-Aydiner E, Reisli I, Artac H, et al. Defects along the T(H)17 differentiation pathway underlie genetically distinct forms of the hyper IgE syndrome. *J Allergy Clin Immunol* 2009; 124(2):342-8.
15. Grimbacher B, Holland SM, Puck JM. Hyper-IgE syndromes. *Immunol Rev* 2005; 203:244-50.
16. McDonald DR. TH17 deficiency in human disease. *J Allergy Clin Immunol* 2012; 129(6):1429-35.
17. Schimke LF, Sawalle-Belohradsky J, Roesler J, Wollenberg A, Rack A, Borte M, et al. Diagnostic approach to the hyper-IgE syndromes: immunologic and clinical key findings to differentiate hyper-IgE syndromes from atopic dermatitis. *J Allergy Clin Immunol* 2010; 126(3):611-7.
18. Al-Herz W, Bousfiha A, Casanova JL, Chapel H, Conley ME, Cunningham-Rundles C, et al. Primary immunodeficiency diseases: an update on the classification from the international union of immunological societies expert committee for primary immunodeficiency. *Front Immunol* 2011; 2:54.
19. Frigenti E, Comminos D. *The Practice of Project Management: a guide to the business-focused approach*: Kogan Page Publishers; 2002.
20. Lewis JP. *Fundamentals of project management: developing core competencies to help outperform the competition*: AMACOM Div American Mgmt Assn; 2002.
21. Makar R. Value of Project Management in Health Care Research. *PM World Today* 2010; 12(8):1-7.
22. Bonilla FA, Bernstein IL, Khan DA, Ballas ZK, Chinen J, Frank MM, et al. Practice parameter for the diagnosis and management of primary immunodeficiency. *Ann Allergy Asthma Immunol* 2005; 94(5 Suppl 1):S1-63.
23. Szczawinska-Poplonyk A, Kyrcer Z, Pietrucha B, Heropolitanska-Pliszka E, Breborowicz A, Gerreth K. The hyperimmunoglobulin E syndrome—clinical manifestation diversity in primary immune deficiency. *Orphanet J Rare Dis* 2011; 6:76.
24. Buckley RH, Becker WG. Abnormalities in the regulation of human IgE synthesis. *Immunol Rev* 1978; 41:288-314.
25. Erlewyn-Lajeunesse MD. Hyperimmunoglobulin-E syndrome with recurrent infection: a review of current opinion and treatment. *Pediatr Allergy Immunol* 2000; 11(3):133-41.
26. Grimbacher B, Schaffer AA, Holland SM, Davis J, Gallin JI, Malech HL, et al. Genetic linkage of hyper-IgE syndrome to chromosome 4. *Am J Hum Genet* 1999; 65(3):735-44.
27. Woellner C, Gertz EM, Schaffer AA, Lagos M, Perro M, Glocker EO, et al. Mutations in STAT3 and diagnostic guidelines for hyper-IgE syndrome. *J Allergy Clin Immunol* 2010; 125(2):424-32.
28. Chu EY, Freeman AF, Jing H, Cowen EW, Davis J, Su HC, et al. Cutaneous manifestations of DOCK8 deficiency syndrome. *Arch Dermatol* 2012; 148(1):79-84.
29. Barlogis V, Galambun C, Chambost H, Lamoureux-Toth S, Petit P, Stephan JL, et al. Successful allogeneic hematopoietic stem cell transplantation for DOCK8 deficiency. *J Allergy Clin Immunol* 2011; 128(2):420-22.
30. Bittner TC, Pannicke U, Renner ED, Notheis G, Hoffmann F, Belohradsky BH, et al. Successful long-term correction of autosomal recessive hyper-IgE syndrome due to DOCK8 deficiency by hematopoietic stem cell transplantation. *Klin Padiatr* 2010; 222(6):351-5.
31. Gatz SA, Benninghoff U, Schutz C, Schulz A, Honig M, Pannicke U, et al. Curative treatment of autosomal-recessive hyper-IgE syndrome by hematopoietic cell transplantation. *Bone Marrow Transplant* 2011; 46(4):552-6.
32. McDonald DR, Massaad MJ, Johnston A, Keles S, Chatila T, Geha RS, et al. Successful engraftment of donor marrow after allogeneic hematopoietic cell transplantation in autosomal-recessive hyper-IgE syndrome caused by deficiency of cytokines 8 deficiency. *J Allergy Clin Immunol* 2010; 126(6):1304-5.
33. Ohameje NU, Loveless JW, Saini SS. Atopic dermatitis or hyper-IgE syndrome? *Allergy Asthma Proc* 2006; 27(3):289-91.
34. Bousfiha AA, Jeddane L, Ailal F, Al Herz W, Conley ME, Cunningham-Rundles C, et al. A phenotypic approach for IUIS PID classification and diagnosis: guidelines for clinicians at the bedside. *J Clin Immunol* 2013; 33(6):1078-87.
35. Notarangelo LD, Fischer A, Geha RS, Casanova JL, Chapel H, Conley ME, et al. Primary immunodeficiencies: 2009 update. *J Allergy Clin Immunol* 2009; 124(6):1161-78.