

CASE REPORT

Iran J Allergy Asthma Immunol
December 2017; 16(6):561-564.

Endobronchial Lesion in Eosinophilic Granulomatosis with Polyangiitis

Guan-Liang Chen^{1,2}, Chun-Han Wu¹, and Wann-Cherng Perng¹

¹ Division of Pulmonary and Critical Care Medicine, Department of Internal Medicine, Tri-Service General Hospital, National Defense Medical Center, Taipei, Taiwan
² Division of Chest Medicine and Respiratory Therapy, Department of Internal Medicine, Taichung Armed Forces General Hospital, Taichung, Taiwan

Received: 13 July 2016; Received in revised form: 3 July 2017; Accepted: 1 August 2017

ABSTRACT

Eosinophilic granulomatosis with polyangiitis is a systemic vasculitis. It could affect respiratory system, kidney, and central nervous system frequently; however, all body organs could be involved. Asthma and eosinophilic pneumonia are predominant manifestations in respiratory system. Bronchoalveolar lavage or lung biopsy may be used for diagnosis, but endobronchial lesion is not considered as a manifestation of eosinophilic granulomatosis with polyangiitis. Here we present a case of eosinophilic granulomatosis with polyangiitis with unusual endobronchial lesion which was confirmed by endobronchial biopsy.

Keywords: Bronchoscopy; Eosinophilic granulomatosis with polyangiitis; Vasculitis

INTRODUCTION

Eosinophilic granulomatosis with polyangiitis (EGPA), formerly named Churg-Strauss syndrome, is vasculitis of small and medium-sized arteries. Lamb reported the first case in 1914. Churg and Strauss systemically described this syndrome from autopsied cases in 1951. The characteristic manifestations are asthma, eosinophilia, and chronic rhinosinusitis.¹ The frequency of asthma is up to 95%.² This disease affects adults of all ages, and both genders equally.

The American College of Rheumatology (ACR) has established six criteria for the classification of EGPA,

including asthma; greater than 10% eosinophils on differential blood cell count; mononeuritis or polyneuropathy; fluctuating opacities on chest radiography; paranasal sinus abnormality; biopsy containing a blood vessel showing the accumulation of eosinophils in extravascular areas, and the presence of four or more of these criteria had 85% sensitivity and 99.7% specificity. The patient responded with systemic glucocorticoids and an additional immunosuppressive agents.

CASE RREPORT

A 58-year-old male Chinese-American was admitted to our hospital because of non-productive cough for ten months, and shortness of breath with wheeze in the past one month. He visited local clinics in Texas, USA in April, 2014, and a chest radiograph was reported to be normal. Asthma was suspected one month earlier. He

Corresponding Author: Wann-Cherng Perng, MD;
Division of Chest Medicine and Respiratory Therapy, Department of Internal Medicine, Tri-Service General Hospital, National Defense Medical Center, 325, Section 2, Cheng-Gung Road, Nei-Hu Dist. 114, Taipei, Taiwan. Tel: (+886 2) 8792 3311, Fax: (+886 2) 6600 8692, E-mail: wperng@ms27.hinet.net

was then treated with fluticasone/salmeterol meter dose inhaler. As no evidence of improvement, he returned to Taiwan, and visited our hospital for further suggestion. No fever, arthralgia, myalgia, and weight loss have been noticed. He gave history of chronic sinusitis. There has been no use of leukotriene receptor antagonists, and no history of drug or food allergy. He was in unemployed state. He has smoked one pack of cigarette per day for 35 years. On admission, chest radiograph revealed pulmonary infiltrates in the left upper lobe (Figure 1), and chest computed tomography showed consolidative change of the lesion (Figure 2). In initial investigation, no specific pathogens grew in cultures of sputum, and pulmonary infiltrates persist under empirical antibiotic. White blood cell count was $13530/\mu\text{L}$, red blood cell count $5.27 \times 10^6/\mu\text{L}$, and platelet count $3.49 \times 10^5/\mu\text{L}$. In the differential counts, eosinophil 59% ($7983/\mu\text{L}$), neutrophil 13%, lymphocyte 20%, and monocyte 8%. Anti-neutrophil cytoplasmic antibodies was absent in the immunofluorescence assay.

For more definite retrieval of specimens, we performed bronchoscopy which revealed scattered whitish plaques and mucosal congestion of the trachea (Figure 3) and bilateral main bronchi (Figure 4).

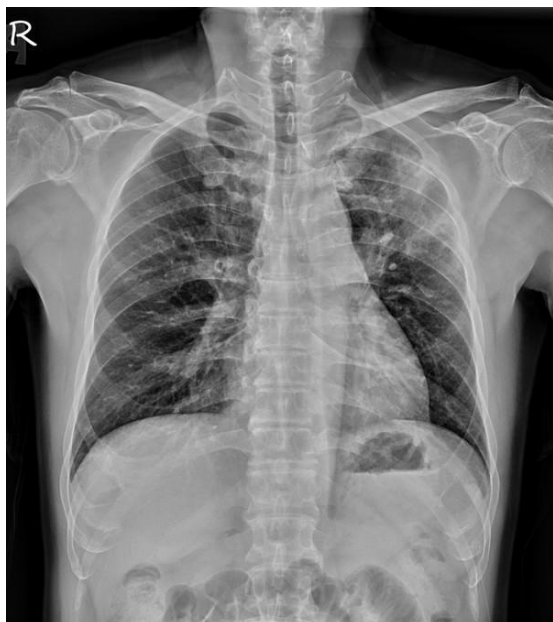

Figure 1. Pulmonary infiltrates in the left upper lobe presented in the chest plain film of this 58-year-old patient with non-productive cough for ten months, and shortness of breath with wheeze in the past one month.

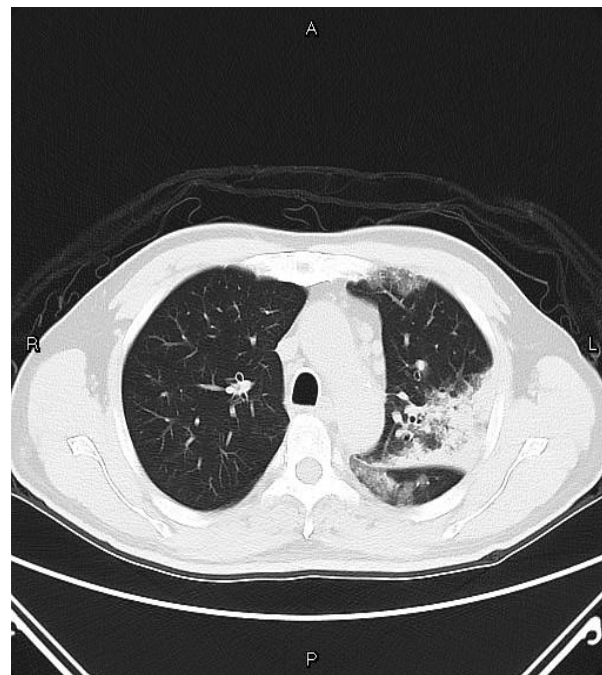


Figure 2. Consolidative change of left lung parenchyma on computed tomography of chest in a 58-year-old patient with non-productive cough for ten months, and shortness of breath with wheeze in the past one month.

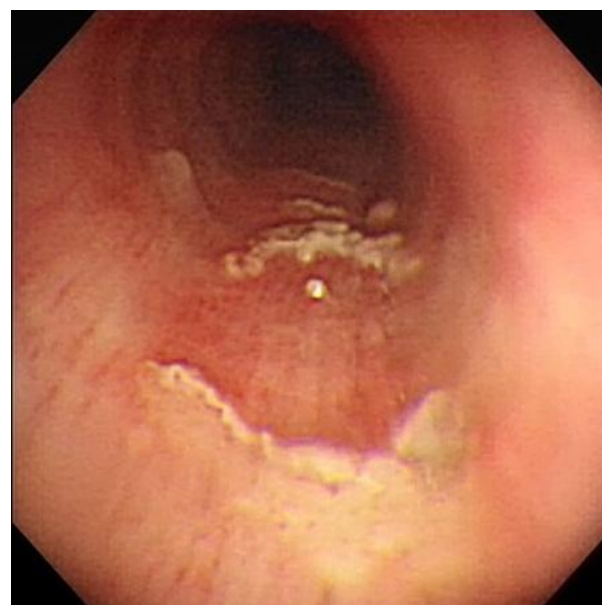

Figure 3. Mucosal erosion and whitish plaques found by bronchoscopy in middle trachea of a patient with non-productive cough, shortness of breath and wheeze, which was proved to be eosinophilic granulomatosis with polyangiitis.

Endobronchial biopsy of the mucosal lesions (Figure 5) revealed extensive necrosis and hemorrhage with large amount of eosinophils infiltrate resulting in small vascular destruction, and squamous cell nests formation due to metaplasia. According to criteria for classification from the ACR, five in these six criterions were compatible with EGPA, including asthma, eosinophilia, sinusitis, pulmonary infiltrates, and histological findings.

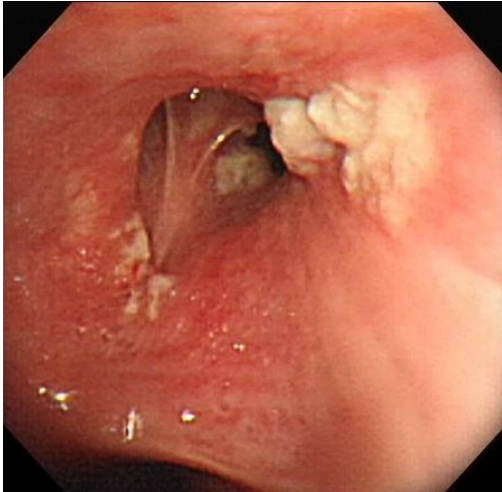


Figure 4. Multiple whitish plaques found by bronchoscopy in right upper lobe bronchus of a patient with non-productive cough, shortness of breath and wheeze, which was proved to be eosinophilic granulomatosis with polyangiitis.

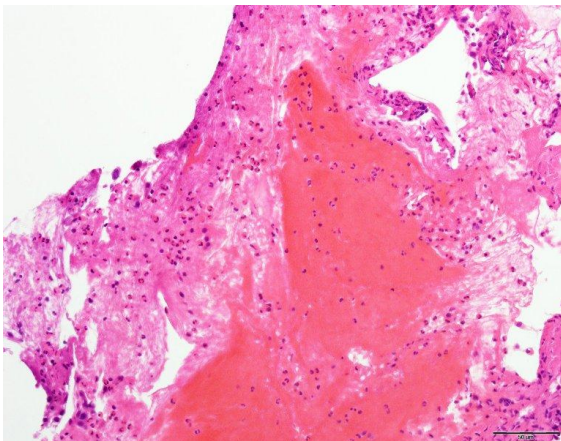


Figure 5 The pathologic picture of an endobronchial biopsy via right upper lobe bronchus in 58-year-old patient with non-productive cough, shortness of breath and wheeze showed extensive necrosis with large amount of eosinophils infiltrates resulting in small vascular destruction.

He started on methylprednisolone treatment, and symptoms subsided soon after. The pulmonary infiltrates also fully resolved within four weeks after steroid therapy.

DISCUSSION

Presentation of EGPA is similar to the other eosinophilic lung diseases, such as chronic eosinophilic pneumonia, allergic bronchopulmonary mycosis, and hypereosinophilic syndrome. Patients of EGPA may also suffer from additional consequences of a vasculitis, like purpura, peripheral neuropathy, and constitutional symptoms which including fever, malaise, and weight loss. All organs could be involved, especially lungs, sinuses, heart, and kidneys. The pathologic change is characterized by extravascular eosinophilic infiltration, but the etiology is still unknown.³ Anti-neutrophil cytoplasmic antibodies are positive in only 40% of the cases while most cases have renal involvement.⁴ In this case, the patient has no specific history of drug or toxin exposure, so the possibility of drug allergy or toxin reaction is low. Furthermore, malignancy and other causes of eosinophilic lung diseases, like fungal or parasite infection, could be excluded after culture and histological reports. The promising therapeutic response with steroid also enhances the diagnosis of vasculitis.

Eosinophilic granulomatosis with polyangiitis could be divided into vasculitic or tissular phenotype. The frequency of vasculitic phenotype is about 40%, and anti-neutrophil cytoplasmic antibodies is often presented, mostly perinuclear anti-neutrophil cytoplasmic antibodies with anti-myeloperoxidase specificity. Kidney, skin, and central nervous system are involved predominantly, and vasculitis is often proved in biopsy. In contrast, the frequency of tissular phenotype is up to 60%, and anti-neutrophil cytoplasmic antibodies is often absent in tissular phenotype. Constitutional symptoms and cardiac involvement are demonstrated frequently.⁵ Clinical features present with eosinophilic pneumonia for the most part.^{6,7} The tissular type may also represent a variant of hypereosinophilic syndrome with systemic manifestations. In this case, the clinical feature appeared as eosinophilic pneumonia and negative anti-neutrophil cytoplasmic antibodies, belong to tissular phenotype. Interestingly, the endobronchial lesion was

demonstrated as eosinophilic infiltration of vessels in endobronchial epithelium, and merely reported in two cases of anti-neutrophil cytoplasmic antibodies-negative eosinophilic granulomatosis with polyangiitis, and none in anti-neutrophil cytoplasmic antibodies-positive eosinophilic granulomatosis with polyangiitis before.⁸⁻⁹ Regardless of phenotype, corticosteroid is the mainstay of treatment, and the response of this patient was satisfying. In this case, the endobronchial vasculitis was reported so rarely while characteristics of both phenotypes coexisted.

Bronchoscopic biopsy was considered for further pathologic diagnosis.¹⁰⁻¹¹ We considered that this unexpected presentation, vasculitis of endobronchial epithelium, provided possible association with asthma as the early presentation of eosinophilic granulomatosis with polyangiitis.

REFERENCES

1. Churg J, Strauss L. Allergic granulomatosis, allergic angiitis, and periarteritis nodosa. *Am J Pathol* 1951; 27(2):277-301.
2. Guillevin L, Cohen P, Gayraud M, Lhote F, Jarrousse B, Casassus P. Churg-Strauss syndrome. Clinical study and long-term follow-up of 96 patients. *Medicine (Baltimore)* 1999; 78(1):26-37.
3. Pagnoux C, Guilpain P, Guillevin L. Churg-Strauss syndrome. *Curr Opin Rheumatol* 2007; 19(1):25-32.
4. Allen JN, Davis WB. Eosinophilic lung diseases. *Am J Respir Crit Care Med* 1994; 150(5 Pt 1):1423-38.
5. Gioffredi A, Maritati F, Oliva E, Buzio C. Eosinophilic granulomatosis with polyangiitis: an overview. *Front Immunol* 2014; 5:549.
6. Sablé-Fourtassou R, Cohen P, Mahr A, Pagnoux C, Mouthon L, Jayne D, et al. Antineutrophil cytoplasmic antibodies and the Churg-Strauss syndrome. *Ann Intern Med* 2005; 143(9):632-8.
7. Sinico RA, Di Toma L, Maggiore U, Bottero P, Radice A, Tosoni C, et al. Prevalence and clinical significance of antineutrophil cytoplasmic antibodies in Churg-Strauss syndrome. *Arthritis Rheum* 2005; 52(9):2926-35.
8. Hara Y, Kanoh S, Shinkai M, Kawana A. Churg-Strauss syndrome with endobronchial eosinophilic vasculitis. *Intern Med* 2012; 51(22):3227.
9. Alvarez-Sala R, Prados C, Armada E, et al. Congestive cardiomyopathy and endobronchial granulomas as manifestations of Churg-Strauss syndrome. *Postgrad Med J* 1995; 71(836):365-6.
10. Rajendra Prasad. (2013). Atlas of fiberoptic bronchoscopy. New Delhi, India: Jaypee Brothers Medical Publishers.
11. Cho BH, Oh Y, Kang ES. Aspergillus tracheobronchitis in a mild immunocompromised host. *Tuberc Respir Dis (Seoul)* 2014; 77(5):223-6.