

Mutation Screening of *ENAM*, *KLK4*, *MMP20* and *FAM83H* Genes among the Members of Five Iranian Families Affected with Autosomal Recessive Hypoplastic Amelogenesis Imperfecta

M. Ghandehari Motlagh,¹ F. Mohandes,¹ H. Noori-Dalooi,² C. Azimi,³ M.R. Noori-Dalooi,² A. Ebrahimi Takalo,¹ M. Ghavam,¹ S. Saeed-Rad,² G. Meighani,¹ J. Pourhashemi,^{1,*} and M. Heidari^{2,**}

¹Department of Pediatric Dentistry, Faculty of Dentistry, Tehran University of Medical Sciences, Tehran, Islamic Republic of Iran

²Department of Medical Genetics, Faculty of Medicine, Tehran University of Medical Sciences Tehran, Islamic Republic of Iran

³Genetics Group, Cancer Research Center, Cancer Institute, Tehran University of Medical Sciences, Tehran, Islamic Republic of Iran

Received: 19 September 2011 / Revised: 20 November 2011 / Accepted: 28 December 2011

Abstract

Amelogenesis Imperfectas (AIs) are clinically and genetically heterogeneous conditions characterized by a wide range of clinical features. These abnormalities of enamel formation are categorized into three main groups, hypoplastic, hypomaturation and hypocalcified with different modes of inheritance such as autosomal recessive (AR), autosomal dominant (AD) and X-linked recessive (XLR). In spite of the fact that frequent studies have explained the histological features of AIs, our knowledge regarding the molecular etiology of the affected enamel is not adequate. Up to now, different loci have been suggested to associate with the causation of AIs. Several genetic mutations including enamelin (*ENAM*), amelogenin (*AMELX*), ameloblastin (*AMBN*), tuftelin (*TUFT1*), kallikrein 4 (*KLK4*), matrix metalloproteinase 20 (*MMP20*) and family with sequence similarity 83, member H (*FAM83H*) have been suggested to play critical roles in the pathogenesis of these disorders. Therefore, the aim of this investigation was to study of mutation screening in *ENAM*, *KLK4*, *MMP20* and *FAM83H* genes, responsible for AIs development in five Iranian families in which the probands were diagnosed with autosomal recessive hypoplastic amelogenesis imperfecta (ARHAI). Genomic DNA was extracted from probands and exon/intron boundaries of afore-mentioned genes were amplified by PCR and subjected to direct sequencing. We could not detect any mutation in the studied genes however; two different novel polymorphisms including T18515C and G18504A were identified in the intron 4 of *MMP20* in the probands of two families. Our findings support the notion that different genes may be involved in the development of amelogenesis imperfectas.

Keywords: Amelogenesis Imperfecta; *ENAM*; *KLK4*; *MMP20*; *FAM83H*

* Corresponding author, Tel.: +98(21)88497505, Fax: +98(21)88953005, E-mail: pourhashemi@tums.ac.ir

**Corresponding Author: Tel: 98-21-88953005, Fax: 98-21-88953005, E-mail : mheidari@sina.tums.ac.ir

Introduction

Amelogenesis imperfectas (AIs) represent a group of genetic disorders affecting tooth enamel formation in both deciduous and permanent dentition. According to the clinical appearance of the enamel and molecular studies, AIs show both clinical and genetic heterogeneity. The amelogenesis imperfecta enamel defects can be classified into three main groups: hypoplastic, hypomaturation and hypocalcified. It is also subdivided into fourteen subtypes, based on the phenotypes and patterns of inheritance[1]. Three different Mendelian mode of inheritance including autosomal recessive, autosomal dominant and X-linked forms have been reported. The molecular basis responsible for AIs still is not well clarified; although more than 300 genes have been documented to be associated with tooth development [2]. Several investigations have been demonstrated that enamel formation is controlled by different biomolecules including enamelin (*ENAM*), dentine sialophosphoprotein (*DSPP*), amelogenin (*AMELX*), ameloblastin (*AMBN*), tuftelin (*TUFT1*), and different enzymes such as kallikrein 4 (12*KLK4*) and matrix metalloproteinase 20 (*MMP20*) [1,3].

Several mutation studies on *ENAM*, *KLK4*, *MMP20* and *FAM83H* have been revealed the importance of these genes in the etiology of amelogenesis imperfectas [4].

The *FAM83H* gene contains 5 exons and is located on 8q24.3. It has been suggested that the role of *FAM83H* gene is in differentiation of preameloblasts into functional ameloblasts and also in calcification of enamel matrix [5]. So far, nine mutations in *FAM83H* have been reported to be involved in the pathogenesis of ADHCAI [6-10].

The *KLK4* gene encodes a serine protease that associated with terminal extracellular degradation of matrix proteins during the maturation stage of enamel formation [11]. This enzyme degrades different types of proteins and is almost responsible for the complete elimination of enamel matrix proteins and biomineralization of enamel[12, 13]. Hart *et al.* reported a mutation (g.2142G>A) in *KLK4* gene and they suggested that this genetic change lead to a truncated protein and could play in the pathogenesis of AIs. [14].

The *MMP20* consists of 7 exons and is located on 11q22.3-q23. This gene encodes a proteolytic enzyme that has an important role in removal of the protein components and formation of fully mineralized mature enamel. The dysfunction of this gene causes autosomal recessive amelogenesis imperfecta [4, 15]. Kim *et al.* have reported homozygosity for a splice site mutation

(g.30 561A→T; c.954-2A→T or IVS6-2A→T) in the *MMP20* gene in two affected members of a family [16].

ENAM mutation causes soft and local hypoplastic amelogenesis imperfecta[17-21] and both autosomal dominant and recessive inheritance patterns have been identified in *ENAM* mutation[22-24]. Rajpar *et al.* reported a G-to-A transition (g.6395G > A) in the splice donor site in *ENAM* gene[18]. Mardha *et al.* identified a nonsense mutation(g.2382A > T) leading to lys53-to-ter (K53X) substitution[20]. Another study reported a g.8344 of G in exon 9 in a Japanese family that was related to hypoplastic type [19].

In this study, the affected members of five Iranian families, which were diagnosed with ARHPAI, were evaluated for mutations in the *ENAM*; *KLK4*; *MMP20* and *FAM83H* genes.

Materials and Methods

Patients

This study was performed with the approval of the Institutional Review Board (IRB) and informed consent was obtained from each patient before genetic testing. All the patients were diagnosed at the Department of Pediatric Dentistry, Faculty of Dentistry, Tehran University of Medical Sciences (TUMS). The pedigree analysis was carried out by Cyrillic 2.1 software.

Molecular Analysis

From each case, five milliliters peripheral blood was collected in test tubes containing EDTA. Then, DNA was extracted using DNGPLUS kit (Cinnagen, Tehran, Iran). PCR amplification was typically carried out using primer pairs of exon-intron boundaries of *ENAM*, *KLK4* and *MMP20* genes as described previously [25]. Also, *FAM83H* primers were designed using Primer3 software (Table 1), 0.2U Taq DNA polymerase (Roche, Mannheim, Germany), 10pmole of each primer, 200 μM of each dNTPs, .0.67μl of 50mM MgCl₂, 60ng DNA and 2.5 μl of PCR buffer in 25μl of PCR reactions. The PCR conditions included an initial denaturation step for 3 min at 95°C, 30 sec at 95°C, 45 sec at 64°C with a 1°C decrease every second cycle down to 55°C, then 55°C for 14 cycles, 1 min at 72°C for extension, and finally 10 min at 72°C. PCR products were separated on 1.8% agarose gels and stained with ethidium bromide. Subsequently, for detection any mutation, PCR products were purified using Quick Spin PCR purification kit according to manufacturer's procedure (Qiagen). Then, purified PCR products were subjected for direct PCR sequencing using forward and reverse

primers as shown in Table 1 (Gene Fanavaran, Iran). redundant nucleic and protein databases BLAST
 Sequence data searches were performed in non- (http://www.ncbi.nlm.nih.gov/BLAST).

Table 1. List of *FAM83H* primer sequences used in screening of mutations in studied genes

Primer Name	Sequence 5'→3'	PCR ProductSize (bp)
FAM83PF1	CTCGCCAGGAGCCCTTGTCCTGTAGA	486
FAM83PR1	GGAAGGCCGACAGGAAGT	
FAM83PF2	CCCTTCTCCTTCCCTAAACG	523
FAM83PR2	CGCCAGGGTGAAGTCAT	
FAM83PF3	CTACCAGCAGCAGTACCAGTG	652
FAM83PR3	CGAGCGGAATGAGTCCTG	
FAM83PF4	GCCTTCCCCACCAAGGTC	497
FAM83PR4	CTGCTGTGCAAAGGAGTCG	
FAM83PF5	GTTGCCAGCCACAGCAAG	566
FAM83PR5	GACTCCCCGGAGATGGTAAG	
FAM83PF6	CAGGATTTATCGAGCAGAAGG	593
FAM83PR6	GGCTGAACACTTGCCTTGTC	
FAM83PF7	AAGCCATTCTGGAGCAGAT	689
FAM83PR7	GACGGTGCAGAGATGAAGGT	

Archive of SID

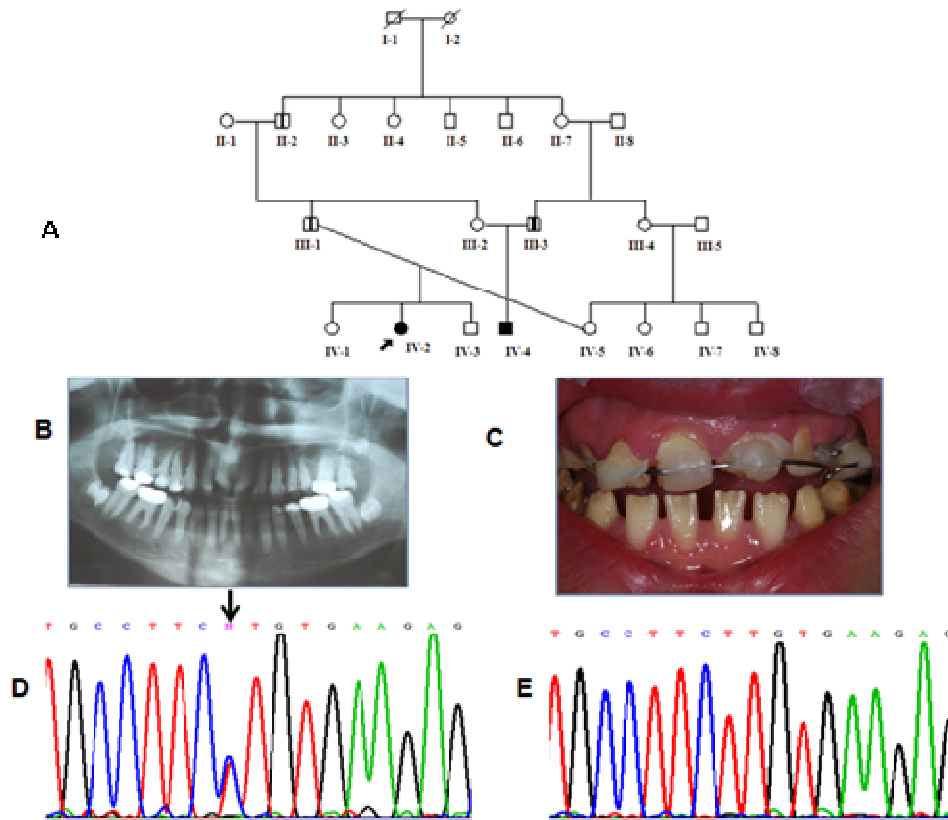


Figure 1. Pedigree, clinical feature and molecular study of proband in family 1. A: The pedigree of family 1 showed two affected patients with ARHAI from a consanguineous family. A arrow indicates the proband. B: Panorex radiography of proband presented the tooth enamel loss. C: Clinical feature of proband demonstrating hypoplastic amelogenesis imperfecta. D: DNA sequencing revealed heterozygous genetic variation in the intron5 of *MMP20* gene (T18515C). E: Chromatogram from wild-type *MMP20* gene (AY673603.1) (arrow indicates the position of nucleotide substitution).

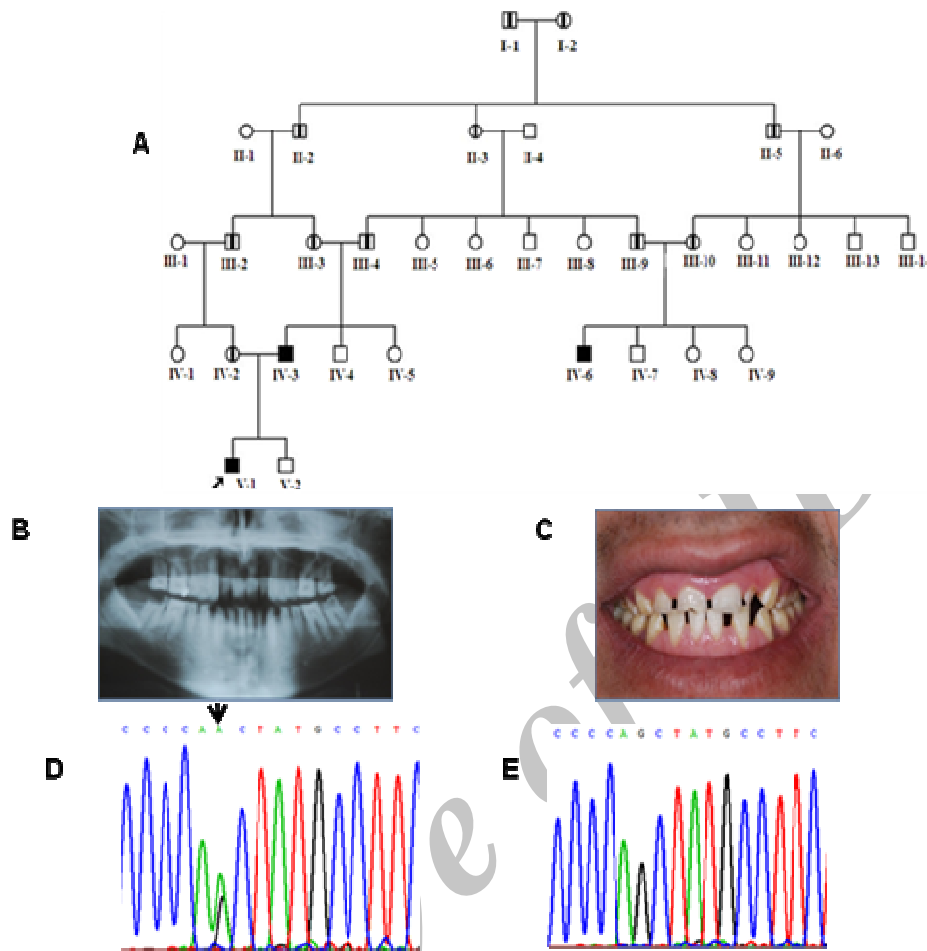


Figure 2. Pedigree, clinical feature and molecular study of propositus in family 2. **A:** The pedigree of family 2 presented three individuals with ARHAI born to three first cousins parents (arrow indicates the propositus). **B:** Panorex radiography of propositus presented the lack of tooth enamel. **C:** Clinical feature of propositus demonstrating hypoplastic amelogenesis imperfecta. **D:** DNA sequencing revealed heterozygous polymorphism in the intron5 of *MMP20* gene in which A→G at position g.18504 (AY673603.1) **E:** Wild-type sequence of intron5 of *MMP20* gene (arrow indicates the position of nucleotide substitution).

Results

The affected patients with ARHAI were studied from five Iranian consanguineous families (Fig. 1A, Fig. 2A). The proband from family 1 was a 17-year-old Iranian girl who had two healthy siblings, born to consanguineous parents. She and her siblings had been born with normal full-term pregnancy. Her first cousin was also affected with ARHAI. The clinical appearances of patients represented hypoplastic amelogenesis with yellow-brown discoloration. Their enamel showed also different range, from thin and smooth, to normal thickness with grooves, furrows

and/or pits. All affected individuals were clinically and radiographically examined and showed non-syndromic enamel defects. Furthermore, the dental examination including an intra-oral evaluation of the parents and unaffected siblings showed no evidence of any enamel malformation or defect and no syndromic signs.

In family 2 the propositus was a 12-year-old boy affected with ARHAI. He and his healthy brother were born to first cousin parents. The proband's father, and his father's first cousin were also affected with ARHAI. The patients showed similar conditions to the index case of family 1.

PCR amplification of *ENAM*, *KLK4*, *MMP20* and *FAM83H* genes were conducted and subsequently

subjected for direct PCR sequencing, and the sequencing data were analyzed. Two different *MMP20* genetic variations were identified in two patients with amelogenesis imperfecta (Fig. 1D and Fig. 2D). Both mutations were heterozygous states, and they clustered in the intron4 of *MMP20* gene.

Discussion

In this study we performed direct PCR sequencing for five families having at least one affected individual with ARHPAI. The clinical appearances of hypoplastic amelogenesis imperfecta of our patients typically showed yellow-brown discoloration and verification of pathological enamel loss.

The amelogenesis imperfectas, are a clinically and genetically heterogeneous group of disorders characterized by faulty development of the tooth enamel due to hypoplasia or hypomineralization. Up to now, various enamel related genes such as *ENAM*, *AMBN*, *AMELX*, *MMP20*, *KLK4*, Amelotin and *FAM83H* genes have been suggested to be implicated in AIs. Our mutation screening in exon/intron boundaries of known candidate genes including, *ENAM*, *KLK4*, *MMP20* and *FAM83H* could not detect any significant variations. However, we found two single nucleotide polymorphisms (SNP) including T18515C and G18504A in the forth intron of *MMP20* gene.

Consistent with our results, different studies also, could not detect any significant mutations in the above genes in AIs [4, 25, 26]. In this regard, Santos et al (2007) evaluated genetic variation for the six major candidate genes including *ENAM*, *AMBN*, *AMELX*, *MMP20*, *KLK4* and Amelotin genes in two Brazilian families with AI. This study indicated that the AI in these two families is not caused by any mutation in afore-mentioned genes for AI [26]. A study was carried out among seven Turkish families affected by AI. They evaluated the *AMBN*, *AMELX*, *ENAM*, *FAM83H*, *KLK4*, *MMP20*, and *TUFT1* genes, but they also failed to detect any mutation in the studied genes [4]. More recent investigation has been performed in four Iranian families with AI[25]. In spite of the fact that the exons and intron/exon junctions of the candidate genes were sequenced, no gene mutations were identified in any individuals [25].

According to our results and previous studies, it is possible that the other genes and/or other mechanism such as epigenetic factors could act to the etiology of AI. Different polymorphisms in candidate genes responsible for amelogenesis imperfecta have been described in various studies [27-29]. Richard et al. studied polymorphism in *AMELX* exon 6 in an

European population and they found low level of variations [28]. In the most recent study, a single nucleotide exchange was identified in the *ENAM* gene from a patient with the clinical features of AI [27]. Further studies are needed to find the exact nature of causation of amelogenesis imperfectas.

References

1. Crawford P.J.M., Aldred M., and Bloch-Zupan A. Amelogenesis imperfecta. *Orphanet. J. Rare Dis.*, **2**: 17-28 (2007).
2. Thesleff I.P.S. *Genetics of dental defects. Encyclopedia of Human Genome. Genes & Disease.* John Wiley & Sons, Ltd. Also online: <http://elswiley.com>.(2003).
3. Iwasaki K., Bajenova E., Somogyi-Ganss E., Miller M., Nguyen V., and Nourkeyhani H. Amelotin--a Novel Secreted, Ameloblast-specific Protein. *J. Dent. Res.*, **84**(12):1127-1132 (2005).
4. Becerik S., Cogulu D., Emingil G., Han T., Hart P.S., and Hart T.C. Exclusion of candidate genes in seven Turkish families with autosomal recessive amelogenesis imperfecta. *Am. J. Med. Genet.*, **149A** (7): 1392-1398 (2009).
5. Lee M.J., Lee S.K., Lee K.E., Kang H.Y., Jung H.S., and Kim J.W. Expression patterns of the *FAM83H* gene during murine tooth development. *Oral Biol.*, **54**:846-850 (2009).
6. Wright J.T., Frazier-Bowers S., Simmons D., Alexander K., Crawford P., Han S.T., Hart P.S., and Hart T.C. Phenotypic variation in the *FAM83H*-associated amelogenesis imperfecta. *J. Dent. Res.*, **88**: 356-360 (2009).
7. El-Sayedab R.C., Shorea D.A., Parryb C.F., Inglehearnb A.J., and Mighella B. Ultrastructural Analyses of Deciduous Teeth Affected by Hypocalcified Amelogenesis Imperfecta from a Family with a Novel Y458X *FAM83H* Nonsense Mutation. *Cells Tissues Organs*, **191**: 235-239 (2010).
8. Kim J.W., Simmer J.P., Lin B.P.L., Seymen F., Bartlett J.D., and Hu J. C.C. Mutational analysis of candidate genes in 24 amelogenesis imperfecta families. *Euro. J. Oral Sci.*, **114**: 3-12 (2006).
9. Lee S.K., Hu J.C.C., Bartlett J. D., Lee K.E., Lin, B.P.J., Simmer J. P., and Kim J.W. Mutational spectrum of *FAM83H*: the C-terminal portion is required for tooth enamel calcification. *Hum. Mutat.*, **29**:E95-E99 (2008).
10. Kim J.W., Lee S.K., Lee Z. H., Park J.C., Lee K.E., Lee, M.H., Park J.T., Seo B.M., Hu J.C.C., and Simmer J.P. *FAM83H* mutations in families with autosomal-dominant hypocalcified amelogenesis imperfecta. *Am. J. Hum. Genet.*, **82**: 489-494(2008).
11. Stephanopoulos G., Garefalaki M.E., and Lyroudia K. Genes and related proteins involved in amelogenesis imperfecta. *J. Dent. Res.*, **84**(12): 1117-1126 (2005).
12. Simmer J.P.H. Expression, structure, and function of enamel proteinases. *Connect. Tissue Res.*, **43**: 441-449 (2002).
13. Simmer J.P.H., Lertlam R., Yamakoshi Y., and Hu J.C. Hypomaturation enamel defects in *Klk4* knockout/LacZ

- knockin mice. *J. Biol. Chem.*, **10**(284): 19110-19121(2009).
14. Hart P.S., Michalec M.D., Ryu O.H., Simmons D., and Hong S. Mutation in kallikrein 4 causes autosomal recessive hypomaturation amelogenesis imperfecta. *J. Med. Genet.*, **41**: 545-549 (2004).
 15. Lee S.K., Seymen F., Kang H.Y., Lee K.E., Gencay K., and Tuna B. MMP20 hemopexin domain mutation in amelogenesis imperfecta. *J. Dent. Res.*, **89**(1): 46-50(2010).
 16. Kim J.W., Simmer J. P., Hart T. C., and Hart P. S., Ramaswami M. D., Bartlett J. D., and Hu J.C.C. MMP-20 mutation in autosomal recessive pigmented hypomaturation amelogenesis imperfecta. *J. Med. Genet.*, **42**: 271-275 (2005).
 17. Shore R.C., Backman B., Elcock C., Brook A.H., Brookes S.J., and Kirkham J. The structure and composition of deciduous enamel affected by local hypoplastic autosomal dominant amelogenesis imperfecta resulting from an ENAM mutation. *Cells Tissues Organs*, **191**(4): 301-306 (2010).
 18. Rajpar M.H., Harley K., Laing C., Davies R.M., and Dixon M.J. Mutation of the gene encoding the enamel-specific protein, enamelin, causes autosomal-dominant amelogenesis imperfecta. *Hum. Mol. Genet.*, **10**: 1673-1677 (2001).
 19. Kida M., Ariga T., Shirakawa T., Oguchi H., and Sakiyama Y. Autosomal-dominant hypoplastic form of amelogenesis imperfecta caused by an enamelin gene mutation at the exon-intron boundary. *J. Dent. Res.*, **81**: 738-742(2002).
 20. Mårdh C.K., Bäckman B., Holmgren G., Hu J.C., Simmer J.P., Forsman-Semb K. A nonsense mutation in the enamelin gene causes local hypoplastic autosomal dominant amelogenesis imperfecta (AIH2). *Hum. Mol. Genet.*, **11**: 1069-1074 (2002).
 21. Pavlic A., Petelin M., and Battelino T. Phenotype and enamel ultrastructure characteristics in patients with ENAM gene mutations g.13185-13186insAG and 8344delG. *Arch. Oral Biol.*, **52**: 209-217(2007).
 22. Hart P.S., Michalec M.D., Ryu O.H., Simmons D., and Hong S. Mutation in kallikrein 4 causes autosomal recessive hypomaturation amelogenesis imperfecta. *J. Med. Genet.*, **41**: 545-549 (2004).
 23. Gutierrez S.J. C., Torres D.M., and Briceno I. Identification of a novel mutation in the enamelin gene in a family with autosomal-dominant amelogenesis imperfecta. *Arch. Oral Biol.*, **52**: 503-506 (2007).
 24. Kang H.Y., Seymen F., Lee S.K., Yildirim M., Tuna E.B., and Patir A. Candidate gene strategy reveals ENAM mutations. *J. Dent. Res.*, **88**(3): 266-269 (2009).
 25. Ghandehari Motlagh M., Aref P., Pourhashemi M., Shahrabi M., Nazarian A.R., Mahbubinejad F., and Heidari M. No Evidence for Association between Amelogenesis Imperfecta and Candidate Genes. *Iranian J. Publ. Health.*, **389**(1): 4-9 (2009).
 26. Santos M.C.L., Hart P.S., Ramaswami M., Kanno C.M., Hart T.C., and Line S.R.P. Exclusion of known gene for enamel development in two Brazilian families with amelogenesis imperfecta. *Head Face Med.*, **3**: 8-16 (2007).
 27. Gopinath V.K., Yoong T.P., Yean C.Y., and Ravichandran M. Identifying polymorphism in enamelin gene in amelogenesis imperfecta (AI). *Arch. Oral Biol.*, **53**: 410-416 (2008).
 28. Richard B., Delgado S., Gorry P., and Sire J.Y. A study of polymorphism in human AMELX. *Arch. Oral Biol.*, **52**(11): 1026-31 (2007).
 29. Hart P.S., Vlaservich A.C., Hart T.C., and Wright J.T. Polymorphism (g2035C>T) in the amelogenin gene. *Hum. Mutat.*, **15**(3): 298-304 (2000).