

B. Zandi MD¹
N. Zandi MD²

Wandering Spleen Presenting as an Asymptomatic Pelvic Mass: A Case Report

Ectopic spleen is a rare entity. It is more common in children than in adults and it is about 15 times more common in females. Here we report a patient with an ectopic spleen who was referred for sonographic evaluation of an asymptomatic pelvic mass by a gynecologist. At sonography, a big homogenous mass located at the RLQ of the abdomen and the right pelvic cavity was detected. Further investigation by color Doppler sonography showed that the mass is an ectopic spleen and the main spleen could not be detected at its normal location. In the abdominopelvic CT scan, the spleen was located at the RLQ, no splenic tissue was found in the left hypochondrium, and this region was occupied by the left colon and stomach. Ectopic spleen, though very rare, should be considered in the differential diagnosis of asymptomatic pelvic masses.

Keywords: Wandering Spleen, Pelvic Mass, Color Doppler Sonography

Introduction

About 500 patients with wandering pelvic spleen have been reported in the literatures so far. It is more common in children than in adults and it is about 15 times more common in females.¹ The presence of a pelvic spleen is an exceedingly rare entity.² Laxity or failure of development of the supporting ligaments of the spleen is thought to be a predisposing factor for ectopic spleen. In 1976 Hatfield et al. reported the first ectopic pelvic spleen demonstrated preoperatively by liver-spleen scan and selective splenic arteriogram.³ Many other cases have been reported, diagnosed by means of conventional and color Doppler sonography, CT Scan and MRI.^{4,5} Ectopic spleen may clinically present as an abdominal or pelvic mass without or mostly with abdominal pain, or as an acute abdominal situation caused by torsion of the long vascular pedicle. Interestingly, a gynecologist referred our case that was clinically diagnosed as an ovarian mass. Imaging evaluation could prove the diagnosis of an ectopic spleen.

Case Presentation

The patient is a 22-year-old virgin female who was referred for sonographic evaluation by a gynecologist. The patient had the clinical diagnosis of an asymptomatic ovarian mass palpable at the right lower quadrant of the abdominal cavity and right pelvic region. All laboratory tests were in normal limits, only her MCV and MCH were slightly lower than normal (MCV=72.6, normal limits=80-95; MCH=23.6, normal limits=25-32).

At sonographic examination which was performed by a Pichnos Partner Ultrasound System (Esaote, Italy), a homogenous lobulated mass with a moderate fine echo pattern was seen in this location. The uterus and the left ovary had a normal appearance, but the right ovary could not be detected, and a solid ovarian

1. Associate Professor, Department of Radiology, Imam Reza Hospital, Mashhad University of Medical Sciences, Mashhad, Iran.

2. Dr. Shariati Hospital, Mashhad University of Medical Sciences, Mashhad, Iran.

Corresponding Author:
Behrooz Zandi
Address: Department of Radiology,
Imam Reza Hospital, Mashhad, Iran.
Tel: +98-511-8525-004
Fax: +98-511-8591-057
Email: b-zandi@yahoo.com

Received August 25, 2007;
Accepted after revision April 8, 2008.

Iran J Radiol 2008;5(3):141-144

tumor or a cystic mass containing thick fluid such as chronic endometrioma was suggested (Fig. 1A).

In the color Doppler sonography evaluation, which was performed by a Pichnos Partner Ultrasound System (Esaote, Italy), a solid mass with a single high flow and a low resistance feeding artery and a single draining vein was detected. This mass resembled the appearance of a normal parenchymal organ (Fig. 1B). The vascular pedicle of the mass containing its tortuous vessels was running from the hilus of the mass in the RLQ toward the epigastric region, joining the celiac and the portal system. Based on the shape, echo pattern and Doppler characteristics of the mass, an ectopic spleen was considered. Further investigation of the abdominal cavity did not reveal the spleen in its normal location. The diagnosis of the ectopic spleen was almost proved. After one year the patient was referred for an abdominopelvic CT scan, which was performed by a GE Dual Detector Spiral System model Nxi (General Electric Company USA). The main spleen and any accessory spleens were not found in their normal anatomical position. The left colon and the gastric fundus had occupied this space, and the ectopic spleen was located in the RLQ and pelvis, with a tortuous vascular pedicle joining the portal system and the celiac axis. Despite the tortuous course of the pedicle, there was no evidence of thrombosis or obstruction (Figs. 2A-D). The patient refused any surgical intervention, and during the one-year clinical observation, no complication occurred.

Discussion

Ectopic pelvic spleen is an exceedingly rare entity. Only a few hundreds of this anomaly have been reported in the literature.^{1,2} Two possible etiologies have been proposed for this anomaly; congenital and acquired. The congenital form occurs due to developmental failure of the dorsal mesogastrium when the lesser sac is formed, and laxity or developmental failure of the ligaments surrounding and supporting the spleen as a predisposing factor. The acquired form occurs mostly in multiparous females due to laxity of the ligaments, which hold the spleen in its position. Many imaging modalities have been used to diagnose this condition but it is still controversial which the most appropriate test is. Sonography as a noninvasive method is still considered to be the most reliable technique and the first diagnostic choice for diagnosis of the ectopic spleen.⁶⁻⁸ Doppler sonography helps in the evaluation of organ blood flow.⁴ In our case there was a normal feeding artery and a draining vein with a normal-high flow pattern as in a normally located spleen, so torsion or infarction of the spleen could be correctly excluded. The information provided by Doppler sonography is particularly valuable to the operating surgeon, especially in asymptomatic young patients when splenopexy can be done instead of splenectomy. In a patient with doubtful ultrasonographic results, CT scan and MRI should be considered as valuable diagnostic aids.^{5,9}

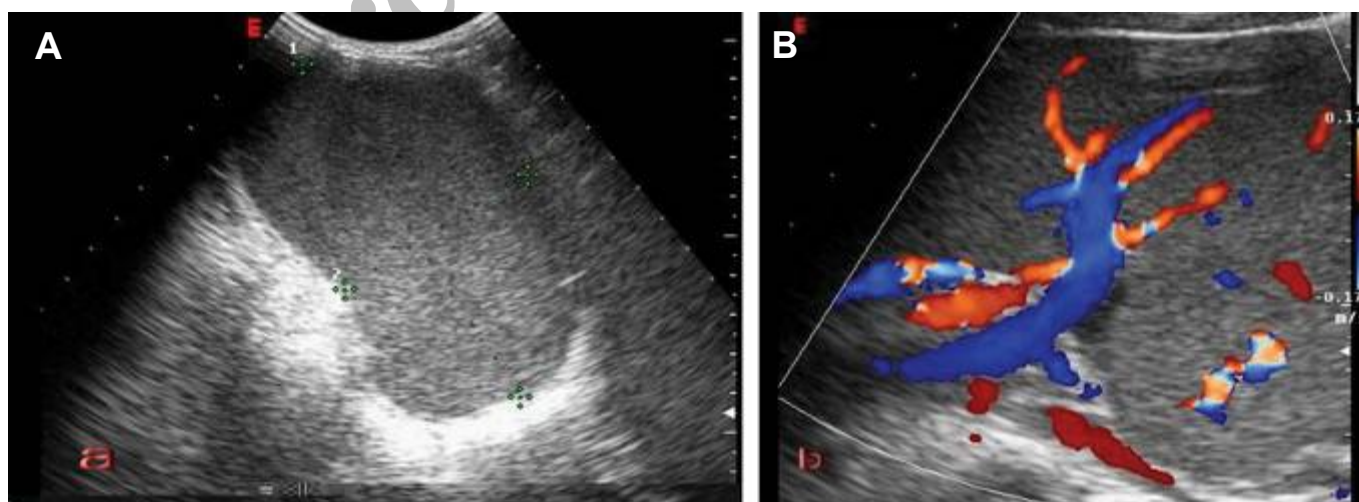


Fig. 1. A 22-year-old woman with an ectopic spleen presenting as a pelvic mass.

A. Transverse Lower abdominal ultrasonography shows spleen in the right lower quadrant of the abdominopelvic cavity.

B. Color Doppler sonography of the abdominal mass (ectopic spleen) shows its normal vessels.

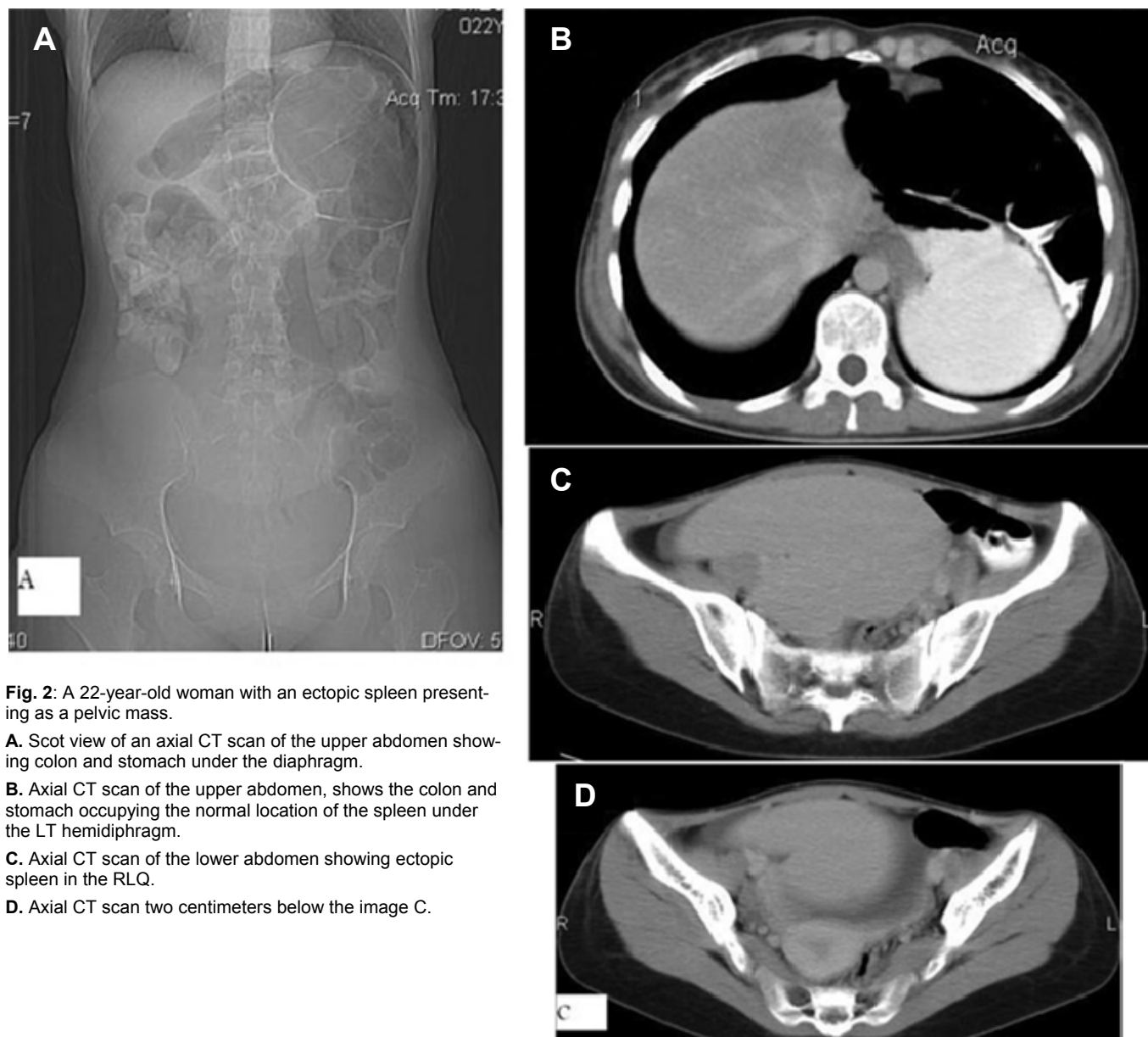


Fig. 2: A 22-year-old woman with an ectopic spleen presenting as a pelvic mass.

A. Scot view of an axial CT scan of the upper abdomen showing colon and stomach under the diaphragm.

B. Axial CT scan of the upper abdomen, shows the colon and stomach occupying the normal location of the spleen under the left hemidiaphragm.

C. Axial CT scan of the lower abdomen showing ectopic spleen in the RLQ.

D. Axial CT scan two centimeters below the image C.

Correct diagnosis of the ectopic spleen, which is essential for appropriate management, can be achieved by conventional and color Doppler sonographic evaluation and confirmed with the use of computed tomography. The case presented here demonstrates the necessity of examination of the entire abdomen by sonography when a pelvic mass of unknown etiology is encountered.

The clinical presentation of this anomaly is variable. Some patients are asymptomatic; more than 50% of patients may have acute abdominal pain due to torsion of the splenic pedicle and infarction, or chronic vague lower abdominal pain because of repeated torsions and detorsions.^{1,4,10} The most common presentation in children is an acute surgical abdomen due to

torsion of the splenic pedicle and infarction.^{11,12} Our case had no major clinical symptoms at the time of admission, but she had considered some vague abdominal pain in her clinical history.

Concerning differential diagnosis, as many patients may present as an acute abdominal emergency. All causes of an acute abdominal situation, especially those presenting with an abdominal or pelvic mass, may be clinically misdiagnosed as complicated ectopic spleen. From the imaging point of view, solid abdominal and pelvic masses, especially ovarian tumors should be considered in the differential diagnosis of a wandering spleen.

Non-operative treatment of the ectopic spleen (clinical follow-up control and observation) has a very

high complication rate, so the treatment of choice is surgery, splenopexy or splenectomy.¹³ Therefore, we recommended a surgical consultation for our patient.

References

1. Alawi MH, Khalifa A, Bana SH. Wandering spleen: a challenging diagnosis. *Pak J Med Sci* 2005 Oct-Dec;21(4):482-4.
2. Golbey S, Gerard PS, Rosenblatt M, Ahmad S. Sonographic evaluation of an ectopic spleen simulating a pelvic mass. *J Diag Med Son* 1992;8(1): 25-7.
3. Hatfield PM, Clouse ME, Cady B. Ectopic pelvic spleen. *Arch Sur* 1976 May;111(5):603-5.
4. Koda M, Hosyo K, Murawaki Y, Horie Y, Suou T, Kawasaki H et al. The wandering spleen with collateral vessels containing gastric varices: color Doppler ultrasound imaging. *J Clin Ultrasound* 1996 Nov-Dec;24(9):528-32.
5. Karantanis A, Stagianis K. The value of MR angiography in predicting the risk of torsion of a pelvic spleen during pregnancy. *Eur Radiol* 2002 Feb;12(2):309-11.
6. Tait NP, Young JR. The wandering spleen: an ultrasonic diagnosis. *J Clin Ultrasound* 1985;13:145-6.
7. Hunter TB, Haber K. Sonographic diagnosis for a wandering spleen. *Am J Radiol* 1977;129:925-6.
8. Gordon DH, Burrell MI, Levin DC. Wandering Spleen: the radiological and clinical spectrum. *Radiology* 1977;125:39-46.
9. Parker LA, Mittelstaedt CA, Mauro MA. Torsion of a wandering spleen CT appearance. *J Comput Assist Tomogr* 1984;8:1202-4.
10. Lamesch P, Lamesch A. Anomalies of the position of the spleen in the child case report and review of the literature from 1896 to 1990. *Langenbecks Arch Chir* 1993;378(3):171-7
11. Buehner M, Baker MS. The wandering spleen. *Surg Gynecol Obstet* 1992;175:373-87.
12. Abell I. Wandering spleen with torsion of the pedicle. *Ann Surg* 1933;98:722-5.
13. Thompson J, Ross R, Pizzaro S. The wandering spleen in infancy and childhood. *Clin Pediatr* 1980 Mar;19(3):221-4.