

A. Khatami MD¹
 S. Sabouri MD²
 J. Ghoroubi MD³
 N. Rassouli MD⁴
 F. Abdollah Gorji Ms⁵

1. Assistant Professor, Department of Radiology, Mofid Children's Hospital, Shahid Beheshti University of Medical Sciences, Tehran, Iran.
 2. Assistant Professor, Department of Radiology, Shohada-e Tajrish Hospital, Shahid Beheshti University of Medical Sciences, Tehran, Iran.
 3. Assistant Professor, Department of Pediatric Surgery, Mofid Children's Hospital, Shahid Beheshti University of Medical Sciences, Tehran, Iran.
 4. Department of Radiology, Shahid Beheshti University of Medical Sciences, Tehran, Iran.
 5. Research Developmental Center, Mofid Children's Hospital, Shahid Beheshti University of Medical Sciences, Tehran, Iran.

Corresponding Author:
 Alireza Khatami
 Address: Department of Radiology, Mofid Children's Hospital, Shariati Ave., Tehran, Iran.
 Tel: +9821-22251737
 Email: alireza_khatami31@yahoo.com

Received September 1, 2008;
 Accepted after revision December 10, 2008.

Iran J Radiol 2008;5(4):231-234

Radiological Findings of Pulmonary Tuberculosis in Infants and Young Children

Background/Objective: Pulmonary tuberculosis (TB) is a common worldwide lung infection. It remains an important cause of morbidity and mortality. Radiographic manifestations of pulmonary tuberculosis are diverse and varied. This study was performed to define the various radiographic manifestations of this infection in the pediatric age group in children who were referred to Mofid Children's Hospital.

Patients and Methods: We reviewed chest x-rays of 30 pulmonary TB patients admitted to our hospital to ascertain the extent of parenchymal and mediastinal involvements on chest x-ray.

Results: Male to female ratio was 1.7:1. The patients' age ranged from 2-163 months with a mean age of 36.9 months. Mediastinal lymphadenopathy was detected in 90% of the cases and pulmonary involvement, especially alveolar shadowing was seen in 83.3% of the cases (of which 43.3% had an air-space pattern and 40% had an interstitial pattern). 19 of the 30 patients (66.3%) were under 36 months, in which 17 of the 19 patients (89.5%) revealed lymphadenopathy. Therefore 63% of all detected lymphadenopathies were seen in this age group. Mediastinal lymphadenopathy was more common on the right side (73.3%). Furthermore, 60% of all alveolar infiltrations were seen on the right side.

Conclusion: Pulmonary tuberculosis most commonly represents as a mediastinal and thereafter as a parenchymal involvement. Hilo-mediastinal lymphadenopathy is the most common presentation in infants and young children.

Keywords: Pulmonary Tuberculosis, Child, Radiography

Introduction

Pulmonary TB is a worldwide infection. It remains an important cause of morbidity and mortality in the world.^{1,2} Worsening of human immunodeficiency virus epidemic, poor economic conditions, drug abuse, and immigration from developing countries cause increased incidence of tuberculosis.²⁻⁶ Children are one of the high risk groups affected by this disease.⁷⁻⁹ Especially those younger than 5 years are at the highest risk for pulmonary TB.^{2,4}

Classically, tuberculosis is divided into primary TB, which is common in childhood, and post-primary TB, usually presenting in adults.¹ Pulmonary TB in infants has some differences from that seen in older children, and the risk of severe and life-threatening complications such as TB meningitis or miliary tuberculosis is higher.^{2,9-11} Early diagnosis and prompt treatment are very important in children's tuberculosis.² Bacteriologic confirmation of the disease is difficult in children. There are also many negative tuberculin skin tests in young infants, so a history of direct contact with adults suffering from contagious tuberculosis, and chest radiographs assume important roles in diagnosing tuberculosis in infants.^{2,7,10-15}

The purpose of this study was to define the radiographic findings in children referred to our hospital with pulmonary tuberculosis.

Patients and Methods

We reviewed chest x-rays of 30 children who were diagnosed as pulmonary tuberculosis in our hospital during the period of 1986-2001. Diagnosis of TB had been established by clinical and radiological findings, contact with a relative with proved TB infection, PPD test >10mm and a positive culture for acid-fast bacilli on gastric aspiration, CSF and surgical specimen (in extra-pulmonary involvement) and response to anti TB drugs.

The children's age and sex, and tuberculous involvement of other systems such as meningitis, spondylitis, arthritis, gastrointestinal and genitourinary involvement, were documented. Patients with BCGitis were excluded from the study and for other cases, contact with a relative with active TB (6 cases with one parent involvement, 1 case with grandmother involvement), nationality (3 cases were immigrants from Afghanistan and 8 cases were born in Iran from Afghanian parents) other 19 cases were Iranian.

Vaccination was complete in 21 cases. In 9 cases (2 Iranian and 7 Afghanian cases) the history of vaccination was not complete.

X-rays were reviewed by two radiologists and imaging findings were recorded on separate sheets as follows: parenchymal involvement (alveolar and/or interstitial), mediastinal involvement (paratracheal, hilar adenopathy) If there was any discrepancy be-

tween the radiologists' reports, another evaluation was done with both of them and the final report was recorded. All documented data were analyzed and our findings were compared with the results from similar studies.

Results

The patients' ages ranged from 2-163 months with a mean age of 36.9 ± 39.2 months. Male to female ratio was 1.7:1. 19 of the 30 patients (63.3%) were under 36 months old. Overall, mediastinal involvement, (hilar and paratracheal lymphadenopathies) was seen in 27 cases (90%), parenchymal involvement was noticed in 25 patients (83.3%), with an air space pattern seen in 13 (43.3%), interstitial pattern (reticulonodular and miliary) in 12 patients (40%). In 22 children (73.3%), both lung and mediastinum were involved. In 3 cases (10%), lymphadenopathy was the only manifestation of the disease and in 2 cases (6.7%) lymphadenopathy with pleural effusion were the CXR findings. Mediastinal lymphadenopathy was a common presentation in patients younger than 36 months and 63% of the cases with this manifestation were in this age group, however, the difference between mediastinal lymphadenopathy in these two groups was not significant (P value=0.9). Right paratracheal and hilar nodes were a more common location for lymphadenopathies (73.3%), and 60% of the alveolar shadowing was seen on the right side (P value=0.8).

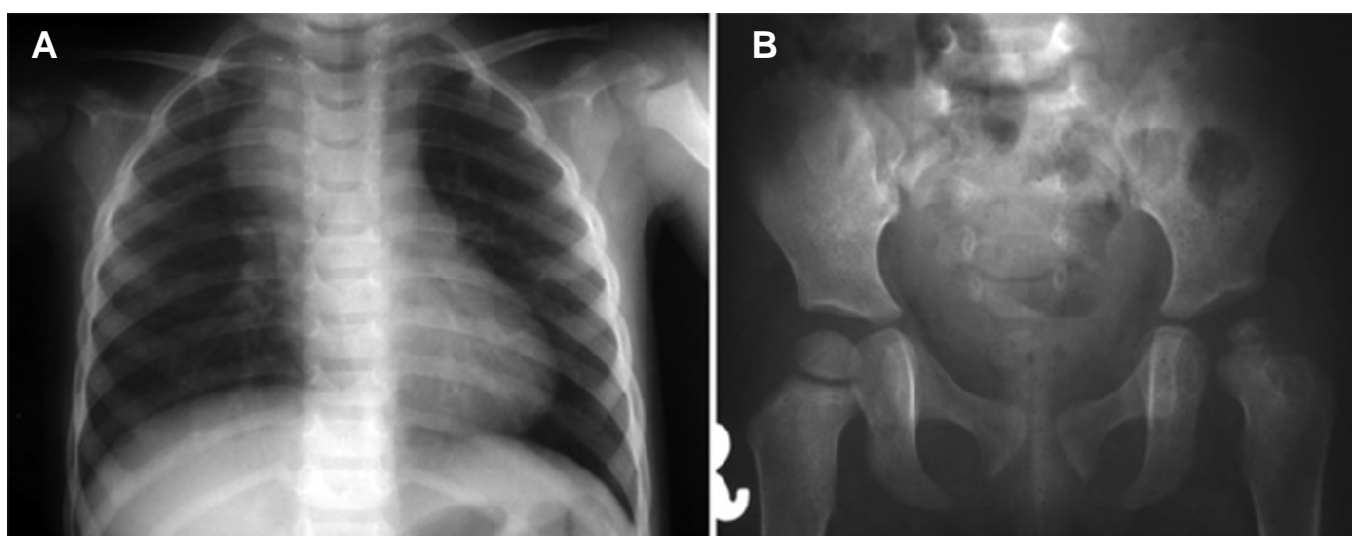


Fig. 1. A 4-year-old child with TB.

A. CXR shows right paratracheal lymphadenopathy

B. Pelvic X-Ray reveals left hip arthritis with femoral epiphyseal destruction

Table 1: Pulmonary and Extra-Pulmonary Tuberculous Lesions Detected on Imaging

Radiological findings	Number	Percent
Pulmonary TB	22	73.3
Extra-pulmonary TB		
– Hydrocephalus & meningitis	1	3.3
– Spinal involvement	3	10
– Renal involvement	1	3.3
– Cecal stricture	1	3.3
– Arthritis	2	6.6
Total	30	100

In children younger than 36 months, parenchymal and mediastinal involvement were both seen in 17 cases (89.5%). However, the prevalence of lymphadenopathy was relatively similar in children younger and older than 36 months (89.5% and 90.9%, respectively), which has no significant difference (P value=0.9). Parenchymal involvement was more common in the first group (89.5% in the first group versus 72.7% in the second group; P value = 0.2) which was also not significant statistically. Other lung manifestations were pneumomediastinum and bronchiectasis. Each of them was noted in 1 patient (3.3%). Pleural effusion and ranke complex were other manifestations. Each of them was seen in 3 of the patients (10%).

Eight patients (26.7%) presented with manifestations of musculoskeletal, gastrointestinal, genitourinary and central nervous system involvement instead of pulmonary symptoms (Table 1). Some radiographic patterns are depicted (Figs. 1-4).

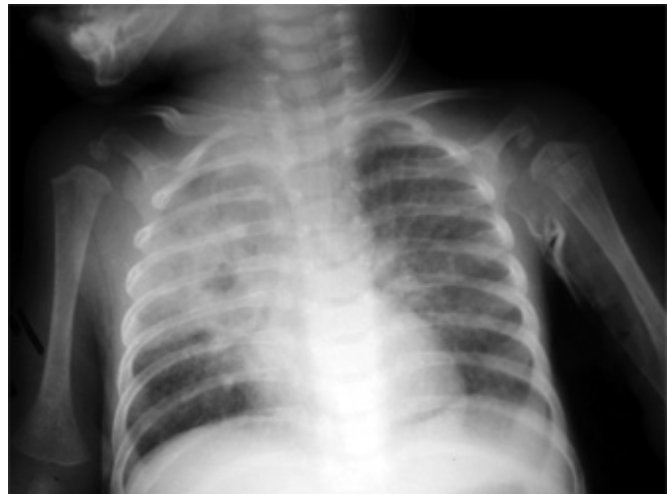

Fig. 2. An 18-month-old child with pulmonary TB. Note consolidation in RUL with air-bronchogram and interstitial lung marking more prominent in the left side.

Discussion

Most pulmonary tuberculosis cases seen in infants are due to primary infection. It begins when the respiratory secretion of a patient with TB is inhaled and reaches the lung alveoli which then causes parenchymal inflammation.^{2,13,16} The primary focus is the initial inflammation which is produced by localized alveolar consolidation.² This primary focus of TB is usually not visible on CXR but may rarely progress to involve a segment or an entire lobe.^{16,17} Infection then spreads to the central lymph nodes from the primary focus via draining lymphatic vessels, (appearing as a linear interstitial pattern on chest radiographs) and

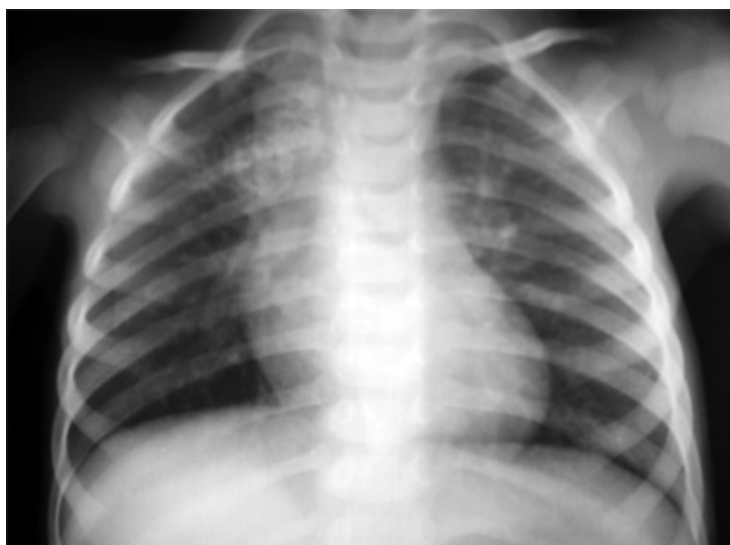

Fig. 3. A 2-year-old child with proved TB. Note calcified right paratracheal and left hilar lymphadenopathies.

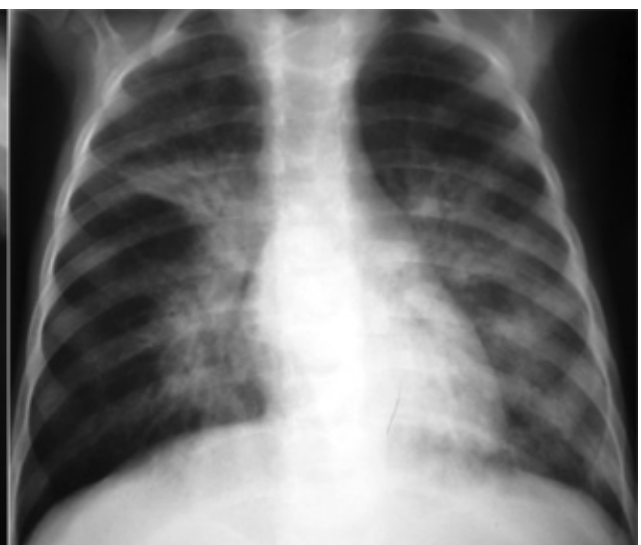

Fig. 4. A 4-year-old child with pulmonary TB. Bronchopneumonic infiltration in both lung fields and right hilar lymphadenopathy are noted.

results in regional lymphadenopathy.² Ranke complex is the primary infection focus of TB in the lung accompanied by regional lymphadenopathy and intervening lymphatic channels.¹⁶⁻¹⁹ In most cases, these parenchymal lesions and the accompanying lymphadenopathy resolve spontaneously.² In some cases, especially in young infants, the involved lymph nodes continue to enlarge.¹³ Some articles report that mediastinal lymphadenopathy with or without parenchymal abnormality is a hallmark of primary tuberculosis in childhood.¹⁶⁻¹⁹

In our study parenchymal and mediastinal involvement was 83.3% and 90%, respectively. Leung et al. in their series of 191 children, reported lymphadenopathy in 92% and parenchymal lesions in 70% of the patients.²⁰ Mikovic et al. reported 84.4% lymphadenopathy and 61.3% parenchymal involvement in a series of 204 cases.¹⁴ Our cases were far fewer in number than others. Although lymphadenopathy was the commonest manifestation (90%), it was less common than the Leung but more common than the Mikovic study. In the Leung study, 100% of the cases under 36 months age had lymphadenopathy, but in our study lymphadenopathy was only detected in 89.5% of the cases in this age group. In both Leung and Mikovic studies, right hila-mediastinal lymphadenopathy and right lung involvement were common;^{14,20} this finding is similar to our study, which reveals right hilar and paratracheal lymphadenopathy in 73.3% and right lung involvement in 60% of the cases.

We conclude that in our study, similar to other researches, lymphadenopathy, particularly right hila-mediastinal lymphadenopathy is one of the most common presentations of pulmonary TB especially in infants and young children (both younger and older than 36 months) without significant differences; and right lung involvement, outstandingly, the air-space pattern followed by interstitial involvement, are the main presentations of pulmonary tuberculosis in children.

Our study had fewer cases than other studies and although there was difference between some radiological aspects between cases younger and older than 36 months as other studies, we could not find significant differences between the age groups. This could be due to more progressive forms of tuberculosis and

more delay in referring the patients to special hospitals, which causes propagation of the disease and changes the pattern of radiography.

References

1. Andreu J, Caceres J, Pallisa E, Martinez-Rodriguez M. Radiologic manifestation of pulmonary tuberculosis. *Eur J Radiol* 2004 Aug;51(2):139-49.
2. Kim WS, Choi JI, Cheon JE, Kim IO, Yeon KM, Lee HJ. Pulmonary tuberculosis in infants: radiographic and CT findings. *AJR Am J Roentgenol* 2006;187:1024-33.
3. Schneider E, Castro KG. Tuberculosis trends in the United States, 1992-2001. *Tuberculosis (Edinb)* 2003;83:21-9.
4. Buckner CB, Leithiser RE, Walker CW, Allison JW. The changing epidemiology of tuberculosis and other mycobacterial infections in the United States: implications for the radiologist. *AJR Am J Roentgenol* 1991;156:255-64.
5. FitzGerald JM, Grzybowski S, Allen EA. The impact of human immunodeficiency virus infection on tuberculosis and its control. *Chest* 1991;100:191-200.
6. Germin BJ. Tuberculosis: the resurgence of our most lethal infectious disease- a review. *Pediatr Radiol* 1995;25:620-6.
7. Burroughs M, Beitel A, Kawamura A, Revai K, Ricafort R, Chiu K et al. Clinical presentation of tuberculosis in culture-positive children. *Pediatric Tuberculosis Consortium. Pediatr Infect Dis J* 1999;18:440-6.
8. Starke JR, Jacobes RF, Jereb J. Resurgence of tuberculosis in children. *J Pediatr* 1992;120:839-55.
9. Amodio j, Abramson S, Berdon W. Primary pulmonary tuberculosis in infancy: a resurgent disease in the urban United States. *Pediatr Radiol* 1986;16:185-9.
10. Schaaf HS, Gie RP, Beyers N, Smuts N, Donald PR. Tuberculosis in infants less than 3 months of age. *Arch Dis Child* 1993;69:371-4.
11. Vallejo JG, Ong LT, Starke JR. Clinical features, diagnosis and treatment of tuberculosis in infants. *Pediatrics* 1994;94:1-7.
12. Shingadia D, Novelli V. Diagnosis and treatment of tuberculosis in children. *Lancet Infect Dis* 2003;3:624-32.
13. Agrons GA, Markowitz RI, Kramer SS. Pulmonary tuberculosis in children. *Semin Roentgenol* 1993;28:158-72.
14. Milkovic D, Richter D, Zoricic-Letoja I, Raos M, Koncul I. Chest radiography findings in primary pulmonary tuberculosis in children. *Coll Antropol Jun* 2005;29(1):271-6.
15. Eisenhuber E, Mostbeck G, Bookier A, Stadler A, Rumetshofer R. Radiologic diagnosis of lung tuberculosis. *Radiologe* May 2007;47(5):393-400.
16. Kuhn JP, Slovis TL, Haller JO. Caffey's pediatric diagnostic imaging, 10th ed. Philadelphia, PA: Mosby 2004:982-1039.
17. McAdams HP, Erasmus J, Winter JA. Radiologic manifestation of pulmonary tuberculosis. *Radiol Clin North Am* 1995;33:655-78.
18. Marais BJ, Gie RP, Schaaf HS, Starke JR, Hesselring AC, Donald PR et al. A proposed radiological classification of childhood intra-thoracic tuberculosis. *Pediatr Radiol* 2004;34:886-94.
19. Lamont AC, Cremin BJ, Pelteret RM. Radiological patterns of pulmonary tuberculosis in the paediatric age group. *Pediatr Radiol* 1986;16:2-7.
20. Leung AN, Muller NL, Pineda PR, FitzGerald JM. Primary tuberculosis in childhood: radiographic manifestations. *Radiology* 1992;182:87-91.