

## UROGENITAL IMAGING

M. Pezeshki Rad MD<sup>1</sup>  
M. Mohammadi Fard MD<sup>2</sup>

## A Case of Pneumosrotum Following Chest Tube Placement

Pneumosrotum is a rare condition that occurs following a variety of procedural and pathological causes. We report a case of multiple trauma, pneumothorax and surgical emphysema, who presented with a swollen scrotum.

**Keywords:** Scrotum, Subcutaneous Emphysema, Pneumothorax

### Introduction

Pneumosrotum is a rare condition, which may be accompanied with retroperitoneal ruptures of air-filled gastrointestinal organs,<sup>1</sup> widespread subcutaneous emphysema,<sup>2</sup> and endoscopic and surgical procedures like peritonoscopy,<sup>3</sup> and retroperitoneal operations.<sup>4</sup> We report this case as well as the differential diagnoses and imaging findings, because pneumothorax followed by chest tube malposition is a rare etiology for pneumosrotum.

### Case Presentation

A 65-year-old man was admitted to the emergency department of the hospital after a motor vehicle accident. He was conscious and his Glasgow Coma Scale (GCS) score was 14, but he had dyspnea, tachypnea and respiratory distress.

On physical examination, there was crepitation and bilateral absence of breath sounds in the chest auscultation.

Chest radiograph showed that there were multiple rib fractures, which had developed flail chest. Also, there was widespread surgical emphysema in the chest wall, and the neck. Bilateral moderate pneumothorax and right costophrenic angle blunting were other findings in the chest film (Fig. 1A). Head CT scan and abdominal ultrasonography were normal, and there was no limb fracture. Bilateral apical chest tubes were inserted, and the patient was ventilated. The lungs were expanded, and respiratory distress was controlled; but malposition of one of the chest tubes and air leak at the entry site complicated the recovery. The increase of subcutaneous emphysema was observed on daily intensive care unit chest films and then an enlarged noncrepitant scrotum was suddenly discovered on the third day. An immediate portable ultrasonography revealed only reverberation artifact and the testes could not be seen (Fig. 1B). The pelvic film showed a huge scrotum filled with air. The air outlined the inner surface of the stretched scrotal wall and surrounded both testes (Fig. 1C). The chest film showed that one chest tube was placed in the chest wall subcutaneously (Fig. 1D). The position of the chest tube was corrected, the patient was treated conservatively and the pneumosrotum resolved after five days. Bilateral pneumothoraces and subcutaneous emphysema eventually resolved, and the patient was discharged from the hospital 13 days after the initial appearance of pneumosrotum.

1. Assistant Professor, Department of Radiology, Imam Reza Hospital, Mashhad University of Medical Sciences, Mashhad, Iran.

2. Assistant Professor, Department of Radiology, Imam Reza Hospital, Birjand University of Medical Sciences, Birjand, Iran.

Corresponding Author:  
Mahyar Mohammadi Fard  
Address: Department of Radiology, Imam Reza Hospital, Birjand, Iran.  
Tel/Fax: +98561 2226776  
Email: mahyarmohammadifard@yahoo.com

Received December 18, 2007;  
Accepted after revision July 20, 2008.

Iran J Radiol 2008;5(4):235-237

**Discussion**

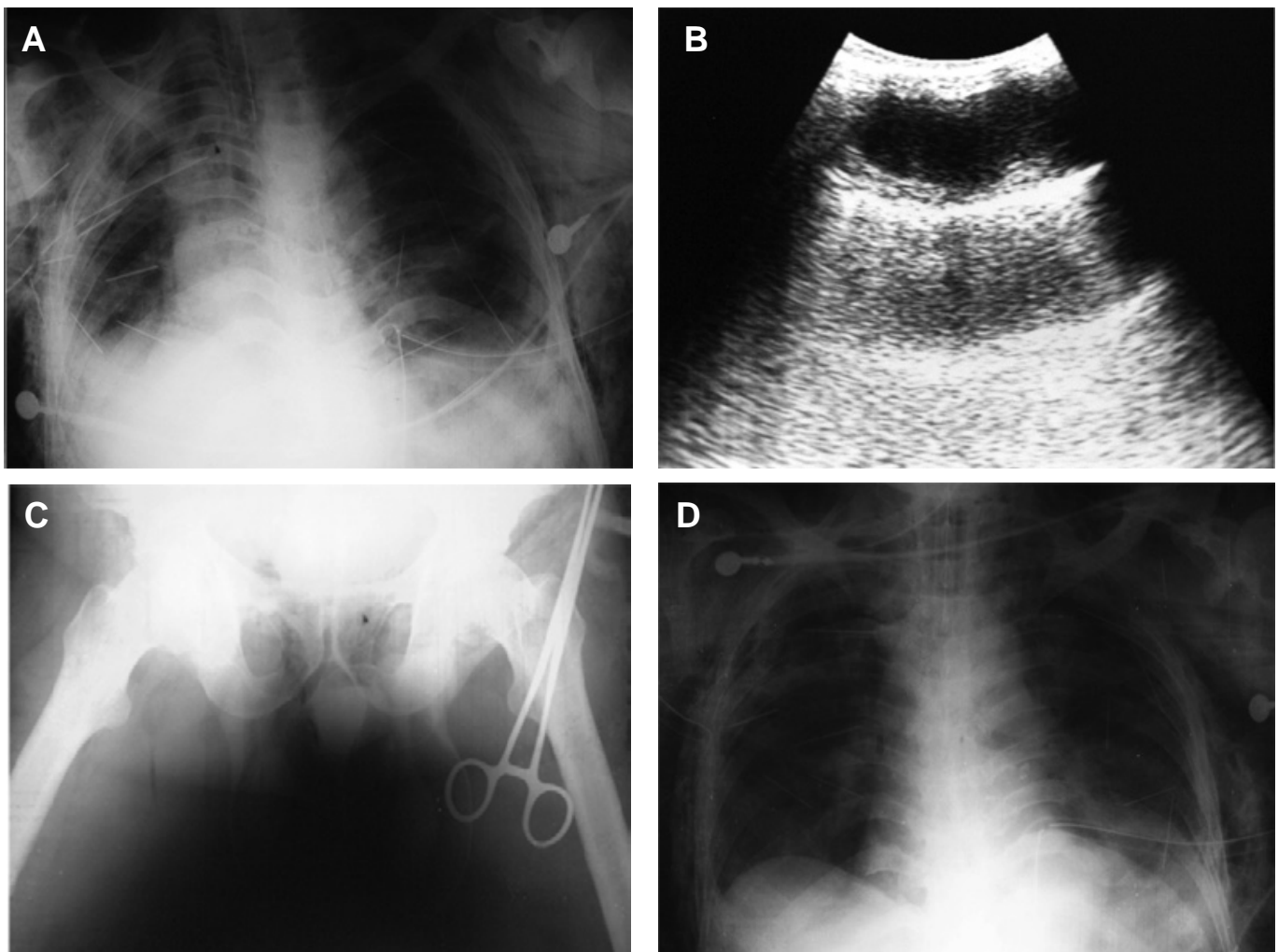
Pneumosrotum is an extremely rare occurrence that has several etiologies.<sup>5</sup> It is important to differentiate pneumosrotum from other causes of acute scrotum as it may be due to a serious pathology and may require medical or surgical intervention.<sup>5</sup>

The finding of air in the scrotal sac may be an early sign of a life-threatening condition or may represent an incidental finding associated with more benign conditions.<sup>6</sup> The varieties of possible etiologies for this rare condition include air accumulation from the lung or retroperitoneal sources, surgical manipulations, or infection with gas producing organisms.

In the review of literature, we found several cases of pneumosrotum with non-infectious etiologies from 1912 to 2006. Some of them are as follows: 8 cases were due to endoscopic and surgical procedures,<sup>3-5,7,8</sup> one case was developed by perforated duodenal ulcer<sup>1</sup> and the origin of seven cases was in the thorax.<sup>2,5,9-12</sup>

Subcutaneous air may have reached the scrotum by any of the three following routes:

1. Subcutaneously to the subcutaneous spaces of the scrotum and remain there, or dissect or diffuse interstitially through the dartos muscle to deeper layers.
2. Retroperitoneally through the inguinal canal but superficial to the facial coverings of the spermatic cord.



**Fig. 1.** A 65-year-old man with widespread surgical emphysema.

**A.** CXR: multiple rib fractures, widespread surgical emphysema in the chest wall and neck, bilateral moderate pneumothorax and right costophrenic angle blunting.

**B.** Scrotum ultrasonography: An immediate portable ultrasonography revealed only reverberation artifact, but testes did not appear.

**C.** Pelvic X Ray: The pelvic film showed a huge scrotum filled with air. The air outlined the inner surface of the stretched scrotal wall and surrounded both testes.

**D.** CXR: The chest film showed that one chest tube was placed in the chest wall subcutaneously.

3. Intraperitoneally through a patent processus vaginalis to the tunica vaginalis (least likely).<sup>2</sup>

In our case, regarding the patient's history of pneumothorax and chest tube malposition, spread of air occurred subcutaneously and retroperitoneally. The patient had no symptoms and signs of an infectious disease, therefore pneumoscrotum due to gas-forming organisms was easily ruled out.

Radiographic evidence of this situation includes two separate round soft tissue densities, which are completely surrounded by air density. Due to this view, the most probable place of the interstitial air is at least deeper than the dartos layer because it is continuous with the scrotal septum.

The interstitial air dissects through the tightly confined spaces pushed forward along a pressure gradient, from the location with the highest pressure to the least pressure space. However, once this tightly confined air has dissected far enough to reach the scrotum, it is proposed that the highly elastic properties of the scrotal skin and fascial layers make the scrotum a compliant pressure sink into which retroperitoneal and/or subcutaneous air boluses tend to decompress and ultimately accumulate, regardless of the route taken by the air.<sup>2</sup>

The present case illustrates the imaging features of pneumoscrotum and reminds us it could be consi-

dered in the differential diagnosis of scrotal swelling in a traumatic patient, especially in the presence of pneumothorax and surgical emphysema.

## References

1. Stahl JD, Goldman SM, Minkin SD, Diaconis JN. Perforated duodenal ulcer and pneumomediastinum. *Radiology* 1977;124(1):23-5.
2. Millmond SH, Goldman SM. Pneumoscrotum after spontaneous pneumothorax with air leak. *J urol* 1991;145(6):1271-2.
3. Christenson PJ, O'Connell KJ, Albert P, Knuff TE. Pneumoscrotum after diagnostic peritonoscopy. *Urology* 1980;16(1):78-9.
4. Adams-Ray J. Emphysema of the scrotum following retroperitoneal operation (sympathectomy). *Acta Chir Scand* 1953;106(1):35-7.
5. Casey RG, Al-Dousari S, Murphy D, Power RE. Chest drain insertion may result in the acute scrotum. *Scand J Urol Nephrol* 2006;40(1):78-9.
6. Watson HS, Klugo RC, Coffield KS. Pneumoscrotum: report of two cases and review of mechanisms of its development. *Urology* 1992;40(6):517-21.
7. Mazraany W. Massive pneumoscrotum following open gastrectomy. *Contemp Surg* 2004;60:219-21.
8. Keyes EL. Two cases of pneumoscrotum following nephrectomy. *Am J Urol* 1912;8:68.
9. Menzies D, Noble JG, Dent CM, Cox PJ. Pneumoscrotum: an unusual complication of cardiopulmonary resuscitation. *Br J Urol* 1991;67(4):440-1.
10. Archer GJ. Pneumoscrotum complicating pneumothorax and surgical emphysema. *Br J Urol* 1974;46(3):343.
11. Stavem K, Hoivik B. Pneumoscrotum after air leak from tension pneumothorax. *Tidsskr Nor laegeforen* 1996;116(10):1214-5.
12. Kono M. Scrotal emphysema: a case report. *Hinyokika Kyo* 2002 Jan 48(1):37-9.