

Ultrasound-Guided Fine Needle Aspiration Cytology in the Assessment of Cervical Metastasis in Patients Undergoing Elective Neck Dissection

Payman Dabirmoghaddam^{1,*}; Shervin Sharifkashany²; Leila Mashali¹

¹Otolaryngology Research Center, Amiralam Hospital, Tehran University of Medical Sciences, Tehran, Iran

²Department of Radiology, Amiralam Hospital, Tehran University of Medical Sciences, Tehran, Iran

*Corresponding author: Payman Dabirmoghaddam, Otolaryngology Research Center, Amiralam Hospital, Tehran University of Medical Sciences, North Saadi Ave., P.O. Box: 1145765111, Tehran, Iran. Tel: +98-2166703037, Fax: +98-2166760245, E-mail: dabirmoghaddam@sina.tums.ac.ir

Received: August 27, 2012; Revised: August 11, 2013; Accepted: September 10, 2013

Background: In head and neck cancer patients, diagnosis of metastatic cervical adenopathy is essential for treatment planning and prognosis assessment. Treatment of patients with head and neck cancer with clinically negative cervical lymph node (N0) remains controversial. While routine neck treatment would result in overtreatment in many patients, observation may delay the diagnosis and decrease the patients' survival.

Objectives: To gain insights into the unclear questions regarding the value of diagnostic modalities in patients with N0 neck, this study was designed to compare the diagnostic efficacy of palpation, ultrasonography (US) and ultrasound-guided fine needle aspiration (USGFNA) in detecting cervical lymph node metastasis.

Patients and Methods: Forty-two patients with head and neck cancer who underwent US and USGFNA prior to elective neck dissection were studied. Histopathologic findings of the neck specimens were compared with each diagnostic technique.

Results: Of the 53 neck dissection specimens, histopathology showed metastases in 16 cases. The overall accuracy of USGFNA, US and palpation was 96%, 68% and 70%, respectively. The specificity of USGFNA was superior to palpation and US alone. USGFNA had the highest sensitivity, predictive value and accuracy in detecting cervical metastases compared with other performed tests.

Conclusions: In our study, USGFNA was superior to palpation and US in detecting metastasis in clinically negative necks. This method can be recommended as a diagnostic tool in preoperative assessment of patients without palpable metastasis, but further investigations are needed before this modality could be considered as an alternative to elective neck dissection.

Keywords: Cancer of Head and Neck; Lymph Nodes; Palpation; Ultrasonography; Neoplasm Metastasis

1. Background

Treatment of patients with head and neck cancer requires an accurate staging to determine the type and extent of therapy and to predict the clinical outcome. Assessment of the cervical lymph nodes for metastases is an important step of this process. It is now widely accepted that the presence of lymph node metastases decreases patient survival by 50% (1).

Accurate detection of cervical metastases in patients with head and neck malignancies is of great importance for all cancer surgeons. Over the years, palpation has been the usual method of neck staging in head and neck cancer. However, the accuracy of palpation especially in clinically negative necks is usually reported to be low (1). To date, computed tomography (CT) and magnetic resonance imaging (MRI) have been shown to be superior to palpation in detecting metastatic cervical adenopathy. The usual criteria for detecting metastatic adenopathy by CT or MRI in most studies are nodal size, nodal shape or the presence of central necrosis (2, 3). Nevertheless, such criteria for identifying microscopic nodal metastases are

not generally applicable and these modalities have rarely changed the management of clinically negative necks (4).

Ultrasound of the neck has been used extensively for cervical metastases in head and neck cancer. Although various diagnostic criteria have been proposed by some authors to differentiate metastatic from reactive nodes, these findings cannot consistently diagnose metastatic deposits and most researchers today use size or grouping of three or more lymph nodes as the only reliable diagnostic criteria (5). Addition of US-guided FNA (USGFNA) to the ultrasound examination offers the benefit of cytologic analysis of suspicious lymph nodes and in previous studies, it has improved the specificity and overall accuracy of ultrasonography (4, 6). However, the role of USGFNA in clinically negative necks needs further investigation (6).

Treatment of patients with head and neck cancer who have a clinically negative cervical lymph node (N0) remains controversial. The routine use of neck dissection or radiation for all N0 patients would result in overtreatment of many patients. On the contrary, the policy of observa-

tion with therapeutic neck dissection once regional metastases become apparent may delay diagnosis and treatment of the disease and result in a less favorable prognosis (7).

Currently, for most head and neck surgeons, observation is the preferred method when the possibility of occult metastasis is less than 20% and elective neck treatment is preferred if the probability of metastasis is greater than 20% (7). Obviously, if a diagnostic test was available to accurately assess the cervical metastases, the need for elective treatment could be reduced.

2. Objectives

The aim of this study was to compare the accuracy of palpation, ultrasonography, and USGFNA with pathological results (as gold standard) to diagnose occult metastasis in N0 patients with head and neck cancer who underwent elective neck dissection.

3. Patients and Methods

The study group consisted of 42 patients with head and neck squamous cell carcinoma who were staged N0 by palpation. These patients subsequently underwent elective neck dissection at Tehran University of Medical Sciences, Amiralam Hospital between 2008 and 2010. Elective neck dissection was performed when the risk of occult neck metastasis was higher than 20% based on clinical assessment of the location and size of the primary tumor. The study was approved by the institutional research ethics committee and patients were informed about objectives of the study and completed informed consent forms.

No patients had a prior history of surgical treatment or radiation to the neck. Clinical assessment included a complete head and neck examination. Palpation of the neck was performed by two head and neck surgeons.

To rule out metastatic cervical disease, all 42 patients underwent preoperative ultrasonography of the neck. In order to decrease the risk of reactive lymphadenopathy, all ultrasounds were performed prior to biopsy of the primary tumor. Ultrasonographic examination was made using a Mylab 50 (Esaote, Italy) with a 10 MHz linear array probe.

The following criteria were used to define a visualized lymph node in ultrasonography as suspicious for metastasis: minimal axial diameter of more than 8 mm for sub-digastric nodes and 7 mm for all other nodes of the neck, effacement of the fatty hilum, round shape and grouping of enlarged nodes. A 25 gauge needle and a 10 cc syringe were used to aspirate suspicious lymph nodes under US guidance (Figure 1). No local anesthesia was used prior to the FNA. During the procedure, multiple passes of needle were made through the node to obtain a single aspirate. The aspirate was then expressed onto glass slides, air-dried and stained with May-Grunwald-Giemsa and interpreted by a cytopathologist (Figure 2). Several aspirates are often necessary for adequate sampling. USGFNA was considered negative if no suspicious nodes were

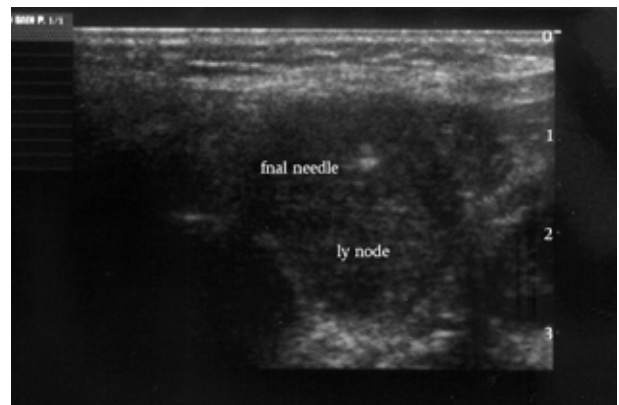


Figure 1. USGFNA; Note the tip of the needle inside a malignant appearing lymph node

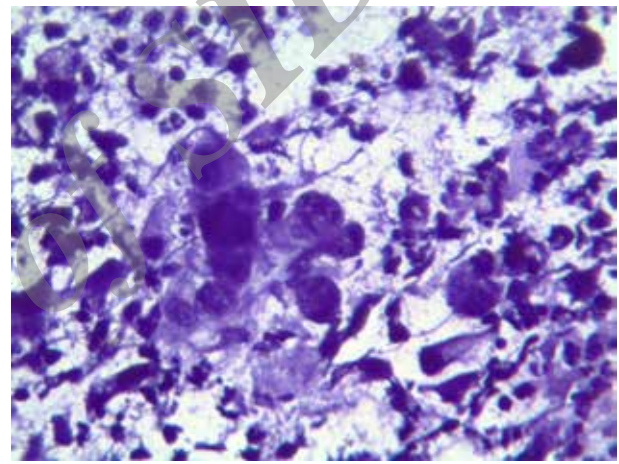


Figure 2. FNA of a cervical lymph node showing cluster of cells with pleomorphism, hyperchromasia and irregular borders

visualized or the cytologic examination revealed benign features. The test was considered positive if the aspirate showed malignant cells.

All patients endured the procedure well without any major complication, but in patients requiring multiple aspirations, the procedure was painful and unpleasant.

Neck dissection was performed within two weeks of the imaging study and USGFNA. The specimen was labeled by the surgeon as level I to V according to surgical neck level classification (8). Consequently, the neck dissection specimen was examined by an experienced pathologist and the findings were recorded per nodal level. Since presence of a single metastasis leads to treatment of the whole neck side, we considered the histopathology results per neck side rather than for a single node. Physical examination and imaging results were compared with histopathological findings, which were accepted as the gold standard. The sensitivity, specificity, positive and negative predictive value for palpation, ultrasonography, and USGFNA were determined. The overall accuracy for each modality was also calculated.

4. Results

The study group consisted of 42 patients with head and neck cancer who were staged N0 by palpation alone by two otolaryngologists. There were 40 men and two women with the average age of 64 years. Primary tumor location was as follows: 18 mobile-tongue, five floor-of-mouth, three buccal mucosa, three alveolar ridge, eleven supraglottic larynx, and two oropharynx tumors. In total, 53 neck dissection specimens were obtained (Table 1).

Sixteen of the 53 neck dissection specimens contained metastatic deposits on permanent histopathology. On average, 17 nodes were evaluated for malignancy per neck specimen.

Sixty-one USGFNA of suspicious nodes were performed in 40 patients. In two other patients, no suspicious lymph node was identified and nodal aspiration was not performed. These patients later proved to be negative on histopathology. Fifteen nodal aspirates showed malignant cells, of which two were on the same side of the neck. Five aspirates (8%) were not satisfactory for a diagnosis after repeated attempts that were considered non-diagnostic. The other aspirates revealed a reactive node. A total of 46 nodes were characterized negative with USGFNA of which forty-one showed features of reactive lymphadenopathy and five were non-diagnostic aspirates.

The tumor negative lymph nodes in USGFNA varied in size from 8 to 14 mm; whereas, metastatic lymph nodes had a size between 5 and 15 mm. The average size of the lymph nodes with non-diagnostic aspirates was 6 mm. Most metastatic lymph nodes were detected at level 2 (Table 2). Four of the non-diagnostic aspirates occurred at level 1 and the other one occurred at level 2. Fourteen of the 16 patients with pathologically-proven metastases were correctly identified by USGFNA, but this technique yielded false negative results in two of the patients. Of the five nondiagnostic smears in USGFNA, two were positive for cancer on histopathological examination. In fact, the false negative results of USGFNA were due to non-diagnostic smears. Palpation of the neck resulted in 16 false negative examinations. USGFNA produced no false positive examination.

The results of the histopathology and the results of the imaging studies were considered per neck side and are presented in Table 3. The results of diagnostic efficacy indices of palpation, US and USGFNA are shown in Table 4.

USGFNA had the highest sensitivity, specificity, predictive value and accuracy in detecting cervical metastases compared with the other performed tests. Ultrasonography alone had a high negative predictive value, but a suspicious lymph node in US did not harbor metastases most of the time, demonstrating the need for a highly specific test (like FNA) as adjunct to US. The accuracy of ultrasonography was lower than USGFNA and similar to palpation of the neck.

Table 1. Characteristics of the Study Population

Variable	No.
Patients	42
Neck dissection specimens	53
Site of the primary tumor	
Oral cavity	29
Supraglottic larynx	11
Oropharynx	2
Tumor stage	
T1	26
T2	13
T3	3

Table 2. Location of the Examined Lymph Nodes

Anatomical Location	Number	Metastatic
Level I (Submandibular and Submental)	8	1
Level II (Upper jugular)	23	9
Level III (Mid jugular)	7	1
Level IV (Lower jugular)	14	3
Level V (Posterior triangle)	9	1
Total	61	15

Table 3. Results of Palpation, Ultrasonography, USGFNA Versus Histopathology

	Histopathology +	Histopathology -	Total
Palpation -	16	37	53
Ultrasonography +	11	12	23
Ultrasonography -	5	25	30
USGFNA +	14	0	14
USGFNA-	2	37	39

Table 4. Diagnostic Efficacy Indices of Palpation, US and USGFNA

	Palpation	US	USGFNA
Sensitivity	-	69	87.5
Specificity	-	67.5	100
Positive predictive value	-	48	100
Negative predictive value	-	83	95
Overall accuracy	70	68	96

5. Discussion

Accurate staging of lymph nodes is essential for optimal patient management in the clinically N0 neck where elective treatment is a controversial issue. The performance of unnecessary neck dissection increases the risk of morbidity for the patient. Generally, elective neck treatment can be considered if the risk of occult neck metastasis exceeds 20%, which in turn is determined by factors such as tumor

histology, size and location. The number of elective treatments of the neck would decrease if an accurate staging method able to reliably detect or exclude metastatic cervical lymph nodes were available. If a diagnostic modality decreases the risk of occult neck metastases to below 20%, then perhaps elective neck dissection can be avoided. While palpation is the traditional method used to stage the neck, of great concern is whether palpation alone is sufficient to evaluate the neck status. It is commonly accepted that palpation alone is inadequate to evaluate whether a lymph node is positive for metastasis (1, 4, 9). Normal sized lymph nodes containing occult metastases can hardly be detected by palpation alone (10). Furthermore, it is often impossible to differentiate a single enlarged lymph node from multiple lymph nodes by palpation; consequently leading to errors in the staging of the disease (10). The rates of diagnosing cervical metastasis by palpation alone reported by various authors range between 65% and 70% (7). In this study, we found an accuracy of 70% for palpation, while thirty percent of palpation negative patients showed pathologically proven metastatic adenopathy. With regard to these findings, it is impossible to detect an important part of malignant lymph nodes by palpation.

To date, CT scan and MRI have been advocated as valuable adjuncts to palpation. Most studies agree on the efficacy of these additional staging modalities and the sensitivity rate of CT scan in different studies has been 60% to 90% (2, 3, 9, 11). Selection of a cutoff point for diagnostic criteria such as size changes the sensitivity and specificity rates. The presence of cervical metastases in the study group also influences the results of CT scan accuracy. In studies with a high number of clinically positive cervical adenopathy, CT scan yielded a sensitivity rate of 90%, while in studies with NO patients; the sensitivity rate for CT scan was approximately 60% (11).

Ultrasonography is reported superior to manual palpation for detecting cervical lymph nodes and metastases. The advantage of US was shown by detection of small, less than 10 mm lesions more frequently than clinical examination. US can detect a large number of nonpalpable lymph nodes (5, 10), but in a majority of patients, the accuracy of this technique is low. In a study by van den Brekel et al. (4), the authors found that in patients with head and neck squamous cell carcinoma (SCC), the accuracy of US never exceeded 70%.

Multiple criteria have been suggested to improve the accuracy of ultrasonography in diagnosing metastatic adenopathy. Although some ultrasound features can help to differentiate benign from malignant lymph nodes, the significance of this criteria in N0 necks should still be evaluated (12).

Normal lymph nodes are usually oval in shape; whereas, metastatic lymph nodes have a tendency to be rounder (Figure 3). In fact, lymph node shape is not a very specific criterion and round adenopathies may be seen in tuberculosis, lymphoma or reactive lymphadenopathy (13). Furthermore, the size of the lymph nodes in most of the

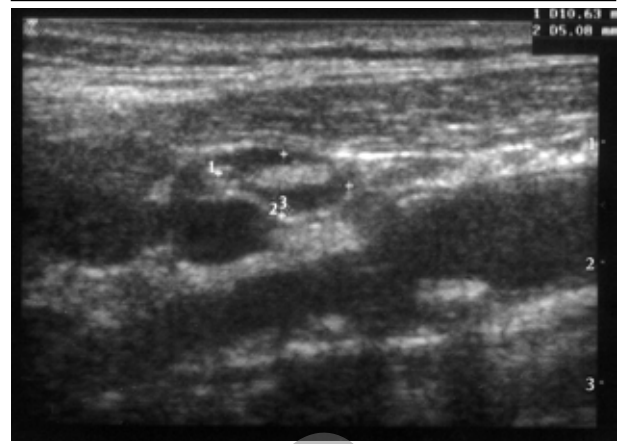


Figure 3. A normal appearing lymph node with a thin cortex and echogenic hilum

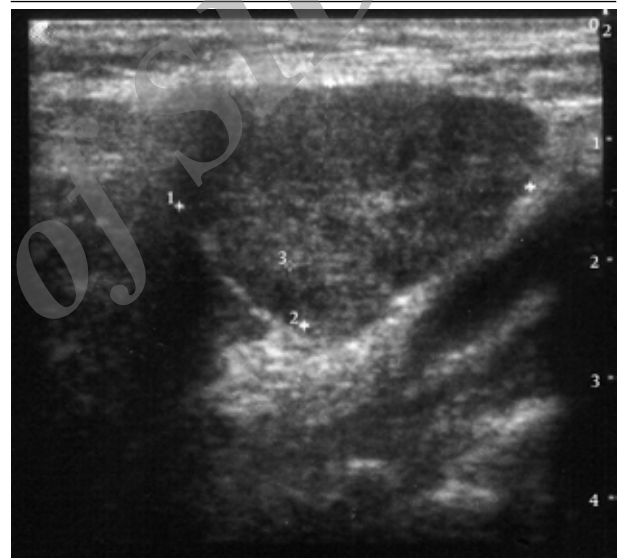


Figure 4. A metastatic lymph node with a lobulated border and heterogeneous echo pattern

previous studies was more than 10 mm, so the importance of lymph node shape in N0 necks is not fully understood. The existence of groups of three or more lymph nodes of borderline size were proven to increase sensitivity at a high specificity (14); however, the importance of such nodal grouping in N0 necks still needs to be assessed.

Lymph node necrosis in ultrasonography is a highly specific sign of head and neck SCC metastasis (Figure 4), but this finding is thought to ensue relatively late in the course of the disease and it is rare for lymph nodes less than 10 mm to show this sign (14).

Normal and reactive nodes have an echogenic hilum due to the interfaces between multiple lymphatic sinuses as they join on the medulla (13). Traditionally, it is believed that malignant nodes have no visible hilum and effacement of the hilum is considered as a diagnostic criteria of malignancy; however, loss of fatty hilum is not a definite indicator of malignancy and may be seen in as many as 9% of reactive lymph nodes (15).

As the above morphologic criteria are rare in small nodes, the size criterion is especially important in NO necks (14). Optimal size criteria should be sensitive and specific. As small size lymph nodes may harbor metastatic foci, reducing cut-off size will increase the sensitivity at the cost of lowering the specificity. Numerous studies have tried to determine the optimal size criteria; however, wide variations in measurement techniques make the decision difficult. Moreover, the number of such studies in NO necks is limited (12). In this study, we used the minimum axial diameter of the lymph nodes, as it has been shown that it is more accurate than other measurements (14).

Because of the limitations of US, combining a highly specific test with US is considered helpful in the assessment of metastasis (10). With USGFNA it is possible to sample suspicious cervical lymph nodes to complete radiologic findings and differentiate benign from malignant nodes. It is important for clinicians to know how reliable a cytologic finding is. The role of FNA in the diagnosis of metastatic cervical lymph nodes has been described before (16). Previous data have shown that the accuracy of FNA in metastatic cervical adenopathy is about 95% (6).

The sensitivity of FNA in correctly diagnosing malignant cervical adenopathy under manual guidance is 90% (10). Several studies have shown that FNA under US guidance is more sensitive than under palpation control. Ultrasound allows sampling of small nonpalpable lymph nodes and improves the adequacy rate of FNA. The sensitivity of FNA under ultrasound guidance is often reported from 98% to 100% in palpable metastatic lymph nodes and 70% in nonpalpable lymph nodes (10). Several studies show that a malignant cytologic finding in FNA is highly reliable. The specificity of FNA in diagnosing malignancy is as high as 100% (10, 16); however, false positive findings of FNA have been reported in patients with previous irradiation of the neck (10).

In the current study, we prospectively compared the accuracy of palpation, US, and USGFNA in patients with head and neck cancer who were candidates for elective neck dissection. Our results showed that USGFNA had a higher specificity than US alone as well as a better overall accuracy (Table 4). The overall accuracy of palpation was noticeably lower than USFNA and was consistent with previously published studies. The specificity and overall accuracy of the imaging methods tested in our patient population were similar to most other studies, except that the sensitivity of US, and USGFNA was somewhat lower. (1, 10-16). The low sensitivity rate of imaging and USGFNA in our study compared to previous studies may be due to including only NO patients. Obviously, the sensitivity of imaging improves if the study population includes clinically positive necks. In a similar study involving 25 head and neck cancer patients with negative necks, the sensitivity of CT and USGFNA was 60% and 50%, respectively, while the specificity was 100% for both modalities (1).

The main drawback incurred by USGFNA in our study was false-negative examinations. USGFNA inaccuracy could have been due to small metastasis missed by the needle, a single tumor cell overlooked by the pathologist or aspiration of a wrong lymph node (1). In addition, lymph nodes near the mandible are difficult to visualize or aspirate due to the shadow of the mandible (11). In our study, four of the non-diagnostic aspirates occurred at level 1.

The 8% rate for insufficient aspirates is well within reported figures of 5% to 20% (6). Immediate cytologic evaluation of the smears by the cytopathologist could improve the diagnostic yields and eliminate the problem of inadequate aspirates (6).

Although USGFNA is an invasive method, it has many advantages over CT scan such as absence of radiation and no need of contrast medium. The method costs less than CT and is well tolerated by patients. On the negative side, USGFNA is more operator-dependent and the primary tumor is difficult to evaluate. Furthermore, the possibility of micrometastasis is a problem with all of the current imaging modalities (10). The size of micrometastases is generally considered less than 3 mm and most of them are found in lymph nodes with less than 10 mm diameter. The size of these lymph nodes is within the resolution of ultrasound; however, placement of the needle into the lesion during FNA is problematic (6).

Our results confirm findings of other studies (1, 6, 10) that showed USGFNA is a highly sensitive, specific, and accurate technique for the diagnosis of metastatic adenopathy in patients with head and neck cancer. USGFNA correctly classified the neck status in 40 out of 42 patients, which is similar to other studies (6). However, because of the small number of patients in this study, further investigations are needed before this modality could be considered as an alternative to elective neck dissection.

Authors' Contributions

Payman Dabirmoghaddam developed the idea, collected clinical data and wrote the manuscript. Shervin Sharifkashani developed the idea and collected clinical data. Leili Mashali developed the idea, collected and analyzed clinical data.

References

1. Righi PD, Kopecky KK, Caldemeyer KS, Ball VA, Weisberger EC, Radpour S. Comparison of ultrasound - fine needle aspiration and computed tomography in patients undergoing elective neck dissection. *Head & Neck*. 1997;19(7):604-10.
2. Mack MG, Rieger J, Baghi M, Bisdas S, Vogl TJ. Cervical lymph nodes. *Eur J Radiol*. 2008;66(3):493-500.
3. Krestan CR. Modern imaging lymph node staging of the head and neck region. *Euro J Radiol*. 2006;58(3):486.
4. van den Brekel MWM, Stel HV, Castelijns JA, Croll GJ, Snow GB. Lymph node staging in patients with clinically negative neck examinations by ultrasound and ultrasound-guided aspiration cytology. *Am J Surg*. 1991;162(4):362-6.
5. Ahuja AT, Ying M, Ho SY, Antonio G, Lee YP, King AD, et al. Ultrasound of malignant cervical lymph nodes. *Cancer Imaging*.

- 2008;**8**:48-56.
6. Knappe M, Louw M, Gregor RT. Ultrasonography-guided fine-needle aspiration for the assessment of cervical metastases. *Arch Otolaryngol Head Neck Surg.* 2000;**126**(9):1091-6.
 7. Jalisi S. Management of the clinically negative neck in early squamous cell carcinoma of the oral cavity. *Otolaryngol Clin North Am.* 2005;**38**(1):37-46.
 8. Robbins KT, Shaha AR, Medina JE, Califano JA, Wolf GT, Ferlito A, et al. Consensus statement on the classification and terminology of neck dissection. *Arch Otolaryngol Head Neck Surg.* 2008;**134**(5):536-8.
 9. Rottey S, Petrovic M, Bauters W, Mervillie K, Vanherreweghe E, Bonte K, et al. Evaluation of metastatic lymph nodes in head and neck cancer: a comparative study between palpation, ultrasonography, ultrasound-guided fine needle aspiration cytology and computed tomography. *Acta Clin Belg.* 2006;**61**(5):236-41.
 10. Atula TS, Grénman R, Varpula MJ, Kurki TJI, Klemi P. Palpation, ultrasound, and ultrasound-guided fine-needle aspiration cytology in the assessment of cervical lymph node status in head and neck cancer patients. *Head & Neck.* 1996;**18**(6):545-51.
 11. Takes RP, Knecht P, Manni JJ, Meeuwis CA, Marres HA, Spoelstra HA, et al. Regional metastasis in head and neck squamous cell carcinoma: revised value of US with US-guided FNAB. *Radiology.* 1996;**198**(3):819-23.
 12. Richards PS, Peacock TE. The role of ultrasound in the detection of cervical lymph node metastases in clinically NO squamous cell carcinoma of the head and neck. *Cancer Imaging.* 2007;**7**:167-78.
 13. Ahuja A, Ying M. An Overview of Neck Node Sonography. *Invest Radiol.* 2002;**37**(6):333-42.
 14. van den Brekel MW, Stel HV, Castelijns JA, Nauta JJ, van der Waal I, Valk J, et al. Cervical lymph node metastasis: assessment of radiologic criteria. *Radiology.* 1990;**177**(2):379-84.
 15. Dudea SM, Lenghel M, Botar-Jid C, Vasilescu D, Duma M. Ultrasonography of superficial lymph nodes: benign vs. malignant. *Ultrasound Med.* 2012;**14**(4):294-306.
 16. Atula TS, Varpula MJ, Kurki TJ, Klemi PJ, Grenman R. Assessment of cervical lymph node status in head and neck cancer patients: palpation, computed tomography and low field magnetic resonance imaging compared with ultrasound-guided fine-needle aspiration cytology. *Eur J Radiol.* 1997;**25**(2):152-61.

Archive of SID