

^{99m}Tc-HMPAO-Labeled Autologous Leukocyte SPECT/CT for Diagnosis of Bacterial Endocarditis of the Prosthetic Pulmonary Conduit: A Clinical Case

Svetlana Ivanovna Sazonova,^{1,2} Julia Nikolaevna Ilyushenkova,^{1,2,*} Konstantin Valer'evich

Zavadovsky,^{1,2} and Yuri Borisovich Lishmanov^{1,2}

¹Nuclear Medicine Department, Federal State Budgetary Scientific Institution, Research Institute for Cardiology, Russia

²Laboratory No. 31, National Research Tomsk Polytechnic University, Russia

*Corresponding author: Julia Nikolaevna Ilyushenkova, Nuclear Medicine Department, Federal State Budgetary Scientific Institution, Research Institute for Cardiology, Russia. Tel: +7-9528816120, E-mail: biofizik85@mail.ru

Received 2015 October 26; Revised 2015 December 11; Accepted 2015 December 16.

Abstract

In this paper, we present a case of bacterial endocarditis of the prosthetic pulmonary conduit found in a 26-year-old man. An echocardiography study around the pulmonary valve showed the presence of a floating mass attached to the wall of the conduit. This formation was thought to be a floating calcific leaflet of the conduit or a developed vegetation of the conduit. Due to the uncertainty of the results, pulmonary multidetector row computed tomography (MDCT) angiography was performed. The MDCT examination showed the presence of a floating 4 × 8-mm sized mass in the pulmonary conduit. Taking into account the patient's complaints, medical history data, and clinical-instrumental examination, myocardial scintigraphy with ^{99m}Tc-HMPAO-labelled autologous leukocytes combined with CT (^{99m}Tc-HMPAO-SPECT/CT) was performed. Based on overlaying of the scintigraphic images and the MDCT aortography scans, anatomic localization of the pathologic accumulation was found in a projection of the pulmonary valve prosthesis. Surgical intervention, with cardiopulmonary bypass, was performed for replacement of the valve-containing conduit. Pathomorphologic study of the surgical material confirmed the hypothesis of bacterial endocarditis. Therefore, hybrid technologies such as ^{99m}Tc-HMPAO-SPECT/CT contribute to the earlier and more precise diagnosis of infectious endocarditis, avoiding many errors associated with patient treatment and the development of complications.

Keywords: SPECT/CT, Inflammation, Bacterial Endocarditis

1. Introduction

Diagnosis of infectious endocarditis (IE) is a challenging and relevant problem of modern medicine due to its high incidence and mortality rates (1). Indeed, according to data of different authors, IE morbidity ranges from 1.7 to 11.6 cases per 100,000 people each year (1). As a rule, IE is detected in only 24.2% of cases and as late as three or more months after onset of the disease. This situation is largely explained by the diagnostic difficulties in verifying this pathology. The known classic signs of IE are cardiac valvulopathy, bacteremia or fungemia, embolism, and autoimmune vasculitis (1). Due to the widespread use of antibiotics nowadays, not all patients present with a polymorphic clinical picture of endocarditis. The so-called peripheral symptoms (Lukin-Libman, Osler) are present in only 10-15% of patients, but are not present in 75% of patients. Nevertheless, IE diagnosis is still based on traditional signs with mandatory verification by diagnostic ultrasound (2).

The majority of radiological methods of study, such as computed tomography (CT), magnetic resonance imaging

(MRI), and echocardiography have high-resolution capabilities, but they are not able to detect signs of inflammation before the development of anatomical changes to the tissues. One of the solutions to this problem may be the use of nuclear medicine that enables evaluation of pathophysiological processes in affected organs and detection of the inflammatory process at early stages of the disease. This is achieved through the use of radiopharmaceuticals that accumulate in the area of inflammation.

2. Case Presentation

A 26-year-old man was admitted to the clinic with complaints of irregular heartbeat, low-grade fever, asthenia, inspiratory dyspnea, feeling unwell, and rapid fatigability.

According to the patient's history, he was diagnosed as congenital heart disease (CHD) (tetralogy of Fallot and type 3 pulmonary atresia) at one year old by echocardiography. For this reason, at age three, the patient underwent radical correction of CHD, which included ventricular septal

defect closure and aortic homograft implantation in a pulmonary position. Since age 13, the patient had complained of palpitation and irregular heartbeat. However, follow-up examination showed a dysfunction of the prosthesis in the form of a worsening regurgitation and ejection pressure gradient on the pulmonary artery up to 75 mm Hg. At age 20, the patient received conduit replacement with a valve-containing 22 mm Hancock conduit in a pulmonary position. One year later, the patient underwent endovascular occlusion of major aortopulmonary collaterals on the right.

The patient had the above-described complaints since 2013. During the period from 2013 to 2015, the patient was repeatedly treated concerning pansinusitis, bronchitis, and abscess-forming pneumonia. The examinations revealed cytomegalovirus carrier, esophageal mycosis, hepatosplenomegaly, and immune deficiency signs. Repeated blood cultures for sterility did not reveal a presence of pathogenic bacteria, though sputum culture showed growth of *Candida albicans*. In March 2015, an echocardiography study detected vegetation in a projection of the pulmonary valve. At the time of admittance to the clinic, the overall health of patient was moderately severe and skin pallor was present. Auscultation of the lungs revealed vesicular respiration and loud heart sounds; single extrasystoles in a horizontal body position and systolic noise over the left sternal border were auscultated. Thus, management of the patient was based on the 2015 European society of cardiology (ESC) guidelines for the management of infectious endocarditis.

The echocardiography study around the pulmonary valve showed the presence of a floating mass attached to the wall of the conduit (Figure 1). This formation was thought to be a floating calcific leaflet of the conduit or a developed vegetation of the conduit. Due to the uncertainty of the results, pulmonary multidetector row CT (MDCT) angiography was administered. The MDCT examination showed the presence of a floating mass, 48 mm in size, in the pulmonary conduit (Figure 2).

Taking into account the patient's complaints, medical history data, and clinical-instrumental examination results, a myocardial scintigraphy with ^{99m}Tc -HMPAO-labelled autologous leukocytes was performed. Radiologists were asked not only to detect the pathologic foci of the radiopharmaceutical accumulation suggestive of the leukocyte infiltration, but also to evaluate the topography. In this case, an administration of MDCT without contrast enhancement would not allow accurate determination of the focus location due to the absence of a difference between the X-ray densities of the cardiac structures. In this regard, contrast-enhanced pulmonary MDCT angiography was administered, with further comparison of the images

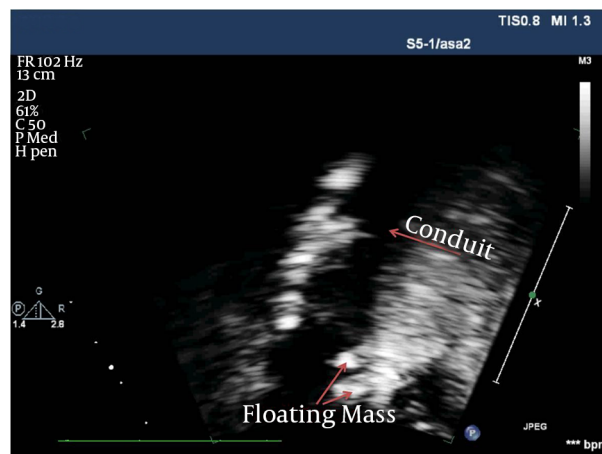


Figure 1. A 26-year-old man with irregular heartbeat, low-grade fever, asthenia and inspiratory dyspnea. He had history of cardiac surgeries due to tetralogy of Fallot that received conduit replacement for prosthetic valve. Transthoracic echocardiography shows floating mass in the pulmonary conduit (red arrows).

in two modalities. The informed consent of the patient was obtained.

Leukocytes were labeled with ^{99m}Tc by using ^{99m}Tc -exametazime (HMPAO, Ceretec, Nycomed Amersham), according to the 2010 guidelines developed by the working group of the European association of nuclear medicine (3).

The scintigraphic examination of the heart was performed in SPECT mode 20 hours after the introduction of the radiopharmaceutical on a hybrid SPECT/CT unit GE Discovery NM/CT 570C (USA) with ultrafast CZT-detectors. Immediately before the acquisition, a radioisotope marking was placed on the patient's chest to facilitate the overlapping of the images. Upon completion of the acquisition, the ECG-electrode was attached over the isotope marking to provide a marking for CT images. There were no changes in the patient's body position or in the tomographic tabulation height.

Analysis of scintigrams demonstrated the presence of a high-intensity round-shaped focal accumulation of the radiopharmaceutical in the anterior mediastinum, left of the sternum, though precise localization of the focus could not be determined. Based on overlaying of the scintigraphic images and the MDCT angiography scans, anatomic localization of the pathologic accumulation was found in a projection of the pulmonary valve prosthesis (Figure 3).

Based on the medical history, the results of the performed examination, and the absence of an effect from conservative treatment, the patient received the following diagnosis: bacterial endocarditis of the pulmonary valve conduit. Surgical intervention with cardiopul-

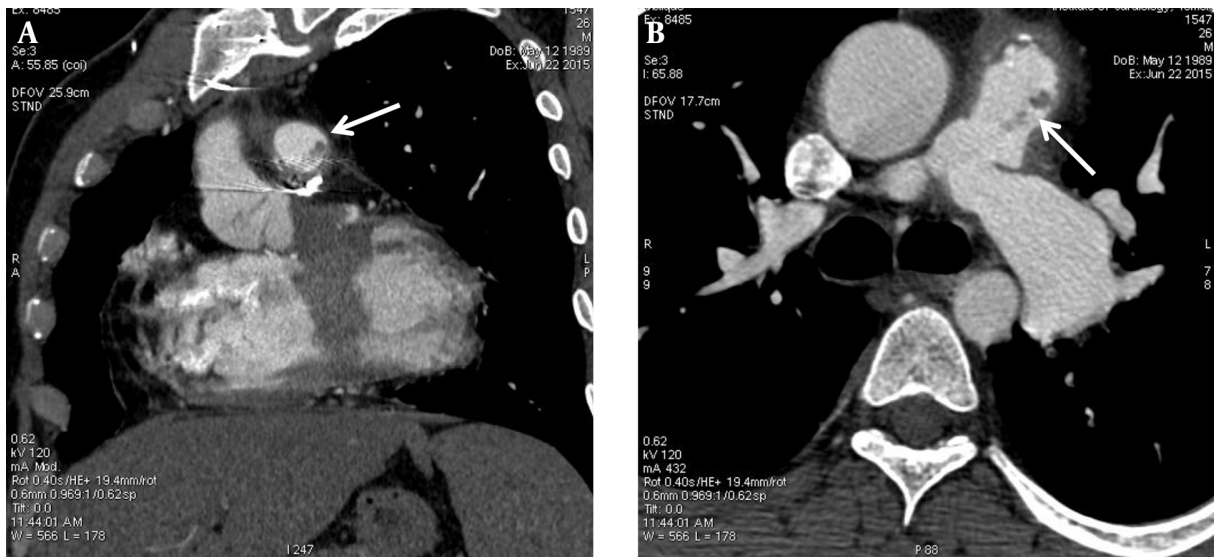


Figure 2. Multislice CT-angiopulmonography; floating mass in the pulmonary conduit (arrows) (A,B).

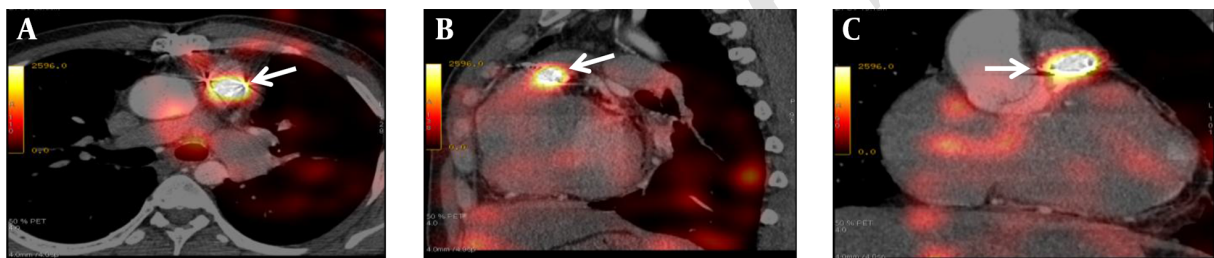


Figure 3. ^{99m}Tc -HMPAO-labelled leukocyte scintigraphy combined with multislice CT-aortography. Focal pathologic accumulation of ^{99m}Tc -HMPAO-leukocytes in the area anatomically corresponding to the pulmonary valve (arrows) (A,B,C).

monary bypass was performed for replacement of the valve-containing conduit. During the revision of the pulmonary valve, floating masses (imaging on transthoracic echocardiography and MDCT) were detected as a tear off flap of valve. A pathomorphology study of the surgical material confirmed the hypothesis of bacterial endocarditis. Bacteriological examination of the prosthetic capsule and the pulmonary valve cultures revealed the growth of pathogenic flora (gram-negative cocci).

3. Discussion

Endocarditis of the prosthetic valve is a rare pathology. According to data of various authors (4), after the first surgery the frequency rates of prosthetic valve endocarditis range from 1.4% to 3.1% during 12 months, from 3.2% to 5.7% during 5 years and do not exceed three cases per 1000 per year (5).

The existing modified Duke criteria, with a sensitivity rate reaching 80%, are currently considered the gold standard for IE diagnosis (6). However, the diagnostic accuracy of these criteria decreases significantly in the case of prosthetic valve IE (7). This can be explained by the absence of big criteria that consider negative results of blood cultures and by limited acoustic accessibility for echocardiography, due to the artefacts from the prosthetic valve. Small criteria suggestive of possible IE include fever, hemogram shift to the left, and symptoms of heart failure, and are significantly present more often.

One of the solutions to this problem of diagnostic inaccuracy may be the use of nuclear medicine methods for evaluating pathophysiologic processes, occurring in the affected organ, and detecting inflammatory process at the early stages of the disease. This can be achieved through the use of radiopharmaceuticals, accumulating in the focus of the injury inflammation. In the current interna-

tional literature, there is a lack of clinical case reports on successful diagnosis of prosthetic valve endocarditis using the methods of radionuclide imaging. The earliest work was performed by Purnell et al. and published in 1990 (8). In this work, ^{111}In -labelled leukocytes were used for indication; scintigraphy data were compared with data of a pathomorphology study of the surgical material. Somewhat later, Thomson et al. (9), Yavari et al. (10) and other authors studied the capabilities of scintigraphy with gallium citrate. Despite the fact that the authors received positive results comparable with histology data independently from each other, they note that radiopharmaceutical approaches have disadvantages such as several peaks and long periods between the times of infusion and the first study (at least 24 hours). It is worth mentioning that the present clinical studies were performed in patients with suspected bacterial endocarditis and with controversial results of clinical, laboratory, and instrumental data.

In clinical practice, $^{99\text{m}}\text{Tc}$ -based radiopharmaceuticals are the most preferable because they have optimal radiation characteristics. Considering this, technetium complex-based radiopharmaceuticals, such as autologous HMPAO-labeled leukocytes, have advantages. The method of labelled leukocytes is widely used for detection of the inflammatory foci of any localization, except pathology of the spleen and liver. According to data of various authors, this method demonstrates high rates of sensitivity and specificity in IE diagnosis (11). Moreover, there are data suggesting the presence of a positive correlation between the activity of the disease and the intensity of $^{99\text{m}}\text{Tc}$ -labelled leukocyte accumulation. According to the data of Sazonova (12), $^{99\text{m}}\text{Tc}$ -HMPAO-labelled leukocyte scintigraphy used in diagnosing IE demonstrates a sensitivity rate of 75%, a specificity rate of 90%, a diagnostic accuracy rate of 79%, a positive predictive value of 94%, and a negative predictive value of 60%.

Due to the rapid development of radiological equipment, hybrid devices with the ability to overlay images of different modalities (PET-CT, SPECT-CT, etc.) are gaining ground. These technologies enable localization of the pathologic accumulation with the radiopharmaceutical, not only in the myocardium and surrounding tissues, but also in any area of interest (13, 14). Overlaying the gamma scintigraphic images with X-ray CT results is the most affordable approach at the present time (15). Unfortunately, evidence regarding the SPECT-CT system-based topical diagnosis of cardiac inflammatory processes is limited by a few reports. In particular, the study of Erba et al. (16, 17) showed a 94% sensitivity of $^{99\text{m}}\text{Tc}$ -HMPAO-labelled leukocyte SPECT-CT for diagnosis of IE and cardiac pacemaker infection. Kostkiewicz (18) compared the results of SPECT-CT with data of an ultrasonic study and received positive

results. Researchers believe that administration of this method contributes to a reduction in the number of false results and recommend its use only in the cases when other laboratory diagnostic test results are controversial, similar to the clinical case presented in this study. Additionally, this method is more specific in elucidating the infection foci compared with $^{18\text{F}}$ -FDG PET-CT (19, 20). The $^{18\text{F}}$ -FDG PET-CT method is based on the accumulation of an ultrashort half-life of $^{18\text{F}}$ -FDG in glycolitically active cells such as monocytes and macrophages. Taking into account these specifics, special protocols and adherence of the patient to a low-carbohydrate diet are required for diagnosis. On the contrary, the HMPAO-labeled leukocyte SPECT method is the most specific due to the mechanism of natural cell migration to the inflammation focus.

In conclusion, use of $^{99\text{m}}\text{Tc}$ -HMPAO-SPECT/CT in this case contributed to an earlier and more precise IE diagnosis and allowed avoidance of many errors associated with patient treatment and the development of complications.

Acknowledgments

This study was supported by a grant from the Russian science foundation (No.14-15-00178).

Footnotes

Authors' Contribution: Julia Nikolaevna Ilyushenkova developed the original idea and the protocol, abstracted and analyzed data, and wrote the manuscript. Svetlana Ivanovna Sazonova was responsible for the study concept and design, Konstantin Valer'evich Zavadovsky and Yuri Borisovich Lishmanov performed critical revision of the manuscript for important intellectual content.

Financial Disclosure: None declared.

Funding/Support: This study was supported by a grant from the Russian science foundation (No. 14-15-00178).

References

- Prendergast BD, Tornos P. Surgery for infective endocarditis: who and when?. *Circulation*. 2010;**121**(9):1141-52. doi: [10.1161/CIRCULATION-AHA.108.773598](https://doi.org/10.1161/CIRCULATION-AHA.108.773598). [PubMed: [20212293](https://pubmed.ncbi.nlm.nih.gov/20212293/)].
- Westphal N, Plicht B, Naber C. Infective endocarditis—prophylaxis, diagnostic criteria, and treatment. *Dtsch Arztebl Int*. 2009;**106**(28-29):481-9. doi: [10.3238/arztebl.2009.0481](https://doi.org/10.3238/arztebl.2009.0481). [PubMed: [19730718](https://pubmed.ncbi.nlm.nih.gov/19730718/)] quiz 490.
- Roca M, de Vries E, Jamar F, Israel O, Signore A. Guidelines for the labelling of leucocytes with $^{111\text{In}}$ -oxine. *Eur J Nucl Med Mol*. 2010;**37**(4):835-41.
- Yamamoto T, Yodogawa K, Wakita S, Ogano M, Tokita M, Miyagi Y, et al. Recurrent prosthetic valve endocarditis caused by *Staphylococcus aureus* colonizing skin lesions in severe atopic dermatitis. *Inter Med*. 2007;**46**(9):571-3.

5. Iung B, Erba PA, Petrosillo N, Lazzeri E. Common diagnostic flowcharts in infective endocarditis. *Q J Nucl Med Mol Imaging*. 2014;**58**(1):55-65. [PubMed: 24231795].
6. Li JS, Sexton DJ, Mick N, Nettles R, Fowler VJ, Ryan T, et al. Proposed modifications to the Duke criteria for the diagnosis of infective endocarditis. *Clin Infect Dis*. 2000;**30**(4):633-8. doi: 10.1086/313753. [PubMed: 10770721].
7. Thuny F, Grisoli D, Collart F, Habib G, Raoult D. Management of infective endocarditis: challenges and perspectives. *Lancet*. 2012;**379**(9819):965-75. doi: 10.1016/S0140-6736(11)60755-1. [PubMed: 22317840].
8. Purnell GL, Walker CW, Allison JW, Dalrymple GV. Indium-111 leukocyte localization in infected prosthetic graft. *Clin Nucl Med*. 1990;**15**(8):585-6. [PubMed: 2390830].
9. Thomson LE, Goodman MP, Naqvi TZ, Feldman R, Buchbinder NA, Waxman A, et al. Aortic root infection in a prosthetic valve demonstrated by gallium-67 citrate SPECT. *Clin Nucl Med*. 2005;**30**(4):265-8. [PubMed: 15764887].
10. Yavari A, Ayoub T, Livieratos L, Raman V, McWilliams ET. Diagnosis of prosthetic aortic valve endocarditis with gallium-67 citrate single-photon emission computed tomography/computed tomography hybrid imaging using software registration. *Circ Cardiovasc Imaging*. 2009;**2**(6):e41-3. doi: 10.1161/CIRCIMAGING.109.854661. [PubMed: 19920033].
11. Hyafil F, Rouzet F, Lepage L, Benali K, Raffoul R, Duval X, et al. Role of radiolabelled leucocyte scintigraphy in patients with a suspicion of prosthetic valve endocarditis and inconclusive echocardiography. *Eur Heart J Cardiovasc Imaging*. 2013;**14**(6):586-94. doi: 10.1093/ehjci/jet029. [PubMed: 23456094].
12. Sazonova SI, Proskokova I, Guseva AM, Konkovskaia Iu A, Garganeeva AA, Suslova TE, et al. [Radionuclide methods for diagnostics of non-rheumatic myocarditis and postmyocarditic cardiosclerosis]. *Klin Med (Mosk)*. 2011;**89**(2):32-5. [PubMed: 21574439].
13. Majmudar MD, Nahrendorf M. Cardiovascular molecular imaging: the road ahead. *J Nucl Med*. 2012;**53**(5):673-6. doi: 10.2967/jnumed.111.099838. [PubMed: 22492729].
14. Kramer CM, Sinusas AJ, Sosnovik DE, French BA, Bengel FM. Multimodality imaging of myocardial injury and remodeling. *J Nucl Med*. 2010;**51** Suppl 1:107S-21S. doi: 10.2967/jnumed.109.068221. [PubMed: 20395347].
15. Prior JO, Farhad H, Muller O. Multimodality Imaging in Ischemic Cardiomyopathy. *Curr Cardiovasc Imaging Rep*. 2014;**7**:9285. doi: 10.1007/s12410-014-9285-x. [PubMed: 25152806].
16. Erba PA, Sollini M, Conti U, Bandera F, Tascini C, De Tommasi SM, et al. Radiolabeled WBC scintigraphy in the diagnostic workup of patients with suspected device-related infections. *JACC Cardiovasc Imaging*. 2013;**6**(10):1075-86. doi: 10.1016/j.jcmg.2013.08.001. [PubMed: 24011775].
17. Erba PA, Conti U, Lazzeri E, Sollini M, Doria R, De Tommasi SM, et al. Added value of 99mTc-HMPAO-labeled leukocyte SPECT/CT in the characterization and management of patients with infectious endocarditis. *J Nucl Med*. 2012;**53**(8):1235-43. doi: 10.2967/jnumed.111.099424. [PubMed: 22787109].
18. Kostkiewicz M. 99mTc-HMPAO labeled leukocyte SPECT/CT in evaluation of infective endocarditis inflammatory processes. *Eur Heart J Cardiovasc Imaging*. 2015;iii-28.
19. Bruun NE, Habib G, Thuny F, Sogaard P. Cardiac imaging in infectious endocarditis. *Eur Heart J*. 2014;**35**(10):624-32. doi: 10.1093/eurheartj/ehu274. [PubMed: 23900698].
20. Tanis W, Scholtens A, Habets J, van den Brink RB, van Herwerden LA, Chamuleau SA, et al. Positron emission tomography/computed tomography for diagnosis of prosthetic valve endocarditis: increased valvular 18F-fluorodeoxyglucose uptake as a novel major criterion. *J Am Coll Cardiol*. 2014;**63**(2):186-7. doi: 10.1016/j.jacc.2013.06.069. [PubMed: 24140668].