

Original Article

# Effect of *Syzygium aromaticum* (clove) extract on seminiferous tubules and oxidative stress after testicular torsion in adult rats

Maryam Moghimian, Seyd-Hosein Abtahi-Evari, Majid Shokoohi, Mostafa Amiri, Malihe Soltani\*

Department of Basic Sciences, School of Medicine, Gonabad University of Medical Sciences, Gonabad, Islamic Republic of Iran

## Abstract

**Introduction:** The aim was to investigate the protective effect of the *Syzygium aromaticum* extract on damaged tissues and the oxidative stress after testicular torsion.

**Methods:** Rats were randomly divided into a control group subjected to a sham procedure and three treatment groups comprising testicular torsion followed by detorsion (TD), testicular torsion detorsion followed by the treatment with an extract of *Syzygium aromaticum* (TDSA) and treatment done by extract of *Syzygium aromaticum* alone. Testicular torsion was induced by 720 degrees of counterclockwise rotation of the left testis for 4h. After the duration of the induction of the torsion, detorsion was done. The animals were given daily oral administrations of just *Syzygium aromaticum* (4 mg/kg) for seven days. The measurement of the oxidative stress and testosterone levels, as well as assessments of histomorphometry were conducted seven days after detorsion.

**Results:** The Johnsen score, along with the thickness of the epithelium and diameter of the seminiferous tubules, significantly increased in the testicular torsion group after receiving treatment with the extract of *Syzygium aromaticum* as compared to TD group. The levels of testosterone and glutathione peroxidase activity also increased significantly in the TDSA compared to TD group. The MDA levels decreased in TDSA compared to TD group.

**Conclusion:** The findings of the current study suggested that *Syzygium aromaticum* might have provided a protective effect against testicular torsion detorsion injury.

## Keywords:

*Syzygium aromaticum*;  
Clove;  
Oxidative stress;  
Testicular torsion

**Received:** 23 Jan 2017

**Accepted:** 31 Aug 2017

## \*Correspondence to:

M. Soltani

**Tel:** +98-9151097612

**Fax:** +98-5157223814

## Email:

m.soltani@gmu.ac.ir

## Introduction

Scrotal pain is a common complaint and testicular torsion accounts for 26% of these cases (Sung et al., 2012; Turgut et al., 2008). This complaint must be differentiated from other complaints of testicular pain because a delay in diagnosis and management can

lead to testicular damage and impaired fertility (Sung et al., 2012; Turgut et al., 2008). The prevalence of testicular torsion is one per 4000 males under 25 years of age (Blaivas et al., 2000; Mirhoseini et al., 2017). Testicular torsion occurs when the spermatic cord twists around the testicles, cuts off the blood supply and leads to tissue hypoxia (Pentya et al.,

2001). Two important predictors of testicular damage depend on the degree and duration of torsion (Barada et al., 1989; Sessions et al., 2003). The major pathophysiology in testicular torsion is the damage caused by ischemia/reperfusion which is followed by the production of reactive oxygen species (ROS). The increased production of the ROS results in damage to the DNA, endothelial destruction and testicular germ cell apoptosis (Karaguzel et al., 2014). The level of peroxidative damage observed in testicular tissue increases following the detorsion, indicating a biochemical basis for reperfusion injury (Aitken and Roman, 2008; Kutikov et al., 2008). Treatment of testicular torsion is through surgery and the testes can be saved, if detorsion occurs immediately (Abbasoğlu et al., 2012; Heindel et al., 1990). Delay in diagnosis and treatment leads to testicular damage and prevents orchiectomy (Cuervo et al., 2007). Studies have shown that the tissue injury and oxidative stress induced by testicular torsion/detorsion can be alleviated by pretreatment with exogenous antioxidants (Aitken and Roman, 2008). In our previous study, we showed that the histological parameters and testosterone levels improved with the administration of Vitamin C within 5h of the torsion (Moghimian et al., 2017). *Syzygium aromaticum*, commonly known as clove from the Asiatic region (Cortés-Rojas et al., 2014), is known to be an effective and beneficial herb with antioxidant antimicrobial, antifungal and antiviral properties (Mishra and Singh, 2008). Concentrations of up to 18% of essential oils can be found in the clove flower buds and roughly 89% of the clove's essential oil is eugenol (Cortés-Rojas et al., 2014). Several studies have shown the antioxidant activity of eugenol via *in vitro* methods and discussed the structure–activity relationship (Gülçin, 2011). Also, the essential oils of *Syzygium aromaticum* can preserve the functionality of the brain, heart, kidney and liver against induced toxicity or oxidative stresses (El-Hadary and Ramadan Hassanien, 2016; Liu et al., 2015; Madlala et al., 2012; Mapanga et al., 2009). It was shown that the safety effect of this essential oil consists of antidepressants like hypoglycemic, anti-hyperlipidemic and antioxidant effects (Atale et al., 2013; Ngubane et al., 2011; Somova et al., 2003). Several other studies have shown that the clove bud not only can be used to treat sexual disorders in males, but it also affects the functional physiology of

the male reproductive system (Choi et al., 2014; Mishra and Singh, 2013), such as causing an increase in the testosterone level (Mishra and Singh, 2008), motility of sperms and the secretory activities of the epididymis and seminal vesicle in lower doses (Mishra and Singh, 2013). The present study examined the effect of *Syzygium aromaticum* on seminiferous tubules, oxidative stress and hormone level caused by testicular torsion in adult rats.

## Materials and methods

This experimental study was performed on 28 adult male Wistar rats weighing 250-300 g. All rats were housed under a 12/12-hour light/dark cycle. The room temperature was maintained at 23±2 °C and humidity at 60-70%. The rats in all groups had free access to food and water. The ethical considerations were based on the guidelines for laboratory animals from the Research and Technology Deputy of Gonabad University of Medical Sciences.

### Experimental groups:

Group 1: sham operated control group without the application of the torsion (n=7); Group 2: testicular torsion for 4 hours followed by detorsion (TD) group (n=7); Group 3: only treatment by daily oral *Syzygium aromaticum* (4 mg/kg) for 7 days without the application of the torsion (SA) group (n=7) and Group 4: testicular torsion (4h) detorsion with treatment by daily oral *Syzygium aromaticum* (4 mg/kg) for 7 days (TDSA) group (n=7).

### Surgical procedure

The rats were anesthetized with ketamine (50 mg/kg) and xylazine (10 mg/kg). The left testis was exposed through a longitudinal scrotal incision and dissected. Torsion was created by 720° counterclockwise rotation of the left testis. Then the testis was carefully returned to the scrotum and pexed in position using three 6/0 silk sutures to approximate the tunica albuginea of the lower pole and the two lateral poles of the testis to the dartos. The scrotum was closed in a single plane with 5/0 silk sutures. In the TD group, testicular torsion was maintained for 4 hours followed by detorsion. Then, the testis was replaced into the scrotum and fixed with 6/0 silk suture. The incision was closed in a single plane with 5/0 silk sutures. In SA and TDSA groups, rats were given daily oral

administrations *Syzygium aromaticum* (4 mg/kg) for 7 days after detorsion. The rats were anesthetized using ketamine-xylazine post-treatment and one ml of blood was drawn from vena cava inferior vein to measure the levels of testosterone and antioxidant enzymes. Blood samples were kept at room temperature and then centrifuged at 3000 rpm for 10 minutes. Once the serum was removed from the blood cells, serum samples were kept at  $-70^{\circ}\text{C}$  until testing. The rats underwent orchietomy 7 days post procedure to examine the left testicular tissue (Guan et al., 2009; Köseoğlu et al., 2009; Moghimian et al., 2016).

#### **Tissue fixation and preparation of specimens**

After the orchietomy, the testicles were placed in Bouin solution for 48 hours. Once the tissue was fixed, tissue passage was performed using incremental increases in ethanol, xylene and liquid paraffin. The testicles were molded in paraffin and slides of tissue  $5\mu\text{m}$  thick were prepared from each specimen, stained with hematoxylin eosinophil and studied under an optical microscope at 400x magnification.

#### **Histological evaluation and maturation of seminiferous tubules**

The Johnsen score was used to evaluate spermatogenesis in the seminiferous tubules. To do so, 50 seminiferous tubules were examined in each cross-section and a score of 1-10 was assigned to each cross-section according to the following criteria (Johnsen, 1970): 10: complete spermatogenesis and perfect tubules; 9: many spermatozoa present but disorganized spermatogenesis; 8: only a few spermatozoa present; 7: no spermatozoa but many spermatids present; 6: only a few spermatids present; 5: no spermatozoa or spermatids present but many spermatocytes present; 4: only a few spermatocytes present; 3: only spermatogonia present; 2: no germ cells present and 1: neither germ cells nor Sertoli cells present.

#### **Morphometry of seminiferous tubules**

The linear eyepiece grids on the microscope were used to characterize the morphometry of the seminiferous tubules. In each rat, 20 seminiferous tubules were randomly selected from those showing round or nearly round cross-sections and studied.

Tubules that were oval or oblique in cross-section were not studied. The diameter of the seminiferous tubules, from the basement membrane on one side of the tubule to that on the other side of the tubule, was calculated at 400x magnification. The two perpendicular diameters were first calculated and the mean diameter of each tubule was then determined. The height of the germinal epithelium was calculated in micrometers (Moghimian et al., 2016).

#### **Evaluation of biochemical parameters**

##### **Measurement of malondialdehyde (MDA) levels**

MDA was measured by placing  $0.20\text{ cm}^3$  of plasma into a test tube containing  $3.0\text{ cm}^3$  of glacial acetic acid, to which  $3.0\text{ cm}^3$  of 1% thiobarbituric acid in 2% NaOH was added. The test tube containing the mixture was placed in boiling water for 15 minutes. Absorbance of the pink-colored product was read at 532 nm after cooling. The calibration curve was constructed using malondialdehyde tetrabutyl ammonium salt obtained from Sigma (USA) (Gwarzo et al., 2014).

##### **Measurement of superoxide dismutase (SOD) and glutathione peroxidase (GPX) activity**

SOD and GPX activity in serum were assayed in accordance with the protocols of the kits used (Randox, UK).

##### **Measurement of testosterone level**

The serum hormone levels were determined using a testosterone enzyme-linked immunosorbent assay kit (Demeditec Diagnostices, Germany). Absorbance was measured at 405 nm for testosterone.

##### **Statistical analysis**

Statistical analysis was carried out in SPSS 20 (IBM, USA). The Kolmogorov-Smirnov test was used to determine whether or not the data were normally distributed. All data were presented as mean $\pm$ SD. One-way ANOVA followed by Tukey's post-hoc test was performed to compare the histopathological parameters and oxidative stress values. Statistical significance levels were determined at  $P<0.05$ .

## **Results**

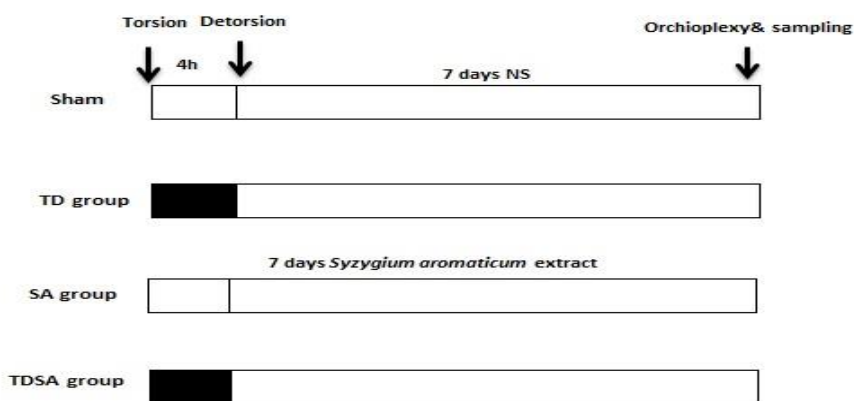
#### **Testicular histological parameters**

The histological parameter included mean Johnsen

**Table 1:** A comparison of the testicular modified Johnsen score, seminiferous tubule diameter and epithelium height in sham, TD, SA and TDSA groups.

group	Modified Johnsen Score	STD	EH
TD	5.88 (.000)*	170.03 (.001) *	39.76 (.009) *
SA	9.47 (.031)	229.02 (.011 )	69.16 (.010)
TDSA	7.03 (.011) #	191.01 (.022 ) #	58.32 (.000 ) #
sham	9.62	264.53	71.01

TD=Testicular torsion/Detorsion, SA=treatment with *Syzygium Aromaticum*, TDSA=testicular torsion /detorsion following by treatment with *Syzygium Aromaticum*. STD=seminiferous tubule diameter, EH=epithelium height. Values are mean±SD. P<0.05 is significant. \*P<0.05 vs sham, #P<0.05 vs TD.



**Fig.1.** Illustration of the experimental protocols. Testes were subjected to 4 hours of ischemia followed by 7 days reperfusion in sham, TD, SA and TDSA groups. TD=testicular torsion/detorsion, SA=treatment with *Syzygium aromaticum*, TDSA=testicular torsion /detorsion following by treatment with *Syzygium aromaticum*, NS=normal saline

score (MJS), diameter of the seminiferous tubules (STD) and height (thickness) of the seminiferous tubule epithelium (HE) in the study groups which were compared. In the TD group, it was observed that there was a significant decrease in MJS, STD and HE as compared with the sham group (all  $P \leq 0.05$ ). In the TDSA group, treatment by *Syzygium aromaticum* significantly increased the MJS, STD and HE when compared with the TD group; however, these parameters were not significantly different in the SA group when compared with the TD group (Table 1; Fig. 2).

**Biochemical parameters**

**Testosterone**

The level of testosterone significantly decreased in TD group when compared with the sham group ( $P \leq 0.05$ ). Treatment by *Syzygium aromaticum* in the TDSA group increased significantly the testosterone level compared with testicular torsion detorsion, ( $P \leq 0.05$ ). SA group showed no significant difference

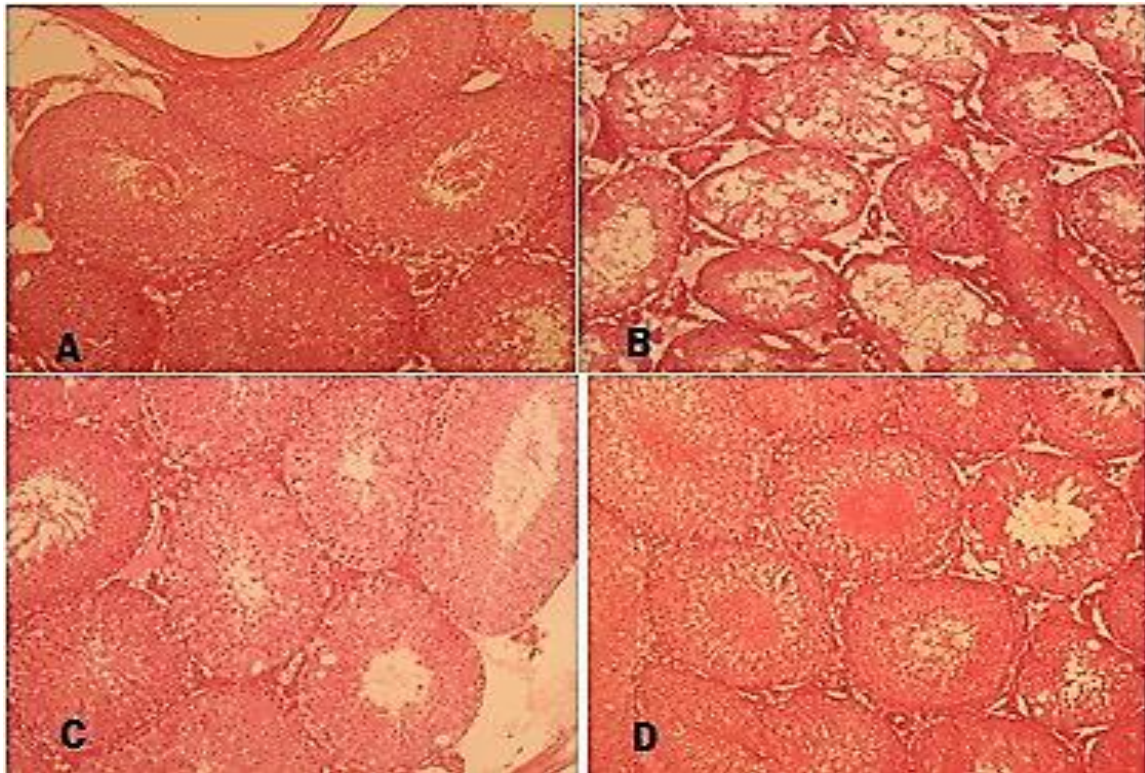
in testosterone level compared with other groups (Fig. 3).

**Antioxidant enzymes**

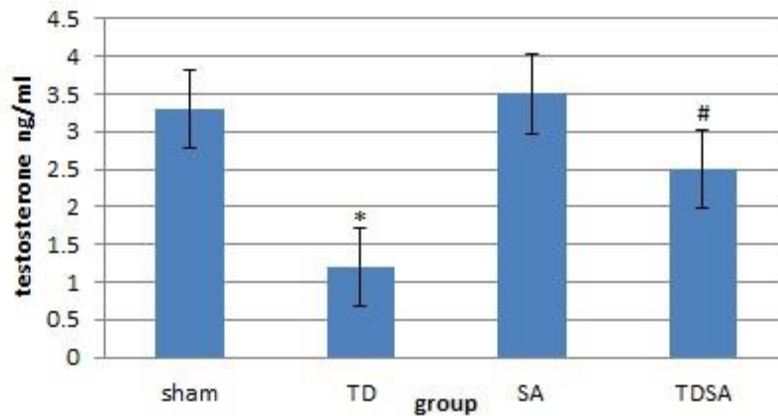
The level of GPX and SOD significantly decreased in TD group as compared with the sham group ( $P \leq 0.05$ ). The level of GPX significantly increased when TDSA group compared with TD group (Fig. 4). The level of SOD increased, although not significantly, in TDSA group compared with TD group (Fig. 5). The level of MDA increased significantly in the TD group when compared with the sham group, and treatment by *Syzygium aromaticum* could significantly decrease the level of MDA in TDSA group (Fig. 6).

**Discussion**

The current study entails the antioxidant potential of the *Syzygium aromaticum* against ischemic reperfusion which induced testicular damage in rats a



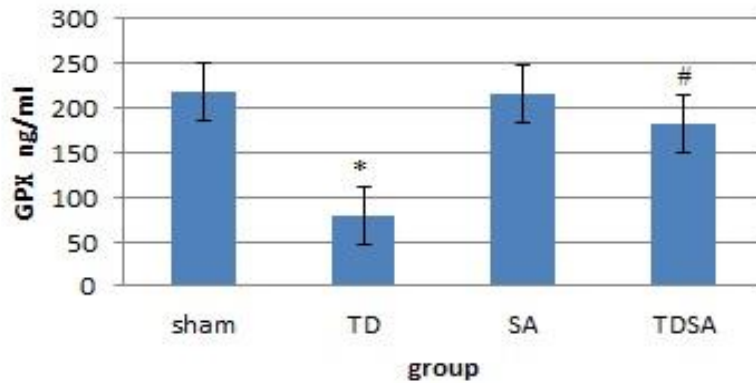
**Fig.2.** Histological findings in sham, TD, SA and TDSA groups (400x). A: sham, B: testicular torsion (4h) followed by detorsion, C: treatment with *Syzygium aromaticum* and D: testicular torsion (4h) detorsion followed by treatment with *Syzygium aromaticum*.



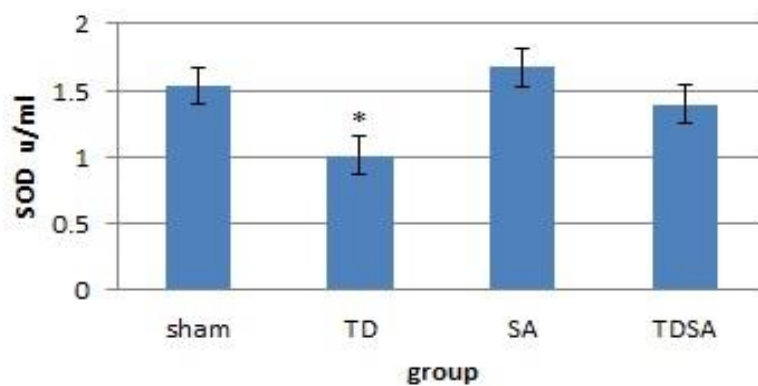
**Fig.3.** A comparison of the testosterone in sham, TD, SA and TDSA groups. TD=testicular torsion/detorsion, SA=treatment with *Syzygium Aromaticum*, TDSA=testicular torsion /detorsion followed by treatment with *Syzygium Aromaticum*. Values are mean $\pm$ SD.  $P<0.05$  are significant. \* $P<0.05$  vs sham, # $P<0.05$  vs TD.

finding which has not been reported thus far. We showed that treatment with *Syzygium aromaticum* could improve the histological and oxidative stress parameters after 4h of ischemia. One type of pathophysiological damage in testicular torsion is an increase in oxidative stress following the ischemia reperfusion (Moghimian et al., 2016). Elshaari et al. (2011) found that 30 minutes of torsion followed by detorsion decreased the level of glutathione and increased the MDA and G6PDH levels 24h post the

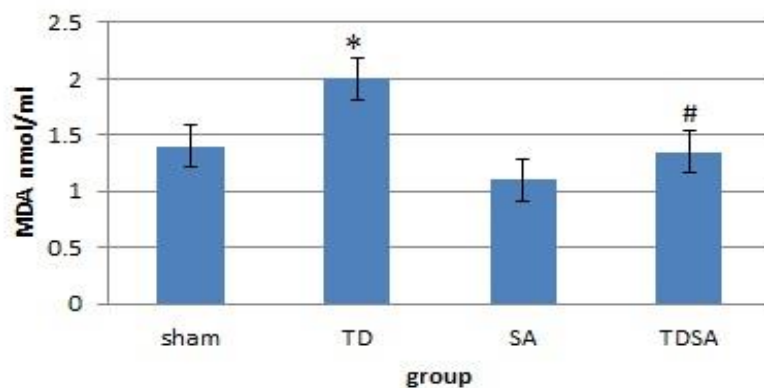
procedure, indicating that the testicular antioxidant defenses against the oxidative stress occurred after the torsion and detorsion. Ikebuaso et al. (2012) explained that testicular torsion and detorsion significantly changed the release of the FSH, LH and testosterone hormones. Our previous study also showed that testicular torsion followed by the detorsion after 24h resulted in a decrease in the level of antioxidant enzymes and testosterone which was directly related to the increase in the duration of



**Fig.4.** A comparison of the GPX in sham, TD, SA and TDSA groups. TD=testicular torsion/detorsion, SA=treatment with *Syzygium Aromaticum*, TDSA=testicular torsion /detorsion following by treatment with *Syzygium Aromaticum*. Values are mean±SD.  $P<0.05$  are significant. \* $P<0.05$  vs sham, # $P<0.05$  vs TD.



**Fig.5.** A comparison of the SOD in sham TD, SA, and TDSA groups. TD=Testicular torsion/detorsion, SA=treatment with *Syzygium Aromaticum*, TDSA=testicular torsion /detorsion following by treatment with *Syzygium Aromaticum*. Values are mean±SD.  $P<0.05$  are significant. \* $P<0.05$  vs sham.



**Fig.6.** A comparison of the MDA in sham, TD, SA, and TDSA groups. TD=testicular torsion/detorsion, SA=treatment with *Syzygium Aromaticum*, TDSA=testicular torsion /detorsion followed by treatment with *Syzygium Aromaticum*. Values are mean±SD.  $P<0.05$  are significant. \* $P<0.05$  vs sham, # $P<0.05$  vs TD.

ischemia (Moghimian et al., 2016). Also, we showed previously that the histological parameters and testosterone level improved with the administration of Vitamin C as an antioxidant within 5h of the torsion (Moghimian et al., 2017). In this study, we used *Syzygium aromaticum* extract as an antioxidant

against the increased oxidative stress followed by testicular torsion-detorsion. The experimental and clinical evaluation of *Syzygium aromaticum* suggests that it has variable significant biological effects such as anti-diabetic (Chaturvedi et al., 2009), anti-inflammatory (Chaudhuri et al., 1990) and free radical

scavenging (Benherlal and Arumughan, 2007). Shukla et al. (2014) showed this plant can attenuate oxidative stress and apoptosis in myocardial damage in rats. Also, our results showed that *Syzygium aromaticum* extract reduced oxidative stress (SOD, GPX) and MDA levels after 4h of ischemia. Mishra and Singh (2008) observed that treatment with 15 mg/kg of *Syzygium aromaticum* extract orally administered led to an increase in the activities of the D5 3-beta-hydroxysteroid dehydrogenase (HSD), 17β-HSD and serum levels of testosterone. This is in line with our results which showed that *Syzygium aromaticum* extract improved testosterone levels after 4h of ischemia. It was shown that *Syzygium aromaticum* exerts a positive influence on male fertility (Choi et al., 2014) and lower dose (4 mg) of the *Syzygium aromaticum* extract by daily oral administration helped to retain the reproductive activities of testes (Choi et al., 2014). Mishra and Singh (2013) also showed that this extract can increase the motility of sperms and stimulate the secretory activities of the epididymis and seminal vesicle. Baghshahi et al. (2014) found that 75 µg/ml of clove bud extract could improve sperm quality after the cooling and freeze–thawing processes. Furthermore, in this study, we found that *Syzygium aromaticum* extract improved the Johnsen score, the height of the epithelium and the diameter of the tubules after 4h of ischemia.

## Conclusion

The findings of the current study suggested that *Syzygium aromaticum* might have provided a protective effect against torsion detorsion-induced oxidative stress injury.

## Acknowledgments

This study was supported by the grant of Gonabad University of Medical Science.

## Conflict of interest

The authors have no financial or other relationship that could lead to a conflict of interest.

## References

- Abbasoğlu L, Kalaz EB, Soluk-Tekkeşin M, Olgaç V, Dođru-Abbasođlu S, Uysal M. Beneficial effects of taurine and carnosine in experimental ischemia/reperfusion injury in testis. *Pediatr Surg Int* 2012; 28: 1125-1131.
- Aitken RJ, Roman SD. Antioxidant systems and oxidative stress in the testes. *Oxid Med Cell Longev* 2008; 1: 15-24.
- Atale N, Chakraborty M, Mohanty S, Bhattacharya S, Nigam D, Sharma M, et al. Cardioprotective role of syzygium cumini against glucose-induced oxidative stress in h9c2 cardiac myocytes. *Cardiovasc Toxicol* 2013; 13: 278-289.
- Baghshahi H, Riasi A, Mahdavi AH, Shirazi A. Antioxidant effects of clove bud (*syzygium aromaticum*) extract used with different extenders on ram spermatozoa during cryopreservation. *Cryobiology* 2014; 69: 482-487.
- Barada JH, Weingarten JL, Cromie WJ. Testicular salvage and age-related delay in the presentation of testicular torsion. *J Urol* 1989; 142: 746-748.
- Benherlal PS, Arumughan C. Chemical composition and in vitro antioxidant studies on syzygium cumini fruit. *J Sci Food Agric* 2007; 87: 2560-2569.
- Blaivas M, Batts M, Lambert M. Ultrasonographic diagnosis of testicular torsion by emergency physicians. *Am J Emerg Med* 2000; 18: 198-200.
- Chaturvedi A, Bhawani G, Agarwal PK, Goel S, Singh A, Goel R. Antidiabetic and antiulcer effects of extract of eugenia jambolana seed in mild diabetic rats: study on gastric mucosal offensive acid-pepsin secretion. *Indian J Physiol Pharmacol* 2009; 53: 137-46.
- Chaudhuri A, Pal S, Gomes A, Bhattacharya S. Anti-inflammatory and related actions of syzygium cuminii seed extract. *Phytother Res* 1990; 4: 5-10.
- Choi D, Roh HS, Kang DW, Lee JS. The potential regressive role of syzygium aromaticum on the reproduction of male golden hamsters. *Dev Reprod* 2014; 18: 57-64.
- Cortés-Rojas DF, de Souza CR, Oliveira WP. Clove (*syzygium aromaticum*): a precious spice. *Asian Pac J Trop Biomed* 2014; 4: 90-96.
- Cuervo JL, Grillo A, Vecchiarelli C, Osio C, Prudent L. Perinatal testicular torsion: a unique strategy. *J Pediatr Surg* 2007; 42: 699-703.
- El-Hadary AE, Ramadan Hassanien MF. Hepatoprotective effect of cold-pressed syzygium aromaticum oil against carbon tetrachloride (ccl4)-induced hepatotoxicity in rats. *Pharm Biol* 2016; 54: 1364-1372.
- Elshaari FA, Elfagih RI, Sheriff DS, Barassi IF. Oxidative and antioxidative defense system in testicular torsion/detorsion. *Indian J Urol* 2011; 27: 479-84.
- Guan Y, Zheng XM, Yang ZW, Li SW. (protective effects of l-carnitine upon testicular ischemia-reperfusion damage in rats). *Zhonghua yi xue za zhi* 2009; 89: 1858-1861.
- Gülçin İ. Antioxidant activity of eugenol: a structure–activity relationship study. *J Med Food* 2011; 14: 975-985.
- Gwarzo MY, Ahmadu JH, Ahmad MB, Dikko AU. Serum glucose and malondialdehyde levels in alloxan induced diabetic rats supplemented with methanolic extract of *tacazzea apiculata*. *Int J Biomed Sci* 2014; 10: 236-42.
- Heindel RM, Pakyz RE, Reinking LN, Cosentino MJ. The

- effect of various degrees of unilateral spermatic cord torsion on fertility in the rat. *J Urol* 1990; 144: 366-369.
- Ikebuaso AD, Yama OE, Duru FI, Oyebadejo SA. Experimental testicular torsion in a rat model: effects of treatment with pausinyntalia macroceras on testis functions. *J Reprod Infertil* 2012; 13: 218-42.
- Johnsen SG. Testicular biopsy score count—a method for registration of spermatogenesis in human testes: normal values and results in 335 hypogonadal males. *Horm Res Paediatr* 1970; 1: 2-25.
- Karaguzel E, Kadihasanoglu M, Kutlu O. Mechanisms of testicular torsion and potential protective agents. *Nat Rev Urol* 2014; 11: 391-399.
- Köseoğlu B, Yılmaz E, Ceylan K, Uzun E, Bayram I, Hızlı F. The protective effect of erythropoietin infusion on testicular torsion/detorsion: An experimental study. *Int Urol Nephrol* 2009; 41: 85-91.
- Kutikov A, Casale P, White MA, Meyer WA, Chang A, Gosalbez R, et al. Testicular compartment syndrome: a new approach to conceptualizing and managing testicular torsion. *Urol* 2008; 72: 786-789.
- Liu BB, Luo L, Liu XL, Geng D, Li CF, Chen SM, et al. Essential oil of syzygium aromaticum reverses the deficits of stress-induced behaviors and hippocampal p-erk/p-creb/brain-derived neurotrophic factor expression. *Planta Med* 2015; 81: 185-192.
- Madlala HP, Masola B, Singh M, Musabayane CT. The effects of syzygium aromaticum-derived oleanolic acid on kidney function of male sprague–dawley rats and on kidney and liver cell lines. *Ren Fail* 2012; 34: 767-776.
- Mapanga RF, Tufts MA, Shode FO, Musabayane CT. Renal effects of plant-derived oleanolic acid in streptozotocin-induced diabetic rats. *Ren Fail* 2009; 31: 481-491.
- Mirhoseini M, Talebpour Amiri F, Karimpour Malekshah AA, Rezanejad Gatabi Z, Ghaffari E. Protective effects of melatonin on testis histology following acute torsion-detorsion in rats. *Int J Reprod BioMed (Yazd)* 2017; 15: 141-146.
- Mishra RK, Singh SK. Safety assessment of syzygium aromaticum flower bud (clove) extract with respect to testicular function in mice. *Food Chem Toxicol* 2008; 46: 3333-3338.
- Mishra RK, Singh SK. Reproductive effects of lipid soluble components of syzygium aromaticum flower bud in male mice. *J Ayurveda Integr Med* 2013; 4: 94-8.
- Moghimian M, Soltani M, Abtahi H, Adabi J, Jajarmy N. Protective effect of tunica albuginea incision with tunica vaginalis flap coverage on tissue damage and oxidative stress following testicular torsion: Role of duration of ischemia. *J Pediatr Urol* 2016; 12: 390.
- Moghimian M, Soltani M, Abtahi H, Shokoohi M. Effect of vitamin c on tissue damage and oxidative stress following tunica vaginalis flap coverage after testicular torsion. *J Pediatr Surg* 2017; S0022-3468: 30412-8.
- Ngubane PS, Masola B, Musabayane CT. The effects of syzygium aromaticum-derived oleanolic acid on glycogenic enzymes in streptozotocin-induced diabetic rats. *Ren Fail* 2011; 33: 434-439.
- Pentyala S, Lee J, Yalamanchili P, Vitkun S, Khan SA. Testicular torsion: a review. *J Low Genit Tract Dis* 2001; 5: 38-47.
- Sessions AE, Rabinowitz R, Hulbert WC, Goldstein MM, Mevorach RA. Testicular torsion: direction, degree, duration and disinformation. *J Urol* 2003; 169: 663-665.
- Shukla SK, Sharma SB, Singh UR, Ahmad S, Maheshwari A, Misro M, et al. Eugenia jambolana pretreatment prevents isoproterenol-induced myocardial damage in rats: evidence from biochemical, molecular, and histopathological studies. *J Med Food* 2014; 17: 244-253.
- Somova LO, Nadar A, Rammanan P, Shode FO. Cardiovascular, antihyperlipidemic and antioxidant effects of oleanolic and ursolic acids in experimental hypertension. *Phytomedicine* 2003; 10: 115-121.
- Sung EK, Setty BN, Castro-Aragon I. Sonography of the pediatric scrotum: emphasis on the ts-torsion, trauma, and tumors. *AJR Am J Roentgenol* 2012; 198: 996-1003.
- Turgut AT, Bhatt S, Dogra VS. Acute painful scrotum. *Ultrasound Clin* 2008; 3: 93-107.