


Original Article

Ameliorative effect of berberine on functional disorders and histological damages of pancreas in renal ischemia/reperfusion

Firouzeh Gholampour* , Sareh Mansouri

Department of Biology, School of Sciences, Shiraz University, Shiraz, Iran

Abstract

Introduction: Renal ischemia/reperfusion (RIR) is considered as one of the most prevalent reasons of acute renal failure. As renal failure is progressed, renal gluconeogenesis and insulin clearance are decreased. Berberine is the most important alkaloid of *Berberis vulgaris*. It has anti-diabetic, anti-inflammatory and anti-microbial properties. The goal of this study was to assign the effect of RIR on the pancreas and to define the effect of berberine on the pancreatic damages induced by RIR.

Methods: Male rats were allocated into four groups (n=7): sham (no intervention), Ber (berberine, 15mg/kg/day), I/R (subjected to 45min bilateral renal artery occlusion), Ber+I/R (berberine, 15mg/kg/day). After 24h, blood samples were collected for biochemical analysis and eventually pancreas tissue samples were kept for subsequent histological examination.

Results: The ischemic challenge of kidneys resulted in pancreatic vascular congestion, which was associated with decreased plasma level of glucose as well as increased plasma insulin, creatinine and blood urea nitrogen levels at the termination of reperfusion period. In Ber+I/R group, pancreatic vascular congestion and decreased plasma level of insulin were improved concomitant to increase in plasma creatinine and urea nitrogen being smaller than those of the non-treated rats.

Conclusion: RIR injury has some roles in the development of tissue damages and probably functional disorders of the pancreas in rats. Furthermore, berberine has an ameliorative effect against organ injury induced by RIR in rat.

Keywords:

Renal ischemia/reperfusion;
Berberine;
Pancreas

Received: 5 Jan 2019

Accepted: 16 May 2019

*Correspondence to:

F. Gholampour

Tel/Fax: +98-7132280916

Email:

gholampour@shirazu.ac.ir

Introduction

Animal studies have shown that renal ischemia/reperfusion (I/R) elicits tissue damage in a number of distant organs including liver (Gholampour and Sadidi, 2018), brain (Liu et al., 2008) and lung (Hassoun et al., 2007). However, remote effects of

renal I/R injury (IRI) on the pancreas remain unclear. The mortality rate caused by acute kidney injury (AKI) induced by I/R grows to several times if it is accompanied by remote organ injury (Abogresha et al., 2016). Thus, the mechanism of damage development by AKI in remote organs should be understood more precisely and proper therapeutic strategies should be designed for it accordingly.

Many investigations have demonstrated that ischemic acute renal failure (ARF) is accompanied by a robust inflammatory response (Bonventre and Zuk, 2004). I/R causes synthesis of pro-inflammatory chemokines and cytokines in the kidney that connect the effects of acute ARF on distant organs (Lemay et al., 2000).

It has been established that the presence of preexisting renal dysfunction and the need for renal replacement therapy is one of the major risk factors for development of hypoglycemia in the intensive care unit (van den Berghe et al., 2001; Van den Berghe et al., 2006; Vriesendorp et al., 2006). Several studies in human and animals have pointed to the importance of the kidney in glucose homeostasis and as an effective participant to insulin resistance, which suggest that it is an active contributor in these metabolic disorders during acute diseases. The kidney has an important function in glucose homeostasis (Meyer et al., 1999). Since insulin regulates glucose homeostasis in the kidney, loss of kidney metabolic function could account for a component of insulin resistance. Besides, the kidney metabolizes insulin too. Thus, reduced renal function prolongs the half-life of insulin which contributes to hypoglycemic events (Meyer et al., 1999).

Oxidative stress and inflammation are proved to be critical for the pathogenesis of renal I/R (Friedewald and Rabb, 2004; Dennis and Witting, 2017). Berberine is a natural compound isolated from plants such as *Berberis vulgaris* (Mohammadzadeh et al., 2017) and with multiple pharmacological activities including antioxidant and anti-inflammatory properties (Li et al., 2014). In the pancreas, a recent study demonstrated impairment of pancreas function by renal I/R injury due to defect in antioxidants and increased lipid peroxidation in pancreatic tissue (Hussein et al., 2014). However, there is no published report, up to the best of our knowledge, regarding the ameliorative effect of berberine as an anti-oxidative and anti-inflammatory agent on pancreatic functional disorders and histological damages induced by renal I/R injury. Thus, the goal of this experiment was to determine the effects of renal IRI on the pancreatic function and to assess the effect of berberine on pancreatic damages induced by renal I/R injury.

Materials and methods

Experimental procedure

Wistar male rats (273.92±15.73g) from Razi institute (Shiraz, Iran) were kept in polyacrylic cages at an ambient temperature of 25±2°C, placed on a 12:12h light/dark cycle and fed with standard pellet diet and water *ad libitum*. The maintenance and care of experimental animals complied with National Institutes of Health guidelines for the humane use of laboratory animals and has been confirmed by the local ethics committee (902061). The rats were assigned into following groups (n=7 per group): sham group in which animals received distilled water for 7 days before surgery, I/R group in which the renal arteries were clamped for 45min after 7 days of distilled water treatment, Ber+I/R group in which the renal arteries were clamped for 45min after 7 days of berberine (Fluka) treatment [15mg/kg/day, intraperitoneally (Zhou and Mineshita, 2000)], Ber group (berberine, 15mg/kg/day during 7 days). In sham and Ber groups, the renal arteries were not occluded. The animals were anesthetized with ketamine (60mg/kg, ip) and xylazine (5mg/kg, ip) before I/R operation. At the termination of reperfusion period, blood samples was obtained from heart ventricles under anesthesia and the pancreas was immediately harvested and preserved.

Biochemical analysis

Plasma samples were evaluated for creatinine (Ziest Chemie Co, Iran), blood urea nitrogen (BUN) and glucose (Man Co, Iran) in milligram per deciliter using an autoanalyser (RA 1000; Technicon Instruments, NY, USA). Insulin concentration in plasma samples was measured with radioimmunoassay method.

Histopathological examinations

After fixation in buffered 10% formaldehyde and dehydration through a graded alcohol series, pancreatic samples were cleared in xylol. Then, paraffin- embedded pancreatic sections (5µm) were stained with hematoxylin and eosin. Light microscopy of each section was blindly done in at least 10 randomly selected non-overlapping fields. In each section, we examined the degree of the presence of congestion and cellular degenerative changes, as well as the diameters of both pancreatic lobular vein and islet cell of langerhans. The level of each pathological manifestation was graded according to the changes involved: none with 0, less than 20% with 1, 21–40% with 3, 61–80% with 4 and greater

than 80% with 5 (Sternberg, 2004). The sum of all numerical scores in each group was taken as the total histopathological score.

Statistical analysis

SPSS ver. 11.5 software (SPSS Software, Chicago, IL, USA) was applied for analysis and presentation of data (mean±SEM). Comparisons between groups were calculated by one-way ANOVA and Duncan's post hoc. The histopathological scores were statistically compared between groups by nonparametric Kruskal–Wallis multiple comparison test. Statistical significance was taken at $P<0.05$.

Results

As it can be seen from Figure 1, plasma levels of creatinine and BUN were statistically higher in I/R group (1.90 ± 0.22 and 144.57 ± 14.75 , respectively) compared to sham (0.57 ± 0.03 and 46.57 ± 9.02 , respectively) and Ber (0.60 ± 0.04 and 41.43 ± 9.42 , respectively) groups ($P<0.001$). Injection of berberine induced a significant reduction in plasma creatinine (Fig. 1a) and BUN (Fig. 1b) levels (0.98 ± 0.05 and 92.43 ± 16.41 , respectively) compared to I/R group ($P<0.001$).

In the I/R group, there was marked decrease in the

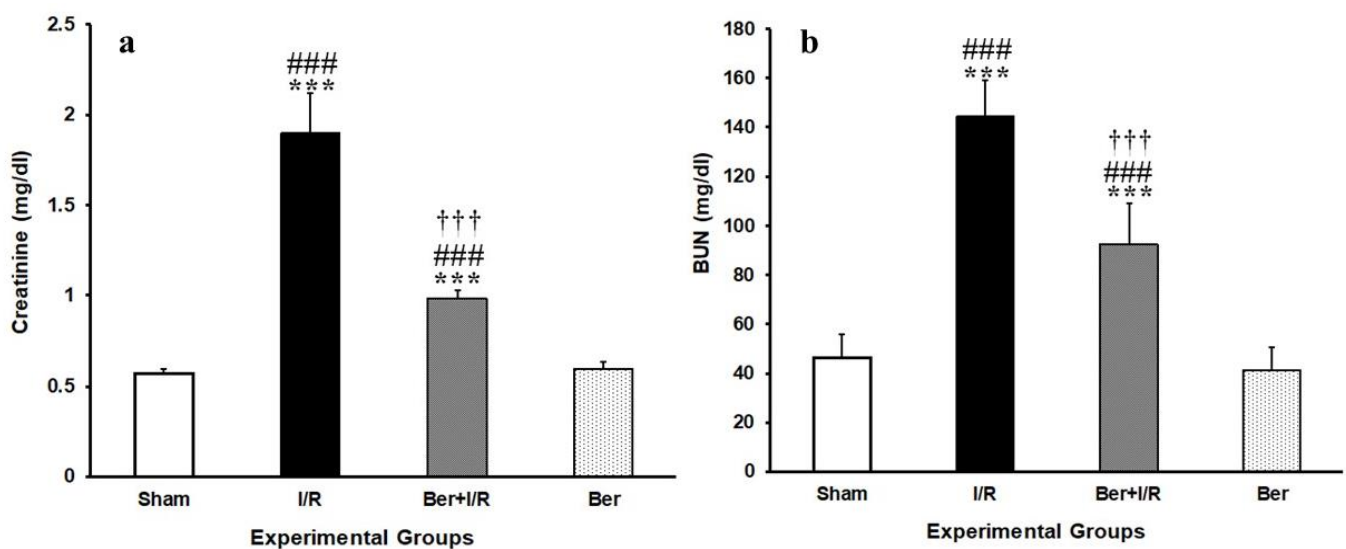


Fig.1. Effects of berberine on (a) plasma creatinine concentration and (b) plasma urea nitrogen concentration. *** $P<0.001$ vs sham group; ††† $P<0.001$ vs I/R group; ### $P<0.001$ vs Ber group.

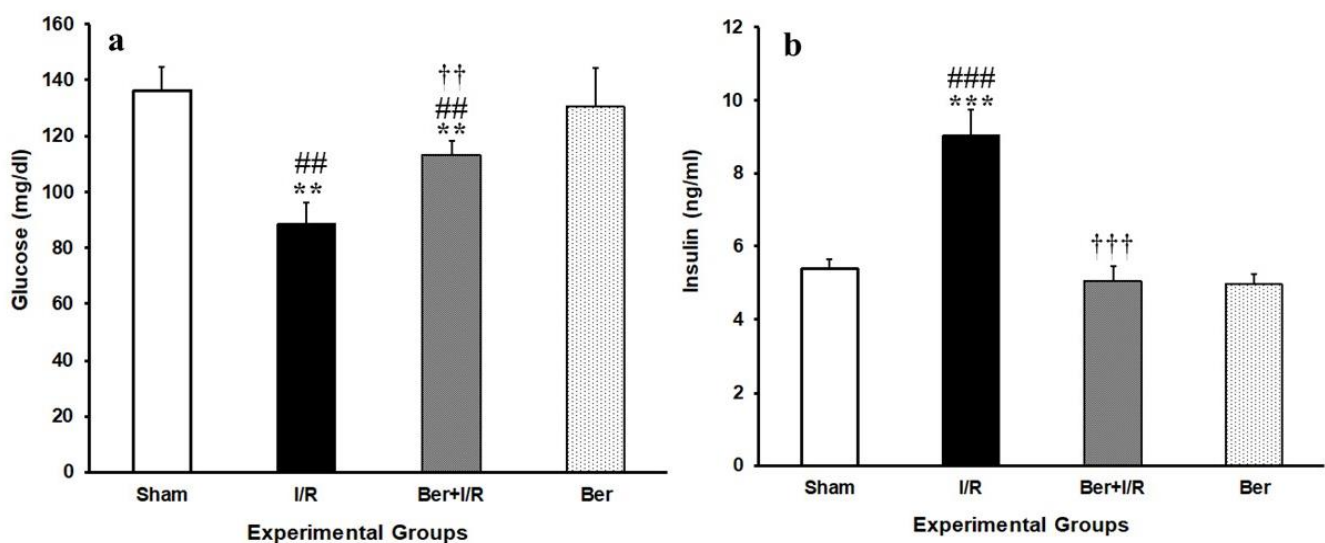


Fig.2. Effects of berberine on (a) plasma glucose concentration and (b) plasma insulin concentration. ** $P<0.01$, *** $P<0.001$ vs sham group; †† $P<0.01$, ††† $P<0.001$ vs I/R group; # $P<0.01$, ### $P<0.001$ vs Ber group.

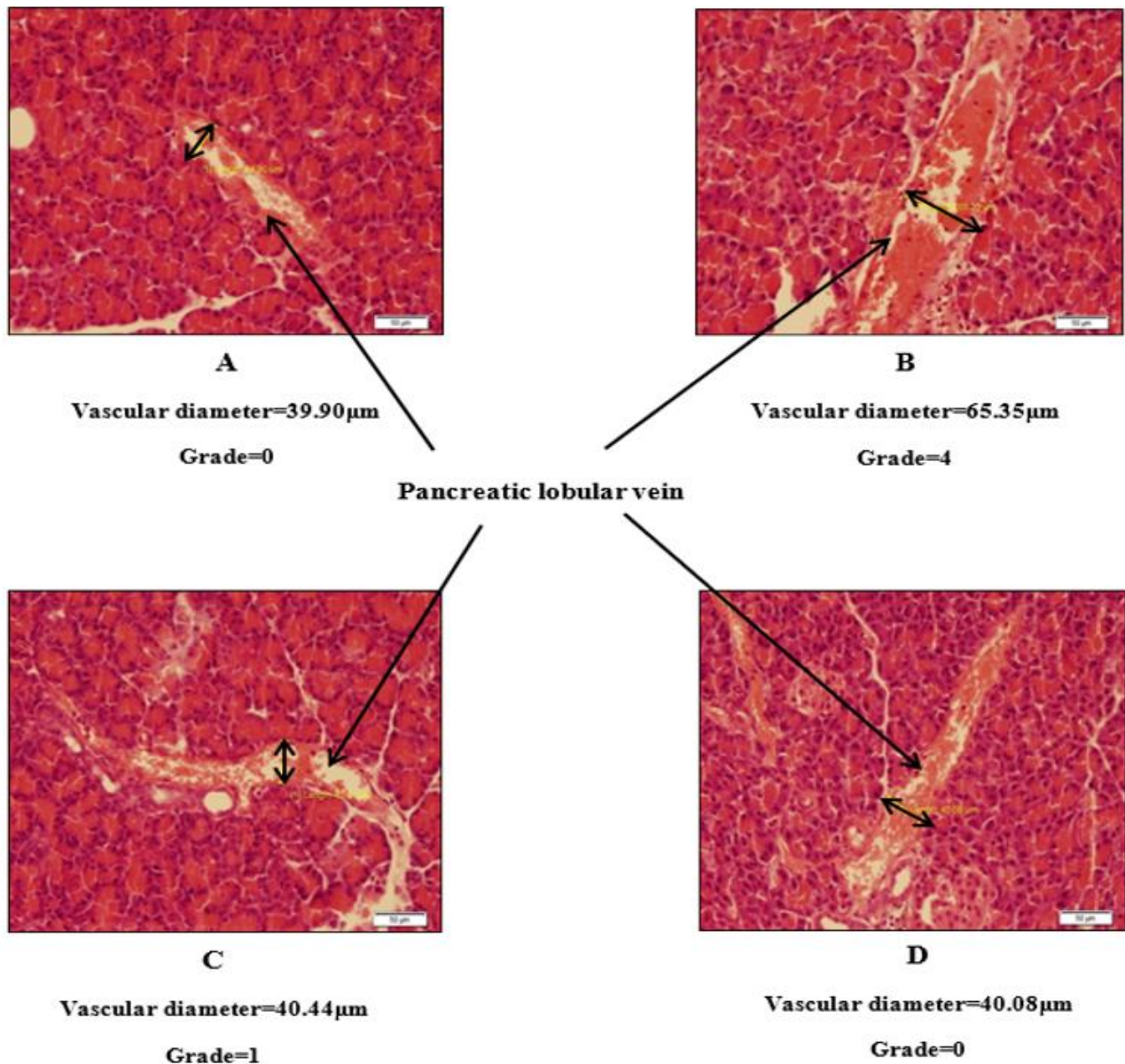


Fig.3. Light microphotographs representing pancreatic lobular vein diameter in Sham (A), I/R (B), Ber+I/R (C) and Ber (D) groups. Hematoxylin and eosin stained sections were examined for histological changes 24h after renal IRI with $\times 200$ magnification.

plasma level of glucose (88.57 ± 7.60) with respect to its level in sham and Ber (136.0 ± 8.60 and 130.71 ± 13.67 , respectively) groups ($P < 0.001$). Glucose level was increased in Ber+I/R group (113.28 ± 5.13) in comparison with I/R group ($P < 0.001$), while it was the same in sham and Ber groups (Fig. 2a). Also, plasma level of insulin (Fig. 2b) in I/R group (9.04 ± 0.69) was statistically higher compared to sham and Ber (5.37 ± 0.26 and 4.95 ± 0.29 , respectively) groups ($P < 0.01$). Administration of berberine led to a significant reduction in insulin level (5.04 ± 0.40) compared to I/R group ($P < 0.01$).

Histology

There were no abnormalities or histological changes in the pancreas of sham and Ber groups (Figs. 3A and D). In the I/R group (Fig. 3B), the most prominent lesions were increase of vascular pancreatic lobular vein diameter (grade 4) and vascular congestion (grade 5). In the Ber+I/R group less intense lesions (grade 1) were noticed in comparison with I/R group (Fig. 3C). Also, the diameter of islet cell of langerhans showed no difference between four experimental groups. The sum of histopathological grades, marking the changes described above is shown in Table 1.

Table 1: Total histopathological score in sham, I/R, I/R+Ber and sham+Ber groups (each n=7) at the end of 24 hour's reperfusion.

Experimental groups	Pancreas
sham	0.0 ± 0.00
I/R	4.85 ± 0.14 ^{***}
Ber + I/R	0.57 ± .20 ^{***†††}
Ber	0.0 ± 0.00

Values (sum of histopathological scores in each group) are expressed as mean±SEM. ^{***}*P*<0.001 as compared to the sham and Ber, ^{†††}*P*<0.001 as compared to the I/R.

Discussion

The current study showed that renal I/R led to significant reduction in plasma glucose concentration and elevation in plasma level of insulin, as well as pancreatic histological damages. The kidney has a great role in glucose homeostasis (Meyer et al., 1999). Approximately 25% of systemic glucose production is attributed to kidneys, whereas renal contribution to systemic glucose removal is 20% (Meyer et al., 1999). As insulin regulates glucose homeostasis in the kidney, renal failure accounts for a component of insulin resistance. In this study, ischemic ARF was revealed by elevated plasma levels of creatinine and BUN (Fig. 1). Besides, 45min ischemia/24h reperfusion resulted in elevated plasma insulin level (Fig. 2b). Our results agree with the findings of Hussein et al. (2014) in male rats; however, contrary to their results which showed no significant change in blood glucose, plasma glucose concentration of I/R group was decreased in the current study (Fig. 2a).

According to the findings of Brier et al. in 1987, an increase in plasma insulin concentration in renal failure may be due to a reduction in insulin uptake from both the tubular lumen and peritubular surface (Brier et al., 1987; Sampanis, 2008). Besides, it has been believed that during the early phase of renal failure, a decrease in renal insulin clearance is occurred due to reduced renal blood flow, which is aggravated as renal function declines. As clearance and metabolism of insulin are declined, the metabolic

effects of insulin would persist longer and the risk for hypoglycemia increases (Sampanis, 2008). In this regard, hypoglycemia has been ascribed to deficiency of precursors of gluconeogenesis, diminished renal gluconeogenesis, impaired glycogenolysis and impaired renal insulin degradation and clearance (Arem, 1989). The reduction in plasma glucose level is likely due to an increment in plasma levels of insulin. In line with our results, a reduction in plasma level of glucose and impaired renal glomerular filtration rate have been observed in an lipopolysaccharides model of sepsis which were associated with decreased expression of sodium/glucose cotransporter 2, sodium/glucose cotransporter 3 and glucose transporter 2 (Schmidt et al., 2007). Moreover, it has been suggested that uremia is associated with reduced hepatic and peripheral glucose uptake and a decrease in peripheral tissue glucose transporters (Jacobs et al., 1989; Friedman et al., 1991).

Berberine pretreatment could greatly reduce plasma levels of urea nitrogen and creatinine. This ameliorative effect of berberine appears to be related to its vasodilatory effect (Affuso et al., 2010; Derosa et al., 2012), which leads to increased clearance of creatinine and urea nitrogen. Besides, berberine treatment could compensate for renal I/R-induced hypoglycemia and increased plasma level of insulin possibly due to its anti-inflammatory and antioxidant activities which improve renal function (D'Apolito et al., 2010; Yu et al., 2013). In this way, according to our histological study, berberine treatment caused reduction in the vascular congestion of lobular pancreatic veins (Fig. 3).

Conclusion

It is concluded that renal I/R caused mild tissue damages and some functional disorders in the pancreas of rats. Berberine had an ameliorative effect against RIR-induced pancreatic injury by improving renal function, probably due to its anti-inflammatory effects.

Acknowledgments

We wish to acknowledge the Research Council of Shiraz University, Shiraz, Iran, for the financial support of this study (grant no. 88-GR-SCST-117).

Conflict of interest

There is no conflict of interest.

References

- Abogresha NM, Greish SM, Abdelaziz EZ, Khalil WF. Remote effect of kidney ischemia-reperfusion injury on pancreas: role of oxidative stress and mitochondrial apoptosis. *Arch Med Sci* 2016; 12: 252-62.
- Affuso F, Mercurio V, Fazio V, Fazio S. Cardiovascular and metabolic effects of Berberine. *World J Cardiol* 2010; 2: 71-7.
- Arem R. Hypoglycemia associated with renal failure. *Endocrinol Metab Clin North Am* 1989; 18: 103-21.
- Bonventre JV, Zuk A. Ischemic acute renal failure: an inflammatory disease?. *Kidney Int* 2004; 66: 480-5.
- Brier ME, Aronoff GR, Mayer PR. Effect of acute renal failure on insulin disposition in the isolated perfused rat kidney. *Am J Physiol* 1987; 253: F884-8.
- D'Apolito M, Du X, Zong H, Catucci A, Maiuri L, Trivisano T, et al. Urea-induced ROS generation causes insulin resistance in mice with chronic renal failure. *J Clin Invest* 2010; 120: 203-13.
- Dennis JM, Witting PK. Protective role for antioxidants in acute kidney disease. *Nutrients* 2017; 9: pii: E718.
- Derosa G, Maffioli P, Cicero AF. Berberine on metabolic and cardiovascular risk factors: an analysis from preclinical evidences to clinical trials. *Expert Opin Biol Ther* 2012; 12: 1113-24.
- Friedewald JJ, Rabb H. Inflammatory cells in ischemic acute renal failure. *Kidney Int* 2004; 66: 486-91.
- Friedman JE, Dohm GL, Elton CW, Rovira A, Chen JJ, Leggett-Frazier N, et al. Muscle insulin resistance in uremic humans: glucose transport, glucose transporters, and insulin receptors. *Am J Physiol* 1991; 261: E87-94.
- Gholampour F, Sadidi Z. Hepatorenal protection during renal ischemia by quercetin and remote ischemic preconditioning. *J Surg Res* 2018; 231: 224-233.
- Hassoun HT, Grigoryev DN, Lie ML, Liu M, Cheadle C, Tuder RM, et al. Ischemic acute kidney injury induces a distant organ functional and genomic response distinguishable from bilateral nephrectomy. *Am J Physiol Renal Physiol* 2007; 293: F30-40.
- Hussein AM, Abd-Elkhabir A, Abozahra A, Baiomy A, Ashamallah SA, Sheashaa HA, et al. Pancreatic injury secondary to renal ischemia/reperfusion (I/R) injury: possible role of oxidative stress. *Physiol Res* 2014; 63: 47-55.
- Jacobs DB, Hayes GR, Truglia JA, Lockwood DH. Alterations of glucose transporter systems in insulin-resistant uremic rats. *Am J Physiol* 1989; 257: E193-7.
- Lemay S, Rabb H, Postler G, Singh AK. Prominent and sustained up-regulation of gp130-signaling cytokines and the chemokine MIP-2 in murine renal ischemia-reperfusion injury. *Transplantation* 2000; 69: 959-63.
- Li Z, Geng YN, Jiang JD, Kong WJ. Antioxidant and anti-inflammatory activities of berberine in the treatment of diabetes mellitus. *Evid Based Complement Alternat Med* 2014; 2014: 289264.
- Liu M, Liang Y, Chigurupati S, Lathia JD, Pletnikov M, Sun Z, et al. Acute kidney injury leads to inflammation and functional changes in the brain. *J Am Soc Nephrol* 2008; 19: 1360-70.
- Meyer C, Dostou JM, Gerich JE. Role of the human kidney in glucose counterregulation. *Diabetes* 1999; 48: 943-8.
- Mohammadzadeh N, Mehri S, Hosseinzadeh H. Berberis vulgaris and its constituent berberine as antidotes and protective agents against natural or chemical toxicities. *Iran J Basic Med Sci* 2017; 20: 538-551.
- Sampanis Ch. Management of hyperglycemia in patients with diabetes mellitus and chronic renal failure. *Hippokratia* 2008; 12: 22-7.
- Schmidt C, Höcherl K, Bucher M. Regulation of renal glucose transporters during severe inflammation. *Am J Physiol Renal Physiol* 2007; 292: F804-11.
- Sternberg SS, Mills SE, Carter D. Sternberg's diagnostic surgical pathology. Lippincott Williams & Wilkins; 2004.
- Van den Berghe G, Wilmer A, Hermans G, Meersseman W, Wouters PJ, Milants I, et al. Intensive insulin therapy in the medical ICU. *N Engl J Med* 2006; 354: 449-61.
- van den Berghe G, Wouters P, Weekers F, Verwaest C, Bruyninckx F, Schetz M, et al. Intensive insulin therapy in the critically ill patients. *N Engl J Med* 2001; 345: 1359-67.
- Vriesendorp TM, van Santen S, DeVries JH, de Jonge E, Rosendaal FR, Schultz MJ, et al. Predisposing factors for hypoglycemia in the intensive care unit. *Crit Care Med* 2006; 34: 96-101.
- Yu W, Sheng M, Xu R, Yu J, Cui K, Tong J, et al. Berberine protects human renal proximal tubular cells from hypoxia/reoxygenation injury via inhibiting endoplasmic reticulum and mitochondrial stress pathways. *J Transl Med* 2013; 11: 24.
- Zhou H, Mineshita S. The effect of berberine chloride on experimental colitis in rats in vivo and in vitro. *J Pharmacol Exp Ther* 2000; 294: 822-9.