


Original Article

Protective effects of *Petroselinum crispum* on ischemia/reperfusion-induced acute kidney injury in rats

Shiva Roshankhah¹, Cyrus Jalili², Mohammad Reza Salahshoor^{1*} 

1. Department of Anatomy, Medical School, Kermanshah University of Medical Sciences, Kermanshah, Iran

2. Medical Biology Research Center, Department of Anatomy, Kermanshah University of Medical Sciences, Kermanshah, Iran

Abstract

Introduction: *Petroselinum crispum* (*P. crispum*) is an associate of Umbelliferae family that has several therapeutic attributes. Ischemia/reperfusion (I/R) is one of the main challenges in acute kidney damage. This study was designed to assess the anti-inflammatory and protective effects of *P. crispum* extract against I/R-induced renal disorders.

Methods: Forty male rats were randomly divided into five groups (n=8) namely normal control (saline) and I/R control group, and three groups of I/R intraperitoneally pretreated with various doses of *P. crispum* (100, 150 and 200mg/kg). The I/R-induced renal inflammation was evaluated by determining leukocyte infiltration and mRNA expression level of intercellular adhesion molecule-1 and tumor necrotic factor-alpha. Antioxidant capacity of kidneys and thiobarbituric acid reactive species were measured in kidneys for the evaluation of oxidative stress. In addition, the diameters of renal glomeruli, kidney function indicators and serum nitrite oxide levels were respectively determined by morphometric analysis, autoanalyzer device and Griess technique.

Results: The I/R increased all measured parameters except for the tissue ferric reducing/antioxidant power (FRAP) level, which was decreased compared to the normal control group. However, pretreatment with *P. crispum* extract in all doses significantly reduced blood urea nitrogen, kidney malondialdehyde, creatinine, glomerular diameter, leukocyte infiltration, levels of tumor necrotic factor-alpha, adhesion molecule-1 expression, and nitrite oxide as well as increased tissue FRAP compared to the I/R control group.

Conclusion: It seems that *P. crispum* administration improves I/R-induced acute kidney injury.

Keywords:

Petroselinum crispum;
Injury;
Kidney

Received: 24 Dec 2018

Accepted: 14 May 2019

*Correspondence to:

M.R. Salahshoor

Tel: +98-09188360349

Fax: +98-8338350177

Email:

mr.salahshour@kums.ac.ir

Introduction

Vegetables show a vigorous character in reducing hunger in the eating habits of many people. They are valuable sources of nutrients such as vitamins,

minerals, proteins and fibers (Rowland et al., 2018). Today, plant extracts have been taken into consideration and their helpful and adverse influence on many organs and tissues of the body have been recognized (Salahshoor et al., 2018). *Petroselinum crispum* (*P. crispum* or parsley) is a biennial plant

from Umbelliferae family used in nutrition and pharmacological applications (Wong and Kitts, 2006). *P. crispum* contains anti-hepatic fibrosis (Petrolini et al., 2013) and is diuretic (Corrêa Filho et al., 2018), anti-microbial (Ancuceanu et al., 2018), anti-menorrhagia (Jassim, 2013) and antioxidant (Nielsen et al., 1999). Additional properties of *P. crispum* include regulating blood pressure, treating eczema and improving reproductive indices (Jalili et al., 2015). *P. crispum* leaves are used as a hot application against inflammatory condition and mastitis (Al-Howiriny et al., 2003). The results of the study by Jassim (2013) indicated the histopathological changes in liver, kidney and pancreas induced by *P. crispum* in male rats. The compounds in *P. crispum* contain various minerals such as iron, ascorbic acid, phenylpropanoids, carotenoids, flavonoids, different terpenoid compounds, coumarin and tocopherol (Heidari et al., 2018). Food supplements containing the leaf of *P. crispum* significantly increase antioxidant level (Corrêa Filho et al., 2018). Petrolini et al. (2013) showed the antibacterial potential of *P. crispum* in the urinary tract infections. Ischemia/reperfusion (I/R) is one of the major causes of acute kidney injury (AKI) (Mahmoudzadeh et al., 2017). AKI happens in 5% of hospitalized patients and is related to 30-50% of admissions to the intensive care unit (Najafi et al., 2016). Pathophysiologically, one of the challenges in managing AKI is inflammation, which also leads to the progress of renal conflicts. Renal ischemia and nephrotoxins are the main causes of AKI (Li et al., 2019). The micro-anatomical structural changes of the kidney under stressful conditions include a reduce number of functional glomeruli from an increased prevalence of nephrosclerosis, the change in the size of the kidneys and hypertrophy nephrons (Mitobe et al., 2005). I/R has toxic effects and *P. crispum* extract has numerous beneficial, especially antioxidant effect. Furthermore, no study has ever investigated the effects of *P. crispum* on the I/R-induced impairments in the kidney tissue. Therefore, the purpose of this study was to evaluate the anti-inflammatory, kidneys antioxidant capacity, functional and morphological effects of *P. crispum* on AKI induced by I/R in male rats.

Materials and methods

Preparation of *P. crispum* stigma extract

P. crispum plant was obtained from a local store and its impurities were removed. After endorsement by a botanist, the plant was cleaned. The leaves and stems were desiccated in shadow for 5 days and ground using a grinder. Next, 100g of the powder was added to 70% ethanol and the acquired solution was reserved in a warm water bath (36°C) under dark condition. Thereafter, the solution was progressively poured on Buchner funnel filter paper and cleaned by a vacuum pump. It was then transferred to a rotary device to obtain the extra solvent. The isolation process continued until the concentrated extract was obtained. The extract was dissolved in distilled water and administered intraperitoneally per a kilogram of animal's weight. It was sterilized following double filtration through a 0.2- μ m filter (Jalili et al., 2015).

Animals

In this experimental study, 40 male Wistar rats (weighing 220-250g) were purchased from the Pasteur Institute and transferred to the animal house in medical school. During the study, the animals were kept under standard conditions (12h light/dark and 22 \pm 2°C) in special cages and on a straw bed. Water and food were provided *ad libitum* to the animals. Standard food and treated municipal water was used to feed the animals. All investigations conformed to the ethical and humane principles of research and were approved by the Ethics Committee of Kermanshah University of Medical Sciences (ethics certificate No.97503) (Ghorbani et al., 2014).

Study groups and treatment

In this section, 40 male rats were randomly assigned into 5 groups, each containing 8 rats. The first group was the normal control group that received normal saline (through intraperitoneal injection) equivalent to the number of experimental groups (0.5ml). In this group, all surgical procedures were performed, yet renal arteries were not occluded. In the second group, the I/R control group, 30min after saline injection, animals underwent a bilateral renal ischemia for 30min followed by 24h of reperfusion. The third to fifth groups, i.e., *P. crispum* groups, were treated with different doses of *P. crispum* (100, 150 and 200 mg/kg) in normal saline. In these groups, 30min following *P. crispum* injection, rats underwent a bilateral renal ischemia for 30min followed by 24h of reperfusion. All the rats received 100IU of heparin

(Merck) intraperitoneally and 30 min preoperatively (Jassim, 2013; Jalili et al., 2015; Mahmoudzadeh et al., 2017).

Surgery and induction of renal I/R

After anesthesia with intraperitoneally injected ketamine HCl (100mg/kg) and xylazine (10mg/kg) (Merck) and 100 units of heparin (Merck) to prevent intravascular blood clotting, a longitudinal incision was created in the linea alba by means of electrocautery (Surgistat-USA). Both, renal arteries were clamped at the same time by a non-traumatic microvascular clamp (Roboz Surgical Instruments-USA) for 30min, after which, they were released to allow for reperfusion. Throughout the surgery, the body temperature was controlled within the range of $37\pm 1^{\circ}\text{C}$ through a rectal probe connected to a thermistor. Rats were then dissected, their kidneys were removed and the left kidneys were separated longitudinally into two halves. One-half was processed for morphometric study and leukocyte infiltration. The other half was used to measure the number of intercellular adhesion molecule-1 (ICAM-1) and tumor necrotic factor-alpha (TNF- α) mRNAs expression. The right kidneys were used for oxidative stress measurements (Najafi et al., 2016).

Kidney function assay

After 24h reperfusion period, blood samples were collected from the animal's abdominal aorta. The blood samples were incubated at 37°C for 15min and centrifuged at 4000 rpm for 15min to acquire the serum. The serum samples were kept in -20°C freezer. Plasma samples were assayed for concentrations of plasma creatinine and blood urea nitrogen (BUN) using an autoanalyzer (RA 1000; Technicon Instruments; USA) (Jalili et al., 2017).

Measuring the diameter of renal glomeruli and rate of leukocyte infiltration

Samples were fixed by 10% formalin solution and washing. The process of tissue preparation was based on the conventional histology method (paraffin method), i.e. passing the samples from ascending alcohols for dehydration, passing through the mesh for clarification and removal of turbidity and ultimately passing paraffin for infiltration and filling the vacuum created at the pores of the fat. All these steps were performed using automatic tissue processors. After

molding each sample, serial sections were prepared by a microtome (Leica RM 2125, Leica Microsystems Nussloch GmbH; Germany) (slices with $5\mu\text{m}$ diameter) from the tissue. Among all sections, about 10 samples were selected for staining, hence 10 slides prepared from the kidneys of each rat. Among all sections, about 10 samples were selected for staining, hence 10 slides prepared from the kidneys of each rat and stained with hematoxylin and eosin (H&E). The diameter of glomeruli was examined under a microscope (Olympus BX-51T-32E01, Japan) linked to a DP12 camera with 3.34-million pixel resolution and Olysia Bio software (Olympus Optical; Japan). To determine the amount of leukocyte infiltration, the number of leukocytes in 20 microscopic fields, each consisting of 0.14 mm^2 was counted, averaged and used to estimate the quantity for each square millimeter (Najafi et al., 2016).

Real-time PCR assay

To assess inflammation, TNF- α and ICAM-1 mRNAs expression levels were measured, following the evaluation rate of leukocyte infiltration. Samples were frozen in liquid nitrogen and stored in a freezer at -80°C pending examination. In the initial step, RNA was extracted from the kidney tissue using the RNeasy mini kit (Qiagen co) according to the manufacturer's instructions. By DNase set kit, the extracted RNA samples were treated to eliminate the genomic DNA. The cDNA version was produced from the RNA extracted in the previous step by means of RevertAid™ First Strand cDNA Synthesis Kit. The expression level of the given gene was measured through GAPDH primer (Glyceraldehyde 3-phosphate dehydrogenase) as endogenous control by Maxima SYBR Green/Rox qPCR master mix (Fermentas co) through comparative Ct ($\Delta\Delta\text{Ct}$) technique. First, 10min denaturation at 59°C , 15s

Table1: Primers used in real-time PCR

Primer ID	Primer sequences
GAPDH-F	AAGCTCATTTCCTGGTATG
GAPDH-R	CTGCCACAAGAAGACTAGAGGATAAGA
TNF- α -F	ATGAGCACTGAAAGCATGAT
TNF- α -R	CTCTTGATGGCAGAGAGGAG
ICAM-1-F	CAGCAGACCACTGTGCTTTGA
ICAM-1-R	GTCGAGCTTCAGGACCCCTAGT

denaturation at 59°C and 1min annealing extension at 60°C were performed with 40 cycles; then, melt curves (increment 3°C, 60°C→95°C) were drawn by Stepone plus (Applied biosystem). The sequence of utilized primers are shown in Table 1 (Esfandiari et al., 2014).

Assessment of oxidative stress

In order to assess the oxidative stress, the thiobarbituric acid (TBA) reactive species were measured using malondialdehyde (MDA) as the last product of lipid peroxidation in kidney tissue by colorimetric analysis. In brief, 1400µl of acetic acid (Sigma, USA), 1400µl of TBA (Sigma, USA) and 1400µl of sodium dodecyl sulfate (Sigma, USA) were added to 100µl of kidney homogenate and the mixture was animated for 50min. Then, 4ml of 1-butanol (Sigma, USA) was added to the combination and vortexed 2min through centrifugation at 5000rpm for 15min. The absorbance of the higher layer was measured at 532nm (Spectro; Germany) and sequential concentrations of tetraethoxypropane (Sigma, USA) were used as the external standard. The antioxidant capacity of the kidney was measured using FRAP assay. The FRAP substance consisted of 30ml of acetate buffer (Sigma, USA) and 1.5ml chloride ferric (Sigma, USA). In brief, 60µl of kidney homogenate was added to 1.5ml of the newly prepared FRAP (Sigma, USA) in a test tube and incubated at 37°C for 10min. The absorbance of the blue-colored complex was read against a blank at 593nm. Sequential concentrations of FeSO₄.7H₂O (Sigma, USA) were used as an external standard (Mahmoudzadeh et al., 2017).

Griess technique

Griess technique was used to specify the serum nitrite oxide level. In this approach, zinc sulfate powder is used to eliminate the serum protein of the samples. Accordingly, zinc sulfate powder (6mg) was mixed with serum samples (400µl) and vortexed for 1min. The samples were centrifuged at 4°C for 10min at 12,000 rpm and the supernatant was used to measure the nitrite oxide. Briefly, 50µl of the sample was added to 100µl of Griess reagent (Sigma; USA) and the reaction mixture was incubated for approximately 30min at room temperature. The sample optical density was measured by ELISA reader (Hyperion; USA) at a wavelength of 450nm according to manufacturer protocol (Jalili et al., 2015).

Statistical analysis

After extracting the information, the Kolmogorov-Smirnov test was primarily conducted to confirm the data compliance of the normal distribution. One-way analysis of variance (one-way ANOVA) was used for statistical analysis and Tukey post hoc test was applied to determine the difference between the groups. SPSS 16 was used for data analysis, the results were expressed as a mean±SEM and $P<0.05$ was considered significant.

Results

Kidney function markers

Renal I/R significantly increased the mean BUN and creatinine concentration in the I/R control group compared to the normal control group ($P<0.001$). The mean plasma BUN and creatinine concentration were significantly reduced in all *P. crispum* treated groups compared with the I/R control group ($P<0.001$, Fig. 1).

Leukocytes infiltration rate

Subsequent renal I/R, lymphocytes were infiltrated significantly from renal vessels in the I/R control group in comparison with the control normal group ($P<0.001$). The mean infiltrated lymphocytes were significantly reduced in animals treated with *P. crispum* in all doses compared with the I/R control group ($P<0.001$, Figs. 2 and 3).

The diameter of renal glomeruli

Morphometric analysis revealed that renal I/R significantly decreased the mean diameter of the glomerulus tubule in the I/R control group compared with the normal control group ($P<0.001$). In all doses, treatment with *P. crispum* significantly increased the diameter of the glomeruli compared with the I/R control group ($P<0.001$, Fig. 4).

Real-time PCR

Renal I/R caused a significant increase in the ICAM-1 and TNF- α genes expression in the I/R control group compared to the normal control group ($P<0.001$). In all doses, *P. crispum* extract was able to significantly reduce the expression of both genes compared with the I/R control group ($P<0.001$, Fig. 5).

Oxidative stress

The results of the testing oxidative stress in the

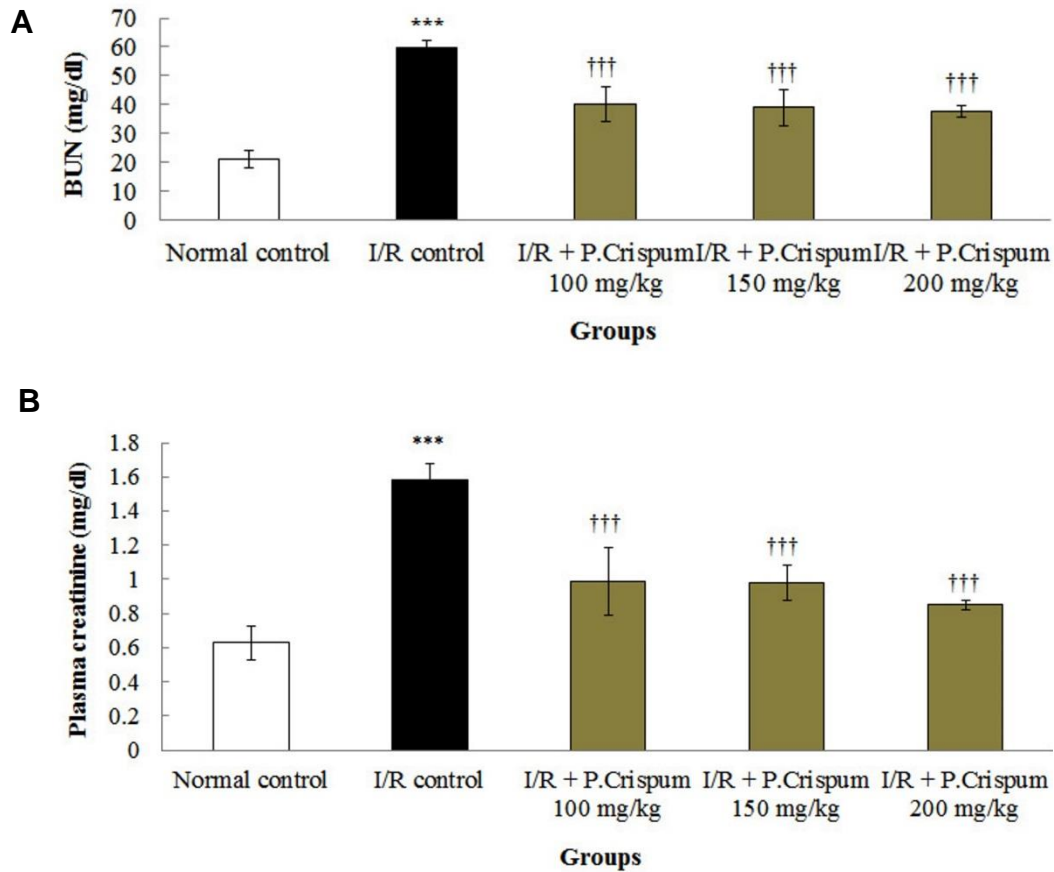


Fig.1. Effect of *P. crispum* and ischemia/reperfusion (I/R) on the mean kidney functional factors: (A) blood urea nitrogen (BUN) (B) creatinine. ***Significant difference compared to the normal control group ($P<0.001$); †††Significant difference compared to the I/R control group ($P<0.001$).

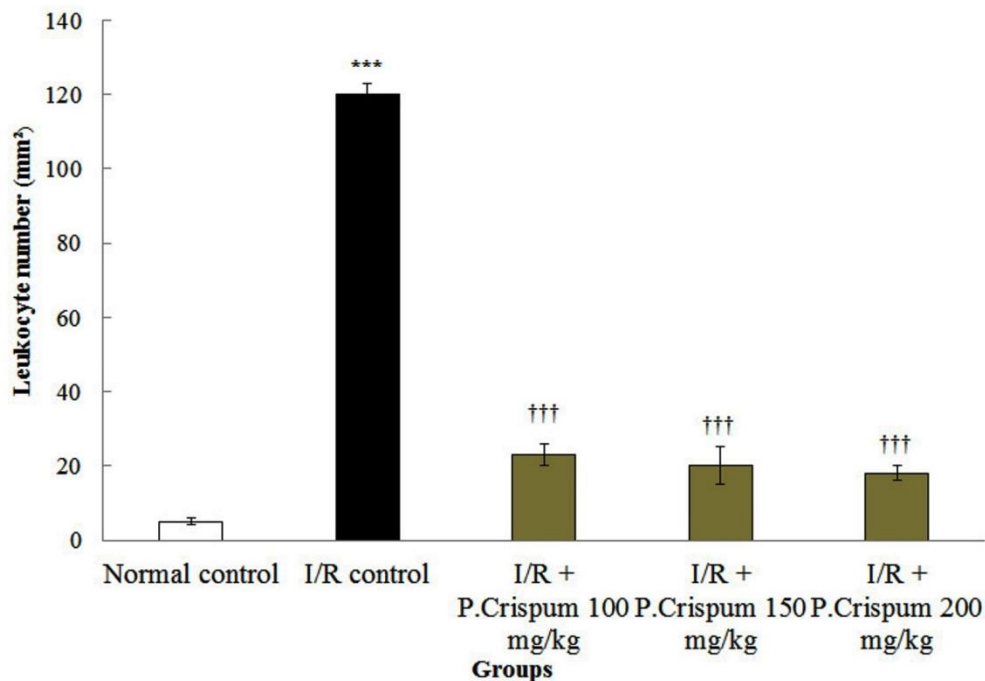


Fig.2. Mean of leukocyte infiltration per square millimeter, at the end of the reperfusion period, in renal ischemia/reperfusion (I/R) and treated with different doses of *Petroselinum crispum* (*P. crispum*). ***Significantly different compared to the normal control group ($P<0.001$). †††Significantly different compared to I/R control group ($P<0.001$).

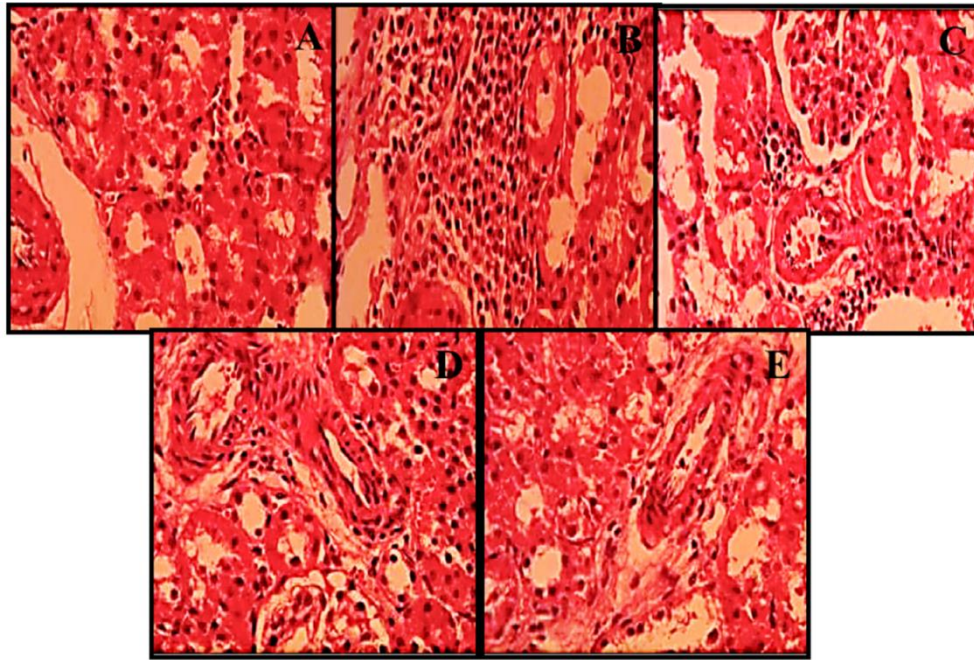


Fig.3. Light microscopic photographs of renal cortex for representing leukocyte infiltration in rats which underwent: (A) normal control group; (B) I/R control group; (C) Treatment with *Petroselinum crispum* (P. Crispum) at dose of 100 mg/kg; (D) Treatment with P. Crispum at dose of 150 mg/kg; and (E) and treatment with P. Crispum at dose of 200 mg/kg.

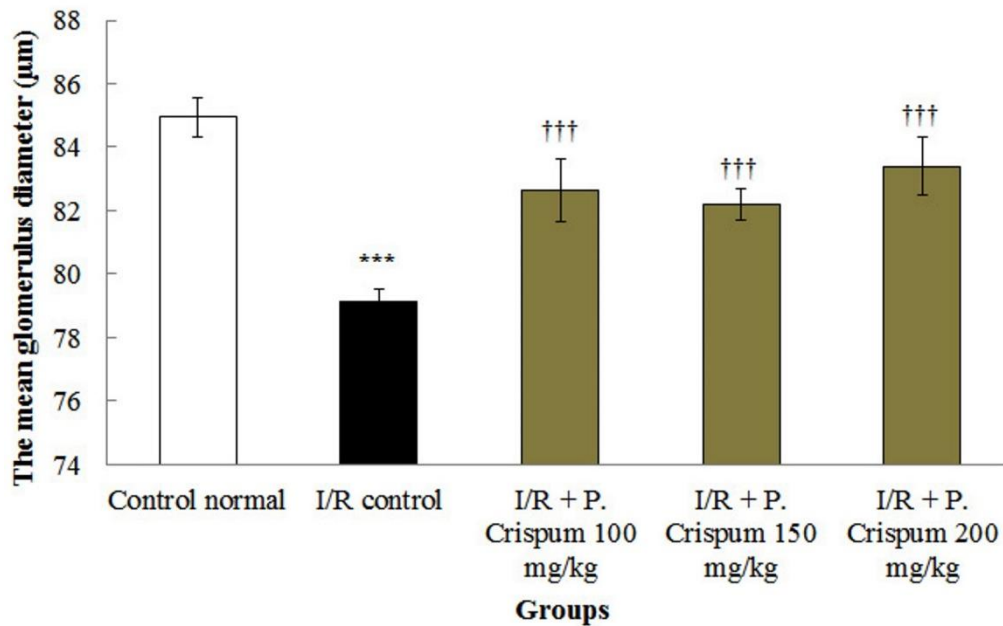


Fig.4. Glomerular diameter changes in kidneys. ***Significant difference compared to the normal control group ($P < 0.001$). †††Significant difference compared to ischemia/reperfusion (I/R) control group ($P < 0.001$).

groups showed that the kidney MDA level increased significantly in the renal I/R control group compared to the normal control group ($P < 0.001$). The kidney MDA level was significantly reduced in all P. crispum groups compared to the I/R control group ($P < 0.001$). Similarly, renal I/R significantly reduced the renal

tissue FRAP level of the I/R control group compared to that of the normal control group ($P < 0.001$). Administration of P. crispum significantly augmented the FRAP level in the kidney tissue in all P. crispum groups compared to the I/R control group ($P < 0.001$, Fig. 6).

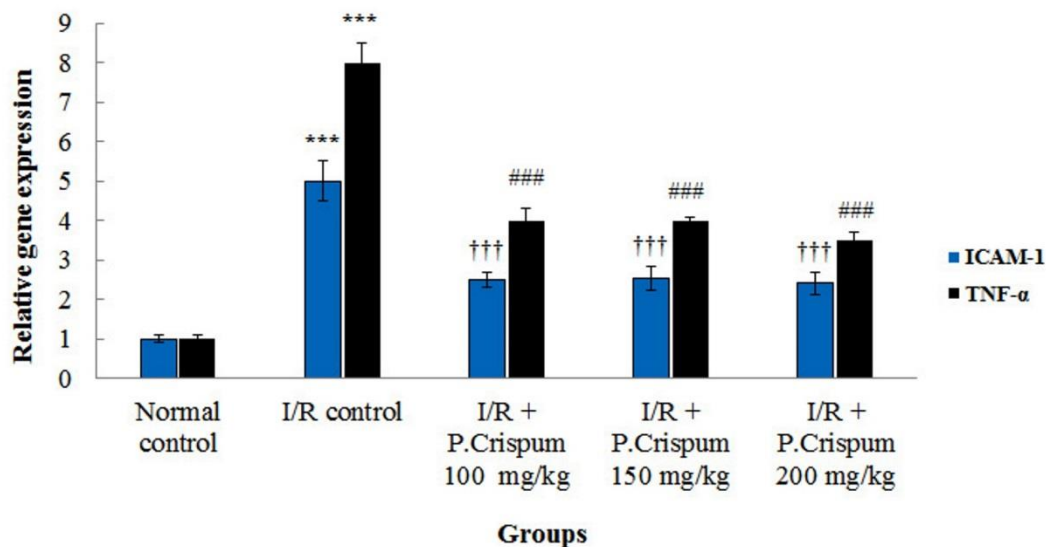


Fig.5. Results of quantitative RT-PCR on the tumor necrosis factor- α (TNF- α) and intercellular adhesion molecule-1 (ICAM-1) mRNAs expression in renal cortex of rats. Relative expression levels of each gene were obtained via comparative threshold cycle (Ct) ($\Delta\Delta$ ct) method. ***A significant increase in ischemia/reperfusion (I/R) control group compared with the normal control group ($P < 0.001$). †††A significant increase of ICAM-1 mRNA expression in P. crispum groups compared to I/R control group ($P < 0.001$). ###Significant increase of TNF- α mRNA expression in P. crispum treated groups compared to I/R control group ($P < 0.001$).

Nitrite oxide

The mean nitrite oxide in the blood serum was significantly increased in the I/R control group compared to the normal control group ($P < 0.001$). The mean nitrite oxide in the blood serum was significantly decreased in all P. crispum groups compared to the I/R control group ($P < 0.001$, Fig. 7).

Discussion

Petroselinum crispum is a vegetable from the species of flowering plant with different pharmacological effects (Jalili et al., 2015). The absence of oxygen from blood during the I/R leads to oxidative injury through the induction of oxidative stress and inflammation (Mahmoudzadeh et al., 2017). The current study evaluated the effects of P. crispum in the renal I/R-induced damage. According to the results of this study, there was no significant relationship between the increase in the dose of P. crispum and its effects on kidney parameters compared with the control group. All P. crispum doses used in this study increased the quality of kidney parameters compared to the control group. Noteworthy, the I/R group was compared with control normal group and P. crispum + I/R groups were compared with I/R control group. All doses of P. crispum improved the quantity of kidney parameters.

It was further observed that the mRNA expression and lymphocyte infiltration of ICAM-1 and TNF- α increased significantly following I/R. This result is consistent with that of Kelly et al. (1996) where renal ischemia led to incremental adjustments of adhesion molecules in the kidney. The inflammatory responses to ischemia can be the main cause of the expansion in injuries. Particularly, TNF- α , through its direct destructive effects entails renal function impairment as well as a reduction in the blood flow and leukocytes infiltration (Alhasson et al., 2018). Moreover, it triggers cell infiltration and creation of ICAM-1 (Grigoryev et al., 2008). In endothelial cells, ICAM-1 gene expression increases within one hour following renal I/R, which increases the movement to the interstitium and leukocytes binding (Ali et al., 2018). Cytokines stimulate leukocytes after their translocation into the interstitium and exiting the blood vessels (Perrone et al., 2018). Conversely, the inhibition of the increase in ICAM-1 might protect kidneys in contrast to injuries caused by I/R (Cosimi et al., 1990). In the present study, lymphocytes infiltrated into the interstitium subsequent renal I/R, which is in line with the results of Rabb et al. (2000). The decreased activation of lymphocyte and subsequent limitation in their infiltration into the interstitium in P. crispum treated groups is possibly due to the anti-oxidative effect of P. crispum and

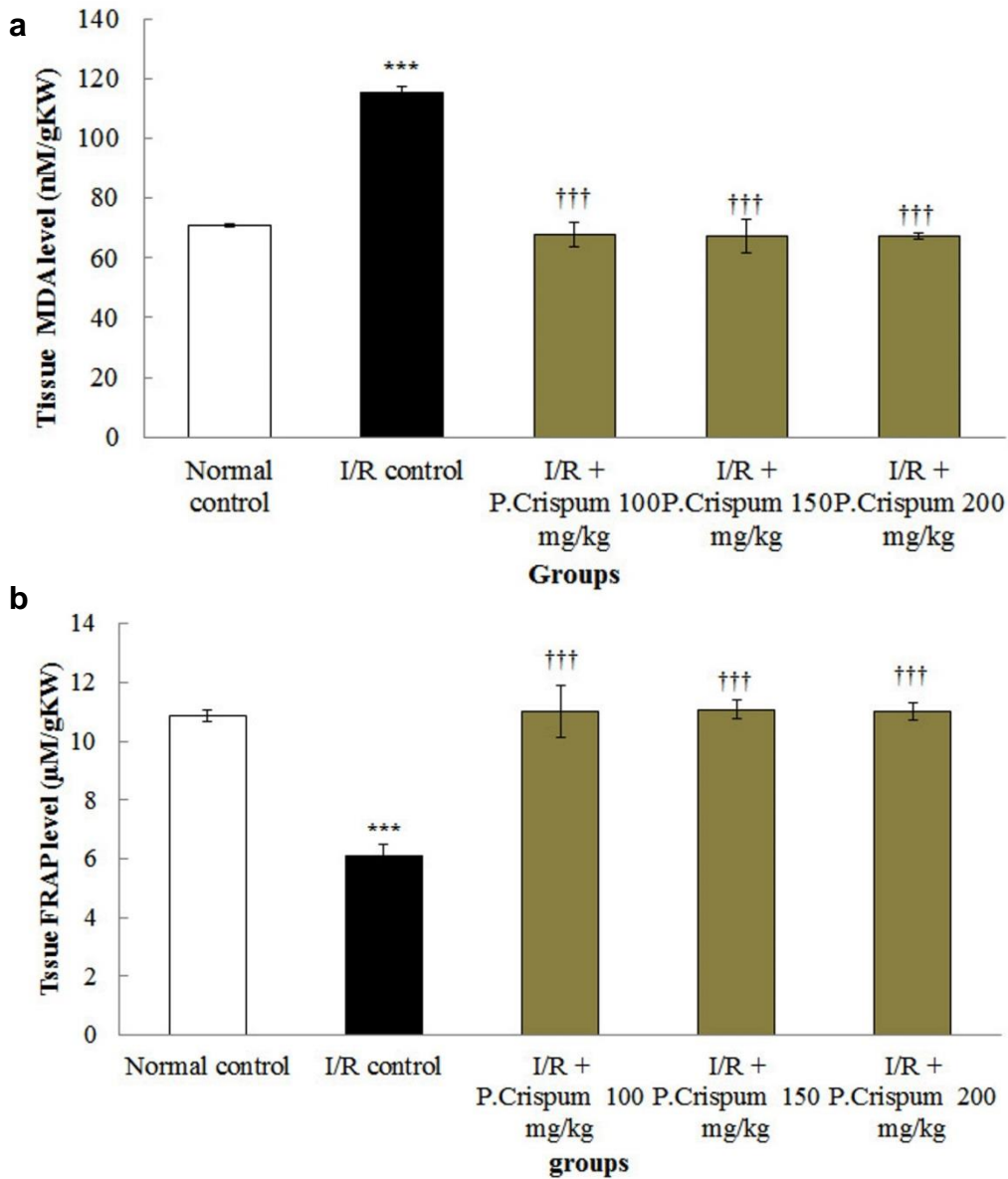


Fig.6. Comparison of ischemia/reperfusion (I/R) and *Petroselinum crispum* (*P. crispum*) groups of (a) kidney malondialdehyde (MDA) level; (b) tissue ferric reducing/antioxidant power (FRAP) level. ***Significant difference compared to the normal control group ($P<0.001$). †††Significant difference compared to I/R control group ($P<0.001$).

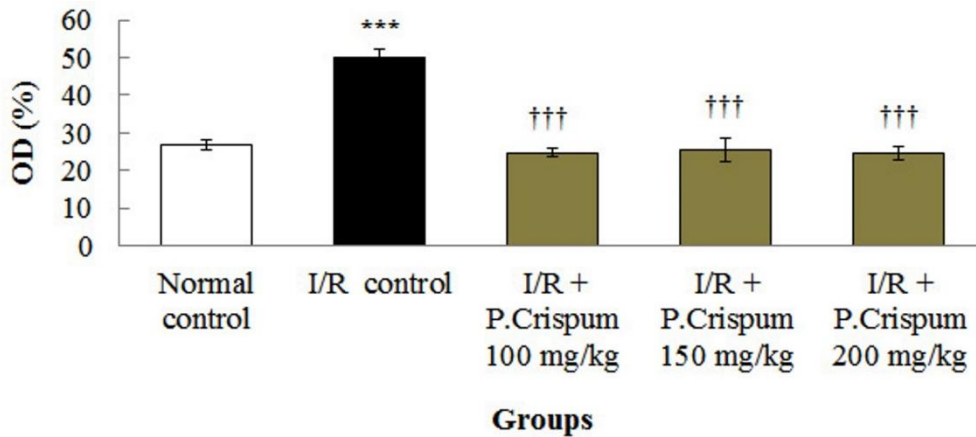


Fig.7. Effects of *Petroselinum crispum* (*P. crispum*) and ischemia/reperfusion (I/R) on the sample optical density (OD) of the mean nitrite oxide in the blood serum was measured by ELISA. ***Significant difference compared to the normal control group ($P<0.001$). †††Significantly different compared to I/R control group ($P<0.001$).

reduced expressions of TNF- α and ICAM-1 genes (Gupta et al., 2010). Petrolini et al. (2013) showed that the treatment of urinary tract with *P. crispum* extract reduced inflammatory cells, also in line with Al-Howiriny et al. (2003) where *P. crispum* administration significantly reduced the inflammation in the livers of the rats. *P. crispum* seems to reduce TNF- α gene expression and reactive oxygen species production (Yousofi et al., 2012). It was suggested that the anti-inflammatory effects of *P. crispum* might be due to its content of flavonoids (Jalili et al., 2015). The results of the present study showed that the amount of nitrite oxide increased significantly in the serum following I/R. In all *P. crispum* treated groups, there was a significant decrease in serum nitrite oxide levels compared to R/I control group. Nitrite oxide is an important molecule that plays a key role in body physiology (Roshankhah et al., 2017). Nitrite oxide molecule produced by iNOS can induce DNA damage and structural degradation in many lipids and proteins (Salahshoor et al., 2016). R/I seems to further cause cell damage by the up-regulation of iNOS (Ajamieh et al., 2004). The results of Ferdinandy et al. (2003) are consistent with the results of the present study, suggesting that R/I can significantly increase the expression of iNOS. *P. crispum* can inhibit nitrite oxide inducing lipopolysaccharide by inducing the expression of Heme oxygenase-1 and calmodulin / calcium-dependent protein kinase-4 (Jalili et al., 2015). The results of the current study further indicated that *P. crispum* is able to reduce lipid peroxidation and increase the antioxidant capacity of kidney tissue, thus reducing oxidative stress. Accordingly, it appears that *P. crispum*, with its anti-oxidant properties is capable of reducing MDA and increasing FRAP in the treatment groups by inhibiting the production of reactive oxygen species. In line with the present research, Haidari et al. (2011) showed that *P. crispum* could reduce MDA levels. In this study, a 30min ischemia and 24h reperfusion led to an increase in plasma creatinine and BUN concentrations in R/I control group. *P. crispum* in all doses was able to reduce the level of creatinine and BUN. These results suggest that the growth in creatinine concentration by I/R is accompanied by the decrease in glomerular filtration rate (Star, 1998). Renal creatinine clearance is the indicator of glomerular filtration rate and is reduced following I/R.

One of the main reasons for the reduction in renal blood flow subsequent I/R is the equilibrium among the vasodilator (such as nitrite oxide) (Byrami et al., 2013). These results are in agreement with those of Jalili et al. (2015) who observed that *P. crispum* reduced nitrite oxide in rat's testis, probably by iNOS inhibition. Therefore, possibly through accumulative blood flow, *P. crispum* reduces cell damages and, the pressure of Bowman's space, leading to enhanced glomerular filtration rate and improvement in the BUN and creatinine levels (Park et al., 2018). Additionally, a part of the protecting effects of *P. crispum* can originate from the reduction in TNF- α construction, resulting in enhanced renal blood flow and glomerular filtration rate (Rezazad et al., 2014). The treatment of animals with *P. crispum* in all doses increased the diameter compared to the I/R control group. The rupture in the glomerular order diminishes glomerular size and damage of proximal tubules, which are among the changes that can indicate the pathological effects of I/R on glomeruli (Damabi et al., 2010). It seems that the decrease in the mean diameter of glomeruli can be associated with kidney functional disorders (Jiang et al., 2018). *P. crispum* can reduce platelet aggregation and fibrinogen as well as have direct effects on inflammatory (Petrolini et al., 2013). It further seems to be able to reduce oxidative stress, hence neutralizing the effects of R/I.

Conclusion

Briefly, the current study showed that *P. crispum* extract contributes to reducing oxidative stress and inflammation due to both 30min renal ischemia and 24h reperfusion in the animals studied. *P. crispum* can further improve the renal damage subsequent to I/R, possibly through its antioxidant properties, reducing the activation of pro-inflammatory elements and correcting the blood flow.

Acknowledgments

We are grateful to the Research Council of Kermanshah University of Medical Sciences (No: 97503) for their financial support.

Conflict of interest

There are no conflicts of interest.

References

- Ajamieh HH, Menéndez S, Martínez-Sánchez G, Candelario-Jalil E, Re L, Giuliani A, et al. Effects of ozone oxidative preconditioning on nitric oxide generation and cellular redox balance in a rat model of hepatic ischaemia-reperfusion. *Liver Int* 2004; 24: 55-62.
- Alhasson F, Seth RK, Sarkar S, Kimono DA, Albadrani MS, Dattaroy D, et al. High circulatory leptin mediated NOX-2-peroxynitrite-miR21 axis activate mesangial cells and promotes renal inflammatory pathology in nonalcoholic fatty liver disease. *Redox Biol* 2018; 17: 1-15.
- Al-Howiriny TA, Al-Sohaibani MO, El-Tahir KH, Rafatullah S. Preliminary evaluation of the anti-inflammatory and anti-hepatotoxic activities of parsley/petroselinum crispum in rats. *J Nat Med* 2003; 3: 54-62.
- Ali RM, Al-Shorbagy MY, Helmy MW, El-Abhar HS. Role of Wnt4/ β -catenin, Ang II/TGF β , ACE2, NF- κ B, and IL-18 in attenuating renal ischemia/reperfusion-induced injury in rats treated with Vit D and pioglitazone. *Eur J Pharmacol* 2018; 831: 68-76.
- Ancuceanu R, Anghel AI, Hovanet MV, Dinu MI, Olaru OT, Dune AL, et al. Variation of iron contents polyphenols and flavonoids in petroselinum crispum (mill) fuss (apiaceae). *Farmacia* 2018; 66: 275-81.
- Byrami G, Boskabady MH, Jalali S, Farkhondeh T. The effect of the extract of *Crocus sativus* on tracheal responsiveness and plasma levels of IL-4, IFN- γ , total NO and nitrite in ovalbumin sensitized guinea-pigs. *J Ethnopharmacol* 2013; 147: 530-5.
- Corrêa Filho LC, Martinazzo AP, de Souza Teodoro CE, Vivès L. Microbiological quality and essential oil of parsley (*Petroselinum crispum*) submitted to the hygienizing and drying process. *Ind Crop Prod* 2018; 114: 180-4.
- Cosimi AB, Conti D, Delmonico FL, Preffer FI, Wee SL, Rothlein R, et al. In vivo effects of monoclonal antibody to ICAM-1 (CD54) in nonhuman primates with renal allografts. *J Immunol* 1990; 144: 4604-12.
- Damabi NM, Moazedi AA, Seyyednejad SM. The role of α - and β -adrenergic receptors in the spasmolytic effects on rat ileum of *Petroselinum crispum* Latifolium (parsley). *Asian Pac J Trop Dis* 2010; 3: 866-70.
- Esfandiari E, Roshankhah S, Mardani M, Hashemibeni B, Naghsh E, Kazemi M, et al. The effect of high frequency electric field on enhancement of chondrogenesis in human adipose-derived stem cells. *Iran J Basic Med Sci* 2014; 17: 571-6.
- Ferdinandy P, Schulz R. Nitric oxide, superoxide, and peroxynitrite in myocardial ischaemia-reperfusion injury and preconditioning. *Br J Pharmacol* 2003; 138: 532-43.
- Ghorbani R, Mokhtari T, Khazaei M, Salahshoor MR, Jalili C, Bakhtiari M. The effect of walnut on the weight, blood glucose and sex hormones of diabetic male rats. *Inter J Morphol* 2014; 32: 833-8.
- Grigoryev DN, Liu M, Hassoun HT, Cheadle C, Barnes KC, Rabb H. The local and systemic inflammatory transcriptome after acute kidney injury. *J Am Soc Nephrol* 2008; 19: 547-58.
- Gupta SC, Kim JH, Prasad S, Aggarwal BB. Regulation of survival, proliferation, invasion, angiogenesis, and metastasis of tumor cells through modulation of inflammatory pathways by nutraceuticals. *Cancer Metastasis Rev* 2010; 29: 405-34.
- Haidari F, Keshavarz SA, Mohammad Shahi M, Mahboob SA, Rashidi MR. Effects of parsley (*Petroselinum crispum*) and its flavonol constituents, kaempferol and quercetin, on serum uric acid levels, biomarkers of oxidative stress and liver xanthine oxidoreductase activity in oxonate-induced hyperuricemic rats. *Iran J Pharm Res* 2011; 10: 811-9.
- Heidari T, Moazedi AA, Seyyednejad SM, Borojeni MP. The role of histaminergic H2 receptors on spasmolytic activity of hydroalcoholic extract of parsley (*Petroselinum crispum*) seeds in isolated rat's ileum. *J Nat Rem* 2018; 17: 114-24.
- Jalili C, Makalani F, Roshankhah S, Sohrabi K, Salahshoor MR. Protective effect of resveratrol against morphine damage to kidneys of mice. *Int J Morphol* 2017; 35: 1409-1415.
- Jalili C, Salahshoor MR, Naderi T. The effect of hydroalcoholic extract of *P. crispum* on sperm parameters, testis tissue and serum nitric oxide levels in mice. *Adv Biomed Res* 2015; 4: 40.
- Jassim AM. Protective effect of *Petroselinum crispum* (parsley) extract on histopathological changes in liver, kidney and pancreas induced by sodium valproate-in male rats. *Kufa j vet Sci* 2013; 4: 20-7.
- Jia H, Aw W, Hanate M, Takahashi S, Saito K, Tanaka H, et al. Multi-faceted integrated omics analysis revealed parsley (*Petroselinum crispum*) as a novel dietary intervention in dextran sodium sulphate induced colitic mice. *J Funct Foods* 2014; 11: 438-48.
- Jiang K, Tang H, Mishra PK, Macura SI, Lerman LO. Measurement of murine single-kidney glomerular filtration rate using dynamic contrast-enhanced MRI. *Magn Reson Med* 2018; 79: 2935-43.
- Kelly KJ, Williams WW Jr, Colvin RB, Meehan SM, Springer TA, Gutiérrez-Ramos JC, et al. Intercellular adhesion molecule-1-deficient mice are protected against ischemic renal injury. *J Clin Invest* 1996; 97: 1056-63.
- Li QP, Wei RB, Yang X, Zheng XY, Su TY, Huang MJ, et al. Protective effects and mechanisms of shenhua tablet () on Toll-like receptors in rat model of renal ischemia-reperfusion injury. *Chin J Integr Med* 2019; 25: 37-44.
- Mahmoudzadeh L, Najafi H, Ashtiyani SC, Yarijani ZM. Anti-inflammatory and protective effects of saffron extract in ischaemia/reperfusion-induced acute kidney injury. *Nephrology (Carlton)* 2017; 22: 748-54.
- Mitobe M, Yoshida T, Sugiura H, Shiota S, Tsuchiya K, Nihei HOxidative stress decreases klotho expression in a mouse kidney cell line. *Nephron Exp Nephrol* 2005; 101: e67-74.
- Najafi H, Owji SM, Kamali-Sarvestani E, Moosavi SM. A1 - Adenosine receptor activation has biphasic roles in development of acute kidney injury at 4 and 24 h of

- reperfusion following ischaemia in rats. *Exp Physiol* 2016; 101: 913-31.
- Nielsen SE, Young JF, Daneshvar B, Lauridsen ST, Knuthsen P, Sandström B, et al. Effect of parsley (*Petroselinum crispum*) intake on urinary apigenin excretion, blood antioxidant enzymes and biomarkers for oxidative stress in human subjects. *Br J Nutr* 1999; 81: 447-55.
- Park JH, Kho MC, Oh HC, Kim YC, Yoon JJ, Lee YJ. 1,2,3,4,6-penta-O-galloyl- β -D-glucose from *Galla rhois* ameliorates renal tubular injury and microvascular inflammation in acute kidney injury rats. *Am J Chin Med* 2018; 46: 785-800.
- Perrone S, Weiss MD, Proietti F, Rossignol C, Cornacchione S, Bazzini F, et al. Identification of a panel of cytokines in neonates with hypoxic ischemic encephalopathy treated with hypothermia. *Cytokine* 2018; 111: 119-124.
- Petrolini FV, Lucarini R, de Souza MG, Pires RH, Cunha WR, Martins CH. Evaluation of the antibacterial potential of *Petroselinum crispum* and *Rosmarinus officinalis* against bacteria that cause urinary tract infections. *Braz J Microbiol* 2013; 44: 829-34.
- Rabb H, Daniels F, O'Donnell M, Haq M, Saba SR, Keane W, et al. Pathophysiological role of T lymphocytes in renal ischemia-reperfusion injury in mice. *Am J Physiol Renal Physiol* 2000; 279: F525-31.
- Rezazad M, Farokhi F. Protective effect of *Petroselinum crispum* extract in abortion using prostadin-induced renal dysfunction in female rats. *Avicenna J Phytomed* 2014; 4: 312.
- Rowland LS, Smith HK, Taylor G. The potential to improve culinary herb crop quality with deficit irrigation. *Sci Am* 2018; 242: 44-50.
- Roshankhah SH, Salahshoor MR, Jalili F, Karimi F, Sohrabi M, Jalili C. Crocin effects on the nicotine-induced ovary injuries in female rat. *Int J Life Sci Pharma* 2017; 7: 1-8.
- Salahshoor MR, Khazaei M, Jalili C, Keivan M. Crocin improves damage induced by nicotine on a number of reproductive parameters in male mice. *Int J Fertil Steril* 2016; 10: 71-8.
- Salahshoor MR, Roshankhah S, Hosseni P, Jalili C. Genistein improves liver damage in male mice exposed to morphine. *Chin Med J (Engl)* 2018; 131: 1598-1604.
- Star RA. Treatment of acute renal failure. *Kidney Int* 1998; 54: 1817-31.
- Wong PY, Kitts DD. Studies on the dual antioxidant and antibacterial properties of parsley (*Petroselinum crispum*) and cilantro (*Coriandrum sativum*) extracts. *Food Chem* 2006; 97: 505-15.
- Yousofi A, Daneshmandi S, Soleimani N, Bagheri K, Karimi MH. Immunomodulatory effect of Parsley (*Petroselinum crispum*) essential oil on immune cells: mitogen-activated splenocytes and peritoneal macrophages. *Immunopharmacol Immunotoxicol* 2012; 34: 303-8.