

Research Paper: Effects of Aloe Vera Gel Extract on Aging-Associated Histological Changes of the Sciatic Nerve

Babak Barmaki¹, Hamidreza Ghaffari^{2*}, Soghra Gholami³, Malihe Alipoor Tabrizi⁴

1. Department of Physiology, School of Medicine, Zabol University of Medical Sciences, Zabol, Iran.

2. Department of Anatomical Sciences, School of Medicine, Zabol University of Medical Sciences, Zabol, Iran.

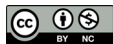3. Department of Anatomy, School of Medicine, Shiraz University of Medical Sciences, Shiraz, Iran.

4. Department of Heart, Emam Reza Hospital, Mashhad University of Medical Sciences, Mashhad, Iran.

Citation: Barmaki B, Ghaffari H, Gholami S, Alipoor Tabrizi M. Effects of Aloe Vera Gel Extract on Aging-Associated Histological Changes of the Sciatic Nerve. *Anatomical Sciences*. 2017; 14(3):89-98.



Hamidreza Ghaffari is the assistant professor of anatomy in the Department of Physiology, School of Medicine, Zabol University of Medical Sciences, Zabol, Iran. His research interests are anatomy, histology and embryology.



Funding: See Page 96

Article info:

Received: 13 November 2016

Accepted: 05 February 2017

Available Online: 01 August 2017

Keywords:

Aging, Aloe vera, Neuropathy, Sciatic nerve, Rats

ABSTRACT

Introduction: Prior qualitative and quantitative studies have reported morphological changes that occur in nerve fibers and non-neuronal cells of peripheral nerve during the lifetime of the rats. Previous studies suggest that Aloe Vera has some beneficial and therapeutic effects such as anti-oxidant effects. In the current study, we have evaluated histological and histomorphometric changes of Sciatic nerve in aged rats treated with Aloe Vera gel extract.

Methods: Sixty healthy male albino Sprague-Dawley rats weighing 200-250 g were randomly divided into two groups: control (normal diet), and experimental group (normal diet+Aloe Vera extract). Rats of the experimental group received 400 mg/kg Aloe Vera extract daily. Within 16, 20 and 24 months, animals were anesthetized with sodium thiopental (40 mg/kg) via IP injection. After removal of Sciatic nerve on the left side, nerve dissected and fixed in 4% glutaraldehyde, post fixed in osmium tetroxide 1%, dehydrated and then embedded in TAAB resin. Thin sections (1 μm) were stained with toluidine blue stain and ten slides were obtained from each animal and got examined on light microscope. Masson's trichrome stain was used to evaluate the development of fibrosis. Histomorphometric and histologic criteria on Sciatic nerve were determined and data were recorded. Data were analyzed using SPSS software.

Results: Results of the current study confirmed accumulation of collagen in the perineurium by aging. Our data suggested that aging caused a decrease in diameter of nerve trunk and nerve fibers, thickness of myelin and nerve fiber area. The nerve fascicle diameter decreased in the control group, only. The numbers of myelinated fibers with enfolding into the axoplasm and out folding, irregularity of nerve fibers, myelin sheath with unclear boundaries and alteration in myelin compaction were also increased. Treatment with Aloe Vera gel prevented nerve trunk, as well as fiber and myelin thickness changes.

Conclusion: In the current study, we observed some alterations in sciatic nerve caused by aging, such as accumulation of collagen in perineurium and endoneurium. Also, a significant decrease was seen in nerve fibers, nerve trunks diameter and myelin thickness which were highly evident in rats of the 24 months age group. Treatment with Aloe vera gel extract improved histological changes and retarded neuropathy signs, significantly.

* Corresponding Author:

Hamidreza Ghaffari, PhD

Address: Department of Anatomical Sciences, School of Medicine, Zabol University of Medical Sciences, Zabol, Iran.

Tel: +98 (54) 32230764

E-mail: hamidghaffary@yahoo.com

1. Introduction

Neurologic diseases are common among the elderly and account for approximately fifty percent of disabilities after age 65 [1]. Peripheral neural function abnormalities are commonly seen during physical examination of elderly patients. Aging accompanies with changes in structure and function of peripheral nerves that may be results of the aging process; however in absence of diseases, relatively minor changes happen [2]. Peripheral neuropathy in aging may occur due to trauma, regenerative disturbance, poor perfusion and local nerve entrapment [3].

Previous studies indicated that functional deficits may be the consequence of nerve fiber loss [4], myelin abnormalities [1, 5, 6] and/or alterations in connective tissue and vascularization [7] as well as changes in neuronal or glial expression of membrane channels, trophic factors and cell adhesion molecules, slow axonal transport or membrane turn over. Aging also deteriorates the capability of peripheral nerve regeneration and reinnervation of effectors, different in motor and sensory nerves [8]. However, in some studies regarding aging, differences between adult and old animals have often been due to comparison of only two experimental groups, whereas the life span and the duration of growth periods should be carefully taken into account to ensure that adult and old animals are compared specifically. Thus the results of these studies performed on rats aged 20±4 months [5] or 30 months [7] are not strictly comparable.

The need for multiple time points in aging studies has been pointed out in earlier research [9]. On the other hand, methodological aspects including the type of explored nerve fibers, the proximity to the neuronal soma, and selected inclusion criteria are of significance in evaluating the aging changes of the peripheral nerves. Severity of morphological alterations is the most pronounced distally [10]. A number of quantitative studies have been demonstrated on the morphological changes that appear in peripheral nerve trunks over time, and have mainly focused on Myelinated nerve Fibers (MF). This is whilst comprehensive, detailed investigations concerned with Unmyelinated Axons (UA), Schwann Cells (SC) and other non-neuronal cells are so limited. Many rare appearances have been described in aged or pathological nerves but an exhaustive ultrastructural study in normal adult and aged nerves is still required.

Aloe vera is a succulent plant with medical benefits and has been used for many years. The plant has a viscous clear gel core. Clinical evaluations have revealed

that some pharmacologically active ingredients are concentrated in both the gel and rind of Aloe vera leaves [11-13]. Aloe vera contains a lot of potentially active constituents, such as: vitamins, enzymes, minerals, sugars, lignin, Saponins, salicylic acids, and amino acids. The pharmacological actions of Aloe vera, are studied in vitro or arthritic activity, and in terms of antibacterial and hypoglycemic effects [13, 14]. The aim of the present work was to evaluate the effects of hydro alcoholic extract of Aloe vera gel on histomorphometric and histologic parameters of Sciatic nerve tissue among aged rats at different time points of the experimental period.

2. Materials and Methods

Animal intervention

Ninety albino Sprague-Dawley adult male rats weighing 200-250 g were received from the Razi Vaccine and Serum Research Institute and housed in a standard condition (25°C temperature and 12 h/12 h light-dark cycle). The rats had been fed a standard rat diet along with the tap water ad libitum. The animals were divided into two groups of control and intervention. We have studied the animals of each group at 16, 20 and 24 months (n=15 at any time point). The animals from the control group received normal diet (subgroup I: 16 months, subgroup III: 20 months, subgroup V: 24 months), whilst 300 mg/kg Aloe vera extract was added to daily diet daily of the experimental group (subgroup II: 16 months, subgroup IV: 20 months, subgroup VI: 24 months).

Tissue processing

At the end of the experimental period, all animals were euthanized by an anesthetic overdose. For dissection purpose, the left Sciatic nerve exposed before dividing into distal branches. Eventually, the animals were euthanized by injecting sodium thiopental overdose.

Histologic and histomorphometric evaluation of sciatic nerve

The separated Sciatic nerves were immersed in glutaraldehyde 4% for 3 to 4 hours, rinsed with buffer, post fixed in osmium tetroxide 1% and dehydrated through a graded ethanol series. The tissue were then placed in a mixture of propylene oxide and TAAB resin (1:1) (TAAB 812, DDSA, MNA, DMP 30) and got transferred into pure resin, afterwards. Semi thin transverse section 2-3 µm thick were cut using a ultramicrotome (Microtome: C. reichert, Austria om U3) and stained with 1%

toluidine blue (fluka) on a 80°C hot plate for 30-45 seconds and 10 slides were obtained from each rat [15].

Connective tissue evaluation of sciatic nerves

Samples were fixed for 24 hours in a 10% formalin solution and phosphate-buffered saline (pH 7.4) at room temperature. The samples were then washed in distilled water, dehydrated in graded ethanol, embedded in paraffin (Merck, Darmstadt, Germany) and cut into 5-mm sections, accordingly. The sections were stained applying Masson's trichrome stain (Sigma-Aldrich, St. Louis, MO, USA) [16]. The following histomorphometric variables were analyzed by Dino software (version 5) for all groups of our study: A. Thickness of myelin sheath; B. Diameter of myelinated nerve fibers; C. Thickness of whole Sciatic nerve; D. Diameter of sciatic nerve Fascicles; E. Nerve fiber area.

Preparation of Aloe vera gel extract

According to the results of previous studies [12] Fresh Aloe vera leaves with approximately 75 to 90 cm length -with slight modifications- were prepared. After cleansing, the leaves were cut transversely into pieces. The viscous gel in the center of the leaves were homogenized. Lyophilization procedure was demonstrated on the homogenate. In the following step, the lyophilized samples were extracted using 95% ethanol and water. The filtrate was vaporized in a rotary evaporator. The intervention group received 400 mg Aloe vera extract per kilogram body weight once daily, to gavage [11].

Statistical analysis

Statistical analysis of the obtained data was performed by SPSS software Version 18. Histomorphometric data were analyzed by ANOVA test at different time points (months 16, 20 and 24) in each group, followed by Post-Hoc Duncan test. Comparison of values between groups

at each time point was demonstrated by student's t-test. $P \leq 0.05$ was considered as significant.

3. Results

Body weight

Changes in body weight among different experimental groups and at different time points (months 16, 20, 24) are shown in Tables 1 and 2. Body weight was significantly decreased at corresponding time points in the experimental groups (subgroups II, IV and VI), compared to the control groups ($P < 0.001$, Table 1).

Morphological aspects

All nerves included in this study showed acceptable structures preservation. One, two or more fascicles were present in the sections, at with equal percentages of previously described [17]. Morphological differences were observed between the groups, not only on the myelinated fibers, but also on the fibers enclosed by endoneurium and perineurium (Figures 1 and 2). Morphologic alterations of the endoneurium of fibers were present in subgroups I and III of the rats in control groups, whilst the same were observed in the most severe condition, in the nerves of the oldest rats (Figure 2, subgroup V). There was an obvious excess of connective tissue correlated with aging with an increase in the connective tissue irregularity.

Also there was morphologic alterations of the myelinated fibers in the control group with the most severe rates in the nerves of the oldest rats (subgroup V) ($P < 0.05$). Main changes consisted of presence of contorted and enfolded myelin sheaths, as well as myelin loops and splitting (Figure 3a). Our results indicated an increased irregularity in myelinated fibers which affected nerve circularity by aging. In addition, myelin thickness decreased and was more evident in large fibers, also some grossly swollen demyelinated fibers were present. Ac-

Table 1. The effects of treatment with Aloe vera hydro alcoholic extract on body weight

Group	Age	Control	Experimental
	16 months	303.4±5 ^{a, b}	248±5.3 ^a
	20 months	341.1±3.9 ^b	262.8±4.3 ^a
	24 months	346.9±4.5 ^b	272.8±4

ANATOMICAL SCIENCES

a: Significant difference were observed between group I, III & V and the animals of the control groups, as well as II and IV subgroups and VI in animals treated with Aloe vera ($P < 0.001$).

b: Our data also revealed significant differences between the same age groups ($P \leq 0.001$) (Mean±SE).

Table 2. Morphometric parameters of sciatic nerves. The diameter of the whole sciatic nerve and its fascicles, nerve fibers and axon, myelin thickness, internodal distance (μm) and nerve fiber area (μm^2) in male rats at the 16th, 20th and 24th month of the experiment

Variables	Groups					
	Control			Intervention		
	16 Months Subgroup I	20 Months Subgroup III	24 Months Subgroup V	16 Months Subgroup II	20 Months Subgroup IV	24 Months Subgroup VI
SN	2008.31±99.8	1823.25±83.9	1604.8±46.8**	2283.72±41 ^a	2116±29.4** ^b	1881.2±17.9*** ^c
F	338.78±46.27	360.74±62	404.4±48.1	665.2±101.4 ^c	512.5±22.6**	340.5±40.03***
NF	8.68±.26	7.69±.13**	6.1±.16***	9.9±.25 ^b	9.3±.14 ^c	8.7±.2*** ^c
MT	3.4±0.07	3.13±.17	2.2±.5***	3.3±.05 ^c	3±.13	2.7±.13*** ^c
NFA	76.2±0.8	67.4±1.2***	53.8±1.2***	93.5±2.8 ^c	79.5±0.7*** ^c	74±1.2*** ^c
AD	3.67±0.18	3.9±.14	2.9±.16***	3.9±.10	3.9±.17	3.3±.12*
IND	46.06±1.6	64.64±3.6	63.7±3.6	64.3±10.4	63.6±1.4	63.8±1.7

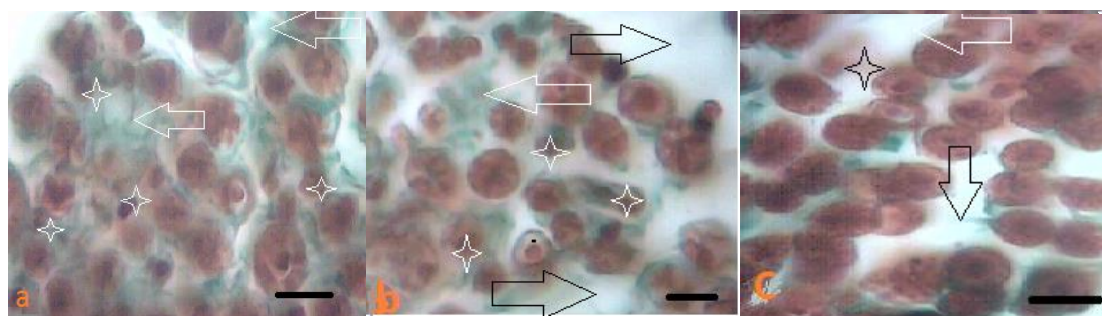
ANATOMICAL SCIENCES

a: Significant differences between subgroups III and V of the of animals in the control group and between subgroups II and IV and VI in animals of the intervention group treated with Aloe Vera; b: Significant differences between groups at same age; ***: Significant differences between subgroups at months 20 and 24 and month 16 subgroup in the control and experimental groups (Mean±SE); SN: Whole sciatic nerve diameter; F: Sciatic Fascicle diameter; NF: Nerve Fiber diameter; MT: Myelin Thickness; NFA: Nerve Fiber Area; AD: Axon Diameter; IND: Inter Nodal Distance

According to our data, large myelinated fibers were affected more ($P < 0.001$).

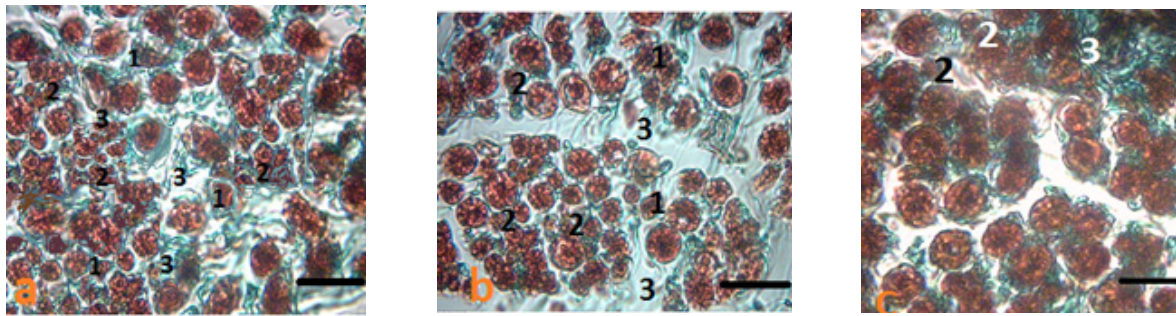
On the light microscopy, semi-thin sections of Sciatic nerve in the rats of the intervention group were compared with the control group rats and consisted of a large number of anomalies; endoneurial swelling along with rupture of nerves, destruction and degeneration of nerve myelin sheath, irregularities in shape and about uncertain results (Figure 3 a, b and 4 a, b). Our findings suggested that, the number of myelinated nerve fibers with myelin folding into axoplasm (in folding) and folds to the my-

elin sheath of Schwann cell cytoplasm (out folding) in the intervention group and a Treatment prolonged for 16 and 24 months with Aloe vera, could reduce and balance all abnormalities in the above-mentioned areas among the control group, to a great extent of progress that prevents the nerve myelinated, abnormal forms increased (Figure 3 a and 4 a) slightly similar to the control group (Figure 3 a and 4 a). As a result, the number of myelinated nerve fibers with myelin abnormalities decreased significantly after receiving treatment with Aloe vera (Figure 3 a and 4 a).



ANATOMICAL SCIENCES

Figure 1. Light photomicrographs of semi thin transverse sections of the Sciatic nerve in the intervention group of 24 (a), 20 (b) and 16 (c) months rats showing stained with Masson's trichrome (a=24 months), (b=20 months), and (c=16 months) rats. The arrow indicates an increasing amount of connective tissue of the endoneurium and perineurium. * Indicates the abnormal fibers (Magnification 400X).



ANATOMICAL SCIENCES

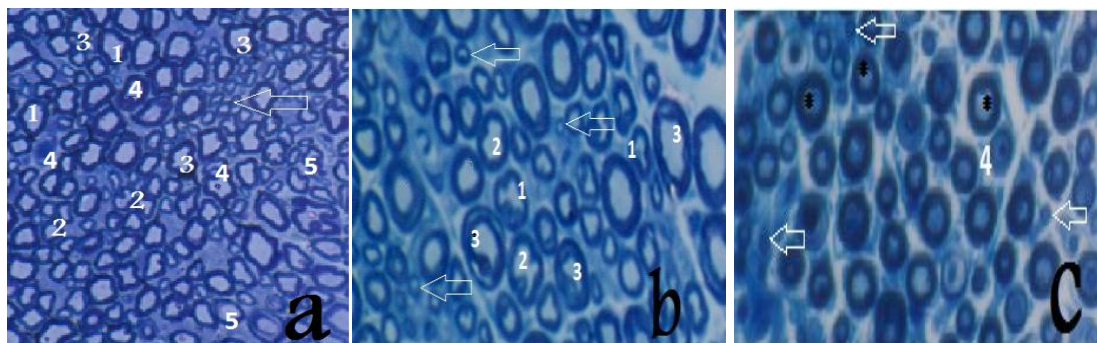
Figure 2. Light photomicrographs of semi thin transverse sections of the Sciatic nerve in control groups stained with Masson's trichrome (a=24 month, b=20 month, and c= 16 month). 1. Irregularity in shape of myelin; 2. Increased small myelinated fibers; and 3. Increased connective tissue on the endoneurium and perineurium were observed in the sections(magnification 400X).

Morphometric aspects

The diameter of whole nerve fiber, sciatic fascicle, myelin thickness, nerve fiber diameter and area, internodal width and axon diameter are all presented in Table 2 in two groups evaluated at months 16, 20 and 24. There was a significant progressive reduction of the whole sciatic nerve diameter , nerve fiber, myelin thickness and nerve fiber area in two groups in respect of aging. The reduction of whole nerve diameter was lower in the group treated by Aloe vera ($P<0.01$ at month 20; $P<0.001$ at month 24). Treatment with Aloe vera caused a significant increase in nerve fiber diameter ,compared to the control group ($P<0.01$ at month 16; $P<0.001$ at months 20 and 24). Myelin thickness was decreased by aging, but treatment has led to improvements in this variable ($P<0.001$ at months 16 and 24). Aging caused a reduction of axon diameter in the control ($P<0.001$ during

months 16 and 24) and the experimental ($P<0.05$ during months 16 and 24) groups; but no significant difference was observed between the studied groups at any time points. Also, our data declared a significant decrease in the nerve fiber area at months 20 and 24 ($P<0.001$) in both groups, which could be concluded that the treatment with Aloe vera caused significant improvement ($P<0.001$ at all time points).

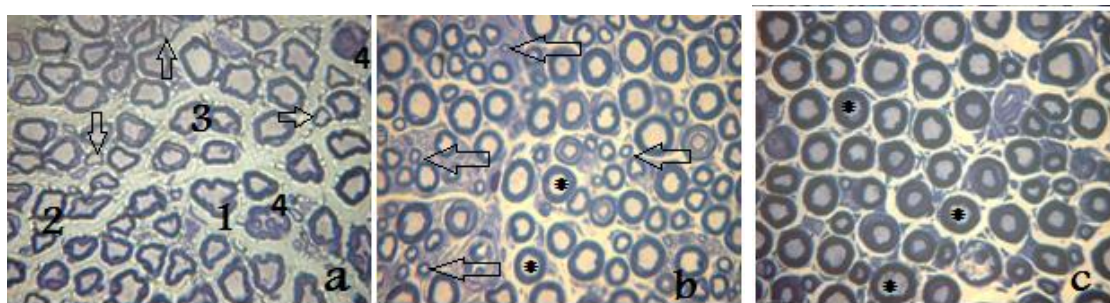
Nerve fascicle measurement showed a significant difference between the control and experimental groups of animals at month 16 ($P<0.001$). In summary, Aging caused a significant increase of this variable, in the intervention group, only. There was no significant changes of internodal distance between both groups during the experimental period. In addition, by aging, rats developed rare age-related pathologies, such as glomerulonephritis and pneumonia (two rats from the control groups).



ANATOMICAL SCIENCES

Figure 3. Light photomicrographs of semi thin transverse sections of the sciatic nerve of Sprague-Dawley male rats in control group at 24th (a), 20th (b) and 16th (c) months showing: 1. Irregularity in shape of myelin; 2. Disruption of myelin density; 3. Enfolding and out folding of myelin; 4. Wallerian degeneration; and 5. Large and small myelinated fiber with very thin myelin sheath. Note that, there are an increase in the number of myelinated fibers with deformed and folded myelin sheaths (enfolding and out folding) and myelin splitting from C (16 months old) to A (24 months old) and B (20 months old) photomicrographs. The arrow indicates the increasing number of nerve fibers with small diameter.

* Indicates the normal fibers. Toluidine blue stained. (Magnification 400X)



ANATOMICAL SCIENCES

Figure 4. Light photomicrographs of semi thin transverse sections of the sciatic nerve of Sprague-Dawley male rats in the intervention group aged 24 (a), 20 (b) and 16 (c) months showing: 1. Irregularity in shape and out folding of myelin; 2. Disruption of myelin density; and 3. Folding of myelin into Axoplasm. Note that, photomicrographs there are an increase in the number of myelinated fibers with deformed and folded myelin sheaths (enfolding and out folding) and myelin splitting from C (16 months old) to A (24 months old) and B (20 months old). In 'a' section , the arrow indicates large and small myelinated fiber with very thin myelin sheath. Number 4 indicates Wallerian degeneration. The arrow in b section, indicates the increasing number of nerve fibers with small diameter. * Indicates the normal fibers (Toluidine blue stained), (Magnification 400X).

Figure 2 light photomicrographs of semi thin transverse sections of the Sciatic nerve in the control groups stained with Masson's trichrome (a=24 months, b=20 months, and c=16 months). 1. Irregularity in shape of myelin; 2. Increased small myelinated fibers; and 3. Increased connective tissue on the endoneurium and perineurium were observed in the sections (magnification 400X).

4. Discussion

Current study investigated the effects of aging on histologic and histomorphometric changes in rat's sciatic nerve. We also examined possible therapeutic effects of Aloe vera gel extract on histologic and histomorphometric changes. Our results have demonstrated that aging was statistically associated with decreased diameter of whole sciatic nerve and nerve fiber, myelin thickness and nerve fiber area. Also, nerve fascicle diameter decreased in the intervention group, only. Our results showed that treatment with Aloe vera has led to an improvements in the Sciatic nerve, nerve diameter and myelin thickness. It is well known that aging phenomenon affects peripheral nerve, both in humans and animal models; and these changes are not linearly correlated with age [1].

Accumulation of collagen in perineurium and myelin deformities were seen in peripheral nerves by aging. The main morphological alterations found in the present study were enfolding and out folding of myelin sheath that increased irregularity of nerve fibers. Some myelin deformities exist in normal nerves such as myelin loops and splitting, relevant with alterations of fiber size [18]. However, the increased frequency of such alterations by aging has been referred to an early response of large fiber myelin sheaths to axonal atrophy [19] as shown by the Morphometric Approach in the present study. These

alterations may reduce conduction velocity of the large myelinated fibers, described for other species [20]. Alteration in myelinated fibers may be a consequence of perfusion deficit of endoneurium that affects Schwann cells function.

Schwann cells numbers are important in the regeneration process, due to their augmented division following stressful conditions such as a trauma [21]. Our results suggested that subgroups II, IV and VI nerves might have been under regeneration, although this process was not sustained in the animals of control subgroups I, III and V nerves. Regeneration process could be impaired by a poor blood supply of the endoneural spaceince, since the blood vessels of control animals were severely damaged (Figure 3 a and 4 a).

The number of fibers in a peripheral nerve is known to be constant during the adulthood lifespan [17, 22, 23], and not correlated with age. On the other hand, it is well known that the myelinated fiber density decreases by development and aging due to the increased amount of the endoneural connective tissue [17, 18, 22]. In the present study, aging increased density of small myelinated fibers and decreased that of large myelinated fibers in the animals of the control groups (Figure 3). Such tendency towards decreasing amount of nerve fibers in subgroups I, III and V was associated with an increase in the amount of the endoneural connective tissue (Figures 1 and 2).

This observation is in line with those regarding the tibial nerves of mice [18] and the sural nerve of female Fisher rats. They did not observe any significant change in the number of myelinated nerve fibers by aging, despite reporting remarkable regeneration in their samples. An important difference between Knox study and ours

is that they have evaluated nerve fibers only, according to their selected method of sampling, whereas whole nerve was investigated in our study. It is well known that nerves with a large population of different size fibers may have a heterogeneous distribution, which could cause a bias in assay [24].

Coleman et al. surveyed aging morphological and functional elements involved in tactile detection, encoding and transmission changes, as well as the skin itself. A combination of several changes contributed to the effect of aging on touch sensation have led to tactile defect with advancing age [9]. Evaluation at different age points, demonstrated that most age-related changes are not necessarily linear, throughout life [1, 18, 25].

Our results revealed an axonal atrophy in the myelinated fibers of the sciatic nerves by aging. This observation ties well with previous studies of the alterations of sural nerve of 60 years old human with disproportionately thick myelin sheaths in small and medium size nerve fibers [26]. Sharma et al. showed reduced average diameter of the myelinated fibers in the tibial and plantar nerves of aged rats.

We have discovered that, morphological alterations were more evident in the large myelinated fibers. These conclusions suggested the presence of a neuropathy due to demyelination in aged rats. As mentioned earlier, decreased number of large myelinated nerve fibers were associated with increased endoneurial connective tissue. Esquisatto et al. investigated structure and composition of sciatic extracellular matrix in rats by aging and observed the most changes in perineurium. Biochemical analyses showed highest rates of non-collagenous proteins accumulations in aged rats (730 days old) and levels of MMP2 and MMP9 enzyme were also high in those rats [27].

Romanovsky et al. declared that density of medium and large sized nerve fibers of dorsal root ganglia that are a3NaK positive decreased significantly by aging. This phenomenon could lead to tendon reflex impairment as an important factor in falling and postural disability in the elderly population. Failure of muscle spindles afferent by aging may contribute to such reflex disturbance. [28].

Our results provided evidence for preventive effects on some morphometric parameters of Sciatic nerve tissue in aged rats receiving hydro alcoholic extract Aloe vera gel. Aloe vera is among few medical plants with a long-term popularity. Clinical evaluations have revealed that the

pharmacologically active ingredients are concentrated in both the gel and rind of Aloe vera leaves [12].

Nagamatsu showed that an increased ROS generation in nerve ischemia, like hydrogen peroxide is accompanied with damages to nerve fibers [29]. Aloe vera extracts have antioxidants compounds like vitamins E and C with the potential to reduce blood lipids in people who suffer from diabetes [11]. Ghaffari et al. have documented that Aloe vera can reduce blood sugar, and may exert a protective effect on the vulnerable tissues, as an antioxidant [30]. Also, prior research identified beneficial effects of Aloe vera on carbohydrate metabolism and optic nerve structure in diabetic rats [31].

Guyen et al. investigated neuroprotective effects of Aloe vera in ischemia reperfusion mediated injury of sciatic nerve and indicated that it caused significant decrease in pathologic changes of the nerve via antioxidant and anti-inflammatory effect as compared with methylprednisolone [32]. Lopez jorner et al. found that application of Aloe vera gel topically decreased burns and pain sensation in patients suffered from burning tongue syndrome [33].

The present study confirmed that consumption of Aloe vera could ameliorate some degenerative process, as per mentioned above, in the sciatic nerve of aged rats. Nevertheless, the morphometric approach used in the present study revealed the existence of an axonal neuropathy, mainly of large myelinated fibers. In conclusion, the present study indicated that consuming Aloe vera could delay the process of neuropathy aging in the Sciatic nerve of male rats.

In the current study, we observed some alterations in sciatic nerve caused by aging, such as accumulation of collagen in perineurium and endoneurium. Also, a significant decrease was seen in nerve fibers, nerve trunks diameter and myelin thickness which were highly evident in rats of the 24 months age group. Treatment with Aloe vera gel extract improved histological changes and retarded neuropathy signs, significantly.

Ethical Considerations

Compliance with ethical guidelines

The study was performed in accordance with the guidelines of National Institute of Health for the care and use of laboratory animals.

Funding

This research did not receive any specific grant from funding agencies in the public, commercial, or not-for-profit sectors.

Authors contributions

All authors have read and approved the manuscript.

Conflict of interest

The authors declare no conflict of interest.

Acknowledgement

We would like to sincerely thank Dr. khodakaram Tafti for pathological examination of specimens.

References

- [1] Verdú E, Ceballos D, Vilches JJ, Navarro X. Influence of aging on peripheral nerve function and regeneration. *Journal of the Peripheral Nervous System*. 2000; 5(4):191-208. [DOI:10.1046/j.1529-8027.2000.00026.x] [PMID]
- [2] Mold JW, Vesely SK, Keyl BA, Schenk JB, Roberts M. The prevalence, predictors, and consequences of peripheral sensory neuropathy in older patients. *The Journal of the American Board of Family Practice*. 2004; 17(5):309-18. [DOI:10.3122/jabfm.17.5.309] [PMID]
- [3] Verghese J, Bieri P, Gellido C, Schaumburg H, Herskovitz S. Peripheral neuropathy in young-old and old-old patients. *Muscle & Nerve*. 2001; 24(11):1476-81. [DOI:10.1002/mus.1171] [PMID]
- [4] Hashizume K, Kanda K. Differential effects of aging on motoneurons and peripheral nerves innervating the hindlimb and forelimb muscles of rats. *Neuroscience Research*. 1995; 22(2):189-96. [DOI:10.1016/0168-0102(95)00889-3]
- [5] Majeed S. Survey on spontaneous peripheral neuropathy in aging rats. *Arzneimittel-Forschung*. 1992; 42(7):986-90. [PMID]
- [6] Melcangi R, Magnaghi V, Cavarretta I, Martini L, Piva F. Age-induced decrease of glycoprotein Po and myelin basic protein gene expression in the rat sciatic nerve: Repair by steroid derivatives. *Neuroscience*. 1998; 85(2):569-78. [DOI:10.1016/S0306-4522(97)00628-3]
- [7] Knox CA, Kokmen E, Dyck PJ. Morphometric alteration of rat myelinated fibers with aging. *Journal of Neuro pathology & Experimental Neurology*. 1989; 48(2):119-39. [DOI:10.1097/00005072-198903000-00001]
- [8] Verdú E, Butí M, Navarro X. Functional changes of the peripheral nervous system with aging in the mouse. *Neurobiology of Aging*. 1996; 17(1):73-7. [DOI:10.1016/0197-4580(95)02010-1]
- [9] Coleman P, Finch C, Joseph J. The need for multiple time points in aging studies. *Neurobiology of Aging*. 1990; 11(1):1-2. [DOI:10.1016/j.neurobiolaging.2003.10.002]
- [10] Thomas P, King R, Sharma A. Changes with age in the peripheral nerves of the rat. *Acta Neuropathologica*. 1980; 52(1):1-6. [DOI:10.1007/BF00687222] [PMID]
- [11] Rajasekaran S, Ravi K, Sivagnanam K, Subramanian S. Beneficial effects of Aloe vera leaf gel extract on lipid profile status in rats with streptozotocin diabetes. *Clinical and Experimental Pharmacology and Physiology*. 2006; 33(3):232-7. [DOI:10.1111/j.1440-1681.2006.04351.x] [PMID]
- [12] Rajasekaran S, Sivagnanam K, Subramanian S. Antioxidant effect of Aloe vera gel extract in streptozotocin-induced diabetes in rats. *Pharmacological Reports*. 2005; 57(1):90-6. [PMID]
- [13] Vogler B, Ernst E. Aloe vera: A systematic review of its clinical effectiveness. *British Journal of General Practice*. 1999; 49(447):823-8. [PMID] [PMCID]
- [14] Sahu PK, Giri DD, Singh R, Pandey P, Gupta S, Shrivastava AK, et al. Therapeutic and medicinal uses of Aloe vera: A review. *Pharmacology & Pharmacy*. 2013; 4(08):599. [DOI:10.4236/pp.2013.48086]
- [15] Bozzola JJ, Russell LD. *Electron microscopy: Principles and techniques for biologists*. Burlington, Massachusetts: Jones & Bartlett Learning; 1999.
- [16] Tseng H, Lin SE, Chang YL, Chen MH, Hung SH. Determining the critical effective temperature and heat dispersal pattern in monopolar radiofrequency ablation using temperature-time integration. *Experimental and Therapeutic Medicine*. 2016; 11(3):763-8. [DOI:10.3892/etm.2015.2956] [PMID] [PMCID]
- [17] Jeronimo A, Jeronimo CAD, Sanada LS, Fazan VPS. Microscopic anatomy of the sural nerve in the postnatal developing rat: A longitudinal and lateral symmetry study. *Journal of Anatomy*. 2005; 206(1):93-9. [DOI:10.1111/j.0021-8782.2005.00368.x] [PMID] [PMCID]
- [18] Ceballos D, Cuadras J, Verdú E, Navarro X. Morphometric and ultrastructural changes with ageing in mouse peripheral nerve. *Journal of Anatomy*. 1999; 195(4):563-76. [DOI:10.1046/j.1469-7580.1999.19540563.x] [PMID] [PMCID]
- [19] Krinke G, Froehlich E, Herrmann M, Schnider K, Da Suva F, Suter J, et al. Adjustment of the myelin sheath to axonal atrophy in the rat spinal root by the formation of infolded myelin loops. *Cells Tissues Organs*. 1988; 131(3):182-7. [DOI:10.1159/000146510]
- [20] Peters A. The effects of normal aging on myelin and nerve fibers: A review. *Journal of Neurocytology*. 2002; 31(8-9):581-93. [DOI:10.1023/A:1025731309829] [PMID]
- [21] Jeronimo A, Jeronimo CAD, Rodrigues Filho OA, Sanada LS, Fazan VPS. A morphometric study on the longitudinal and lateral symmetry of the sural nerve in mature and aging female rats. *Brain Research*. 2008; 1222:51-60. [DOI:10.1016/j.brainres.2008.05.055] [PMID]
- [22] Schellens RL, van Veen BK, Gabreëls-Festen AA, Notermans SL, van't Hof MA, Stegeman DF. A statistical approach to fiber diameter distribution in human sural nerve. *Muscle & Nerve*. 1993; 16(12):1342-50. [DOI:10.1002/mus.880161212] [PMID]

- [23] Berthold C, Carlstedt T, Corneliussen O. Anatomy of the nerve root at the central-peripheral transitional region. *Peripheral Neuropathy*. 1984; 1:156-70.
- [24] Romero E, Cuisenaire O, Deneff J-F, Delbeke J, Macq B, Veeraart C. Automatic morphometry of nerve histological sections. *Journal of Neuroscience Methods*. 2000; 97(2):111-22. [DOI:10.1016/S0165-0270(00)00167-9]
- [25] Bouche P, Cattelin F, Saint-Jean O, Leger J, Queslati S, Guez D, et al. Clinical and electrophysiological study of the peripheral nervous system in the elderly. *Journal of Neurology*. 1993; 240(5):263-8. [DOI:10.1007/BF00838158] [PMID]
- [26] Jacobs J, Love S. Qualitative and quantitative morphology of human sural nerve at different ages. *Brain*. 1985; 108(4):897-924. [DOI:10.1093/brain/108.4.897] [PMID]
- [27] Esquisatto MAM, de Aro AA, Fêo HB, Gomes L. Changes in the connective tissue sheath of Wistar rat nerve with aging. *Annals of Anatomy-Anatomischer Anzeiger*. 2014; 196(6):441-8. [DOI:10.1016/j.aanat.2014.08.005] [PMID]
- [28] Romanovsky D, Mrak RE, Dobretsov M. Age-dependent decline in density of human nerve and spinal ganglia neurons expressing the $\alpha 3$ isoform of Na/K-ATPase. *Neuroscience*. 2015; 310:342-53. [DOI:10.1016/j.neurosci.2015.09.034] [PMID] [PMCID]
- [29] Nagamatsu M, Schmelzer JD, Zollman PJ, Smithson IL, Nickander KK, Low PA. Ischemic reperfusion causes lipid peroxidation and fiber degeneration. *Muscle & Nerve*. 1996; 19(1):37-47. [DOI:10.1002/mus.880190103] [PMID]
- [30] Ghaffari H, Gholami S, Naghdi M. Histologic and histomorphometric study of tibial nerve treated by hydro-alcoholic Aloe vera gel extract in diabetic male rats. *Anatomical Sciences Journal*. 2013; 10(2):63-72.
- [31] Saberi M, Gholami S. An investigation on the effects of the Aloe vera extract on the thickness of the retina in male diabetic rats. *Iranian Journal of Veterinary Research*. 2012; 13(4):296-302.
- [32] Guven M, Gölge UH, Aslan E, Sehitoglu MH, Aras AB, Akman T, et al. The effect of Aloe vera on ischemia – Reperfusion injury of sciatic nerve in rats. *Biomedicine & Pharmacotherapy*. 2016; 79:201-7. [DOI:10.1016/j.biopha.2016.02.023] [PMID]
- [33] López Jornet P, Camacho Alonso F, Molino Pagan D. Prospective, randomized, double-blind, clinical evaluation of Aloe vera *Barbadensis*, applied in combination with a tongue protector to treat burning mouth syndrome. *Journal of Oral Pathology & Medicine*. 2013; 42(4):295-301. [DOI:10.1111/jop.12002] [PMID]