

Original Article

Clinical and histological response of human pulp tissue to direct pulp capping with mineral trioxide aggregate, Biodentine and propolis

Zahra Nasri¹, Maryam Zare Jahromi¹, Atousa Aminzadeh²

Departments of ¹Endodontic and ²Oral Pathology, School of Dentistry, Isfahan (Khorasgan) Branch, Islamic Azad University, Isfahan, Iran

ABSTRACT

Background: This study clinically and histologically compared the human pulp response to direct pulp capping (DPC) with mineral trioxide aggregate (MTA), Biodentine, and propolis in 2 months. **Materials and Methods:** In this clinical trial evaluated 41 premolars candidate for extraction due to orthodontic purposes of patients between 15 and 25 years of age. A group of 5 was separated randomly as the negative control. The remaining teeth were randomly divided into three experimental groups of 12 after mechanical exposure of the pulp by bur in high-speed handpiece under air and water spray. The exposed areas were capped with MTA, Biodentine, or propolis. Glass ionomer was applied as base over the cap. The teeth were restored with composite resin. Patients were recalled in 2 months for clinical and radiographic examinations and also pulp vitality test. Teeth were then extracted. Slides were prepared and tissue sections were evaluated for the presence and severity of inflammation, dentinal bridge, and continuity. Data were analyzed using the Chi-square and Fisher's exact tests.

Results: The clinical success rate was 100% in the MTA and 91.7% in both the propolis and Biodentine groups. The presence and severity of pulpal inflammation and dentinal bridge formation were similar in all the experimental groups ($P > 0.05$). Dentinal bridge formation was similar in the MTA and Biodentine groups and was higher than in the propolis group. Continuation of dentinal bridge in the MTA group was significantly higher than that in the Biodentine and propolis groups ($P < 0.05$).

Conclusion: MTA, Biodentine, and propolis are equally effective for DPC.

Key Words: Biodentine, direct pulp capping, mineral trioxide aggregate, propolis

Received: 28-Jan-2020
Revised: 02-Jul-2020
Accepted: 09-Nov-2021
Published: 27-Apr-2022

Address for correspondence:

Dr. Maryam Zare Jahromi,
Department of Endodontic,
Isfahan (Khorasgan) Branch,
Islamic Azad University,
Arghavanieh, Jey Street,
Isfahan, Iran.
E-mail: m.zare@khuif.ac.ir

INTRODUCTION

Vital pulp therapy preserves the vitality of the pulp exposed to the oral environment due to trauma, caries, restorative treatments, or anatomical anomalies. It can also be performed for permanent teeth with reversible pulpitis.^[1] Pulp tissue, similar to other connective tissues, can heal. Regeneration of exposed pulp includes regeneration and reorganization of the

injured tissue and differentiation of odontoblast-like cells of the subodontoblastic cell-rich layer leading to repair of dentin by the formation of dentinal bridge at the site of pulp exposure.^[2] The main goal of vital pulp therapy is to induce the formation of reparative tertiary dentin or a calcified bridge to close

This is an open access journal, and articles are distributed under the terms of the Creative Commons Attribution-NonCommercial-ShareAlike 4.0 License, which allows others to remix, tweak, and build upon the work non-commercially, as long as appropriate credit is given and the new creations are licensed under the identical terms.

For reprints contact: WKHLRPMedknow_reprints@wolterskluwer.com

How to cite this article: Nasri Z, Jahromi MZ, Aminzadeh A. Clinical and histological response of human pulp tissue to direct pulp capping with mineral trioxide aggregate, Biodentine and propolis. Dent Res J 2022;19:40.

Access this article online	
	Website: www.drj.ir www.drjjournal.net www.ncbi.nlm.nih.gov/pmc/journals/1480

Archive of SID

the exposure site. This is, particularly important for saving permanent teeth with immature roots, keeping the integrity of dental arch during maxillofacial development.^[3]

Direct pulp capping (DPC) is a type of vital pulp therapy, in which a biocompatible dental material covers and seals the vital pulp at the site of exposure (mechanical or due to caries) in order to induce reparative dentin formation and preserve the pulp vitality.^[4]

A number of materials have been proposed for DPC. Calcium hydroxide has long been used for this purpose.^[5] However, remaining a tunnel-shaped defect in the formed dentinal bridge, high solubility in oral fluids, no adhesion properties, and dissolving by acid in etching process are some of the limitations in using calcium hydroxide compounds. Due to these limitations, new materials have been proposed for DPC.^[6] Evidence shows that mineral trioxide aggregate (MTA) can be used as an alternative to calcium hydroxide. MTA induces the formation of dentinal bridge faster than calcium hydroxide.^[7] It has optimal biocompatibility, bioactivity and antibacterial properties, unique stability, and high sealing ability.^[8] However, evidence shows that MTA has drawbacks such as long setting time, difficult handling, high cost, and tooth discoloration.^[9,10] Some modifications were made to improve the properties of MTA and shortening its setting time. Adding calcium chloride to MTA elevated its pH, shortened its setting time, and improved its mechanical properties.^[11,12] White MTA was introduced to prevent tooth discoloration.^[10] However, white MTA has a setting time slower than the gray one.^[13]

Biodentine is a new calcium silicate-based restorative cement with the mechanical properties similar to dentin. It can be used as a substitute for dentin in crown and root and has the applications similar to MTA. It has a positive effect on vital pulp cells and induces the formation of tertiary dentin.^[14,15] Biodentine is prepared by mixing a powder and a liquid. The powder consists of tricalcium silicate, dicalcium silicate, calcium carbonate, and zirconium dioxide. The liquid is calcium chloride, which accelerates the setting time.^[14] The consistency of Biodentine is similar to that of phosphate cement. It can be directly applied over the exposure site as a substitute for the lost dentin.^[14,15]

Recently, propolis has increasingly become the focus of interest in dentistry. It is produced by the

honey bees and has antibacterial properties.^[16] It is composed of 50% balsam resin, 30% wax, 10% aromatic oils, 5% pollens, and 5% organic debris depending on the location, weather, season, and time of collection.^[17,18] Thus, it does not have a constant ingredient.^[18] Flavonoids are the most important active component in propolis which have anti-oxidative, antibacterial, antifungal, antiviral, and anti-inflammatory properties.^[19]

Considering the significance of the type of pulp-capping agent in DPC, this study aimed to clinically and histologically assess the response of pulp tissue of premolars to DPC by propolis, MTA, and Biodentine.

MATERIALS AND METHODS

This randomized clinical trial (IR.IAU.KHUIF.REC.1398.064) evaluated 41 sound premolars of 12 patients between 15 and 25 years of age referred to the Department of Orthodontics, School of Dentistry, Islamic Azad University, Isfahan, Iran, and a private clinic. The teeth had the criteria for DPC and were candidate for extraction due to orthodontic purposes.

Sample size was calculated to be 12 in each group considering alpha = 0.05, beta = 0.2, and power of 80%.

The inclusion criteria were general health, absence of systemic disease, taking no medications, sound permanent premolars with closed apices, and no carious lesions, normal response to pulp vitality tests (cold, heat, percussion, and touch) before treatment, no periodontal disease and no periapical lesions on periapical radiographs, and signing informed consent forms before participation in the study.

The exclusion criteria were open apex teeth, pathological periapical changes with endodontic origin, pulp calcification, discontinuation of lamina dura, widening of periodontal ligament, and patients unwilling to participate in the study.

The patients were asked to show up in 8 weeks of treatment for clinical examination and extraction of premolars. Initial radiographs of the patients showed no contraindication for DPC.

A group of 5 was separated randomly as the negative control which received no treatment.

The crowns of experimental teeth were rinsed with 2% chlorhexidine. A rubber dam was then placed after anesthetizing the teeth with 1.8 ml 2% xylocaine

Archive of SID

lidocaine and 1:100,000 epinephrine. A Class I cavity was prepared using a sterile round diamond bur (#801) in high-speed handpiece under air and water spray, and the pulp was exposed with approximately 1.2 mm diameter using the same bur. A new bur was used for each tooth. Bleeding of the pulp at the exposure site was controlled by a moistened cotton with saline for 5 min. The teeth were then randomly based on the case number divided randomly based on the case number into three experimental groups of 12.

In Group 1, the exposed pulp was covered and sealed with a mixture of 100% propolis and 70% ethyl alcohol in the consistency of a thick paste.

In Group 2, the exposed pulp was covered with ProRoot MTA (Dentsply, Switzerland) prepared according to the manufacturer's instructions (3:1 ratio). The mixture was kept wet and condensed lightly by a moistened sterile cotton pellet to reach a thickness of 2–3 mm. The teeth were restored in the same session. In Group 3, Biodentine (Septodont, France) was prepared according to the manufacturer's instructions such that the liquid was mixed with the powder in an amalgamator for 30 s. The paste was then applied over the exposure site.

Resin-modified glass-ionomer cement was applied as the base on the pulp-capping agent in all the three experimental groups before restoring the cavity with composite resin. The teeth were then radiographed. All procedures were performed by the same operator. Patients received no medications postoperatively.

Patients were recalled in 8 weeks to ask about posttreatment tooth hypersensitivity or pain. Clinical examinations including thermal and electric pulp tests were performed to assess the pulp status. The teeth were radiographed with parallel technique and the same angulation of preoperative ones to assess the pulp status [Figures 1-3]. Pre- and postoperative radiographs were evaluated by one endodontist.

Data were entered in a table to compare responses before and after the procedure to assess the clinical success of DPC treatment. The teeth with normal response to pulp vitality and electric pulp tests, no radiographic evidence of periapical problem, and no complaint of stimulated or spontaneous pain were considered normal. The teeth were extracted less traumatically by forceps with rotational movement under local anesthesia following using periostom to cut periodontal fibers.

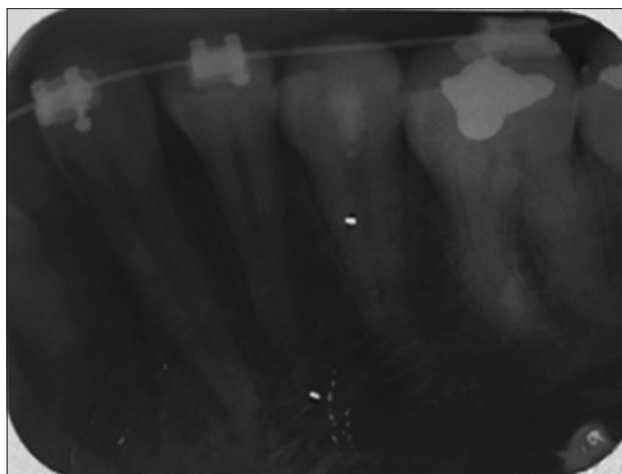


Figure 1: Radiograph immediately before extraction. Direct pulp capping with propolis.

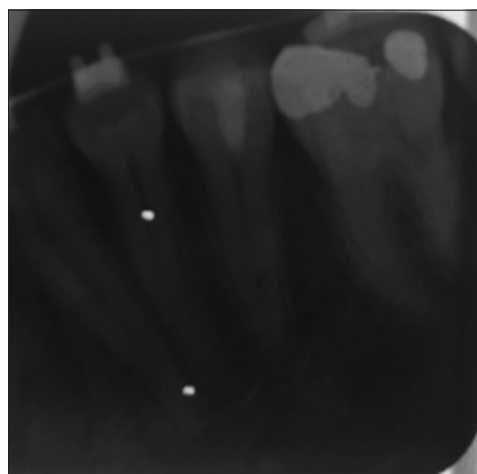


Figure 2: Radiograph immediately before extraction. Direct pulp capping with Biodentine.

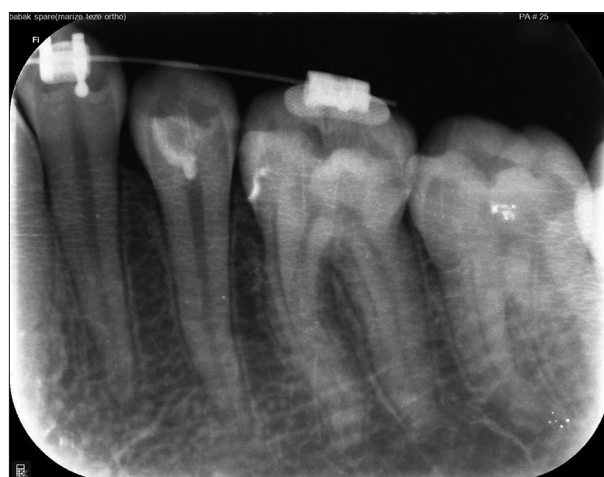

Figure 3: Radiograph immediately before extraction. Direct pulp capping with mineral trioxide aggregate.

Extracted teeth were immersed in 10% buffered formalin for 2 weeks and then in 10% nitric acid

Archive of SID

for 12 days to decalcify tooth structure. The teeth were longitudinally sectioned into two equal halves. Following routine and paraffin processing, 6 μ m thick sections were prepared by a microtome and stained by hematoxylin and eosin. Histological analysis was performed in three microscopic fields under E100 Clips light microscope (Nikon, Japan) at x400 magnification by two pathologists in a single-blind fashion [Figures 4-6]. The presence and severity of inflammation and the quality of dentinal bridge were evaluated. In terms of severity of inflammation, the samples were assigned to the following groups:

- Absence of inflammation: Presence of 0–10 inflammatory cells
- Mild inflammation: Presence of 10–30 inflammatory cells
- Moderate inflammation: Presence of 30–60 inflammatory cells
- Severe inflammation: Presence of >60 inflammatory cells.

The presence/absence of dentinal bridge and its continuation were also evaluated.

Data were analyzed using the Chi-square test and Fisher's exact test. All statistical analyses were carried out using SPSS (version 21.0. Armonk, NY, USA: IBM Corp.).

RESULTS

Clinical findings

In terms of pulp vitality, 11 out of 12 patients in each of the experimental groups had no clinical and radiographic signs or symptoms such as persistent pain, abscess, fistula, radiolucency, or mobility. Only one patient in each group reported mild posttreatment pain, which was resolved within the same day with no need of analgesic. Clinical pulp vitality tests in all the three experimental groups were similar to the control group preoperatively but in 11 patients in each group postoperatively (91.7%). Only one patient in the Biodentine and one in the propolis group had negative cold and heat tests, but their electric pulp test was positive; however, since they did not have any complaint, a definite conclusion regarding pulp necrosis or any other condition could not be drawn. All samples in all the three experimental groups (100%) had a normal reaction to cold, heat, and electric pulp tests and had no sensitivity to percussion, touch, and pain preoperatively. After treatment, 11 samples (91.7%) in each of the propolis

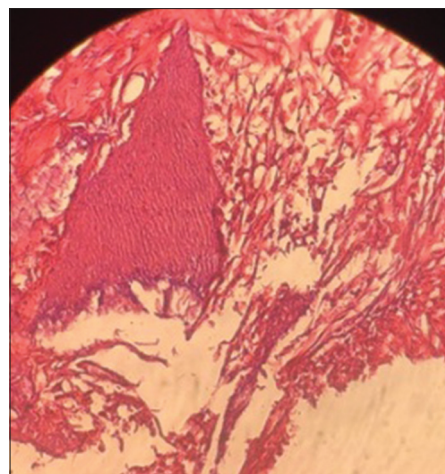


Figure 4: Continuous dentinal bridge including dentinal tubules in direct pulp capping with mineral trioxide aggregate.

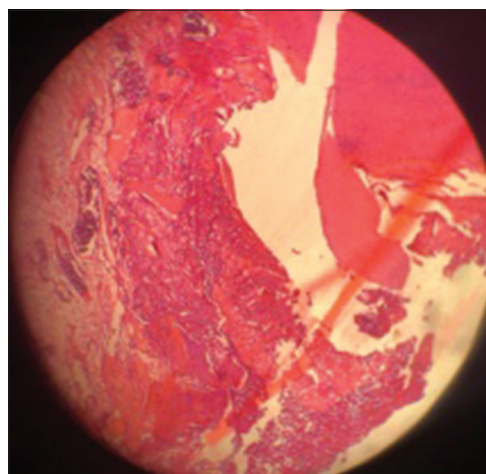


Figure 5: Scattered calcification in congestive pulp in direct pulp capping with propolis.

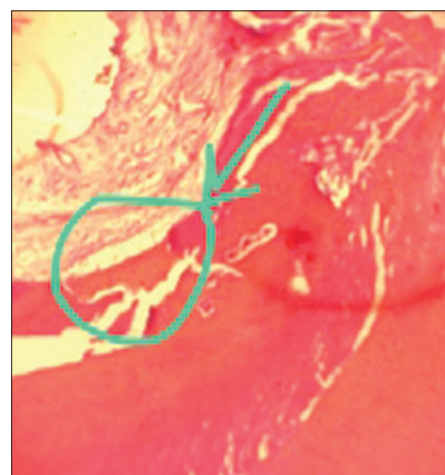

Figure 6: Discontinuous dentinal bridge in direct pulp capping with Biodentine.

and Biodentine groups, and 100% of samples in the MTA group had the same signs and symptoms

Archive of SID

as normal. Table 1 compares propolis, MTA, and Biodentine in terms of clinical signs and symptoms.

Histological findings

In terms of the presence/absence of inflammation, no inflammation was noted in the control group. Of all samples, 4 (33.3%) in the propolis group, 2 (16.7%) in the MTA group, and 6 (50%) in the Biodentine group had pulpal inflammation. A maximum number of samples with pulpal inflammation were noted in the Biodentine group while minimum in the MTA group. No significant difference was noted in the presence of pulpal inflammation among the three experimental groups ($P > 0.05$).

Table 2 shows the severity of inflammation in the three groups. The maximum level of inflammation was noted in the Biodentine group and minimum in the MTA group. No significant difference was noted in severity of inflammation among the three experimental groups ($P = 0.223$).

In terms of dentinal bridge formation, no dentinal bridge was noted in the control group. The frequency of dentinal bridge formation was the same in the MTA and Biodentine groups (83.3%). This rate was lowest (58.3%) in the propolis group. The difference among the three groups was not significant ($P > 0.05$).

In terms of continuity of dentinal bridge, no dentinal bridge was formed in the control group. The presence of a continuous dentinal bridge was significantly higher in the MTA (70%) group compared to the propolis (14.3%) and Biodentine (10%) groups ($P = 0.050$ for the comparison of MTA and propolis and $P = 0.020$ for the comparison of MTA and Biodentine), but the difference between the Biodentine and propolis groups was not significant ($P = 1.00$).

DISCUSSION

This clinical trial compared clinically and histologically the human pulp tissue response to DPC with MTA, Biodentine, and propolis in 2 months. Regarding the results of the present study [Table 1], it seems that DPC with propolis, MTA, and Biodentine was clinically successful. Our results were in agreement with those of Kusum *et al.*,^[20] who studied the clinical success of pulpotomy on 75 primary teeth with propolis, MTA, and Biodentine in 3, 6, and 9 months. They reported a 100% success rate in all the three groups in 3 and 6 months. Moreover, 100% success rate in the MTA and Biodentine groups in

Table 1: Comparison of propolis, mineral trioxide aggregate, and Biodentine in terms of clinical signs and symptoms of patients

Variable	Propolis, n (%)	MTA, n (%)	Biodentine, n (%)	P
Cold (positive)				
Before treatment	12 (100.0)	12 (100.0)	12 (100.0)	1.000
After treatment	11 (91.7)	12 (100.0)	11 (91.7)	0.598
P	0.317	1.000	0.317	
Heat (positive)				
Before treatment	12 (100.0)	12 (100.0)	12 (100.0)	1.000
After treatment	11 (91.7)	12 (100.0)	11 (91.7)	0.598
P	0.317	1.000	0.317	
Touch (negative)				
Before treatment	12 (100.0)	12 (100.0)	12 (100.0)	1.000
After treatment	12 (100.0)	12 (100.0)	12 (100.0)	1.000
P	1.000	1.000	1.000	
Percussion (negative)				
Before treatment	12 (100.0)	12 (100.0)	12 (100.0)	1.000
After treatment	12 (100.0)	12 (100.0)	12 (100.0)	1.000
P	1.000	1.000	1.000	
Pulp tester (positive)				
Before treatment	12 (100.0)	12 (100.0)	12 (100.0)	1.000
After treatment	12 (100.0)	12 (100.0)	12 (100.0)	1.000
P	1.000	1.000	1.000	
Pain (negative)				
Before treatment	12 (100.0)	12 (100.0)	12 (100.0)	1.000
After treatment	11 (91.7)	11 (91.7)	11 (91.7)	0.598
P	0.317	0.317	0.317	

MTA: Mineral trioxide aggregate

Table 2: Severity of inflammation in the three groups (n=12)

Severity of inflammation	Propolis, n (%)	MTA, n (%)	Biodentine, n (%)
No inflammation	8 (66.7)	10 (83.3)	6 (50.0)
Mild	3 (25.0)	1 (8.3)	3 (25.0)
Moderate	0	1 (8.3)	2 (16.7)
Severe	1 (8.3)	0	1 (8.3)

MTA: Mineral trioxide aggregate

9 months. However, the success rate in the propolis group decreased to 84% in 9 months.

Our clinical findings were in agreement with those of Nowicka *et al.*^[21] They compared MTA and Biodentine pulp-capping agents in sound molars and reported spontaneous pain in 7 patients (four in the Biodentine group and three in the MTA group) in 6 weeks of follow-up. Other patients did not report any specific symptom. Furthermore, our clinical findings were in line with those of Katge and Patil^[22] who compared DPC with MTA and Biodentine. They reported a 100% success rate in 6 and 12 months in both the groups.

The presence and severity of inflammation in this study are summarized in Table 2.

The anti-inflammatory properties of Biodentine and MTA are related to the alkalinity of them.^[23,24] Low inflammation in the propolis group is related to the presence of flavonoids and caffeic acid in its composition which plays an important role in decreasing the inflammatory response by inhibiting the lipoxygenase pathway; moreover, these agents reinforce the immune system by enhancing phagocytosis and stimulating the cell immunity.^[24] The lower level of inflammation in the MTA group compared to Biodentine might be attributed to the higher sealing ability of MTA and higher solubility of Biodentine.^[25] Nowicka *et al.*^[21] reported the same results for MTA and Biodentine. They showed the superior anti-inflammatory properties of MTA to Biodentine although this difference was not significant in their study and ours. They found no significant difference in severity of inflammation between the two groups which was in line with our results. Parolia *et al.*^[26] histologically evaluated the pulp response of premolars to propolis, MTA, and Dycal in 15 and 45 days. In 15 days, inflammation was lower in the MTA than the propolis group, and inflammation in the propolis group was lower than that in the Dycal group. In 45 days, inflammation subsided in both the MTA and propolis groups which were in agreement with our findings. Jalan *et al.*^[27] evaluated the human pulp response to DPC with Dycal and Biodentine. In 45 days, no or really mild inflammation was noted in the Biodentine group. In the calcium hydroxide group, mild inflammation was noted in 5 out of 20 teeth while the remaining 15 had no inflammation. Although the differences were not significant, they suggested Biodentine as an alternative to calcium hydroxide.

In our study, dentinal bridge was formed in 58.3% of teeth in the propolis group and 83.3% in the MTA and Biodentine groups. In terms of integrity and continuity of the formed dentinal bridge, only one (10%) sample of the propolis group dentinal bridge had continuity. This value was 7 (70%) in the MTA group and 1 (10%) in the Biodentine group. Dentinal bridge formation might be due to the release of hydroxyapatite from Biodentine and MTA. Furthermore, its formation adjacent to MTA and Biodentine might be attributed to their alkaline pH.^[28-30] Evidence shows that dentinal bridge formation in the use of propolis contributes to the stimulation of different enzyme systems, cell

metabolism, and collagen formation.^[26] Another study reported that in the Biodentine, MTA, and propolis groups, stimulation of transforming growth factor beta-1 is a key factor for differentiation of odontoblasts and fabrication of reparative dentin.^[20] Another study showed that MTA causes odontogenic differentiation of pulp cells and formation of dentinal bridge.^[31] However, the exact mechanism of dentinal bridge formation has not yet been elucidated. It seems that Biodentine and MTA have the advantage of releasing hydroxyapatite, which contributes to the greater dentinogenesis, compared with propolis. It has been shown that cell viability in the presence of MTA is slightly (but not significantly) higher than that in the presence of Biodentine.^[32] Another study showed that solubility of Biodentine is higher than that of MTA. Moreover, sealing ability is an important factor in success of DPC and formation of dentinal bridge, which is lower in Biodentine compared to MTA.^[33]

Another controversy arises from the belief of some authors that adding calcium chloride to MTA enhances dentinogenesis while some others believe that it has no effect or has an adverse effect on this process.^[21] This may explain the poorer continuity of dentinal bridge in the Biodentine group in our study. Our results were in agreement with those of Nowicka *et al.*,^[21] who reported the formation of a continuous dentinal bridge in 7 out of 11 teeth (4 dentinal bridges were noncontinuous) while this rate was 6 out of 11 teeth in the Biodentine group (5 dentinal bridges were noncontinuous). Parolia *et al.*^[26] evaluated dentinal bridge formation in three groups of propolis, MTA, and Dycal. They reported the results similar to ours in 15 days. However, in 45 days, dentinal bridge had formed in all teeth in the propolis and MTA groups. They reported that the formation of dentinal bridge may increase over time. If we had also scheduled a longer follow-up, the frequency and thickness of formed dentinal bridges might have increased. Moradi *et al.*^[34] in their study on dogs evaluated the expression of fibronectin, indicating dentinal bridge formation, in response to MTA, propolis, and platelet-rich plasma. They reported that the rate of fibronectin expression in 30 days was significantly higher than that in 7 days. Furthermore, fibronectin expression in the MTA group was higher than that in propolis, indicating greater formation of dentinal bridge in the MTA group; this finding was similar to our result. Jalan *et al.*^[27] compared Biodentine and calcium hydroxide in terms of dentin formation and

Archive of SID

showed the formation of dentin in 80% of Biodentine and 20% of Dycal samples, which highlighted the superiority of Biodentine over calcium hydroxide. The results of the present study are similar to those of Awawdeh *et al.* who compared Biodentine with MTA in DPC and found no significant difference in 6 months. They concluded that both materials can be used for DPC.^[35] Hoseinifar *et al.*, the same as us, histologically showed a higher inflammatory pulp response to Biodentine compared with MTA in humans.^[36]

Future studies on propolis, MTA, and Biodentine in comparison with calcium hydroxide are required. Furthermore, animal studies are recommended to assess the efficacy of these materials for apexogenesis.

CONCLUSION

Propolis, MTA, and Biodentine can be successfully used for DPC with no significant difference among them. However, considering the limited number of studies on propolis and Biodentine, further studies are warranted on their properties.

Financial support and sponsorship

Nil.

Conflicts of interest

The authors of this manuscript declare that they have no conflicts of interest, real or perceived, financial or non-financial in this article.

REFERENCES

1. Cho SY, Seo DG, Lee SJ, Lee J, Lee SJ, Jung IY. Prognostic factors for clinical outcomes according to time after direct pulp capping. *J Endod* 2013;39:327-31.
2. Tziafas D, Smith AJ, Lesot H. Designing new treatment strategies in vital pulp therapy. *J Dent* 2000;28:77-92.
3. Seale NS, Coll JA. Vital pulp therapy for the primary dentition. *Gen Dent* 2010;58:194-200.
4. Torabinejad M, Fouad A, Walton RE. *Endodontics: Principles and Practice*. 5th ed. St Louis: Elsevier; 2015.
5. Accorinte Mde L, Loguercio AD, Reis A, Muench A, de Araújo VC. Response of human pulp capped with a bonding agent after bleeding control with hemostatic agents. *Oper Dent* 2005;30:147-55.
6. Kitasako Y, Ikeda M, Tagami J. Pulpal responses to bacterial contamination following dentin bridging beneath hard-setting calcium hydroxide and self-etching adhesive resin system. *Dent Traumatol* 2008;24:201-6.
7. Eskandarizadeh A, Shahpasandzadeh MH, Shahpasandzadeh M, Torabi M, Parirokh M. A comparative study on dental pulp response to calcium hydroxide, white and grey mineral trioxide aggregate as pulp capping agents. *J Conserv Dent* 2011;14:351-5.
8. Zarrabi MH, Javidi M, Jafarian AH, Joushan B. Histologic assessment of human pulp response to capping with mineral trioxide aggregate and a novel endodontic cement. *J Endod* 2010;36:1778-81.
9. Parirokh M, Torabinejad M. Mineral trioxide aggregate: A comprehensive literature review – Part I: Chemical, physical, and antibacterial properties. *J Endod* 2010;36:16-27.
10. Dammaschke T, Gerth HU, Züchner H, Schäfer E. Chemical and physical surface and bulk material characterization of white ProRoot MTA and two Portland cements. *Dent Mater* 2005;21:731-8.
11. Villat C, Tran VX, Pradelle-Plasse N, Ponthiaux P, Wenger F, Grosgeat B, *et al.* Impedance methodology: A new way to characterize the setting reaction of dental cements. *Dent Mater* 2010;26:1127-32.
12. Parirokh M, Asgary S, Eghbal MJ, Kakoei S, Samiee M. A comparative study of using a combination of calcium chloride and mineral trioxide aggregate as the pulp-capping agent on dogs' teeth. *J Endod* 2011;37:786-8.
13. Islam I, Chng HK, Yap AU. Comparison of the physical and mechanical properties of MTA and Portland cement. *J Endod* 2006;32:193-7.
14. Laurent P, Camps J, About I. Biodentine™ induces TGF-β1 release from human pulp cells and early dental pulp mineralization. *Int Endod J* 2012;45:439-48.
15. Koubi G, Colon P, Franquin JC, Hartmann A, Richard G, Faure MO, *et al.* Clinical evaluation of the performance and safety of a new dentine substitute, biodentine, in the restoration of posterior teeth-A prospective study. *Clin Oral Investig* 2013;17:243-9.
16. Olsson H, Petersson K, Rohlin M. Formation of a hard tissue barrier after pulp cappings in humans. A systematic review. *Int Endod J* 2006;39:429-42.
17. Molan P. Why honey is effective as a medicine: 2. The scientific explanation of its effects. *J Bee World* 2001;82:22-40.
18. Sforcin JM, Fernandes A Jr., Lopes CA, Bankova V, Funari SR. Seasonal effect on Brazilian propolis antibacterial activity. *J Ethnopharmacol* 2000;73:243-9.
19. Marcucci MC. Propolis: Chemical composition, biological properties and therapeutic activity. *Apidologie* 1995;26:83-99.
20. Kusum B, Rakesh K, Richa K. Clinical and radiographical evaluation of mineral trioxide aggregate, biodentine and propolis as pulpotomy medicaments in primary teeth. *Restor Dent Endod* 2015;40:276-85.
21. Nowicka A, Lipski M, Parafiniuk M, Sporniak-Tutak K, Lichota D, Kosierkiewicz A, *et al.* Response of human dental pulp capped with biodentine and mineral trioxide aggregate. *J Endod* 2013;39:743-7.
22. Katge FA, Patil DP. Comparative analysis of 2 calcium silicate-based cements (biodentine and mineral trioxide aggregate) as direct pulp-capping agent in young permanent molars: A split mouth study. *J Endod* 2017;43:507-13.
23. Dammaschke T, Stratmann U, Wolff P, Sagheri D, Schäfer E. Direct pulp capping with mineral trioxide aggregate: An immunohistologic comparison with calcium hydroxide in rodents. *J Endod* 2010;36:814-9.

24. Firla MT. Direct pulp capping with a bioactive dentine substitute. *Oral Health* 2012;102:40.
25. Gupta A, Makani S, Vachani K, Sonigra H, Attur K, Nayak R. Biodentine: An effective pulp capping material. *Sch J Dent Sci* 2016;3:15-9. google scholar: https://scholar.google.com/scholar?hl=en&as_sdt=0%2C5&q=Biodentine+%3A+an+effective+pulp+capping+material&btnG=. [Last accessed on 2020 Jan 28].
26. Parolia A, Kundabala M, Rao NN, Acharya SR, Agrawal P, Mohan M, *et al.* A comparative histological analysis of human pulp following direct pulp capping with propolis, mineral trioxide aggregate and dycal. *Aust Dent J* 2010;55:59-64.
27. Jalan AL, Warhadpande MM, Dakshindas DM. A comparison of human dental pulp response to calcium hydroxide and biodentine as direct pulp-capping agents. *J Conserv Dent* 2017;20:129-33.
28. Bogen G, Kim JS, Bakland LK. Direct pulp capping with mineral trioxide aggregate: An observational study. *J Am Dent Assoc* 2008;139:305-15.
29. Cavalcanti BN, Rode Sde M, França CM, Marques MM. Pulp capping materials exert an effect on the secretion of IL-1 β and IL-8 by migrating human neutrophils. *Braz Oral Res* 2011;25:13-8.
30. Déjou J, Raskin A, Colombani J, About I. Physical, chemical and mechanical behavior of a new material for direct posterior fillings. *Eur Cell Mater* 2005;10:22.
31. Okiji T, Yoshiba K. Reparative dentinogenesis induced by mineral trioxide aggregate: A review from the biological and physicochemical points of view. *Int J Dent* 2009;2009:464280.
32. Pérard M, Le Clerc J, Watrin T, Meary F, Pérez F, Tricot-Doleux S, *et al.* Spheroid model study comparing the biocompatibility of Biodentine and MTA. *J Mater Sci Mater Med* 2013;24:1527-34.
33. Kaup M, Schäfer E, Dammaschke T. An *in vitro* study of different material properties of biodentine compared to ProRoot MTA. *Head Face Med* 2015;11:16.
34. Moradi S, Saghravani N, Moushekhian S, Fatemi S, Forghani M. Immunohistochemical evaluation of fibronectin and tenascin following direct pulp capping with mineral trioxide aggregate, platelet-rich plasma and propolis in dogs teeth. *Iran Endod J* 2015;10:188-92.
35. Awawdeh L, Al-Qudah A, Hamouri H, Chakra RJ. Outcomes of vital pulp therapy using mineral trioxide aggregate or biodentine: A prospective randomized clinical trial. *J Endod* 2018;44:1603-9.
36. Hoseinifar R, Eskandarizadeh A, Parirokh M, Torabi M, Safarian F, Rahmanian E. Histological evaluation of human pulp response to direct pulp capping with MTA, CEM Cement, and Biodentine. *J Dent (Shiraz)* 2020;21:177-83.