

Case Report

Midface advancement in an adult patient with Crouzon syndrome: Modified LeFort III + LeFort I osteotomy accompanied by genioplasty and nasal dorsum augmentation

Milad Etemadi Sh¹, Golnaz Tajmiri²

¹Department of Oral and Maxillofacial Surgery, Dental Implants Research Center, Dental Research Institute, School of Dentistry, Isfahan University of Medical Sciences, Isfahan, Iran, ²Dental Implants Research Center, Dental Research Institute, Isfahan University of Medical Sciences, Isfahan, Iran

Received: 07-Jul-2020
Revised: 15-Sep-2021
Accepted: 10-Oct-2021
Published: 27-Apr-2022

Address for correspondence:
Dr. Golnaz Tajmiri,
Dental Implants Research
Center, Dental Research
Institute, Isfahan University
of Medical Sciences, Isfahan,
Iran.
E-mail: gtajmiri.gt@gmail.
com

ABSTRACT

Crouzon syndrome is an autosomal dominant trait, leading to midface deficiency, undeveloped orbits, short nasal dorsum, and exophthalmos as the typical clinical features. Early correction of craniofacial problems can improve patients' quality of life, but many of these patients with Crouzon syndrome are seeking treatment in older ages when they are missed for multidisciplinary management and distraction technique in proper timing. Modified LeFort III osteotomy is one of the treatment options that can be used for proper resolution in adult patients. The present case report study aims to describe a patient with midface deficiency due to the Crouzon syndrome who has undergone a combination of modified LeFort III osteotomy with the periocular approach and LeFort I osteotomy, nasal dorsum augmentation accompanied by genioplasty, wholly as a single surgical procedure which has been shown that can result in highly satisfactory outcomes for both patient and surgeon.

Key Words: Craniofacial dysostosis, Crouzon syndrome, midface advancement, midface hypoplasia, modified LeFort iii osteotomy

INTRODUCTION

Crouzon syndrome is defined as premature closure of one or more cranial sutures due to the mutation in fibroblast growth factor receptor-2 gene with the autosomal dominant trait,^[1] leading to an abnormal growth pattern in the skull base, orbital cavities, and nasomaxillary complex, but there are no digital anomalies such as those seen in *Apert* syndrome as another craniosynostosis syndrome.^[2] The typical clinical features are midface and maxillary deficiency, short nasal dorsum, undeveloped orbits, and subsequent exophthalmos; moreover, upper

airway obstruction can occur in the most severe cases.^[3,4]

The management of patients with Crouzon syndrome has two stages; in the first early stage, patients undergo cranial surgery for releasing the prematurely closed sutures usually at the age of 3 to 6 months and based on increased levels of intracranial pressure (ICP). In the second stage, craniofacial reconstructive surgery is done to correct the midface deficiency and subsequent Class III malocclusion,

This is an open access journal, and articles are distributed under the terms of the Creative Commons Attribution-NonCommercial-ShareAlike 4.0 License, which allows others to remix, tweak, and build upon the work non-commercially, as long as appropriate credit is given and the new creations are licensed under the identical terms.

For reprints contact: WKHLRPMedknow_reprints@wolterskluwer.com

How to cite this article: Sh ME, Tajmiri G. Midface advancement in an adult patient with Crouzon syndrome: Modified LeFort III + LeFort I osteotomy accompanied by genioplasty and nasal dorsum augmentation. Dent Res J 2022;19:38.

Access this article online	
	<p>Website: www.drj.ir www.drjjournal.net www.ncbi.nlm.nih.gov/pmc/journals/1480</p>

to decrease the scleral show and other anomalies in need of surgery.^[4]

Besides the physical problems, quality of life in patients with Crouzon syndrome is highly affected, and as a result, all these problems have negative effects on patients' self-confidence and social relationships; therefore, early correction of craniofacial problems can improve patients' quality of life.^[5,6]

Modified LeFort III osteotomy is one of the treatment modalities that can be used for proper resolution in adult patients. Historically, the first successful results for correction of midface deficiency using this technique were achieved by Tessier. It can be a good choice of treatment in conditions when the nasomaxillary complex is not involved.^[7]

The present case report study aims to describe a patient with midface deficiency due to the Crouzon syndrome who was undergone modified LeFort III osteotomy with a periocular approach, nasal dorsum augmentation, and LeFort I osteotomy accompanied by genioplasty, wholly as a single surgical procedure.

CASE REPORT

The case reported in this study was a 21-year-old female patient complaining of difficulty in chewing and extreme scleral show of the eyes. Clinical examination showed severe deficiency in the midface area and lower rim of the orbits and subsequently severe exophthalmos. No digital deformity was noted and contour of the forehead was within the normal range, but there was a decrease in the nasofrontal angle which became exacerbated after the modified LeFort III osteotomy procedure. The length of the upper lip was 21 mm. Incisor show was 1 mm at rest and 6 mm at smile [Figure 1a-l]. A consultation was done with neurosurgeon and ophthalmologist. The patient had no mental problem and ICP was normal. The visual condition was normal. The patient had no upper airway obstruction or respiratory problems. In the intraoral examination, a 5 mm anterior open bite and bilateral posterior crossbite were detected. The dental relationship was Class III (CI III) bilaterally both in molar and canine region with approximately 10 mm reverse overjet [Figure 1m-o]. The patient had just undergone orthodontic treatment aiming alignment and levelling of both maxillary and mandibular teeth, obtaining compatible arch forms, resolving crowding/spacing, and removing dental compensations.^[8] Preoperative radiographic evaluation

showed no asymmetry in the posteroanterior view and no root resorption in the panoramic view [Figure 2a and e]. The cephalometric evaluation revealed severe maxillary deficiency (Sella-Nasion Angle [SNA] =71) and consequently a concave profile of the face (angle of convexity = -3). "A point-Nasion-B point ANB" and "A-B plane angle" measures showed CI III jaw discrepancy. Obtuse Frankfort plane-mandibular plane angle and increased Y-axis A line from sella turcica to gnathion. It indicates the degree of the downward, rearward or forward position of the chin concerning the upper face showed vertical growth of the mandible and long-face tendency due to the backward rotation of the mandible. Severe retrogenia was noted in both clinical and cephalometric evaluation [Table 1 and figures 1a-l and 2c].

Treatment planning was performed based on the patient's chief complaint and severity of the problems as follows:

- Modified LeFort III osteotomy to resolve the midface deficiency not involving nasomaxillary complex^[9]
- Iliac crest bone grafting for zygomatic gap
- LeFort I osteotomy for maxillary advancement
- Nasal dorsum augmentation using iliac crest bone graft
- Advancement genioplasty for correction of severely deficient chin.

Modified LeFort III osteotomy

This study followed the Declaration of Helsinki on medical protocol and ethics, and in informed consent was obtained from the patient. Since no experimentation was performed, we did not require any approval by the Regional Ethical Review Board. After nasotracheal intubation which was secured to the membranous septum and columella by sutures; draping was done. For subtarsal incision with lateral extension approach, 3–5 mm inferior to the gray line of the lower eyelid, an inferior palpebral crease was found and marked and extended to crow's-feet wrinkle in the lateral orbit. One cc of 2% lidocaine with 1:80,000 epinephrine was injected into the marked incision line on each side. Subperiosteal dissection was performed considering not detaching the medial canthus and preserving the facial nerve in the periorbital area. The osteotomy was initiated just 5 mm lateral to the lacrimal crest, continued inferiorly just below the inferior turbinate of the nasal cavity. Then, continued horizontally to terminate in the piriform rim using a guard osteotome to perform

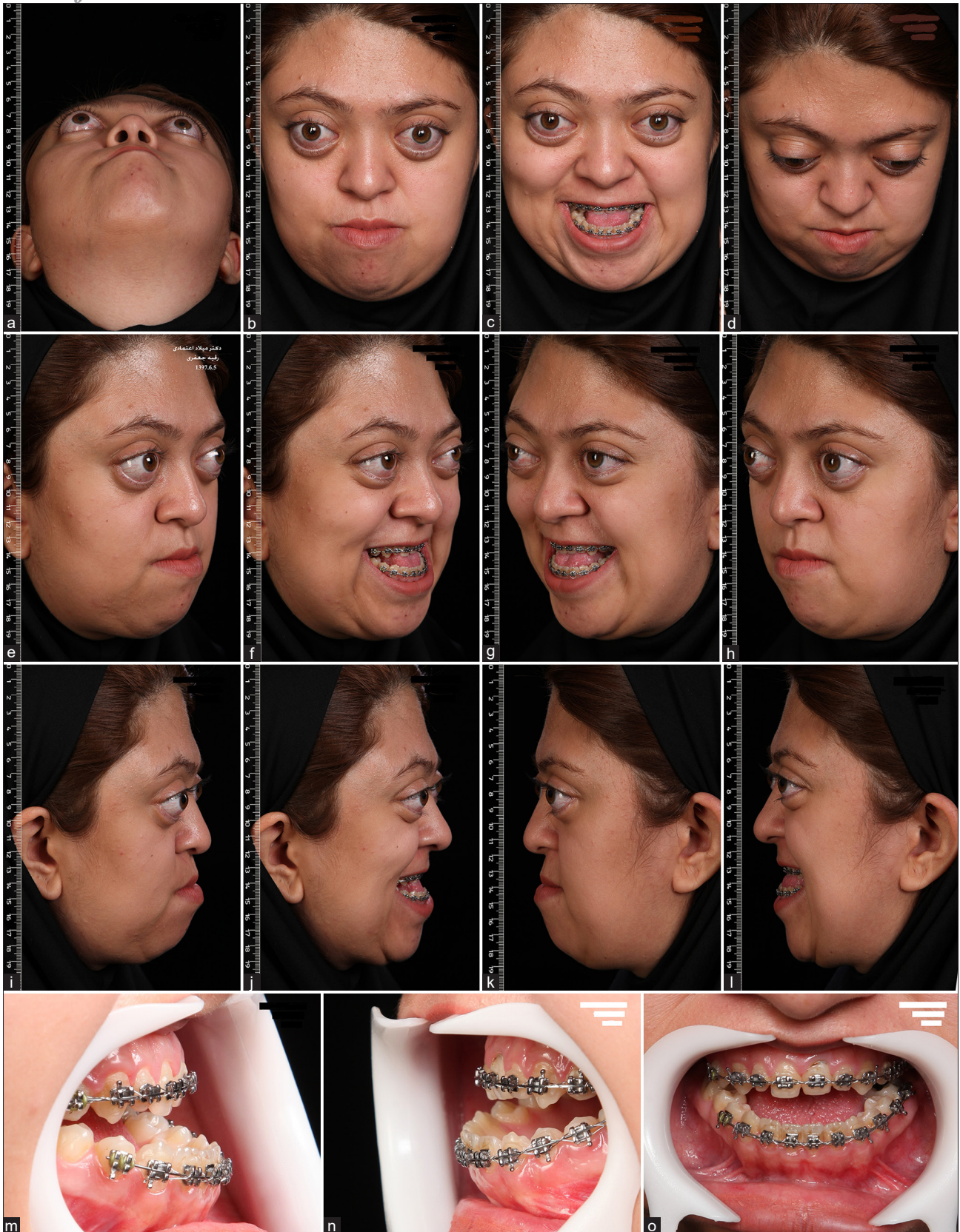

Figure 1: Preoperative photography (a) Inferior view, (b and c) frontal lip closed and smile views, (d) Superior view, (e and f) Right oblique lip closed and smile views, (g and h) Left oblique smile and lip closed views, (i and j) Right profile lip closed and smile views, (k and l) Left profile smile and lip closed views; Presurgical intraoral photography. (m) Right, (n) Left, and (o) Frontal views of the occlusion.

Table 1: Preoperative and postoperative cephalometric evaluation

	Preoperative measures	Postoperative measures	Normal values
Skeletal parameters			
SN-FH°	5	5	9
SNA°	71	79	82
A point to N-Perpendicular (mm)	-10	-5	2
SNB°	74	77	80
Pogonion to N-Perpendicular (mm)	-17.5	-12	-4-0
Facial angle°	80	84	87.8
ANB °	-3	2	2
Angle of convexity°	-3	2	0.0
A-B plane to the facial angle°	+5	-4	-4.6
FMA°	49	38	21.9
Y-Axis°	72.5	67	59.4
Jaraback index	45%	62%	62%-65%
Lower facial height	62%	60%	55%
Dental parameters			
Occlusal plane to FH°	20	18	9
U1* to FH°	108	104	112
U1 to A-Perpendicular (mm)	5	4	4
U1 to A-Pogonion Plane (mm)	7	4	2.7
U1 to L1°**	124	133	135.4
IMPA°#	-6	-2	1.4
FMIA°##	52	54	68
L1 to A-Pogonion Plane (mm)	14	3	0
Overjet (mm)	-10	0.5	0.5
Overbite (mm)	5 (open bite)	1	2-4 (25%-40%)
Molar discrepancy (mm)	6	0	0
Soft-tissue parameters			
Nasofrontal angle°	118	127	134
Nasolabial angle°	84	98	99

*Upper first incisor; **Lower first incisor; #Incisor-Mandibular Plane Angle; ##Frankfort-Mandibular Incisor Angle

2.5 cm anteroposterior osteotomy in the lateral wall of the nose. The horizontal part of the osteotomy line was continued in the inferior wall of the orbit and approximately 1 cm posterior to the inferior rim toward the lateral rim. Just before reaching the lateral canthal tendon of the globe, osteotomy was continued anteriorly while half of the lateral rim of the orbit and the lateral orbital wall was involved. Moreover, finally, the body of the zygomatic bone was osteotomized vertically to the lower limit of the zygomatic buttress. An intraoral approach, maxillary vestibular mucosa was anesthetized with the same agent and a typical vestibular incision was made from tooth #3 to #14 and 5 mm superior to mucogingival junction aiming to access to the pterygoid plates behind the tuberosity area. After preserving the maxillary artery in the vestibular area by subperiosteal dissection; first of all, the osteotomy line in the nasal area was checked and completed if necessary. After that, osteotomy of the pterygoid plates was performed using a 10 mm curved osteotome; continued in the superior-anterior

direction to reach the inferior orbital fissure and separate the posterior wall of the maxilla. Finally, the complete release of the midface from the skull base was performed using disimpaction row forceps and 7 mm advancement of the maxilla was done. Then, the separated segment was stabilized using an intermediate surgical splint and intermaxillary fixation and a mono-cortical bone graft harvested from the iliac crest was used to fill the gap in zygomatic area, and finally, rigid fixation was done using mini plates [Figure 3].

LeFort I osteotomy

After osteotomy was performed beginning from the tuberosity area, continued in a parallel direction to the occlusal plane and terminated at the piriform rim; considering pterygomaxillary disjunction just performed in modified LeFort III procedure, 4 mm advancement was performed. The final positioning of the maxillary segment was done using the final surgical wafer with rigid fixation using mini plates.

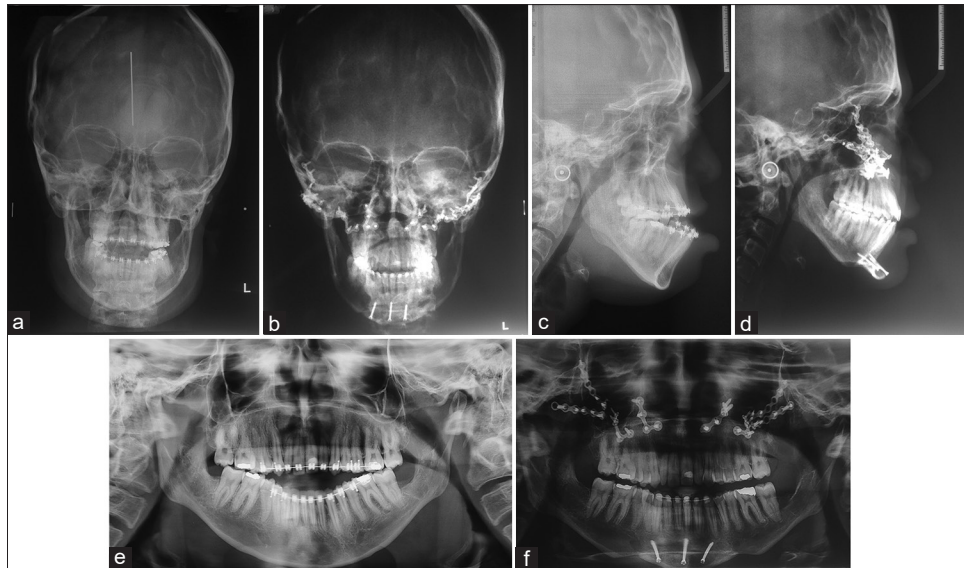


Figure 2: Radiographic evaluation (a) preoperative PA cephalometric evaluation, (b) postoperative PA cephalometric evaluation, and (c) preoperative lateral cephalometric evaluation, (d) postoperative lateral cephalometric evaluation, (e) preoperative panoramic view, (f) postoperative panoramic view. Note that the copper beaten skull appearance is obvious in lateral and anteroposterior cephalometric evaluation because of the raised intracranial pressure.

Nasal dorsum augmentation

Nasal dorsum augmentation was done using a closed approach by left intercartilaginous incision. Supraperichondreal and subperiosteal dissection were done and a 15 mm × 5 mm × 4 mm iliac crest bone graft harvested primarily for LeFort III osteotomy was used for augmentation.

Advancement genioplasty

Advancement genioplasty using the jumping technique was done due to the severe deficiency of the chin. After making a vestibular incision and subperiosteal dissection in the mandibular vestibule, osteotomy and 9 mm advancement of the segment was done. Final rigid fixation was performed using triple cortex screws.

Postoperative evaluation

The postoperative phase of orthodontic treatment was finalized aiming to achieve maximum interdigitation and optimum occlusion [Figure 2b,d, and f]. A 1-year postoperative follow-up was done after the final phase of orthodontic treatment. Midface and malar deficiency was improved significantly. There was a decrease in the scleral show and Proper chin projection was obtained [Figure 4a-l]. Nasofrontal angle was improved as well as nasolabial angle; former due to the dorsum augmentation and later as a result of maxillary advancement [Table 1]. The postoperative intraoral evaluation showed resolved posterior crossbite and anterior open bite. Class I occlusal relationship with 1 mm vertical overlap and

0.5 mm overjet was obtained [Figure 4m-o]. The cephalometric evaluation showed improvement in SNA value leading to improvement of deficient maxilla and correction of jaw discrepancy (“ANB” and “A-B Plane angle”). A slightly convex profile was obtained which is in the optimum range for females (Angle of convexity = 2). Facial height proportions were improved to ideal ranges and severely deficient chin was resolved mostly by advancement genioplasty and slightly by forwarding rotation of the mandible which is significant in both radiographic and clinical examination [Figures 2, 4 and 5].

DISCUSSION

Management of patients with craniosynostosis syndromes should be with a multidisciplinary approach. As noted previously, surgical management of *Crouzon* patients is a two-stage procedure leading to the improvement of the facial aesthetic as well as psychosocial aspects of the patient’s life. Ideally, surgical reconstruction of the midface should be done in permanent dentition between the age group of 13–21 years following a comprehensive phase of orthodontic treatment, but if there are high levels of skeletal imbalance, then surgical intervention may be postponed to later ages.^[8]

Some authors have recommended that LeFort III distraction osteogenesis (DO) can be considered

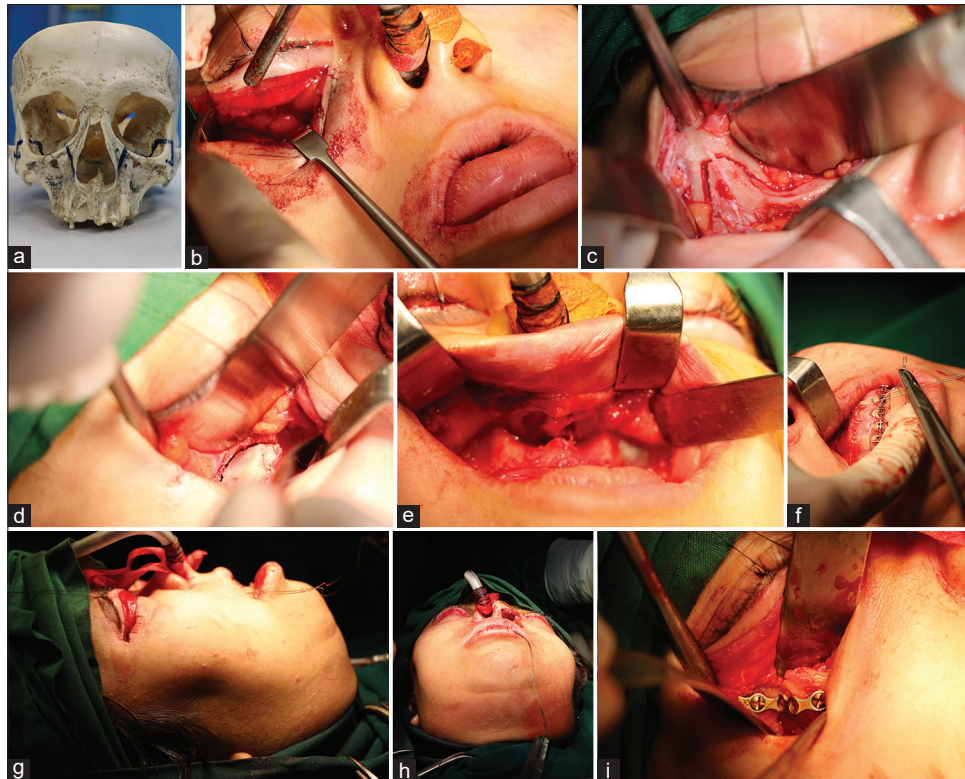


Figure 3: Modified LeFort III osteotomy (a) Osteotomy lines, (b) Sub tarsal incision, (c and d) Priauricular osteotomies, (e and f) vestibular incision and initial stabilization with intermediate surgical splint and intermaxillary fixation, (g and h) profile and inferior views immediately after initial fixation, and (i) rigid fixation of the bone graft.

as a reliable treatment modality for these patients due to the stable results and minimum risk of relapse and low rate of minor distraction-related complications.^[10,11] While, patient compliance in utilizing the rigid external distractor device at low ages and socioeconomic status are the factors with paramount importance in achieving desired outcomes; many of these patients have socioeconomic problems which means that they are not economically affordable for receiving such a comprehensive, extended, and timely mannered treatment. On the other hand, in the osteotomy technique, unlike DO, the surgeon has full control over the amount and direction of the movement. Furthermore, there is a need for a second surgery in the DO technique for removing the device.

In another case report study performed by Mohammadi *et al.*, it is reported that severe midface deficiency in an adult patient with Crouzon syndrome was improved by modified LeFort III osteotomy solely and without previous orthodontic treatment due to the low socioeconomic status of the patient.^[9] While performing such surgery in combination with orthodontic treatment and other needed surgical procedures can produce more satisfactory results from

the surgeon's point of view as well as the patients if she/he is financially affordable. Moreover, performing genioplasty in cases with severe retrogenia can improve fascial aesthetic in addition to resolving the probable obstructive sleep apnea; also, performing LeFort I osteotomy following modified LeFort III osteotomy may reduce the risk of relapse and achieving more precise occlusal relationship.

Finally, selection between “the modified LeFort III osteotomy with sub tarsal approach accompanied by closed-approach nasal dorsum augmentation” and “total LeFort III osteotomy with the coronal approach,” depends on the surgeon's preference and the former approach may be preferred to the coronal one due to the less complication and discomfort for the patient following extensive flap elevation in the coronal area.

CONCLUSION

Since many of patients with Crouzon syndrome are seeking treatment in older ages when they are missed for multidisciplinary management and DO technique in proper timing, osteotomy technique accompanied by other indicated procedures like LeFort I osteotomy,

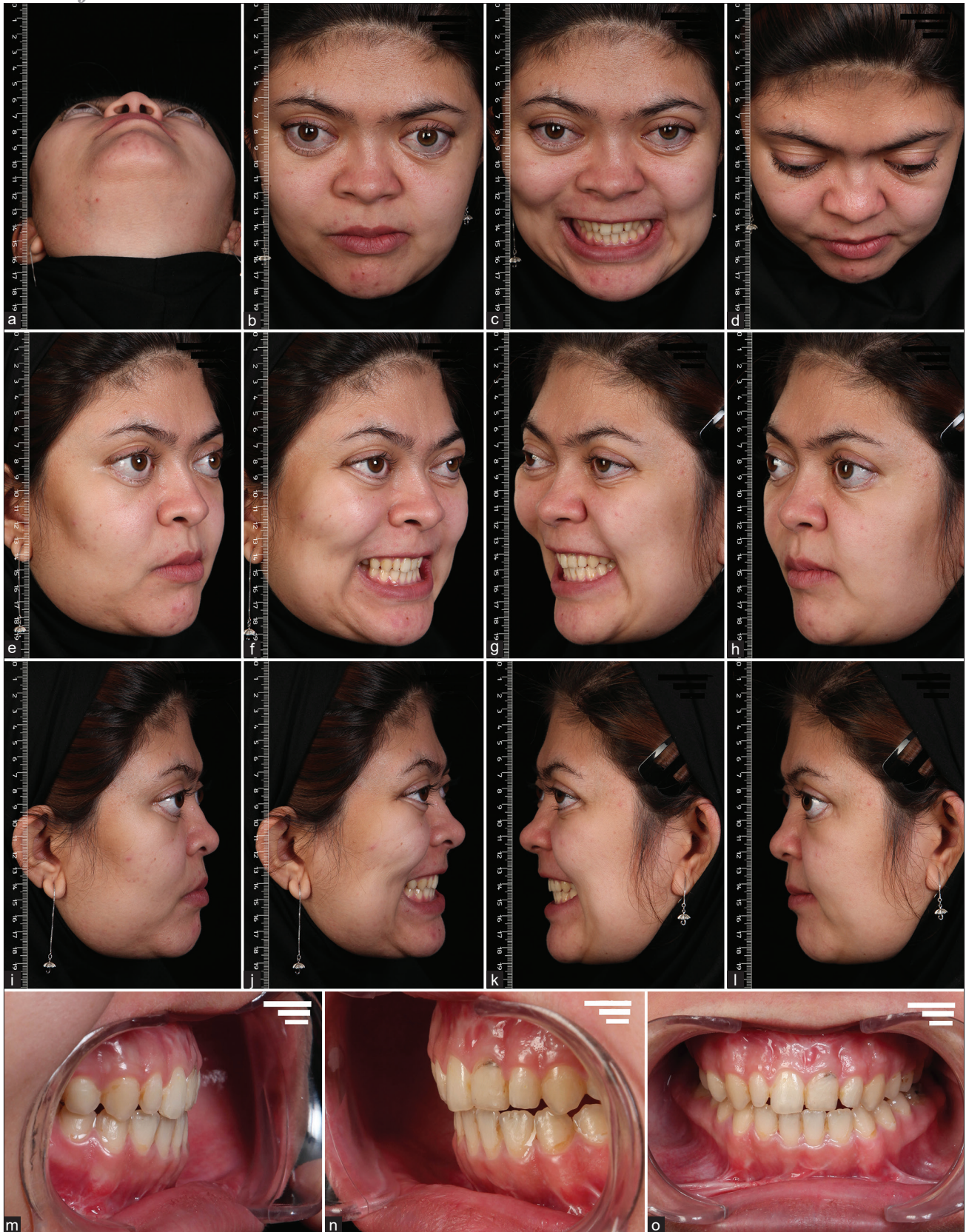

Figure 4: Postoperative photography (a) Inferior view, (b and c) Right frontal lip closed and smile views, (d) Superior view, (e and f) Right oblique lip closed and smile views, (g and h) Left oblique smile and lip closed views, (i and j) Right profile lip closed and smile views, (k and l) Left profile smile and lip closed views; Postsurgical intraoral photography. (m) Right, (n) Left, and (o) Frontal views of the occlusion.

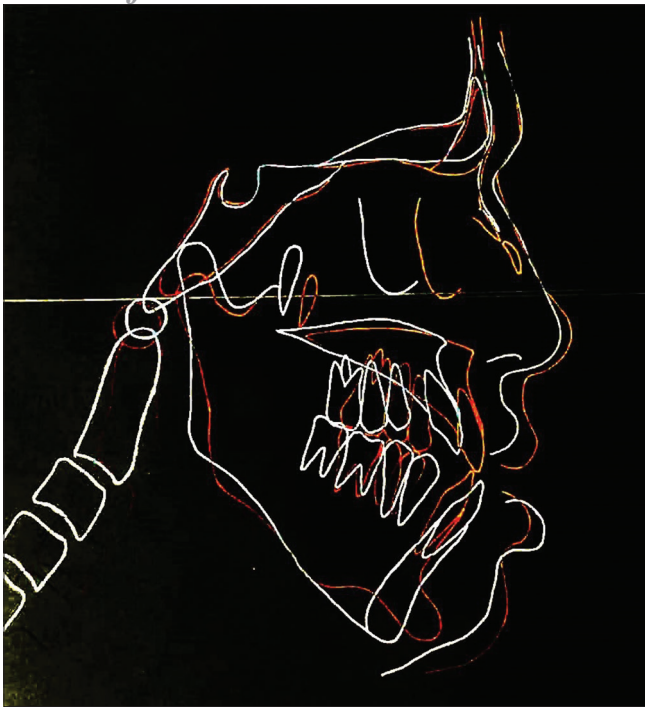

Figure 5: Cephalometric tracing superimposition on skull base showing obvious improvement in the occlusal relationship and skeletal discrepancy as well as soft-tissue parameters. (white lines for preoperative tracing and red lines for postoperative one). Slight mandibular forward rotation is noted in condylar and dental areas.

nasal dorsum augmentation, and genioplasty can result in highly successful outcomes both for patient and surgeon as well as many positive effects on patient's self-confidence and social aspect of his/her life; thus, such an approach is highly recommended, especially if the patient is financially affordable.

Declaration of patient consent

The authors certify that they have obtained all appropriate patient consent forms. In the form, the patient has given her consent for her images and other clinical information to be reported in the journal. The patient understand that name and initials will not be published and due efforts will be made to conceal identity, but anonymity cannot be guaranteed.

Financial support and sponsorship

Nil.

Conflicts of interest

There are no conflicts of interest.

REFERENCES

1. Goos JA, Mathijssen IM. Genetic causes of craniosynostosis: An update. *Mol Syndromol* 2019;10:6-23.
2. Chen H. Atlas of Genetic Diagnosis and Counseling: Lesch-Nyhan Syndrome. *ELS*; 1974. p. 600-3. [cited 2020 Jul 2]. Available from: <http://onlinelibrary.wiley.com/doi/10.1002/9780470015902.a0001457.pub2/full>.
3. Gothwal S, Nayan S, Kumar J. Crouzon syndrome with bony upper airway obstruction: Case report and review literature. *Fetal Pediatr Pathol* 2014;33:199-201.
4. Balyen L, Deniz Balyen LS, Pasa S. Clinical characteristics of Crouzon syndrome. *Oman J Ophthalmol* 2017;10:120-2.
5. Sarwer DB, Bartlett SP, Whitaker LA, Paige KT, Pertschuk MJ, Wadden TA. Adult psychological functioning of individuals born with craniofacial anomalies. *Plast Reconstr Surg* 1999;103:412-8.
6. Visram SM, Gill D, Shute JT, Cunningham SJ. Qualitative study to identify issues affecting quality of life in adults with craniofacial anomalies. *Br J Oral Maxillofac Surg* 2019;57:47-52.
7. Tessier P. The definitive plastic surgical treatment of the severe facial deformities of craniofacial dysostosis: Crouzon's and Apert diseases. *Plast Reconstr Surg* 1971;48:419-42.
8. Azoulay-Avinoam S, Bruun R, MacLaine J, Allareddy V, Resnick CM, Padwa BL. An overview of craniosynostosis craniofacial syndromes for combined orthodontic and surgical management. *Oral Maxillofac Surg Clin North Am* 2020;32:233-47.
9. Mohammadi F, Javanmard A, Mojtahedi H. Patient with Crouzon syndrome treated with modified Le Fort III osteotomy without previous orthodontic treatment: Case report and a review of the literature. *Case Rep Dent* 2020;2020:6248971.
10. Engel M, Berger M, Hoffmann J, Kühle R, Rückschloss T, Ristow O, *et al*. Midface correction in patients with Crouzon syndrome is Le Fort III distraction osteogenesis with a rigid external distraction device the gold standard? *J Craniomaxillofac Surg* 2019;47:420-30.
11. Fariña R, Valladares S, Raposo A, Silva F. Modified Le Fort III osteotomy: A simple solution to severe midfacial hypoplasia. *J Craniomaxillofac Surg* 2018;46:837-43.