

Original Article

Ameliorating Effects of Vitamin E on Morphological and Histological Alterations and Oxidative Stress Factors Assessment Against Titanium Dioxide Nanoparticle-Induced in Mice Testis

Jahangirfard R¹, Raji AR², Moghaddam Jafari A³, Nourani H⁴

1. Faculty of Veterinary Medicine, Urmia University, Urmia, Iran
2. Department of Comparative Histology, Faculty of Veterinary Medicine, Ferdowsi University of Mashhad, Mashhad, Iran
3. Department of Toxicology, Faculty of Veterinary Medicine, Ferdowsi University of Mashhad, Mashhad, Iran
4. Department of Pathology, Faculty of Veterinary Medicine, Ferdowsi University of Mashhad, Mashhad, Iran

Received: 15 May 2020

Accepted: 07 Jul 2020

Abstract

Background & Objective: Nano titanium dioxide particles (TiO₂) are chemical compounds that are widely used in industrial and foodstuff such as cosmetics, toothpaste, colored materials, and non-fat milk whitening. Vitamin E (Vit E) is a dietary compound that functions as an antioxidant scavenging free radicals. The goal of this study was to carry out the protective effect of vitamin E on histomorphometry, oxidative stress factors and biochemical parameters as well as testosterone concentration.

Materials & Methods: In the present study, 35 adult male mice were divided into 7 control and experimental groups. The experimental groups received TiO₂ at 2.5, 5 and 10 doses, and the positive control group received vitamin E (100 IU) mg/kg alone (by gavage tube). After treatment, animals were euthanized by cervical dislocation and testes samples were taken. The level of $p < 0.05$ was considered significant.

Results: The results of histomorphometry revealed that the weight of testis and body, testicular capsule thickness, seminiferous tubules diameter, germinal epithelium height, spermiogenesis and meiotic indices were reduced while sertoli cells and repopulation index had no significant changes. Also, biochemical results showed the Malondialdehyde was enhanced and it diminished the total antioxidant capacity, catalase enzyme activity, protein content, as well as testosterone concentration. ($p < 0.05$).

Conclusion: The TiO₂ nanoparticles caused detrimental pathologic effects when used at the highest doses. However, vitamin E could ameliorate the toxic effects of TiO₂-induced on testicular tissue in experimental animals.

Keywords: Histomorphometry, Mice, Testis, Titanium dioxide, Vitamin E

Introduction

Titanium dioxide nanoparticles (TiO₂) are an inflammable, odorless, and white powder this is widely used in cosmetics, food preservation, medicine, and other products. However, studies

have highlighted the adverse potential toxic effects of TiO₂ (1).

Titanium dioxide has three isoforms including anatase, rutile, and brookite. The titanium dioxide properties have been reported that erythrocytes intoxicated with nano-sized TiO₂ exhibited abnormal sedimentation, hemolysis and hemagglutination unlike their micro-sized on the contrary (2). Besides, one of the major applications of TiO₂ is sun protection (2). It has

*Corresponding Author: Raji Ahmadreza, Department of Comparative Histology, Faculty of Veterinary Medicine, Ferdowsi University of Mashhad, Mashhad, Iran.
Email: rajireza@um.ac.ir
<https://orcid.org/0000-0002-8192-8374>

been demonstrated that the photocatalytic activity of anatase form is higher than that of rutile form (3). Furthermore, the anatase form is mostly used for sterilization materials and other productions. Several studies have reported that the TiO₂ has no toxic effects, while it is stated that TiO₂ may induce cytotoxic pathological impacts on living cells (4). In one study, IV administration of TiO₂ to animal models led to its accumulation of organs and/or tissues (5). Another study demonstrated that titanium dioxide and other nanoparticles could enter the brain tissue via inhalation and olfactory nerves (6). Observations have shown that after intranasal injection, titanium dioxide could be found as a pathway for conduction into the central nervous system and then accumulated in some organs consisting of the cerebral cortex, olfactory nerve tract, hippocampus, and thalamus (7). More studies have reported that TiO₂ nanoparticles induce intracellular reactive oxygen species (ROS) and can affect the biological activity of cells (8-10). Wang et al. stated that the influence of Nano-titanium oxide could induce hepatic and renal injuries after chronic exposure to nanoparticles (7). Chen et al. indicated that after intraperitoneal injection of TiO₂, it was accumulated in spleen, liver, kidney. It also induced hepatocellular necrosis, apoptosis, hepatic fibrosis, and interstitial pneumonia (11). Simultaneous use of titanium dioxide and silver nanoparticles not only leads to translocation into maternal bloodstream but also their metabolites can cross the blood-placental barrier to reach the prenatal mouse. Hence, the newborn embryos exposed to nanoparticles demonstrate several disorders caused by teratogenicity, mutagenicity, genotoxicity and reactive oxygen species (ROS) production (12). Recent studies have reported that food safety problems gradually dissolved in the field of nanotechnology using supplementary materials in the world (13-15). Studies have revealed that when titanium dioxide penetrates the cells and mitochondria, it can generate free radicals by mitochondrial suppressing activation in the body. In line with this, the free radicals, Reactive Oxygen Species, play an important role in the induction of adverse effects on testes (16). Many studies have shown that the toxic effects of TiO₂ nanoparticles are in a size-dependent manner (6, 16, 17). However, some studies have revealed that the toxicity of TiO₂ nanoparticles did not depend on particle size (13, 14, 16). Therefore, in

the present experimental study, mice were given titanium dioxide as an oxidative stress inducer and vitamin E as an antioxidant combination via gavage. The purpose of this study was to assess the protective effects of vitamin E against TiO₂ induced on histoarchitecture and antioxidant machinery in testicular tissue.

Materials & Methods

Animals and Treatments

Thirty-five adult male albino mice (NMRI strain) with an approximate weight of 30-35 gr were obtained from the animal house of the Faculty of Pharmacy, University of Mashhad, Mashhad, Iran. The animals were acclimatized for two weeks under laboratory standard conditions in terms of temperature, humidity, and 12hrs light/dark cycle before the beginning of the experiment and then food (in form pellet) and tap water access to ad libitum. This study was approved by the Ethics Committee of Faculty of Veterinary Medicine, University of Mashhad, Mashhad, Iran. The animals were randomly divided into seven main groups with five mice in each group. The groups were labeled as the first group: Negative-Control group (without any substance), the second group: Control-Shem group (received only distilled water), the third to fifth groups considered as treatment groups: (2.5, 5, and 10 mg/kg, BV, daily) respectively, the sixth group: 10 mg/kg + vit E (vitamin E administered after 2 hours' oral administration of high dose) and the seventh group: Positive-Control group (only vitamin E). Both titanium dioxide and vitamin E were administered orally with a gavage needle. As a vehicle, TiO₂ and vitamin E dissolved in distilled water and olive oil, respectively. After 35 days, the testicles were harvested and blood samples were taken from the heart with heparin syringe and centrifuged for assessment of testosterone levels. Also, the removed testes were transmitted to 10% fixative solution.

Samples preparation

The tissue sections were prepared and stained using hematoxylin and eosin. Then, the sections were cut at 6-7 μm by rotary microtome section (Microm, GMBH, Type HM 335 E, Germany). All histological parameters were measured by the latticed and graded lens (Periplan GF 10X/18 M, Leitz Wetzlar Germany). Moreover, testis and total body weight were measured (Table 1).

Table 1. Total body and testicular weights and Histomorphometrical characteristics in mice seminiferous tubules

Groups Index	Control	Sham	LD-TiO ₂	MD-TiO ₂	HD-TiO ₂	Vit E+TiO ₂	Vit E
Total testicular weight (gr)	1.57±0.26 ^a	1.57±0.17 ^a	1.52±0.17 ^a	1.42±0.15 ^b	0.85±0.17 ^c	1.57±0.17 ^a	1.57±0.26 ^a
Total body weight (gr)	27.03±1.32 ^a	27.23±1.26 ^a	27.39±1.22 ^a	27.08±1.57 ^a	23.96±1.24 ^b	28.5±1.33 ^a	27.66±1.45 ^a
Testicular capsule thickness (µm)	10.32±1.95 ^a	11.18±3.03 ^a	11.69±3.06 ^a	9.80±1.99 ^a	7.57±2.28 ^b	11.69±1.91 ^a	11.69±1.33 ^a
Seminiferous tubules diameter(µm)	195.79±20.03 ^a	191.66±28.22 ^a	181.86±18.93 ^a	157.42±8.50 ^b	132.99±8.09 ^c	209.21±12.08 ^a	198.72±14.79 ^a
Germinal epithelium height (µm)	56.43±14.36 ^a	53.68±8.11 ^a	57.46±12.84 ^a	41.12±4.51 ^b	43.7±4.30 ^{b,c}	64.86±9.69 ^a	66.75±10.63 ^a

Chemical materials

Titanium dioxide (TiO₂, CAS Number: 1317-70-0, purity: 99.7%) and vitamin E (CAS Number: T3376-5G) were obtained from Sigma-Aldrich company.

Histological assessments

For histomorphometry study, the tubules well-developed spermatozoa were considered as tubules with a positive spermiogenesis index (SPI). Positive repopulation index (RI) were assessed the ratio of spermatogonia type B (with a dark nucleus) to spermatogonia type A (with a light nucleus). The percentages of seminiferous tubules with SPI, and RI were performed in 25 per cross-sections from the mouse testis of each animal in each group and the results were compared among all groups. The diameter of seminiferous tubules and the thickness of germinal epithelium were investigated using a graded lens. Then, data analysis results were expressed in micrometer. To evaluate the round spermatid cells relative to primary spermatocytes of seminiferous tubules considered as Meiotic index (MI). Moreover, the ratio of the number of germ cells to the number of sertoli cells was randomly computed in 25 seminiferous tubules per section (18).

Malondialdehyde (MDA) assay

After the homogenizing testis, 0.20 g of the testicular tissue sample was transferred to 0.05 M phosphate buffer with pH= 7.40 (10% w/v). Blood samples were centrifuged at 1000 rpm.

Afterwards, 150 µg of the supernatant of the sample was removed and 300 µg of 10% trichloroacetic acid was added and centrifuged at 1000rpm for 10 min. Also, 300 µL of the supernatant was transferred to the test tube and incubated with 300 µL of 0.67% thiobarbituric acid (TBA) at 100 °C for 25 min. After 5 min, the pink color resulted from the reaction between MDA and TBA was measured using a spectrophotometer at 535 nm wavelength. The MDA concentration was computed using MDA absorption coefficient and expressed as nmol/g tissue (19).

Total antioxidant capacity (TAC) assay

The total antioxidant capacity (Randox Elisa Kit) of testicular tissue was evaluated using ferric reducing antioxidant power method. The regeneration rate of each sample was assessed through increasing the concentration of Fe⁺² complex with tripyridile triazine at 593nm wavelength via spectrophotometry (20).

Serum testosterone levels

Testosterone concentration was measured by an ELISA method using the IDEAL kit (ab108666 Abcam).

Catalase enzyme activity examination

Catalase enzyme activity was assessed based on its ability to decompose H₂O₂ in homogenized testicular tissue using Aebi method (21).

Protein assay

The rate of protein content was measured in testis tissue using Lowry method (22).

Statistical Analysis

Data analyses were performed using SPSS (version, 22) software for windows. One-way ANOVA and Tukey Tests were done to assess statistical differences between treated and untreated animals. The data were expressed as Mean±Standard deviation ($p < 0.05$).

Results

Macroscopic findings

Macroscopic observations consisted of hepatomegaly, splenomegaly and internal organ adhesions.

Histomorphometric findings

The results of this study showed that The total testicular weight was decreased in mid and high doses of TiO₂ in comparison with the control group. Whereas no significant difference between control, sham and a low dose of treated groups ($p < 0.05$; Table 1). Also, total body weight had significantly diminished in the highest dose of treatment versus the control group but there were no significant differences between mid and a low dose of TiO₂ (Table 1).

mid and high dosages of TiO₂ treatment in comparison with control ($p < 0.05$; Table 1). Also, there was a significant difference between mid and high doses. However, there were no changes in the low dose of TiO₂ treated group compared to the control and sham groups ($p < 0.05$; Table 1). A decreased germinal epithelium height was seen in mid and high doses of treated groups versus the control (Fig 1C-D). While the receiving of mid and high dosages of TiO₂ had no significant difference when compared to each other ($p < 0.05$; Table 1). Sertoli cell and repopulation indices results showed that there were no significant differences in all treated and untreated groups ($p < 0.05$; Table 2). Likewise, the spermiogenesis index was diminished in treated groups, especially in the highest dose of TiO₂, compared to the ones but there were no changes between control and sham groups (Table 2). Meanwhile, the mean of the meiotic index had significantly decreased in all of the treated groups compared to control. This reduction of meiotic index most was in the group receiving the highest dose of TiO₂-induced. So, in all treated animals had a significant difference in

Table 2. Histomorphometric characteristics of mice testis

Groups Index	Control	Sham	LD-TiO ₂	MD-TiO ₂	HD-TiO ₂	Vit E+TiO ₂	Vit E
Sertoli cell index	23.46±2.47 ^a	24.53±2.09 ^a	26.33±5.39 ^a	23.53±2.35 ^a	21.26±2.25 ^a	23.53±2.35 ^a	24.93±1.57 ^a
Repopulation index (SB/SA)	4.24±0.91 ^a	4.14±1.08 ^a	3.88±0.55 ^a	3.61±0.51 ^a	3.90±0.53 ^a	3.74±0.49 ^a	3.83±0.36 ^a
Spermiogenesis index	81.73±4.60 ^a	84.8±5.68 ^a	75.2±5.01 ^b	80.73±6.38 ^{a,b}	58.13±3.85 ^c	80.33±7.05 ^{a,b}	85.93±6.98 ^{a,b}
Meiotic index	0.46±0.07 ^a	0.43±0.09 ^a	0.75±0.21 ^b	0.62±0.08 ^c	0.54±0.09 ^d	0.53±0.09 ^a	0.57±0.09 ^{a,d}

Our results of this study exhibited that a decrease of testicular capsule thickness in the highest dose receiving was seen alone. While no significant changes between low and mid dosages of treated groups compared to control and/or sham. Accordingly, a significantly decreased seminiferous tubule diameter was observed in

comparison with the other each (Table 2). The results of biochemical parameters exhibited that the testicular malondialdehyde (MDA) was significantly increased in mid and high doses treatment compared to the control group. However, there were no significant changes between them. Results of testicular total

antioxidant capacity (TAC) had decreased in the groups of mid and high dosages versus the control group. Also, there were significant changes when compared with each other. While any alterations were not observed in a low dose compared to the ones (Table 3). Catalase enzyme activity had significantly diminished in the experimental groups compared to the control group. This reduction was significant in high dose versus low and mid dosages. However, there were no significant differences in comparison with each other. Also, the enzymatic activity of catalase was decreased in the group of vit E+TiO₂ compared to the control group.

Results of protein content showed that the rate of protein was reduced in all experimental groups versus the control group. Whereas a significant decrease was not observed between mid and high doses of TiO₂ treatment. According to table 3, the levels of testosterone hormone had significantly reduced in all animals experiment related to the control group. In line with that, there were no significant changes between mid and high dosages. But the group of low dose had significantly decreased in comparison with the aforementioned groups ($p < 0.05$; Table 3; Figure 1).

Table 3. Characteristics of stress oxidative parameters, catalase enzyme and protein content in mice

Groups Index	Control	Sham	LD-TiO ₂	MD-TiO ₂	HD-TiO ₂	Vit E+TiO ₂	Vit E
Testicular MDA (nmol/g)	13.50±0.02 ^a	13.52±0.03 ^a	13.93±0.01 ^a	20.54±0.11 ^b	22.71±0.57 ^b	13.42±0.11 ^a	13.40±0.11 ^a
Testicular TAC (mM/g)	2.41±0.01 ^a	2.30±0.005 ^a	2.13±0.03 ^a	1.76±0.02 ^b	1.02±0.07 ^c	2.27±0.05 ^a	2.17±0.05 ^a
Catalase activity (u/mg)	501.92±2.07 ^a	504.36±0.62 ^a	405±04±3.24 ^b	400.73±1.96 ^b	303.28±1.84 ^c	406.26±4.22 ^b	506.85±2.79 ^a
Protein content (µg/ml)	194.85±2.57 ^a	198.72±0.91 ^a	183.87±3.60 ^b	173.17±3.97 ^c	170.50±1.96 ^c	193.02±3.21 ^a	197.51±1.61 ^a
Testosterone levels (ng/ml)	0.39±0.03 ^a	0.39±0.05 ^a	0.30±0.02 ^b	0.23±0.02 ^c	0.19±0.01 ^c	0.40±0.02 ^a	0.36±0.01 ^a

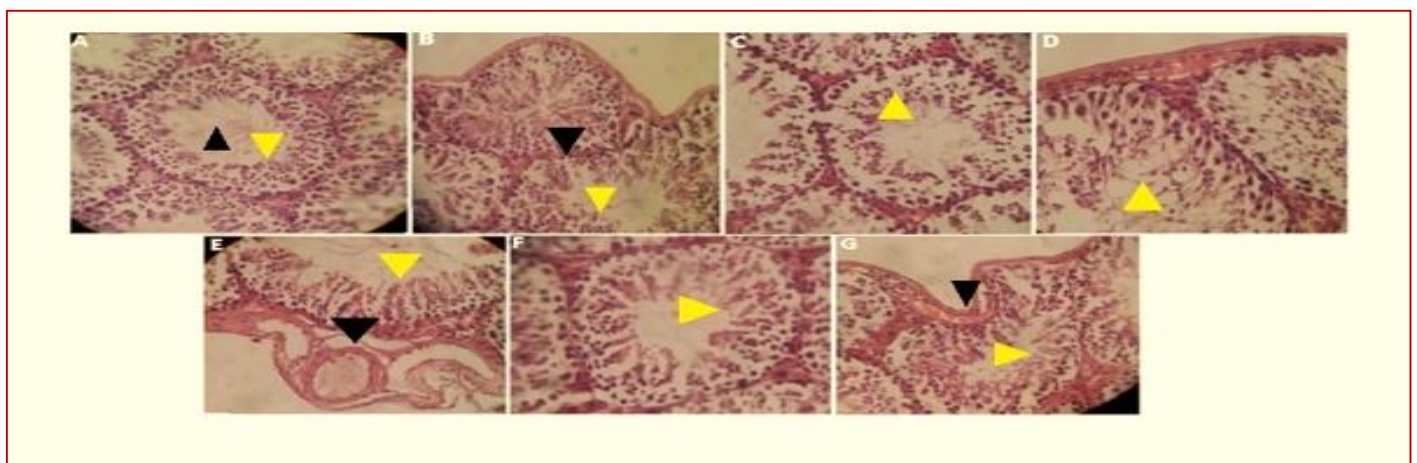


Fig. 1. Cross-sections of testis in A) Control, Central Canal with normal sperms (Black arrowhead) and normal spermatogenesis cells (Yellow arrowhead); B) Sham, Connective tissue (Black arrowhead) and normal cells (Yellow arrowhead); C) Mid-dose, Interrupted cells (Arrowhead); D) High-dose, Note the dissociation of spermatogenesis (Arrowhead); E) Vitamin E + Titanium dioxide, Normal cells (Yellow arrowhead) and Artery (Black arrowhead); F) Vitamin E, Note the normal cells (Arrowhead); G) Low-dose, Testicular capsule (Black arrowhead) and spermatogenesis cells (Yellow arrowhead). Hematoxylin and Eosin staining. Magnification (X 400). *Different letters show significant differences between groups. Numerical values were considered as Mean ± SEM ($p < 0.05$). *LD-TiO₂: Low dose titanium dioxide (2.5 mg/kg); MD-TiO₂: Mid-dose titanium dioxide (5 mg/kg); HD-TiO₂: High dose titanium dioxide (10 mg/kg); Vit E+TiO₂: Vitamin E+Titanium dioxide.

Discussion & Conclusion

Nanoparticles are frequently used in food products such as packaged foods. The toxicity of TiO₂ NPs acts on the reproductive function of animals, which has not received the attention it deserves (23). It has been demonstrated that the rutile form of TiO₂ NPs had a dose-dependent significant and adverse effect on the testicular mouse after using 100 or 1000 mg/kg (8). Besides, this form of TiO₂ NP has been deemed to be harmless after oral administration with a dose of 5 g/kg. However, there are reports that the anatase form of TiO₂ NPs can cause neural tissue damage in rats (12). Thus, this study suggests that TiO₂ NP may cause more injuries to testis tissue and then the concentration of testicular and serum MDA, TAC, and testosterone levels. In one study, reduced fecundity in female drosophila after treatment of TiO₂. Also, TiO₂ caused a reduction of fertility and sterility in male mice. Anatase TiO₂ NPs harmed structurally and functionally testicular mouse after a single maternal oral dose of 5 and 10 mg/kg (Table 1). This is important considering that these NPs have previously been deemed to be relatively harmless after oral administration at dose of 5 g/kg (9). However, prenatal exposure to the possibly more harmful anatase TiO₂ NPs causes neural tissue damage in rats (12, 10). Thus, our results suggest that TiO₂ NPs may be more harmful to testicular degeneration. It is not known how TiO₂ NPs cause developmental abnormalities; however, the production of ROS is believed to damage mammalian germline cells (17). It is probably due to the generated intracellular ROS after using TiO₂ nanoparticle. Moreover, the role of oxidative stress in TiO₂ toxicity has been demonstrated previously (24).

Studies have reported that Ag NPs had a significant adverse impact on the morphological changes in zebrafish embryos along with a myriad of other toxicological responses (25). However, all of the parameters studied here approximately diminished, especially with the highest dose (10 mg/kg; Table 1). No significant effects were seen in parameters of sertoli cells and repopulation indices with higher doses (5 and 10 mg/kg). A previous study demonstrated that larger Ag NPs may diminish pupation success more than smaller NPs; therefore, toxicity may not be easily classified according to particle size (26). However, the larger nanoparticles up to 10µm have less chance for

cellular absorption, so that they more restricted than smaller particles (27). Several studies have shown that particles only one tenth-sized were not found to cross the rat gastrointestinal mucosa (28). Consistently, our macroscopic findings exhibited inflammation of gastrointestinal tracts and urogenital apparatus only at 10 mg/kg dose. Previous studies have demonstrated that accumulation of TiO₂ NPs can be observed in the kidney, liver, lung, and spleen followed by intraperitoneal, intravenous, and/or dermal administration (5, 11). Wang et al. found that the use of TiO₂ (5 g/kg) caused hepatic injury after oral administration (7). Our findings are consistent with Fabian et al. who reported that the accumulation of TiO₂ in some tissues including liver, kidney, lung, and spleen in the rat; however, there were no remarkable toxic effects seen in these organs (5). In conclusion, due to possible public health hazards, general awareness regarding the use of titanium dioxide should be improved. More studies are needed to completely understand the TiO₂ influences on testiculopathies the cellular and/or molecular levels.

Acknowledgments

All authors especially thank the Departments of Anatomy, Histology, Embryology and Toxicology. This research was funded by the Faculty of Veterinary Medicine, Ferdowsi University of Mashhad, Mashhad, Iran (Number 2, Research Code: 51118).

Conflict of Interests

The authors declare that they have no conflicts of interest.

Reference

1. Oberdörster G, Maynard A, Donaldson K, Castranova V, Fitzpatrick J, Ausman K, et al. Principles for characterizing the potential human health effects from exposure to nanomaterials: elements of a screening strategy. *Particle and fibre toxicology*. 2005; 2(1):1-8.
2. Strobel C, Torrano AA, Herrmann R, Malissek M, Bräuchle C, Reller A, et al. Effects of the physicochemical properties of titanium dioxide nanoparticles, commonly used as sun protection agents, on microvascular endothelial cells. *Journal of nanoparticle research*. 2014; 16(1): 21-30.

3. Sayes CM, Wahi R, Kurian PA, Liu Y, West JL, Ausman KD, et al. Correlating nanoscale titania structure with toxicity: a cytotoxicity and inflammatory response study with human dermal fibroblasts and human lung epithelial cells. *Toxicological sciences*. 2006; 92(1): 174-185.
4. Takahashi Y, Mizuo K, Shinkai Y, Oshio S, Takeda K. Prenatal exposure to titanium dioxide nanoparticles increases dopamine levels in the prefrontal cortex and neostriatum of mice. *The Journal of toxicological sciences*. 2010; 35(5): 749-756.
5. Fabian E, Landsiedel R, Ma-Hock L, Wiench K, Wohlleben W, Van Ravenzwaay B. Tissue distribution and toxicity of intravenously administered titanium dioxide nanoparticles in rats. *Archives of toxicology*. 2008; 82(3): 151-157.
6. Oberdörster G, Sharp Z, Atudorei V, Elder A, Gelein R, Kreyling W, et al. Translocation of inhaled ultrafine particles to the brain. *Inhalation toxicology*. 2004; 16(6-7): 437-445.
7. Wang J, Chen C, Liu Y, Jiao F, Li W, Lao F, et al. Potential neurological lesion after nasal instillation of TiO₂ nanoparticles in the anatase and rutile crystal phases. *Toxicology Letters*. 2008; 183(1-3): 72-80.
8. Philbrook NA, Winn LM, Afrooz AN, Saleh NB, Walker VK. The effect of TiO₂ and Ag nanoparticles on reproduction and development of *Drosophila melanogaster* and CD-1 mice. *Toxicology and applied pharmacology*. 2011; 257(3): 429-436.
9. Sugibayashi K, Todo H, Kimura E. Safety evaluation of titanium dioxide nanoparticles by their absorption and elimination profiles. *The Journal of Toxicological Sciences*. 2008; 33(3): 293-298.
10. Shimizu M, Tainaka H, Oba T, Mizuo K, Umezawa M, Takeda K. Maternal exposure to nanoparticulate titanium dioxide during the prenatal period alters gene expression related to brain development in the mouse. *Particle and fibre toxicology*. 2009; 6(20): 6-20.
11. Chen J, Dong X, Zhao J, Tang G. In vivo acute toxicity of titanium dioxide nanoparticles to mice after intraperitoneal injection. *Journal of applied toxicology*. 2009; 29(4): 330-337.
12. Takeda K, Suzuki KI, Ishihara A, Kubo-Irie M, Fujimoto R, Tabata M, et al. Nanoparticles transferred from pregnant mice to their offspring can damage the genital and cranial nerve systems. *Journal of Health science*. 2009; 55(1): 95-102.
13. Dagani R. Nanomaterials: safe or unsafe?. *Chemical & engineering news*. 2003; 81(17): 30.
14. Warheit DB. Nanoparticles: health impacts? *Mater. Today*. 2004; 7: 32-35.
15. Service RF. American Chemical Society meeting. Nanomaterials show signs of toxicity. *Journal of Science*: 2003; 300(5617): 243.
16. Gurr JR, Wang AS, Chen CH, Jan KY. Ultrafine titanium dioxide particles in the absence of photoactivation can induce oxidative damage to human bronchial epithelial cells. *Toxicology*. 2005; 213(1-2): 66-73.
17. Braydich-Stolle LK, Schaublin NM, Murdock RC, Jiang J, Biswas P, Schlager JJ, et al. Crystal structure mediates mode of cell death in TiO₂ nanotoxicity. *Journal of Nanoparticle Research*. 2009; 11(6): 1361-1374.
18. Azad F, Nejati V, Shalazar-Jalali A, Najafi G, Rahmani F. Antioxidant and anti-apoptotic effects of royal jelly against nicotine-induced testicular injury in mice. *Environmental toxicology*. 2019; 34(6): 708-718.
19. Malekiyan R, Abdanipour A, Sohrabi D, Jafari Anarkooli I. Antioxidant and neuroprotective effects of lycopene and insulin in the hippocampus of streptozotocin-induced diabetic rats. *Biomedical Reports*. 2019; 10(1): 47-54.
20. Anbara H, Shahrooz R, Razi M, Malekinejad H, Najafi G. The effect of vitamin C on mice hemolytic anemia induced by phenylhydrazine: an animal model study using histological changes in testis, pre-implantation embryo development, and biochemical changes. *Iranian journal of basic medical sciences*. 2018; 21(7): 668-677.
21. Eskandari A, Heidari R, Farokhi F, Salimi Z, Ghasemi Z. Effect of aqueous extract from rhizome of *Cynodon dactylon* L. pers on renal and hepatic catalase activity and testicular histopathology in diabetic rats. *KAUMS Journal (FEYZ)*. 2012; 16(1): 9-16. [In Persian]
22. Kashyap ML, Hynd BA, Robinson K. A rapid and simple method for measurement of total protein in very low density lipoproteins by the Lowry assay. *Journal of Lipid Research*. 1980; 21(4): 491-495.
23. Gui S, Li B, Zhao X, Sheng L, Hong J, Yu X, et al. Renal injury and Nrf2 modulation in mouse kidney following chronic exposure to TiO₂ nanoparticles. *Journal of agricultural and food chemistry*. 2013; 61(37): 8959-8968.



24. Abou-Zeid SM, Allam T, El Bahrawy A, Mohamed A. Ameliorating effects of green tea on ethephon-induced immunotoxicity and oxidative stress in mice. *International Journal of Pharma Sciences & Scientific Research*. 2018; 4(1): 1-9.
25. Asharani PV, Wu YL, Gong Z, Valiyaveetil S. Toxicity of silver nanoparticles in zebrafish models. *Nanotechnology*. 2008; 19(25): 255102 (8pp).
26. Gorth DJ, Rand DM, Webster TJ. Silver nanoparticle toxicity in *Drosophila*: size does matter. *International journal of nanomedicine*. 2011; 6: 343-350.
27. Li N, Sioutas C, Cho A, Schmitz D, Misra C, Sempf J, et al. Ultrafine particulate pollutants induce oxidative stress and mitochondrial damage. *Environmental health perspectives*. 2003; 111(4): 455-460.
28. Jani PU, McCarthy DE, Florence AT. Nanosphere and microsphere uptake via Peyer's patches: observation of the rate of uptake in the rat after a single oral dose. *International journal of pharmaceuticals*. 1992; 86(2-3): 239-246.

مقاله پژوهشی

بررسی آثار بهبودی ویتامین ای بر روی تغییرات مورفولوژیکی و هیستولوژیکی و فاکتورهای استرس اکسیداتیو در بیضه موش سوری تحت درمان با نانو ذرات تیتانیوم دی اکساید

رامین جهانگیر فرد^۱، احمدرضا راجی^{۲*}، امیر مقدم جعفری^۳، حسین نورانی^۴

۱. دانشکده دامپزشکی، دانشگاه ارومیه، ارومیه، ایران
۲. گروه بافت شناسی مقایسه‌ای، دانشکده دامپزشکی، دانشگاه فردوسی مشهد، مشهد، ایران
۳. گروه سم شناسی، دانشکده دامپزشکی، دانشگاه فردوسی مشهد، مشهد، ایران
۴. گروه آسیب شناسی، دانشکده دامپزشکی، دانشگاه فردوسی مشهد، مشهد، ایران

تاریخ پذیرش مقاله: ۱۳۹۹/۰۴/۱۷

تاریخ دریافت مقاله: ۱۳۹۹/۰۲/۲۶

چکیده

زمینه و هدف: نانوذرات تیتانیوم دی اکساید ترکیبات شیمیایی هستند که در مواد صنعتی و غذایی از جمله مواد آرایشی، خمیردندان، مواد رنگی و سفید کردن شیر بدون چربی به وفور استفاده می‌شود. ویتامین E یک ترکیب رژیم غذایی که به عنوان یک آنتی اکسیدان مہاری رادیکال‌های آزاد می‌باشد. هدف از این مطالعه بررسی اثر محافظتی ویتامین E بر تغییرات هیستومورفومتری، پارامترهای بیوشیمیایی و استرس اکسیداتیو همچنین غلظت تستوسترون است.

مواد و روش‌ها: در مطالعه حاضر، ۳۵ موش بالغ نر به ۷ گروه کنترل و آزمایشی تقسیم بندی شدند. گروه‌های آزمایشی تیتانیوم دی اکساید را با دوز ۲/۵، ۵ و ۱۰ میلی گرم بر کیلوگرم و همچنین گروه کنترل مثبت ویتامین E را با دوز ۱۰۰ واحد بین المللی به صورت خوراکی دریافت کردند. بعد از تیمار، حیوانات از طریق جابجایی مہره‌های گردنی آسان کشی شدند و نمونه‌های بیضه اخذ شدند. سطح $p < 0/05$ معنی‌دار در نظر گرفته شد. **نتایج:** نتایج هیستومورفومتری نشان داد که وزن بیضه و بدن، ضخامت کپسول بیضه، قطر لوله‌های منی ساز، ارتفاع اپیتلیوم زایا، شاخص‌های اسپرماتوژنز و میوز کاهش یافتند. در حالی که ضریب سلول‌های سرتولی و ضریب جایگزینی مجدد سلول‌های اسپرماتوگونی تغییرات معناداری نداشتند. همچنین، نتایج بیوشیمیایی نشان داد افزایشی در مالون دی آلدئید و کاهش در ظرفیت آنتی اکسیدانی تام، فعالیت آنزیم کاتالاز، میزان پروتئین غلظت تستوسترون مشاهده شد ($p < 0/05$).

نتیجه گیری: نانوذرات TiO_2 با دوز بالا باعث ایجاد اثرات سوء پاتولوژیکی می‌گردد. در حالی که ویتامین E توانست اثرات سمی تیتانیوم دی اکساید را بر روی بافت بیضه حیوانات مورد مطالعه بهبود بخشد.

کلمات کلیدی: هیستومورفومتری، موش، بیضه، تیتانیوم دی اکساید، ویتامین E

*نویسنده مسئول: احمدرضا راجی، گروه بافت شناسی مقایسه‌ای، دانشکده دامپزشکی، دانشگاه فردوسی مشهد، مشهد، ایران.

Email: rajireza@um.ac.ir

<https://orcid.org/0000-0002-8192-8374>