



A Case of Isolated Congenital Mitral Regurgitation Presenting with Heart Failure in Infancy

Maruti Yamanappa Haranal^{1,*}, Joseph Xavier¹, Hetal Mehta², Sridhar Melagiriappa³

¹Department of Cardio-Thoracic and Vascular Surgery, Fortis Hospitals, Bengaluru, Karnataka, India

²Department of Cardiology, Fortis Hospitals, Bengaluru, Karnataka, India

³Department of Pediatrics, Fortis Hospitals, Bengaluru, Karnataka, India

ARTICLE INFO

Article Type:
Case Report

Article History:
Received: 23 Jul 2017
Revised: 22 Dec 2017
Accepted: 24 Dec 2017

Keywords:
Congenital
Heart Failure

ABSTRACT

Isolated congenital Mitral Regurgitation (MR) occurring in infancy is rare (< 0.4% of live births with congenital heart disease). Presentation in infancy with symptoms of heart failure reflects the severity of the condition and needs mandatory surgical correction to prevent progressive deterioration and death. Isolated Congenital MR in infancy is a surgical challenge and various surgical techniques employed for valve repair have to be judiciously used. We report a case of isolated congenital MR presenting in infancy, who underwent successful surgical correction.

1. Introduction

Even though rare, congenital malformations of the mitral valve present with a wide range of morphologic abnormalities, are often complex, and affect various segments of the valvular apparatus. Often, it is difficult to define the predominant lesion and its effect on the valve function. Isolated congenital mitral valve disease is present in < 0.4% of patients born live with congenital heart defects. Mitral regurgitation (MR) occurring in association with other congenital cardiac anomalies is common, but MR occurring as an isolated entity due to abnormal mitral valve is rare.

2. Case Presentation

A ten month old baby, with a known congenital heart disease, presented with respiratory distress of three months duration. On examination, the child appeared to be breathing faster, with a respiratory rate of 36 breaths per minute, and there were no signs of distress. The heart rate was 130 beats per minute and the blood pressure was 80/50 mmHg. The precordium appeared hyperdynamic. On auscultation, there

was a grade 4/6 pansystolic murmur in the mitral area with radiation to the axilla and the back. Auscultation of the chest showed bilateral basal fine crepitations. On examination, the abdomen and central nervous system were normal.

A clinical diagnosis of severe MR was made aiming to rule out anomalous left coronary arising from pulmonary artery (ALCAPA), Aorto Pulmonary (AP) window or any other large left to right shunt resulting in MR. On evaluation, ECG showed normal sinus rhythm with a heart rate of 140 beats/min, biventricular enlargement by voltage, and evidence of LV volume overload. Chest X Ray revealed cardiomegaly (CTR > 60%) and plethoric lung fields.

2 D Echo showed AML prolapse and restricted PML with severe MR, and did not show any AP window or other left to right shunts nor ALCAPA. The LV function was normal. There were no other associated cardiac anomalies.

Based on the above findings, a diagnosis of isolated congenital MR was made. We started anti-failure treatment consisting of oral diuretic, ACE inhibitor and digitalis. Intraoperatively, the baby had grossly dilated tortuous coronaries possibly due to the hyperdynamic state (Figure 1a).

Conventional CPB with aortic and bicaval cannulation was established; blood cardioplegia at blood temperature (32°C) was used to arrest the heart following aortic cross clamp.

*Corresponding author: Maruti Y Haranal, Department of Cardiothoracic and Vascular Surgery Fortis Hospitals, #154/9, Bannerghatta Road, Opp. IIM-B, Bengaluru-560076, India, Tell: +91-9900732599
E-mail: marusurg@gmail.com.

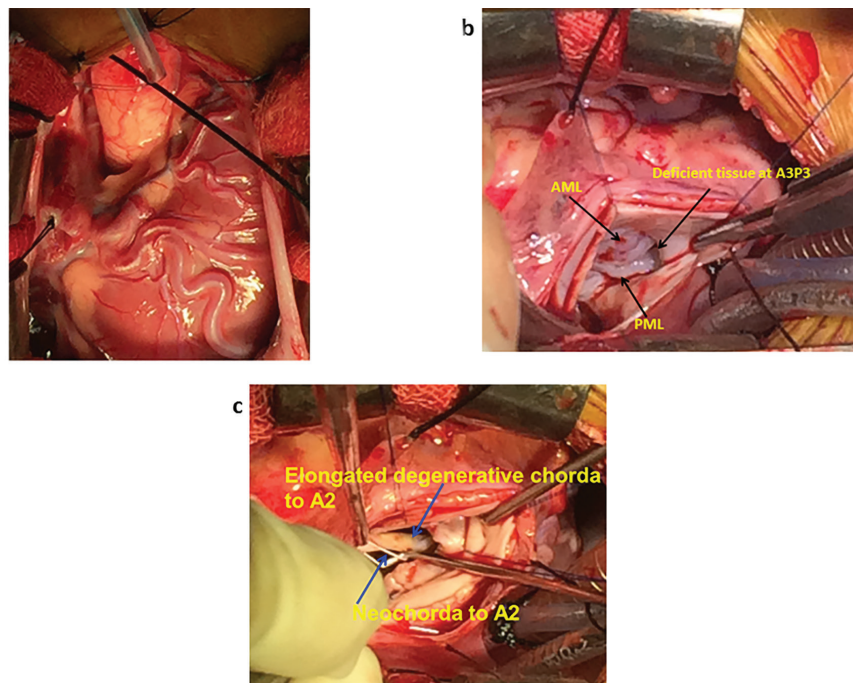


Figure 1. Intraoperative Pictures (1a. Dilated Tortuous Coronaries, 1b. Absent Leaflet Tissue at Posteromedial Commissure in the Region of A3P3, 1c. Thickened Degenerative Primary Chorda to A2 and Neochorda to A2)

Mitral valve was approached through trans-septal approach. Mitral valve inspection revealed absent leaflet tissue at the posteromedial commissure in the region of A3P3 (Figure 1b) and elongated and thickened AML with thickened degenerative primary chorda to A2 with AML prolapse (Figure 1c). Anterolateral commissure was normal. LV appeared trabeculated (Figure 2a). The mitral annulus was normal for the age. Both papillary muscles were present.

Kay's stitch was taken at the posteromedial commissure with 5-0 polypropylene suture as a horizontal mattress suture so as to approximate the end of the posteromedial commissure where there was deficiency in the valve tissue (Figure 2b).

A neochorda was created with a 5-0 Polytetrafluoroethylene (PTFE) suture that was passed in a 'U' fashion from the base of the anterolateral papillary muscle into the centre of the free edge of the AML at the A2 region (Figure 1c), judging the height of the neochorda by matching the coaptation level of the AML to the PML using valve hooks. This length of the neochorda was fixed with a ligaclip and then the knots were tied down to this predetermined level. The ligaclip was then removed. Saline insufflation was done and the competence of the mitral valve was confirmed.

The patient came off bypass in single attempt in sinus rhythm with minimal inotropic support. Post-CPB TEE

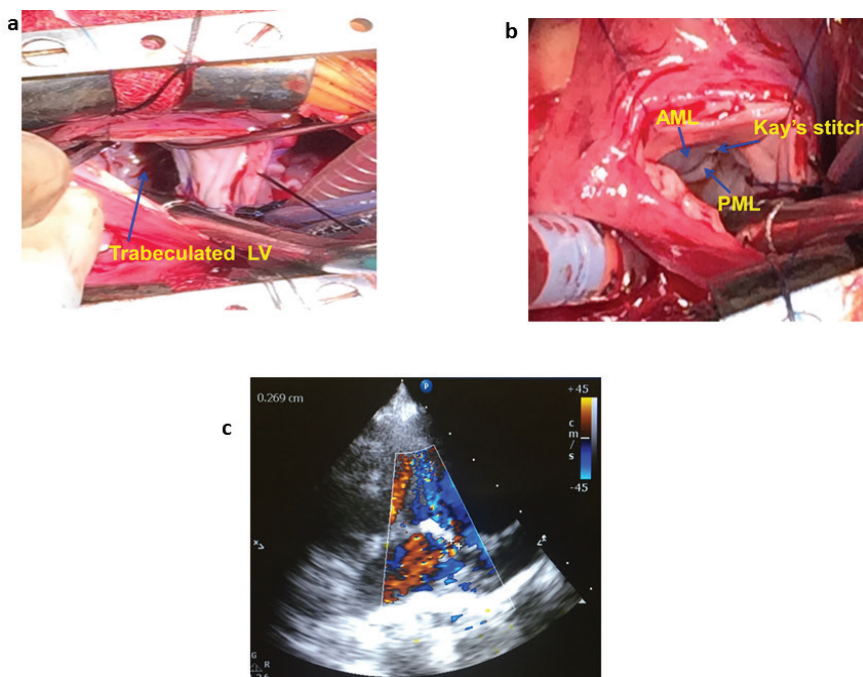


Figure 2. Intraoperative Pictures (2a. LV Trabeculated, 2b. Kay's Stitch Taken at Posteromedial Commissure, 2c. Postop 2D Echo)

Archives of SID

showed mild central jet with normal biventricular function. Perioperative period was uneventful. Post-op 2D ECHO (Figure 2c) at six months showed trivial central MR with good biventricular function. The baby is under follow up and is doing well.

3. Discussion

Natural history of untreated isolated congenital MR ends in fatality. Mitral valve repair during the first year of life remains the treatment of choice. Good surgical results can be achieved by adhering to the principles of mitral valve repair: AML length should be preserved, leaflets should be augmented with pericardium treated with 0.6% glutaraldehyde, and lengthened chordae should be shortened if there is no degenerative change. Using PTFE Neochorda, although debatable in children, can be safely used (1) as any tethering effect during growth will be accommodated by the growing leaflets' surface of contact. Commissural plication can be done where indicated to reduce the annular dilatation at the commissures. In our case, it also helped to cover the deficiency of the valve leaflet at this commissure. Some form of annuloplasty band should be used posteriorly to reduce the dilated annulus. (Our practice is to use a strip of glutaraldehyde treated autologous pericardium or a stiff Teflon strip).

When indicated, surgical repair provides good long-term results (2). In paediatric population, mitral valve repair is always preferable when possible and most often possible. Mitral valve replacement has been done and appears to provide acceptable long-term results (3).

Because suboptimal primary repair is a significant predictor for reoperation, the successful management of congenital mitral valve regurgitation is dependent on the detailed preoperative assessment of the anatomical substrate (4).

In our study, there was ample AML length. PML leaflet was not well developed, but it was not dysplastic and had normal chordal attachments. The posterior mitral annulus was not dilated. (In our limited experience, we feel that unlike secondary MR which is brought about by annular dilatation, in isolated congenital MR the annulus remains undilated).

Here, the posteromedial commissural part of the annulus was stretched out with neither chordal support nor leaflet attachment. The A3 and P3 segments of the mitral valve were not developed. This was the primary cause of the regurgitation. AML thickening and elongation, along with A2 chordal lengthening, were attributed to degeneration.

A good repair was achieved by plicating the posteromedial commissure with a Kay's commisuroplasty stitch using 5 - 0 polypropylene Dacron pledgetted stitch and reducing the AML prolapse using 5 - 0 PTFE neochorda. The annuloplasty ring was not required as the annulus was normal.

Okamoto Y et al. reported a case of isolated congenital MR secondary to a partial defect near the postero-medial commissure of the anterior leaflet and mild prolapse of the anterior leaflet. They performed direct closure of the defect of the leaflet, and also added annuloplasty at the posteromedial commissure by modified Kay method (5). Also, a study by Lorier et al. showed that the unsupported mitral valvuloplasty with Wooler's technique had a low surgical risk and good

long-term results. The use of prosthetic rings in these patients is considered unnecessary (6).

3.1. Conclusion

Congenital MR occurring as an isolated entity in infancy due to abnormal mitral valve is rare. This has to be differentiated from secondary causes of MR in infancy; failure to do so leads to significant mortality. Surgical mitral valve repair is necessary to ensure survival, which can be successfully carried out if one adheres to the principles of mitral valve repair. This case is presented to emphasize that the rare occurrence of isolated congenital mitral regurgitation in infancy can be fatal if unrecognized.

3.2. Ethical approval

All procedures performed in studies involving human participants were in accordance with the ethical standards of the institutional and/or national research committee and with the 1964 Helsinki Declaration and its later amendments or comparable ethical standards.

3.3. Informed Consent

Informed consent was obtained from all individual participants included in the study.

Acknowledgements

There is no acknowledgement.

Authors' Contribution

All the authors have equal roles in manuscript preparation and editing.

Financial disclosure

The authors declare that there is no conflict of interests.

Funding/Support

This study was not supported.

References

1. Sai S, Konishi A, Sato M, Matsuo S, Nitta M. Efficacy of Artificial Chordal Reconstruction for Idiopathic Severe Mitral Regurgitation Due To Chordal Rupture in Infancy. *Seminars in thoracic and cardiovascular surgery*. 2015;**27**(3):321-5.
2. Kalfa D, Vergnat M, Ly M, Stos B, Lambert V, Baruteau A, et al. A standardized repair-oriented strategy for mitral insufficiency in infants and children: midterm functional outcomes and predictors of adverse events. *The Journal of thoracic and cardiovascular surgery*. 2014;**148**(4):1459-66.
3. Henaine R, Nloga J, Wautot F, Yoshimura N, Rabilloud M, Obadia JF, et al. Long-term outcome after annular mechanical mitral valve replacement in children aged less than five years. *The Annals of thoracic surgery*. 2010;**90**(5):1570-6.
4. Oppido G, Davies B, McMullan DM, Cochrane AD, Cheung MM, d'Udekem Y, et al. Surgical treatment of congenital mitral valve disease: midterm results of a repair-oriented policy. *The Journal of thoracic and cardiovascular surgery*. 2008;**135**(6):1313-20; discussion 20-1.
5. Okamoto Y, Tomino T, Satoh H, Hohjo Y, Hamawaki M, Nagashima M, et al. [The isolated congenital mitral regurgitation due to a partial defect of the anterior leaflet]. *Kyobu geka The Japanese journal of thoracic surgery*. 2003;**56**(3):231-4.
6. Lorier G, Kalil RA, Hoppen GR, Barcellos C, Teleo N, Homs Netto A, et al. Unsupported valvuloplasty in children with congenital mitral valve anomalies. Late clinical results. *Arquivos brasileiros de cardiologia*. 2001;**76**(3):209-20.