



Idiopathic Right Atrial Enlargement (Volume: 700 cc) in a Young Man: A Case Report

Zahra Khajali¹,^{ORCID} Fateme Jorfi^{1,*},^{ORCID} Mozhghan Parsaei¹, Mohammad Kasaei¹, Mehrdad Jafarifesharaki²

¹Rajaei Heart Medical and Research Center, Iran University of Medical Sciences, Tehran, IR Iran

²School of Medicine, Shahid Beheshti University of Medical Sciences, Tehran, IR Iran

ARTICLE INFO

Article Type:
Case Report

Article History:
Received: 16 Apr 2019
Revised: 21 Sep 2019
Accepted: 5 Oct 2019

Keywords:
Ebstein Anomaly
Heart Atria
Cardiomyopathies
Congenital Heart Disease

ABSTRACT

Idiopathic right atrial dilation is known as a congenital anomaly in the absence of obvious causes that produce right ventricular pressure or volume overload. Congenital giant right atrium can cause functional tricuspid regurgitation, arrhythmia, and right-sided heart failure. A massive Idiopathic Dilation of Right Atrium (IDRA) was reported in a 30-year-old man presented with intermittent palpitation and dyspnea on effort. Transthoracic echocardiography revealed huge right atrium leading to severe tricuspid regurgitation, moderate right ventricular enlargement with moderate dysfunction, and no evidence of other valvular heart diseases increasing the right ventricular pressure or volume, left to right shunt, and Ebstein anomaly. Cardiac Magnetic Resonance Imaging (MRI) confirmed the right atrial enlargement. The estimated right atrium volume by MRI was about 700 mL. With regard to the patient's symptoms, he was scheduled for surgical treatment. The patient underwent partial surgical resection of the dilated right atrium wall and mechanical tricuspid valve replacement because the tricuspid valve was unrepairable on the operation table. Idiopathic right atrial enlargement is a very rare disease and may be easily confused with other anomalies that lead to right atrial enlargement, such as Ebstein anomaly. Hence, the probability of this pathology should be kept in mind when the usual etiologies of right atrial enlargement are excluded. Partial surgical resection of the dilated right atrium is an effective therapeutic option in symptomatic patients.

1. Introduction

Idiopathic right atrial dilation is known as a congenital anomaly in the absence of obvious causes that produce right ventricular pressure or volume overload (1). This rare anomaly can present with atrial arrhythmia, symptoms of right-sided heart failure, and thromboembolic events. As suggested in the previous reports, this anomaly does not seem to be benign.

The present report aims to describe a young man with very severe right atrial dilation in the absence of obvious causes who presented with intermittent palpitation and exercise dyspnea.

2. Case Presentation

A 30-year-old man was referred to our center because of prominent right atrial dilation in transthoracic

echocardiography in the absence of other anomalies leading to right atrial enlargement. His chief complaint was dyspnea on effort at a level of slightly more than usual activities and intermittent palpitation without any history of syncope. He was candidate for electrophysiological study and ablation of atrial flutter, but it was not done due to unknown reasons and there was no documentation regarding this procedure. The patient also had no family history of congenital heart diseases or premature sudden cardiac death. He was on medications, including metohexal 47.5 mg daily and furesmide 20 mg daily. His blood pressure was 110/70 mmHg and his pulse rate was regular and about 75 beats/min. The O₂ saturation was 95% in room air at rest. No obvious heart murmur was heard, except for a systolic murmur of tricuspid regurgitation. No sign of lower extremity edema or ascites was detected, as well. Blood tests were almost within the normal ranges. No eosinophilia was found. Electrocardiography recorded a regular sinus rhythm with a rate of 75 beats/min, normal P wave, and

*Corresponding author: Fateme Jorfi, Rajaei Heart Medical and Research Center, Iran University of Medical Sciences, Tehran, Iran. Cellphone: +98-09163082294, postal code: 1995614331, Email: fajorfi@gmail.com.

Archives of SID

depression of the ST segment in the right precordial leads.

Chest radiography showed prominent right cardiac border and slight cardiomegaly without increased bronchovascular markings. Transthoracic two-dimensional echocardiography was also done and demonstrated a huge right atrium with about 12.2 cm length in the four chamber view and the estimated volume of about 631 cc with a moderate smoke pattern and no clots, suggesting the congenital origin of the right atrial aneurysm (Figure 1, Video 1 [To watch the videos, please refer to the html format]). The right ventricle was moderately enlarged with moderate systolic dysfunction. The pulmonary artery pressure was normal. The diameter of the pulmonary artery was normal, as well. Tricuspid valve was prolapsed with severe regurgitation, but no tricuspid stenosis and no evidence of tricuspid valve leaflets displacement and Ebstein anomaly were detected. The size of the left ventricle was normal and its ejection fraction was preserved and about 50%. Mitral valve was prolapsed with mild mitral regurgitation. The left atrium was not enlarged. A small Patent Foramen Ovale (PFO) was detected by contrast study. No signs of pericardial effusion were found.

In order to clarify the results of transthoracic echocardiography, cardiac magnetic resonance imaging with Late Gadolinium Enhancement (LGE) was performed by 1.5 T scanner. Cine MR showed normal left ventricular size with normal systolic function. A mild dilation of the right ventricle was also observed (RVEDVI: 84mL/m²) and the right ventricular ejection fraction was about 54%. The right atrium was severely enlarged (volume: 700 mL). Moreover, the mitral valve was prolapsed with mild regurgitation. Tricuspid valve had severe regurgitation with partial distortion of the anterior leaflet of tricuspid valve due to severe dilation of the right atrium without apical displacement of any of its leaflets. No sign of any congenital heart disease was found. There was also no LGE and no evidence of arrhythmogenic right ventricular cardiomyopathy (Figure 2, Video 2 [To watch the videos,

please refer to the html format]).

Based on the aforementioned findings, the diagnosis of idiopathic right atrial enlargement was confirmed. Considering the patient's symptoms, surgical resection of a portion of the huge right atrium and tricuspid valve repair was planned. The tricuspid valve was not repairable; therefore, the surgeon decided to replace it with mechanical valve (30 St. Jude).

Specimen of the right atrial wall was sent to the histology laboratory and the results of pathological examination showed myocardial tissue with foci of fibrosis, atrophy, and myocytolysis without any evidence of inflammation.

3. Discussion

Right atrial size is a reflection of right-sided filling pressure and volume. The most frequent causes of right atrial enlargement are atrial fibrillation and tricuspid regurgitation (2).

In the present case, the diagnosis of Idiopathic Dilation of the Right Atrium (IDRA) was made after all other lesions known to produce it were excluded.

IDRA can present with atrial arrhythmia, systemic embolism, right-sided heart failure, and functional tricuspid regurgitation. In some reports, IDRA showed inevitable progression to right-sided heart failure. A congenital origin of this condition has also been suggested.

Dj Kurz evaluated the long-term outcome of familial IDRA in 14 members of a pedigree. During the 23-year follow-up, severe IDRA induced atrial fibrillation, systemic embolism, and symptoms of right-sided heart failure without systolic dysfunction. Mild IDRA manifested during the middle ages and was then followed by a gradual increase in the right atrial size, resulting in clinical presentation. The distribution of cases among consecutive generations in that study suggested a genetic role for idiopathic right atrial dilation (3). There is also a probability that such cases of severe IDRA are the presentation of so-called atrial

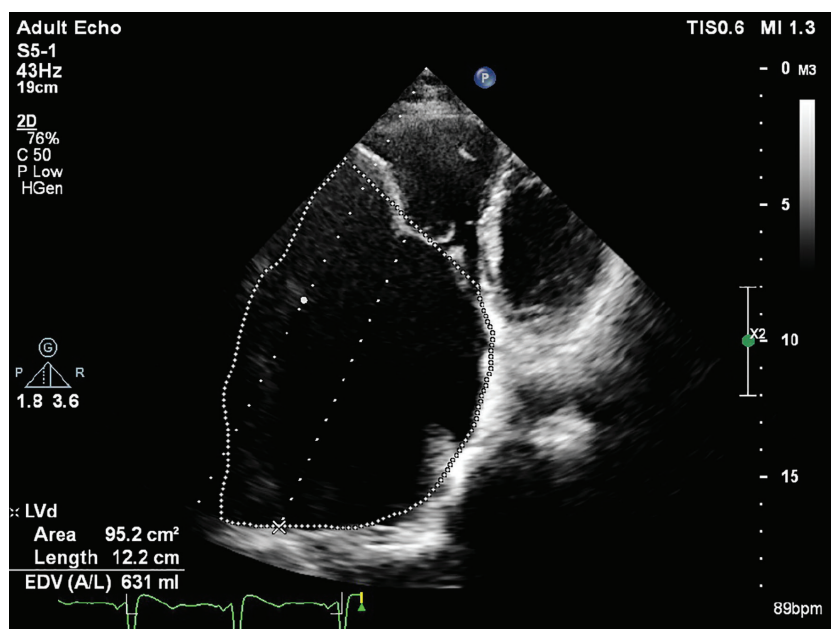


Figure 1. The Right Atrial Volume Estimated by Transthoracic Echocardiogram in Apical View

Video 1. The Huge Inappropriate Right Atrial Enlargement Seen in Apical Four-Chamber Echocardiographic View

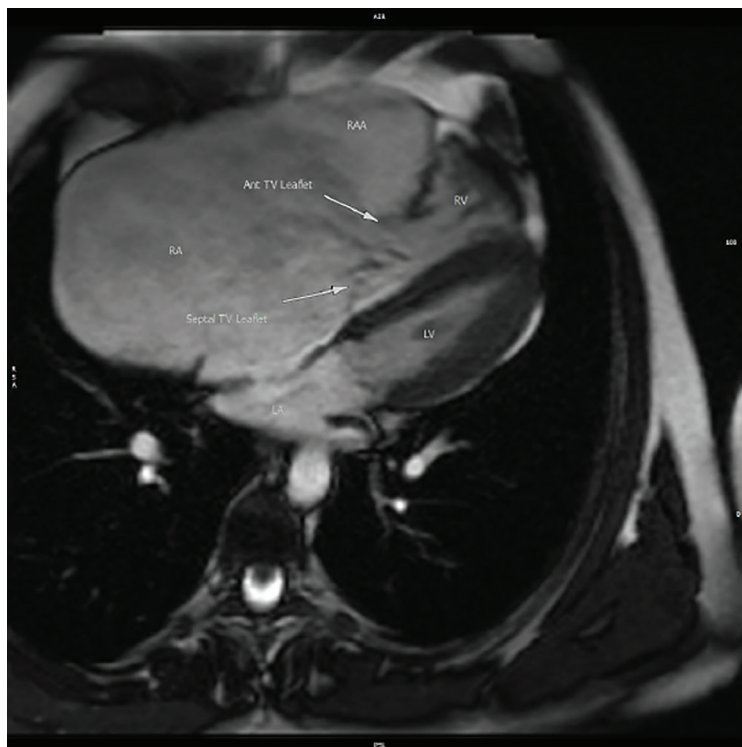


Figure 2. Magnetic Resonance Imaging of the Severely Dilated Right Atrium in the Four-Chamber View

Video 2. Axial Cine MR Showing Severe Right Atrial Enlargement and Severe Tricuspid Regurgitation with Partial Distortion due to Severe Right Atrial Dilation without Apical Displacement of Any of Its Leaflets

cardiomyopathy (4). EHRA/HRS/APHS/SOLAECE expert consensus on atrial cardiomyopathies defined it as any complex structural, architectural, contractile, or electrophysiological changes affecting the atria with the potential to produce clinically-relevant manifestations (5).

Lore Tenckloff reported a case of IDRA presented with sudden cardiac death. Hence, this anomaly should not be considered as benign. It is important to define this anomaly as a clinical entity that can be easily treated by surgical excision of a portion of the enlarged atrium in patients with severe and resistant symptoms to medical therapy (6).

The present case had the symptoms of heart failure and intermittent palpitation. Thus, surgical approach directed to partial resection of the severely enlarged right atrium and correction of the secondary tricuspid regurgitation by tricuspid valve repair seemed to be the best therapeutic approach.

In conclusion, IDRA is a rare disease and may be easily confused with other anomalies that lead to right atrial enlargement, such as Ebstein anomaly. Therefore, the probability of this pathology should be kept in mind when the usual etiologies of right atrial enlargement are excluded. Because of the rarity of this anomaly, there is very little evidence-based data about its management and treatment. Surgical resection, anticoagulation, catheter-based ablation, watchful waiting without medical intervention, and compensation of the heart failure symptoms are the therapeutic options for right atrial enlargement and the associated presentations.

3.1. Informed Consent

The presented case saw and agreed with the submitted paper.

Acknowledgements

There is no acknowledgments.

Authors' Contribution

Manuscript writing: F.J., data preparation: M.P, M.J, and M.K, concept and development of the manuscript: Z.K.

Financial disclosure

There is no financial disclosure.

Funding/Support

The authors received no financial support for the research, authorship, and/or publication of this article.

References

- Hofmann SR, Heilmann A, Hausler HJ, Dahnert I, Kamin G, Lachmann R. Congenital idiopathic dilatation of the right atrium: antenatal appearance, postnatal management, long-term follow-up and possible pathomechanism. *Fetal diagnosis and therapy*. 2012;**32**(4):256-61.
- Zipes DP, Libby P, Bonow RO, Mann DL, Tomaselli GF. *Braunwald's Heart Disease E-Book: A Textbook of Cardiovascular Medicine*. Elsevier Health Sciences; 2018.
- Kurz DJ, Oechslin EN, Kobza R, Jenni R. Idiopathic enlargement of the right atrium: 23 year follow up of a familial cluster and their unaffected relatives. *Heart*. 2004;**90**(11):1310-4.
- Sinitsyn V, Merzhina E, Bazaeva E, Myasnikov R. Idiopathic dilatation of the right atrium: A case report.
- Goette A, Kalman JM, Aguinaga L, Akar J, Cabrera JA, Chen SA, et al. EHRA/HRS/APHS/SOLAECE expert consensus on atrial cardiomyopathies: definition, characterization, and clinical implication. *Ep Europace*. 2016;**18**(10):1455-90.
- Surace FC, Iezzi F, Colaneri M, Pozzi M. Surgical Treatment of Idiopathic Enlargement of the Right Atrium. *Case reports in surgery*. 2018;**2018**:7241309.