

## Sinus Tarsi Syndrome: Diagnosed on $^{99m}\text{Tc}$ -MDP bone SPECT/CT

Abhishek Mahato<sup>1\*</sup>, Partha B Mukherjee<sup>2</sup>, Deepak Kumar Jha<sup>1</sup>, A G Pandit<sup>2</sup>, Vigneshwaran M<sup>2</sup>

<sup>1</sup> DNB Nuclear Medicine, Department of Nuclear Medicine, Army Hospital Research & Referral, New Delhi, India

<sup>2</sup> Department of Nuclear Medicine, Army Hospital Research & Referral, New Delhi, India

### ARTICLE INFO

*Article type:*

Case Report

*Article history:*

Received: 22 Jan 2020

Revised: 22 Apr 2020

Accepted: 4 May 2020

*Keywords:*

Sinus Tarsi Syndrome

Ankle sprain

$^{99m}\text{Tc}$ -MDP

SPECT-CT

Bone scan

### ABSTRACT

Sinus Tarsi Syndrome is a cause of chronic ankle instability and pain. MRI of the ankle has been the modality of choice for diagnosing the condition. However, SPECT-CT offers an alternate modality for diagnosing and evaluation of the condition. We present the case of a footballer who was suffering from chronic right leg pain despite receiving physiotherapy. He was being managed as a case of a chronic ankle sprain. Meanwhile, he was referred to the department as radiology for MRI of the ankle could not be performed as the patient felt claustrophobic. The patient subsequently underwent a  $^{99m}\text{Tc}$ -MDP Bone scan. He was diagnosed to be suffering from sinus tarsi syndrome as it showed a characteristic pattern noted on  $^{99m}\text{Tc}$ -MDP Bone scintigraphy. This case report reveals the potential of SPECT-CT as an alternative in the evaluation of chronic ankle sprain to MRI in segment of cases where MRI is not performed due to various reasons.

► Please cite this paper as:

Mahato A, Mukherjee P B, Jha D K, Pandit A G, Vigneshwaran M. Sinus Tarsi Syndrome: Diagnosed on  $^{99m}\text{Tc}$ -MDP bone SPECT/CT. Asia Ocean J Nucl Med Biol. 2020; 8(2):153-156.doi: 10.22038/AOJNMB.2020.45897.1309

### Introduction

Skeletal scintigraphy or bone scan in common parlance is an investigation vital in the nuclear medicine department. Though appears simple it has got plethora of applications which is limited only by our knowledge of the pathogenesis. Though most of the applications of the bone scan have been replaced by anatomical imaging none of the imaging modality answers the functional pathological state as better as bone scan. In some of the scenarios bone scan becomes vital non-invasive tool of evaluation helping in choosing the time to intervention. We present a case of chronic ankle sprain which went undermanaged due to lack of conclusive diagnosis. Chronic ankle sprain is mainly caused due to ligament injury, bony injury, osteochondral injury and mechanical instability with a small percentage contributed by

impingement syndrome and soft-tissue pathology (1, 2). Though MRI is the gold standard in evaluation of chronic ankle sprain several case series have proposed the potential role of SPECT/CT in evaluation of lesions of foot and ankle (3, 4). These case series propose SPECT/CT as a modality of choice in cases where a) MRI is equivocal b) claustrophobic patients c) patient with metal implant d) MRI is inconclusive due to lack of edema (3).

As in our case MRI was not feasible due to claustrophobia of the patient, bone scan with  $^{99m}\text{Tc}$ -MDP (Methylene Diphosphonate) diagnosed the sinus tarsi syndrome. The case report highlights the impact bone scan can bring in a small subset of patient affected with sports injuries where MRI (Magnet Resonance Imaging) is not feasible due to various reasons. Also

\* Corresponding author: Abhishek Mahato. DNB Nuclear Medicine, Department of Nuclear Medicine, Army Hospital R&R, New Delhi-110010, India. Tel: 9821420190; E-mail: dr.abhi22ndleo@gmail.com

© 2020 mums.ac.ir All rights reserved.

This is an Open Access article distributed under the terms of the Creative Commons Attribution License (<http://creativecommons.org/licenses/by/3.0>), which permits unrestricted use, distribution, and reproduction in any medium, provided the original work is properly cited.

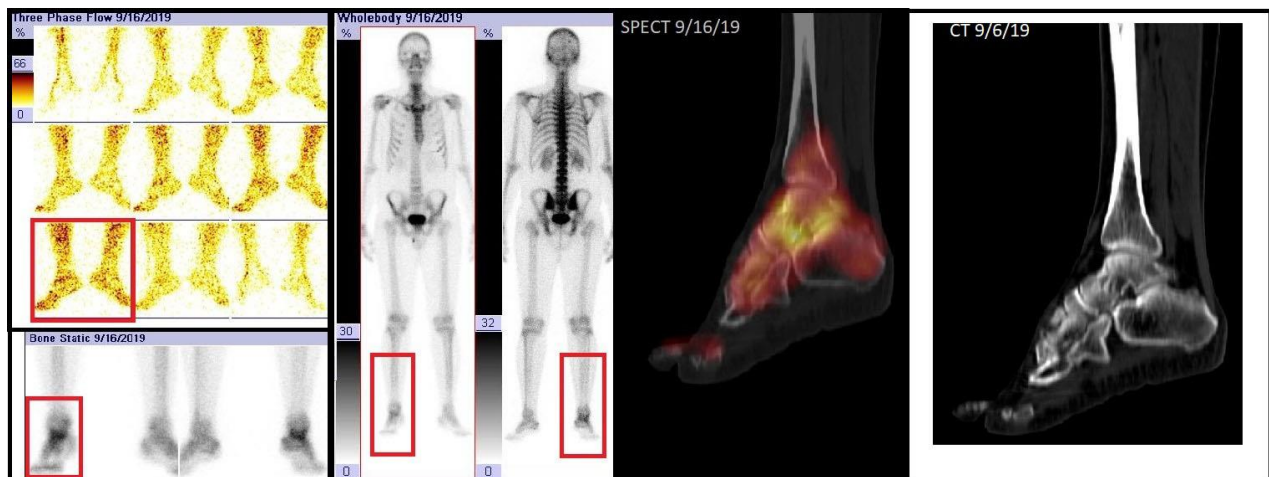
described is the symptomatology and the imaging characteristic of sinus tarsi syndrome on a bone scan.

### Case Report

31 year old male football player suffered ankle sprain of right foot during practice. Initial clinical examination revealed tenderness on the lateral aspect of ankle with restricted movement at ankle due to pain. His initial radiograph did not reveal any bony trauma or dislocation or subluxation of the bones. He was provided with ice pack and compression dressings. After the initial management of ankle sprain the patient visited the physiotherapist for early rehabilitation. Despite a specialized care he continued to have pain in his right ankle. The patient was not able to walk with proper weight bearing on both legs even after 03 (three) months of trauma. This made it difficult to join the football team. Clinical examination of the right foot revealed a tender point on the lateral aspect of the mid-foot. Radiograph of the foot was essentially normal and did not reveal any fracture, dislocation or subluxation. MRI scan of the ankle was asked for by the treating physician but the same could not be conducted as patient felt claustrophobic. Left with not many choices bone scan was asked for to evaluate the underlying pathology of the pain.

Three phase bone scan of the right feet was performed after intravenous administration of 370 MBq of <sup>99m</sup>Tc-MDP. Dynamic perfusion phase was acquired at the rate of 1 frame/sec for the first minute. Following which the blood pool phase was acquired with the imaging of the right feet after 05 min of the perfusion study. The static whole body skeletal phase was acquired after 3 hours gap. The bone scan findings revealed increased perfusion along with augmented blood pool and skeletal phase uptake in the region of mid-foot. This suggested active inflammation in the mid-foot and correlated with the clinically observed point of tenderness. To evaluate the exact anatomical site of uptake SPECT-CT (Single Photon Emission Tomography- Computed Tomography) of the right foot was performed. The SPECT-CT revealed abnormal tracer uptake in the space between inferior surface of talus and superior surface of calcaneum with normal cortical outlines of the talus and calcaneal surfaces (Figure 1). There was no soft tissue abnormality or bony changes noted on the computed tomographic image.

Based on the clinical and scintigraphic evidence he was diagnosed to have sinus tarsi syndrome. The patient was managed with local application of lignocaine injection into the tarsal sinus and has recovered after few weeks of rest.



**Figure 1.** Three-phase <sup>99m</sup>Tc-MDP Bone scan highlighting increased tracer uptake in the region of right ankle (Red box). SPECT-CT scan localising the uptake to the tarsal sinus. Corresponding CT reveals no bony abnormality in the tarsal and calcaneal bone. Features suggestive of inflammation in the tarsal sinus

### Discussion

Ankle sprain is caused because of sudden inward twisting of ankle leading to ligamentous injury. The ligament injury occurs on the lateral aspect of ankle resulting in pain, swelling and tenderness. Most of such cases are managed by the patient themselves with painkillers and RICE (R-rest; I-Ice; C-Compression; E- elevation). Patient visit the doctor because of persisting pain and other

residual ankle issues like instability. Studies have shown that at least 40% of acute ankle sprains result in residual ankle symptoms at 6 months (5, 6). At least 10-20% of acute ankle sprains result in residual ankle instability, pain, or other chronic symptoms (7-9).

Chronic lateral ankle instability is a feeling of recurrent sprain or history of recurrent instability, pain, swelling, and stiffness. If associated with pain it is commonly caused due to

Sinus Tarsi syndrome. Sinus Tarsi is a space on the lateral aspect of the foot between neck of the talus and superior aspect of the calcaneum. It contains blood vessels, nerves, fat and ligaments (10, 11). It is also site of nociceptive and proprioceptive receptors (12).

Clinically the syndrome is associated with tenderness over sinus tarsi and pain on forced inversion of the foot. Radiograph of the ankle has poor sensitivity and might show changes of osteoarthritis in advanced stages. MRI is presently the best imaging modality with a sensitivity and specificity of 73% and 94% respectively. The characteristic MRI feature of sinus tarsi is obliteration of fat in the sinus best noted on sagittal T1W/PD fat suppressed images. However in our case it could not be performed due to claustrophobia of the patient. Our patient had the typical symptom of tenderness in right ankle on weight bearing and had tenderness on the lateral aspect of mid-foot. As mentioned both the radiograph of the ankle and CT scan (conducted as a part of SPECT-CT) did not reveal any cortical irregularity, elevation of periosteum, periosteal reaction or dislocation/subluxation of bones. Inflammatory uptake of <sup>99m</sup>Tc-MDP in the talocalcaneal interface suggested the possibility of Sinus Tarsi syndrome.

Sinus Tarsi is confirmed by the cessation of symptoms upon injection of lignocaine into the sinus tarsi (13). Our patient was also managed with local anesthetic agent and is symptom free.

## Conclusion

Though MRI (Magnetic Resonance Imaging) becomes the gold standard for evaluation of sinus tarsi syndrome (13). However there are a subset of patients in which MRI may not provide a definite diagnosis as in a) claustrophobic patients b) patient with metallic implants c) patient with contrast allergy or other contraindications to MRI. MRI can also be equivocal or can be normal in conditions where there is no soft tissue edema. In this subset of patients bone scan has a potential to evaluate such cases. In our case denial to undergo an MRI prompted us to conduct bone scan. This not only helped in arriving at a diagnosis at the same time alleviated the patient's phobia.

This aspect of bone scintigraphy to diagnose this pathology is under-rated due to few published cases. Our literature search revealed only one such published case clearly highlighting the strength of bone scan with supportive images (14).

## Compliance with Ethical Standards:

**Funding:** The authors received no financial support for the research, authorship or publication of this article.

## Conflict of Interest

None to declare.

## Ethical approval

All procedures performed in studies involving human participants were in accordance with the ethical standards of the institutional and/or national research committee and with the 1964 Helsinki declaration and its later amendments or comparable ethical standards.

## Informed Consent

Informed consent was obtained from the patient for publication of his case/report and accompanying images.

## References

1. Ferkel RD, Karzel RP, Del Pizzo W, Friedman MJ, Fischer SP. Arthroscopic treatment of anterolateral impingement of the ankle. *Am J Sports Med* 1991; 19:440-446.
2. Ogilvie-Harris DJ, Gilbert MK, Chorney K. Chronic pain following ankle sprains in athletes: the role of arthroscopic surgery. *Arthroscopy* 1997; 13:564-574
3. Chicklore S, Gnanasegaran G, Vijayanathan S, Fogelman I. Potential role of multislice SPECT/ CT in impingement syndrome and soft-tissue pathology of the ankle and foot. *Nucl Med Commun.* 2013; 34:130-139.
4. Williams T, Cullen N, Goldberg A, Singh D. SPECT-CT imaging of obscure foot and ankle pain. *Foot Ankle Surg* 2012; 18:30-33
5. Braun BL. Effects of ankle sprain in a general clinic population 6 to 18 months after medical evaluation. *Arch Fam Med.* 1999 Mar-Apr. 8(2):143-8.
6. Gerber JP, Williams GN, Scoville CR, Arciero RA, Taylor DC. Persistent disability associated with ankle sprains: a prospective examination of an athletic population. *Foot Ankle Int.* 1998 Oct. 19(10):653-60 .
7. Löfvenberg R, Kärrholm J, Sundelin G, Ahlgren O. Prolonged reaction time in patients with chronic lateral instability of the ankle. *Am J Sports Med.* 1995 Jul-Aug. 23(4):414-7.
8. Bosein WR, Staples OS, Russel SW. Residual disability following acute ankle sprains. *J Bone Joint Surg Am.* 1955 Dec. 37- A (6):1237-43.
9. Balduini FC, Tetzlaff J. Historical perspectives on injuries of the ligaments of the ankle. *Clin Sports Med.* 1982 Mar. 1(1):3-12.
10. Lektrakul N, Chung CB, Lai Ym, Theodorou DJ, Yu J, Haghighi P, et-al. Tarsal sinus: arthrographic, MR imaging, MR arthrographic, and pathologic findings in cadavers and retrospective study data in

- patients with sinus tarsi syndrome. Radiology. 2001; 219 (3): 802-10 .
11. Rosenberg ZS, Beltran J, Bencardino JT. From the RSNA Refresher Courses. Radiological Society of North America. MR imaging of the ankle and foot. Radiographics. 2000; 20 Spec No: S153-79.
  12. Akiyama K, Takakura Y, Tomita Y, Sugimoto K, Tanaka Y, Tamai S. Neurohistology of the sinus tarsi and sinus tarsi syndrome. J Orthop Sci. 1999; 4(4) p: 299-303.
  13. Helgeson K. Examination and Intervention for Sinus Tarsi Syndrome. North American Journal of Sports Physical Therapy 2009 February; 4(1):29-37 (level: A1).
  14. Usmani S1, Abu Al Huda F, Al Kandari F. Three-Phase <sup>99m</sup>Tc MDP Bone Scintigraphy and SPECT-CT in Sinus Tarsi Syndrome. Clin Nucl Med. 2016 Apr; 41(4):e208-10.